

## CHOLINE AS A MEMBER OF THE VITAMIN B<sub>2</sub> COMPLEX

BY PAUL GYÖRGY, M.D., AND HARRY GOLDBLATT, M.D.

*(From the Babies and Childrens Hospital, the Institute of Pathology, and the Departments of Pediatrics and Pathology, School of Medicine, Western Reserve University, Cleveland)*

PLATES 1 AND 2

(Received for publication, April 1, 1940)

The experimental rations used in the study of the vitamin B<sub>2</sub> complex, especially of vitamin B<sub>6</sub> and its related factors, are, as a rule, low in content of choline. This is also true of the basal diet deficient in vitamin B<sub>6</sub> which one of us (1) has employed during the last seven years in the production of rat acrodynia. It consists of 18 parts of casein, 68 of sucrose or rice starch, 8 of melted butter fat, 4 of salt mixture, 2 of cod liver oil, and is supplemented with thiamine and riboflavin. This diet is deficient in choline, but, until recently, no pathological changes attributable to this defect have been recognized in animals fed this mixture. On the whole, the ration appeared to serve its purpose without any visible interference due to the absence of choline.

Oleson, Bird, Elvehjem and Hart (2) have lately reported the results of experiments in which choline (300 to 500 mg. per kilo) was added to the basal diet used for the studies of the vitamin B<sub>2</sub> complex, but these authors did not mention the reason for this precautionary measure.

The experimental data presented here not only substantiate the need for the incorporation of choline in a synthetic ration for rats used in the study of the vitamin B<sub>2</sub> complex, but they also support the important interrelationship between content of choline and the ratio cystine/methionine in the diet. Du Vigneaud, Chandler, Moyer and Keppel (3) have called attention to the close relationship of choline and methionine metabolism. At about the same time and independently, Griffith and Wade (4) have pointed out the importance of the ratio cystine/methionine together with a low choline content in the diet.

### EXPERIMENTS

Our first observations pertaining to the recognition of choline as a member of the vitamin B<sub>2</sub> complex were purely accidental. With the isolation and, later, with the synthesis of vitamin B<sub>6</sub> it became possible to go one step

further in the systematic analysis of the vitamin B<sub>2</sub> complex, namely, to incorporate crystalline vitamin B<sub>6</sub> in the diet which heretofore had contained only thiamine and riboflavin as the constituents of the vitamin B complex.

From the time that vitamin B<sub>6</sub>, as the third factor of the vitamin B complex, was added, in doses of 10 to 100 micrograms daily, to the diet of rats that had just been weaned and that weighed 20 to 35 gm., a growing number of fatalities was noted between the 11th and 15th days of the experiment. Death was preceded by failure to gain weight or even by decline of weight, but by no other visible signs of a specific disease.

#### *Gross Examination*

At autopsy, in the gross, the most obvious abnormalities were observed in the kidneys and liver. In most animals that died before the 15th day, both kidneys were large, with a purplish red surface color, apparently due to intracapsular and subcapsular hemorrhage. On section, the cortex was diffusely dark red, or there were alternating patches of dark red and yellow throughout the cortex, in contrast to the grayish yellow color of the medulla. The color of the surface and of the cross sections of the liver was, as a rule, a uniformly light yellow, suggesting a high content of fat.

#### *Microscopic Examination*

Microscopically, the kidney showed a striking picture which varied in both type and degree. (See Fig. 1.) Between the fibers of connective tissue in the capsule and also beneath the capsule, there was a variable amount of recently extravasated blood. The most pronounced lesion of the parenchyma consisted of almost complete necrosis of the tubules of the cortex, without destruction of the architecture. In most kidneys the outline of the tubules was still recognizable. In the neighborhood of the necrotic tubules there was a variable amount of infiltration with polymorphonuclear leucocytes. This type of exudation was never great and was absent or only very slight in many of the kidneys. Within the lumen of some of the convoluted tubules, especially the distal ones, and within the loops of Henle, as well as in some of the collecting tubules, there was a variable amount of homogeneous, acidophilic material in the form of casts of the lumen. Even in those kidneys in which the cortex showed the greatest pathological change, some of the collecting tubules showed only this hyaline acidophilic material in the lumen; their lining epithelium showed no microscopic abnormality. A striking feature of the diffuse necrosis of the cortex was the intense hyperemia of the interstitial tissue between the tubules and surrounding the glomeruli. The hyperemia was so intense in the cortex of some of the kidneys that it had the appearance of hemorrhage, and imparted the dark red color to the tissue observed in the gross. Definitely recognizable extravasation of blood was unusual, however, except at the extreme periphery of the cortex of some kidneys in which the blood appeared to have infiltrated into the cortical tissue from the subcapsular hemorrhage and did not seem to have originated from capillaries within the cortex itself. Hemorrhage in the capsular space around

the glomerular tufts or within the tubules of either cortex or medulla was not observed. In some of the kidneys in which the cortex was practically completely necrotic, glomeruli showed some degenerative change characterized mainly by swelling of the cytoplasm of the surface epithelium. A few of the glomeruli were intensely hyperemic, but there was no actual necrosis of the glomeruli, and there was no sign of inflammation. There were no recognizable pathological changes in the wall of the blood vessels, either large or small, and in none of these was premortem thrombosis observed. In some of the kidneys there was diffuse necrosis of the cortex without hyperemia, but with hemorrhage into and under the renal capsule. In other kidneys there were patches of cortical necrosis, with or without hyperemia, alternating with patches of hydropic degeneration and cloudy swelling. In such kidneys also a variable number of the tubules, especially those in the region at the junction of cortex and medulla, contained hyaline material in the lumen. Several kidneys showed marked diffuse hydropic degeneration of most tubules in the cortex with only a relatively small number of necrotic ones interspersed among them and with hyperemia of the interstitial tissue.

Microscopic examination of the liver showed the typical picture of marked diffuse fat infiltration (see Fig. 2), the cytoplasm of almost all the cells in the lobules being occupied by one vacuole or by a few large vacuoles. Occasionally a liver showed only a patchy lobular distribution of the fat or a moderate diffuse deposit limited to the periphery of the lobules.

Of 175 rats fed, from the first day after they were weaned, the experimental diet supplemented not only with thiamine and riboflavin (20 micrograms daily of each) but also with vitamin B<sub>6</sub> in an amount varying from 10 to 100 micrograms daily, 17 died between the 11th and 15th experimental days. 2 of these rats died on the 11th, 3 on the 12th, 3 on the 13th, 7 on the 14th and 2 on the 15th day. At autopsy, all showed typical capsular hemorrhage and cortical necrosis of the kidneys. The livers were light yellow and large in the gross.

Of this group of 175 rats, 5 more died in the further course of the experiment. Rat 32-00 died on the 17th day, rat 30-25 on the 23rd, rat 45-27 on the 24th day of the experiment, rat 26-13 after 4 weeks, and, finally, rat 30-76 after 11 weeks. In the gross, these kidneys were characterized by irregular yellow patches with, occasionally, small foci of hemorrhage under the renal capsule. In several of the kidneys the surface was roughly nodular and the kidney almost invariably was smaller than natural. Microscopically (see Fig. 3), there was a small amount of blood pigment within the capsule of some of the kidneys, but there was little or no recently extravasated blood within or under the capsule, and many kidneys showed no sign of previous hemorrhage within or beneath the capsule. Most of the kidneys showed considerable shrinkage of the cortex, so that glomeruli, which are not naturally present immediately beneath the capsule, were closely crowded together in the periphery of the shrunken cortex, many immediately beneath the capsule. There appeared to be no reduction in the number of glomeruli, but many of them were smaller than natural. There was little hyperemia in any portion of the kidney. In a few small foci in the cortex of some of the kidneys, occasional tubules, mainly proximal convoluted tubules, showed remnants of necrotic lining epithelium. In the cortex of some of the most atrophic kidneys, there was at least a relative increase of interstitial fibrous connective tissue. In the capsule of a few kidneys there was slight infiltration by lymphocytes. In the intermediate zone between cortex and medulla, a number of the tubules, mainly distal convoluted tubules

and loops of Henle, contained hyaline material in the form of casts. Some of the collecting tubules also contained these hyaline casts. Blood vessels showed no microscopic abnormality. There was no recent or old thrombosis of large or small blood vessels. These changes occurred invariably in animals that survived 16 days or longer and appeared to represent only a later stage of the acute, diffuse necrosis of the cortex. This will be referred to as the subacute or presumably healing stage of this process.

Altogether 22 rats of the group of 175 rats to which vitamin B<sub>6</sub> was administered prophylactically from the beginning of the experiment seemed to have succumbed to renal injury. In contrast, in a group of about 3,000 rats fed the same basal diet, but to which vitamin B<sub>6</sub> was not administered, all examined postmortem, only 3 rats, in the gross, showed the characteristic capsular and subcapsular hemorrhage and, microscopically, bilateral acute cortical necrosis of the kidneys. Microscopically, 2 additional rats showed the subacute type of lesion; in one of these the lesion developed after vitamin B<sub>6</sub> had been administered, in a later stage, in order to cure an already fully developed acrodynia. If this last rat is added to the first group, the total number of animals that received vitamin B<sub>6</sub> in which the renal lesions developed is brought to 23, whereas not more than 4 rats of the much larger group kept on a diet free from vitamin B<sub>6</sub> showed evidence of the same kind of renal injury. On a percentage basis, about 15 per cent of the first group stands against 0.1 to 1.2 per cent of the second group.

It should be noted that apart from the rats with positive and specific findings, 73 animals, examined macroscopically and microscopically, showed no significant pathological changes in the kidneys. The animals in which the findings did not contribute to the diagnosis are not included in the present analysis.

With the mounting frequency of losses caused apparently by severe injury to the kidneys and the liver, the need for a closer investigation of the etiology of these lesions was indicated.

Hartwell (5) had revealed that in young rats kept on a high edestin diet there was a high percentage of fatalities. At autopsy, she observed in these rats or in rats killed after 14 days of the experiment "kidneys of a deep purple colour and gorged with blood." This description is suggestive of the acute lesions described here. She reported also that marmite, which is a potent commercial yeast autolysate, when added to this diet in adequate doses rendered innocuous the harmful edestin diet. Replacement of edestin by casein or by egg albumin proved equally beneficial, for the renal lesions did not develop in rats fed these diets. Curtis and Newburgh (6) and especially Cox, Smythe and Fishback (7) reported the finding of similar renal lesions in rats fed a casein diet to which cystine was added. Cox, Smythe and Fishback (7) emphasized the fact that the specific renal lesions occurred only in young animals and also stated that some of the young rats that had probably had the renal lesions recovered and grew normally without change of ration.

The question of the effect of cystine has received substantial clarification by the recent work of du Vigneaud, Chandler, Moyer and Keppel (3), as well as by that of Griffith and Wade (4). The results of these investigations have, at the same time, shed light on our own findings, in linking them to deficiency of choline. Du Vigneaud and his coworkers have conclusively shown that choline is needed by the rat for the transformation of homocystine (homocysteine) into methionine, which is an essential amino acid, whereas Griffith and Wade made it highly probable that in the absence of choline a high cystine/methionine quotient is responsible for the hemorrhagic renal lesions described heretofore in cystine intoxication, and that the poisonous effect can be neutralized by adequate intake of choline.

In view of these considerations, fat infiltration of the liver, which has been known for a long time as a regular manifestation of lack of choline in the diet (8), and the renal lesions in our rats can be attributed to an absolute or relative deficiency of choline (relative to the cystine/methionine quotient in the diet).

The application of these analogies presupposes the following conditions: (a) the possible prevention of the lesions in kidney and liver by administration of choline and (b) the identity of the lesions seen in our rats fed the original casein diet with those produced by the addition of cystine.

The first requirement was fulfilled when no fatalities due to renal lesions of the specific type here described were noted in a group of 109 rats that received from the beginning of the experiment 2 mg. daily of choline and daily amounts of vitamin B<sub>6</sub> varying from 10 to 100 micrograms, in addition to the experimental casein diet which contained thiamine and riboflavin.

As circumstantial evidence in favor of the relationship existing between the specific hemorrhagic renal lesions and the cystine/methionine quotient, the fact should also be noted that substitution of 10 per cent of egg white for 10 per cent of the sucrose in the basal diet, with a corresponding change in favor of methionine in the quotient cystine/methionine, definitely reduced the nephrotoxic effect of the diet.

The second requirement was put to a test when 135 rats were divided into seven groups, each of which received a different ration as indicated in Table I, in which the results of the experiments, as determined by macroscopic and microscopic examination, are summarized.

The renal lesions seen in the rats that were placed on the diet containing cystine, with or without vitamin B<sub>6</sub>, and that died before the 16th experimental day were, in the gross, indistinguishable from those seen in the rats fed a casein diet supplemented with vitamin B<sub>6</sub> without added cystine. 8 rats that received the supplement of cystine died before the 11th day, one as early as the 7th day. It should be emphasized that in several rats killed on the 16th day the microscopic examination of the lesions revealed

distinct signs of progressive recovery and healing. These rats often exhibited symptoms of sickness, such as anorexia and loss in weight, but they were definitely improving before they were killed. These observations are in accord with those of Cox, Smythe and Fishback (7), who also described recovery in rats receiving a diet high in content of cystine without any change in the experimental ration.

The effect of administration of 2 mg. of choline daily was uniform in all rats, whether they received cystine or not. With the exception of one rat

TABLE I

Group	Supplement to basal diet	No. of rats	No. of rats that died before 16th experimental day	No. of rats killed on 16th day	No. of rats with renal lesions		No. of rats with fat infiltration of liver				
					A-acute	Sub-acute	++++	+++	++	+	-
1	Thiamine and riboflavin	21	0	21	0	1	12	5	3	0	1
2	Thiamine, riboflavin and cystine	14	4	10	5	5	12	1	1	0	0
3	Thiamine, riboflavin, cystine and choline	14	0	14	0	1	8	0	1	4	1
4	Thiamine, riboflavin and vitamin B <sub>6</sub>	32	2	30	5	5	27	1	2	0	1*
5	Thiamine, riboflavin, vitamin B <sub>6</sub> and choline	18	0	18	0	0	3	3	3	5	4
6	Thiamine, riboflavin, vitamin B <sub>6</sub> and cystine	19	5	14	8	6	15	1	0	1	2
7	Thiamine, riboflavin, vitamin B <sub>6</sub> , choline and cystine	17	0	17	0	0	5	5	4	2	1

\* Liver of one other rat was not examined.

in group 2 which showed subacute changes, the renal lesions did not develop in these animals. That vitamin B<sub>6</sub> has a definitely provocative effect on the production of the specific renal lesions again becomes manifest in comparison of groups 1 and 4 in Table I.

It has been mentioned that in addition to the renal lesions, fat infiltration of the liver was a regular finding in all the groups that did not receive choline. Choline in the dosage used (2 mg. daily) had a slightly or, in group 5, a definitely lipotropic effect, with the result that the histologically demonstrable fat infiltration was distinctly decreased or absent. Here

again the results are in favor of the assumption of a deficiency of choline in rats kept on basal rations commonly used in the study of the vitamin B<sub>2</sub> complex. Griffith and Wade (4) have shown that whereas 0.4 mg. of choline per gm. of diet regularly prevents renal lesions, the fat infiltration of the liver can be prevented or cured only by higher doses (2 mg. of choline per gm. of the experimental diet).

Apart from the renal lesions and fat infiltration of the liver, of the group of young rats fed the basal diet supplemented by thiamine, riboflavin and vitamin B<sub>6</sub>, in 4 rats there developed severe flaccid paralysis of the hind legs, such as has been described by Sure (9) and attributed by this author to deficiency of choline. In the group of rats that received choline, no similar neurological manifestations were encountered.

The addition of 2 mg. of choline daily had no appreciable preventive effect either on suprarenal hemorrhage or on panmyelophthisis (10) in rats fed a diet deficient in vitamin B<sub>6</sub>.<sup>1</sup> Furthermore, in only 2 rats was hemorrhagic necrosis of the suprarenal glands found associated with cortical necrosis of the kidneys, while patchy or diffuse necrosis of the liver (11) was not observed in any of the animals with cortical necrosis of the kidneys.

#### DISCUSSION

In rats kept on a diet containing 18 per cent of casein, 8 per cent of melted butter fat, 68 per cent of sucrose, 4 per cent of salt mixture and 2 per cent of cod liver oil, with a daily supplement of 20 micrograms each of thiamine and riboflavin, the only lesion which could be attributed to deficiency of choline was, as a rule, fat infiltration of the liver. The addition of vitamin B<sub>6</sub> (10 to 100 micrograms daily) was followed in about 15 per cent of the experimental rats by necrosis of the renal cortex, with other characteristic histological findings.

The data presented in this communication serve to illustrate the importance of choline as a potential member of the vitamin B<sub>2</sub> complex<sup>2</sup> and the aggravating influence of vitamin B<sub>6</sub> on the specific effect of choline deficiency on the kidney. Inasmuch as recently the determining factor for the need of choline has been found (4) in the ratio cystine/methionine

<sup>1</sup> In a more recent series of 169 rats fed the diet deficient in vitamin B<sub>6</sub> with the addition of larger amounts of choline (2 mg. of choline per gm. of diet), incidence of hemorrhage in the suprarenal glands, panmyelophthisis and hepatic injury remained practically unchanged.

<sup>2</sup> That choline may well be considered a member of the vitamin B complex has also been asserted by King (12, page 389) and by du Vigneaud, Chandler, Moyer and Koppel (3, page 75).

in the diet, the present experiments show that this quotient is by no means a fixed figure, but may be profoundly influenced by other conditions, such as content of vitamin B<sub>6</sub> in the diet. Griffith (13) found similar relationships to the absolute amount of cystine and methionine in the ration and to the nature of the fat added to the diet in the form of lard or cholesterol.

As to the character of the pathological changes in the kidney and the liver, it can be stated that they are identical with those caused by cystine intoxication (6, 7). In earlier and even in more recent investigations the renal lesions were produced by a diet containing casein, to which cystine was added, or by a diet containing proteins particularly rich in cystine, such as edestin or fibrin. In view of the fact that identical lesions develop in rats on a simple casein diet containing vitamin B<sub>6</sub> but without added cystine, these older studies now appear in a new light and need thorough reconsideration also from the point of view of practical implications.

The possible identity of the renal lesions in rats with bilateral symmetrical cortical necrosis of the kidneys which occurs in human beings, frequently in the pregnant female, should be mentioned. The nature and distribution of the cortical necrosis and the almost invariable bilateral involvement of the kidneys are suggestive of a similarity of the two conditions. There is, however, at least one definite and significant difference between the microscopic pictures of the two. Vascular thrombosis, which has been described in the human kidneys, and to which pathogenetic significance has been ascribed (14), was not observed in the kidneys of the animals. The pathogenesis of the renal lesions in the animals must therefore be attributed to a nephrotoxic effect acting directly on the parenchyma, and not to ischemia brought about by vascular thrombosis. Since thrombosis is not always found even in the human kidneys, and since it is sometimes not widely distributed in these kidneys, there remains the possibility that bilateral symmetrical cortical necrosis in human beings is also due to a nephrotoxic effect, with or without angiospasm, determined by a dietary deficiency, and that the thrombosis, as has been suggested by Ash (15), is only a terminal event that plays no primary part in the pathogenesis of the renal lesions.

#### SUMMARY

The experimental rations commonly used in studies on the vitamin B<sub>2</sub> complex are, as a rule, low in content of choline.

Addition of vitamin B<sub>6</sub> has an aggravating influence on the specific effect of deficiency of choline, especially with regard to the development of cortical necrosis of the kidneys.

The acute and subacute lesions associated with this specific type of renal injury are described.



The renal lesions and fat infiltration of the liver, observed in rats kept on a vitamin B free diet, supplemented with thiamine, riboflavin and vitamin B<sub>6</sub>, are indistinguishable from those attributed hitherto to cystine intoxication.

Attention is drawn to the rôle of choline as a potential member of the vitamin B<sub>2</sub> complex and, in this connection, to the importance of the ratio cystine/methionine in the diet.

## BIBLIOGRAPHY

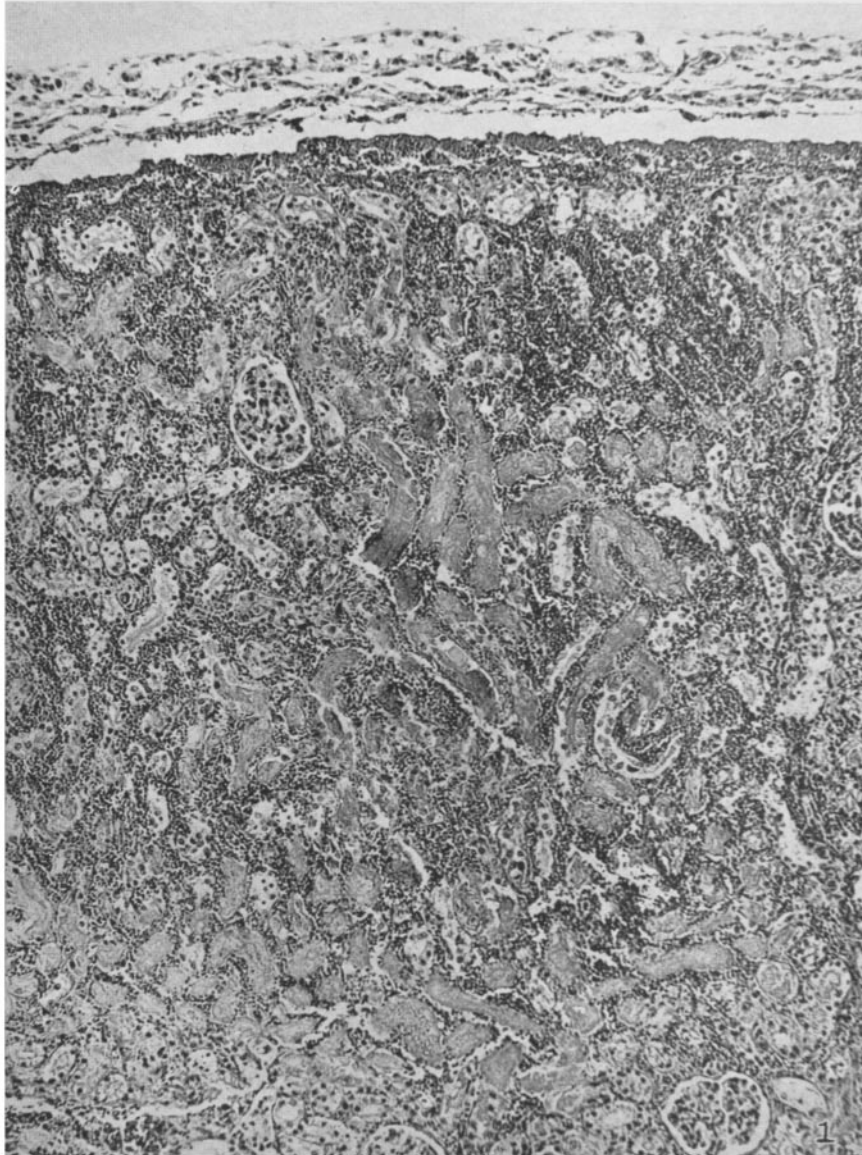
1. György, P., *Biochem. J.*, 1935, **29**, 741.
2. Oleson, J. J., Bird, H. R., Elvehjem, C. A., and Hart, E. B., *J. Biol. Chem.*, 1939, **127**, 23. Oleson, J. J., Elvehjem, C. A., and Hart, E. B., *Proc. Soc. Exp. Biol. and Med.*, 1940, **43**, 161.
3. du Vigneaud, V., Chandler, J. P., Moyer, A. W., and Keppel, D. M., *J. Biol. Chem.*, 1939, **128**, cviii; 1939, **131**, 57.
4. Griffith, W. H., and Wade, N. J., *Proc. Soc. Exp. Biol. and Med.*, 1939, **41**, 188, 333; *J. Biol. Chem.*, 1939, **131**, 567.
5. Hartwell, G. A., *Biochem. J.*, 1928, **22**, 1212.
6. Curtis, A. C., and Newburgh, L. H., *Arch. Int. Med.*, 1927, **39**, 817.
7. Cox, G. J., Smythe, C. V., and Fishback, C. F., *J. Biol. Chem.*, 1929, **82**, 95.
8. Best, C. H., and Ridout, J. H., in Luck, J. M., Annual review of biochemistry, Stanford University, Annual Reviews, Inc., 1939, **8**, 349.
9. Sure, B., *J. Nutrition*, 1940, **19**, 71.
10. György, P., Goldblatt, H., Miller, F. R., and Fulton, R. P., *J. Exp. Med.*, 1937, **66**, 579.
11. György, P., and Goldblatt, H., *J. Exp. Med.*, 1939, **70**, 185.
12. King, C. G., in Luck, J. M., Annual review of biochemistry, Stanford University, Annual Reviews, Inc., 1939, **8**, 371.
13. Griffith, W. H., *J. Biol. Chem.*, 1940, **132**, 639.
14. Weaver, R. G., and von Haam, E., *Arch. Int. Med.*, 1939, **63**, 1084.
15. Ash, J. E., *Am. J. Med. Sc.*, 1933, **185**, 71.

## EXPLANATION OF PLATES

## PLATE 1

FIG. 1. Rat 33-40. Fed diet deficient in vitamin B complex (including choline), with supplement of thiamine chloride, riboflavin and vitamin B<sub>6</sub>.

Kidney: Acute diffuse necrosis and hydropic degeneration of tubules of cortex and intense hyperemia of the interstitial tissue. There is hemorrhage into and beneath the renal capsule and some interstitial extravasation of blood in the periphery of the cortex. Section stained with hematoxylin and eosin. × 150.



(György and Goldblatt: Choline as member of vitamin B<sub>2</sub> complex)

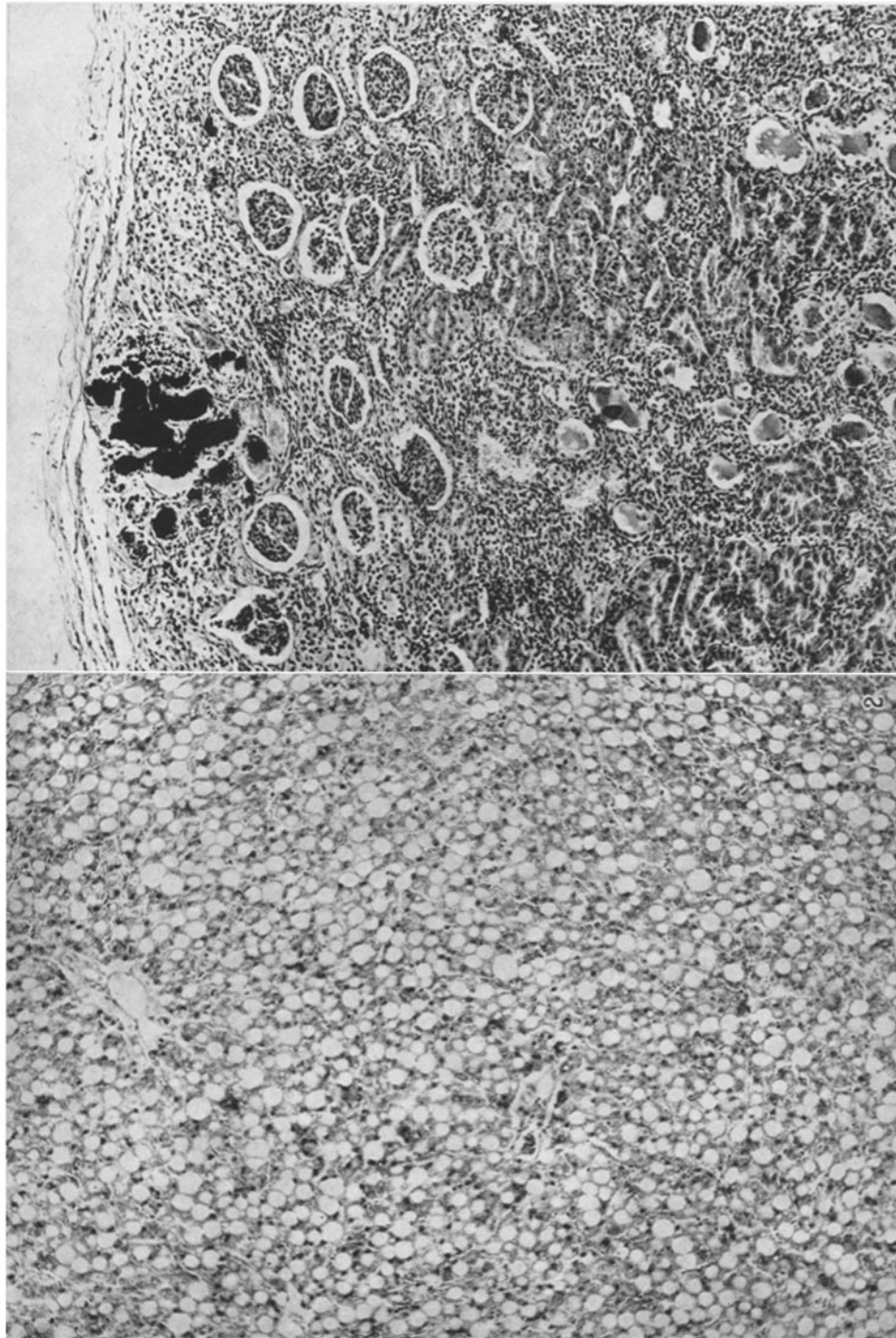
PLATE 2

FIG. 2. Rat 45-66: Diet and supplements like those of rat in Fig. 1.

Liver: Typical picture of marked diffuse fat infiltration. Section stained with hematoxylin and eosin.  $\times 138$ .

FIG. 3. Rat 31-08: Diet and supplements like those of rat in Fig. 1.

Kidney: Subacute lesion. Note remnants of necrosis and calcification of tubules, beginning fibrosis of cortex, and hyaline material in lumen of distal convoluted tubules and loops of Henle. Hematoxylin and eosin.  $\times 138$ .



(György and Goldblatt: Choline as member of vitamin B<sub>2</sub> complex)