

Reconstruction of Digital Defects with the Free Proximal Ulnar Artery Perforator Flap

Luigi Troisi, MD, PhD,
FEBOPRAS*

Francesco Zanchetta, MD*†

Juan Enrique Berner, MD, MSc,
FRCS(Plast) ‡§

Giuseppe Mosillo, MD*

Giorgio Eugenio Pajardi, MD*

Background: The aim of post-traumatic digital reconstruction is to restore form and function, allowing early rehabilitation. In the absence of feasible local options, free tissue transfer can be a versatile and reliable alternative. The aim of this study was to describe our experience with the use of the free proximal ulnar artery perforator flap (PUPF).

Methods: Our prospectively maintained free flap database was inquired for patients that had undergone digital reconstructions with free PUPFs.

Results: Six patients that underwent digital reconstruction were eligible. The ipsilateral forearm was donor site of choice, with all flaps based on a perforator of the ulnar artery, without the need to compromise the main vessel. A superficial vein was routinely included with the flap. No flap failures were encountered. Mean hospital stay was 5.5 days, and all patients achieved a satisfactory functional result.

Conclusions: The proximal ulnar perforator free flap offers an alternative for finger reconstruction, having the advantage of including thin and hairless skin from the proximal ulnar forearm. The vascular anatomy of the ulnar perforators seems to be constant. Furthermore, donor site morbidity is low, as the ulnar artery is not harvested with the flap, the donor site defect can generally be closed directly, and the scar is well concealed. (*Plast Reconstr Surg Glob Open* 2022;10:e4054; doi: 10.1097/GOX.0000000000004054; Published online 27 January 2022.)

INTRODUCTION

Achieving timely soft tissue cover for traumatic digital wounds is crucial for ensuring healing of the damaged deep tissues and starting early rehabilitation. Functional and aesthetic considerations are important when selecting a reconstructive modality. An ideal reconstruction should not only resemble the quality of the lost skin, but also have in mind the functional result and the impact of any potential donor sites.

Homodigital¹⁻⁴ and heterodigital⁴⁻⁶ flaps can be reliable local alternatives, offering simpler solutions for smaller defects.⁷ However, these are associated with donor site

morbidity, either from the same or adjacent fingers.⁸ This inevitably can result in additional scars, potential swelling and stiffness within an already injured hand. Propeller and pedicled flaps from the dorsum of the hand and forearm have also been described,⁹⁻¹¹ but these rarely reach the distal segments of the fingers. These limitations explain why there has been an increasing interest in the use of free tissue transfer for resurfacing complex digital wounds.^{7,8,12-18}

The ulnar artery supplies the medial skin of the forearm via multiple perforators, most of which are musculocutaneous.¹⁹ On average there are five to seven ulnar artery perforators with a caliber equal to or greater than 0.5 mm, and an average length of 27 mm. Each perforator is able to nourish an area of skin of approximately 19 to 33 cm².²⁰⁻²³

Most anatomical studies have shown that there are constant ulnar artery perforators between the proximal third and the middle third of the forearm, in the middle of the forearm, and between the middle third and the distal third of the forearm.^{22,23} Proximally, these tend to have a musculocutaneous course within the muscle bellies of the flexor carpi ulnaris or the flexor digitorum superficialis, perforating the fascia along a longitudinal axis that

*From the *Reconstructive Microsurgery Service, University Department of Hand Surgery and Rehabilitation, San Giuseppe Hospital, IRCCS MultiMedica Group, Milan, Italy; †Plastic Reconstructive and Aesthetic Surgery Unit, University of Messina, Policlinico "G. Martino," Messina, Italy; ‡Plastic Surgery Department, The Newcastle upon Tyne Hospitals NHS Trust; and §Kellogg College, University of Oxford. Oxford, United Kingdom*
Received for publication May 15, 2021; accepted November 9, 2021.

Copyright © 2022 The Authors. Published by Wolters Kluwer Health, Inc. on behalf of The American Society of Plastic Surgeons. This is an open-access article distributed under the terms of the [Creative Commons Attribution-Non Commercial-No Derivatives License 4.0 \(CCBY-NC-ND\)](https://creativecommons.org/licenses/by-nc-nd/4.0/), where it is permissible to download and share the work provided it is properly cited. The work cannot be changed in any way or used commercially without permission from the journal.

DOI: 10.1097/GOX.0000000000004054

Disclosure: The authors have no financial interest to declare in relation to the content of this article.

Related Digital Media are available in the full-text version of the article on www.PRSGlobalOpen.com.

follows the course of the medial cutaneous nerve of the forearm.²⁴ This perforator has demonstrated to supply an area of skin in the proximal ulnar forearm that can be harvested as a free flap.

The aim of this study was to describe our experience with the use of the free proximal ulnar perforator flap (PUPF) in the reconstruction of digital defects.

MATERIALS AND METHODS

A review of our prospective free flap database was undertaken, including all patients that had a proximal ulnar artery perforator flap for reconstruction of digital injuries. Demographic data, along with information regarding the causing injury and reconstruction modalities, were recorded using a predefined gathering spreadsheet. Functional outcomes, photographs, and patient satisfaction were also recorded.

From July 2019 to September 2019, six proximal ulnar perforator free flaps were used for the reconstruction of six digital defects by the first author. The alternative of having an amputation of the affected digit and its benefits and drawbacks compared with a reconstruction were routinely discussed preoperatively. All patients were men, with a mean age of 39.5 years, ranging from 13 to 63 years of age. For all cases, only one finger was reconstructed with a free PUPF.

Five patients suffered crush injuries and one sustained degloving of his digit. The size of the defects ranged from 4 × 3.5 cm to 11 × 3 cm. All cases presented not only by a skin defect but also associated soft tissue and bony component (Table 1). The size of the flaps raised ranged from 4 × 3.5 cm to 9 × 7 cm with a pedicle length between 3 cm and 5 cm. For all these cases, a perforator of the ulnar artery between the proximal third and the medial third of the forearm was used, including a superficial vein for achieving venous drainage.

DVT prophylaxis, as well as antibiotic and pain killers were prescribed postoperatively. Bed rest was indicated for 3 days. For fractures stable enough to be mobilized, rehabilitation started 2 weeks following surgery.

SURGICAL TECHNIQUE

The ipsilateral forearm of the injured finger is preoperatively marked by drawing a line between the pisiform bone and the medial humeral epicondyle. Subsequently, the point between the proximal third and the middle third is identified and marked. The actual presence of a perforator in the established area is assessed with a handheld Doppler probe. We routinely use a thermal camera (FLIR ONE, FLIR Systems. Oregon) for assessing the

Takeaways

Question: Is the free proximal ulnar artery perforator flap a good option for digit reconstruction?

Findings: The results show that the free proximal ulnar artery perforator flap is a reliable flap which provides thin and hairless skin.

Meaning: The free proximal ulnar artery perforator flap could be a good option to reconstruct digital defects.

chosen perforator along with the presence of superficial veins (Fig. 1).

With the patient supine and under general anesthesia, adequate wound debridement is followed by a careful assessment of the defect size and shape. Using reverse planning, the shape of the required flap is drawn on the donor site (Fig. 2). We routinely use a tourniquet-control for harvesting this flap. A second surgeon is able to prepare the recipient vessels while the flap is being raised.

An incision along the radial margin of the planned skin paddle is used to expose and incise the fascia. Dissection proceeds ulnarly in the subfascial plane until a suitable perforator is seen in its course toward the skin (Fig. 3A). If necessary, the flap design can be adjusted at this stage. The perforator is then followed between the flexor carpi ulnaris and the flexor digitorum superficialis muscles or through the flexor carpi ulnaris muscle belly and isolated from the surrounding tissues up to its point of origin from the ulnar artery (Fig. 3B). One or more superficial veins are always included in the flap, while aiming to preserve the medial cutaneous nerve of the forearm.

Once the flap has been harvested, the tourniquet is released to evaluate the perfusion of the flap. (See Video 1 [online], which shows the flap reperfusion after tourniquet releasing.) Only when the vascular perfusion of the flap is stable, the pedicle is divided flush on its origin from the ulnar artery (Fig. 4), and the flap is transferred to the recipient site. The recipient vessels usually are a dorsal vein of the injured finger or of the hand and a digital artery, usually ipsilateral to the defect. For the venous anastomosis, the superficial vein of the flap is always preferred due to its larger caliber.

RESULTS

In all cases, it was possible to intraoperatively find the perforator that had been identified using thermography. Sometimes a small discrepancy was reported

Table 1. Case Series Included in This Study

	Sex	Age	Digit	Trauma	Wound (cm)	Associate Lesions
1	M	31	III	Crush injury	11 × 3	P3 necrosis + partial necrosis P2
2	M	13	IV	Crush injury	5 × 3	P3 amputation
3	M	63	II	Crush injury	4 × 3.5	Osteomyelitis P2
4	M	31	I	Crush injury	7 × 3	Intrarticular fracture (IF) + EPL laceration
5	M	45	III	Ring avulsion	9 × 3	None
6	M	54	IV	Crush injury	7 × 4	Crush injury II digit, amputation P3 III digit, laceration V digit

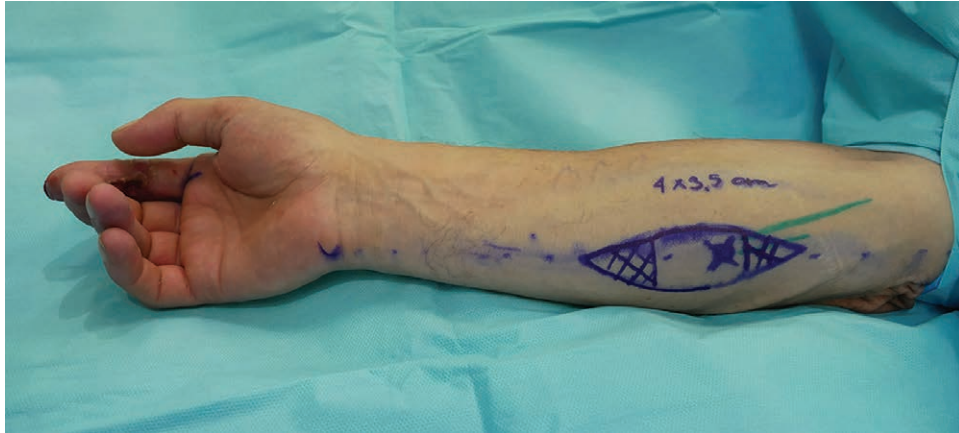

Fig. 1. Preoperative photograph showing marking of the flap, including a previously identified perforator. A superficial vein is marked with a green line.

between the supposed position of the perforator and the effective localization; in no one case did this force a plan change, but a partial change of the flap position was sufficient.

In five cases, a digital artery was used for the anastomosis, while in one case the dorsal branch of the radial artery was used in an end-to-side fashion. Similarly, in five cases, a dorsal superficial digital vein was used, and in one case, the vena comitans of the dorsal branch of the radial artery was used as recipient vein. In three cases, the donor site was closed directly, while in the other three a dermal

substitute was used in combination with partial primary closure (Table 2).

All the flaps survived without any partial or total necrosis. Re-exploration or revision surgery was not necessary. The mean postoperative hospital stay was 5.5 ± 0.8 days. Mean follow-up was 18.5 months (from 7 to 22 months) (Fig. 5). Functional assessment was evaluated by using the PRWHE instrument,²⁵ obtaining an average score of 14 out of 100 (ranging from 3 to 2.5) as all the patients achieved a good functional result (Table 3). (See Videos 2 and 3 [online], which show

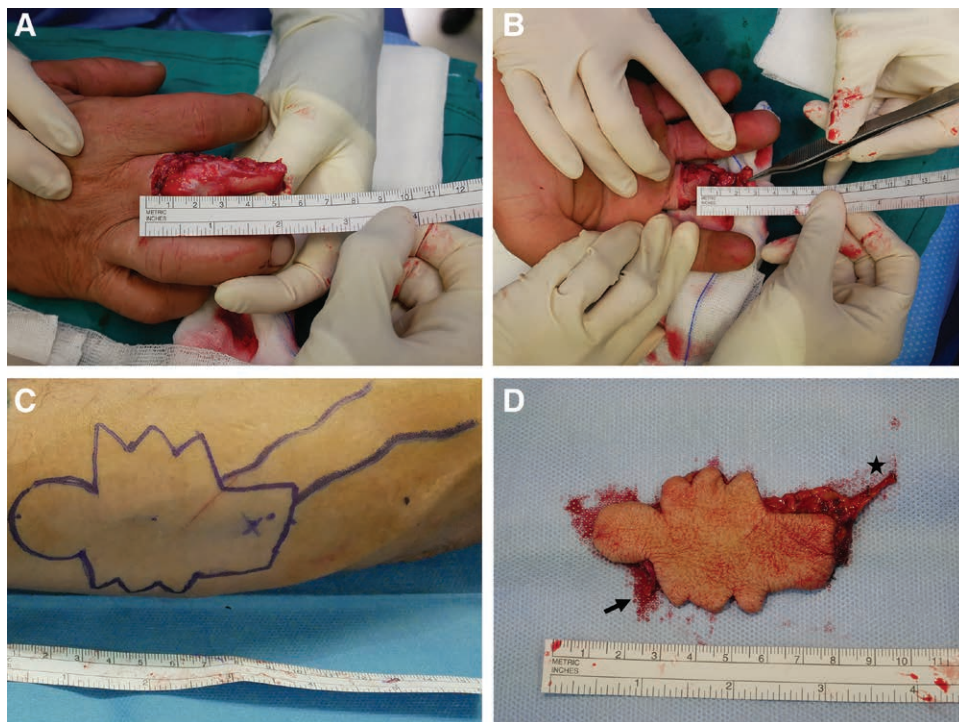


Fig. 2. Case involving a patient that sustained a degloving injury to his right third finger. A, B, preoperative dorsal and pal-mar views. C, Flap markings. This shape was designed to avoid straight scars along the digit with a round distal extension to cover the tip. D, The detached flap with its perforator (→) and superficial vein (★).

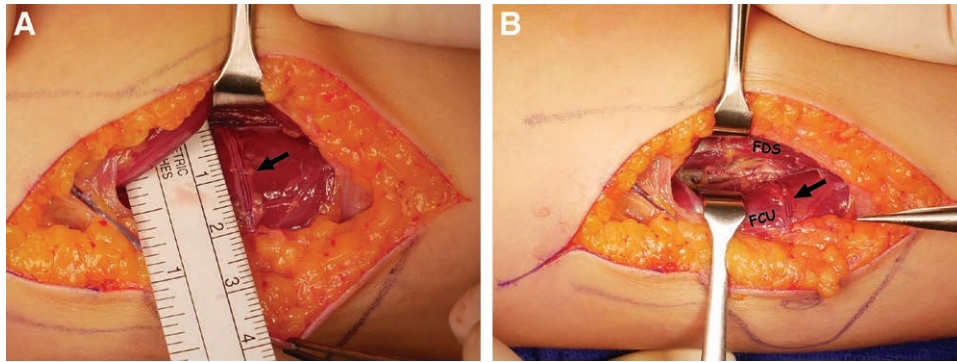


Fig. 3. Intraoperative views. A, perforator (→) . B, perforator (→) identified between the flexor carpi ulnaris (FCU) and flexor digitorum superficialis (FDS) tracked up to the ulnar artery.

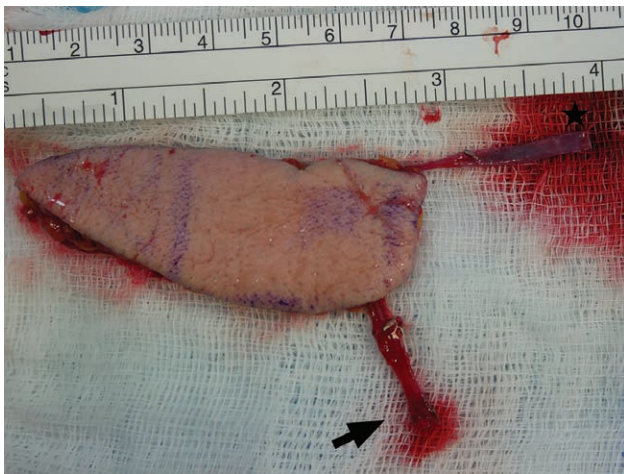


Fig. 4. Intraoperative photograph showing the detached flap with its perforator (→) and superficial vein (★).

the physiotherapist session 8 weeks postoperative.) (See **Video 4 [online]**, which shows the functional result 8 weeks postoperative.) Regarding sensation recovery, all patients were satisfied; no signs of neuroma formation or cold intolerance have been detected to date. The subjective result from the aesthetic point of view was considered very good by one patient, good by four patients, and sufficient by one patient. No one patient complained about the thickness of the flap, and a debulking procedure was never necessary. No patients have complained of paresthesia in the donor forearm, and no sensitivity or strength deficit in the ipsilateral hand and forearm were reported.

DISCUSSION

The free ulnar artery perforator flap was originally described by Lovie et al.²⁶ It was based on the septocutaneous perforators of the ulnar artery and praised for its reliability, versatility, and ease of harvesting. This flap relied on a segment of the ulnar artery distally to the origin of the interosseous artery. Lovie highlighted the multiple advantages of this flap such as the absence of hair, the greater ease of direct closure of the donor site, and the minor evidence of the residual scar compared with radial artery-based flaps (**Fig. 6**). Another advantage of this flap is that if the donor site required skin grafting, better results were usually obtained due to the lack of tendon exposure in this area.^{27,28}

Despite its extreme utility, the ulnar flap described by Lovie et al²⁶ involves the compromise of the ulnar artery. However, if only a short segment of the ulnar artery is harvested, the main vessel is still suitable for direct repair of the stumps.^{29,30} This approach can be completely overcome by harvesting a true ulnar perforator flap, entirely preserving the ulnar artery.³¹

In our experience, the use of a proximal ulnar perforator flap has had multiple advantages. The skin in this area is thin, pliable, and hairless. The location of the donor site is more conceivable, in the medial proximal forearm. In addition, as the forearm is wider proximally, it allows the harvesting of larger flaps. The length of the flap may be extended so that with a single flap, a complete finger or two different wounds in two adjacent fingers may be resurfaced.²³ If a skin graft is required, tendon exposure is minimal in this area. Harvesting a sensory flap is possible if the medial cutaneous

Table 2. Reconstruction Performed for Each Case, including Flap Characteristics, Microsurgical Technique, and Donor Site Closure Method

	Flap Dimension (cm)	Pedicle Length (cm)	Recipient Artery	Stitch Size and Anastomosis Technique	Recipient Vein	Stitch Size and Anastomosis Technique	Donor Site Closure
1	11 × 3	4	UDA	11/0 E-S	Dorsal vein (MF)	9/0 E-E	Delayed primary closure
2	5 × 3	4	RDA	11/0 E-E	Dorsal vein (MF)	10/0 E-E	Dermal substitute
3	4 × 3.5	3.5	RDA	10/0 E-E	Dorsal vein (P1)	9/0 E-E	Direct closure
4	9 × 7	3.5	RA	11/0 E-S	Vena comitans	11/0 E-E	Direct closure
5	9 × 5	5	RDA	12/0 E-E	Dorsal vein (MF)	10/0 E-E	Dermal substitute
6	11 × 4	3	RDA	10/0 E-E	Dorsal vein (MF)	9/0 E-E	Dermal substitute

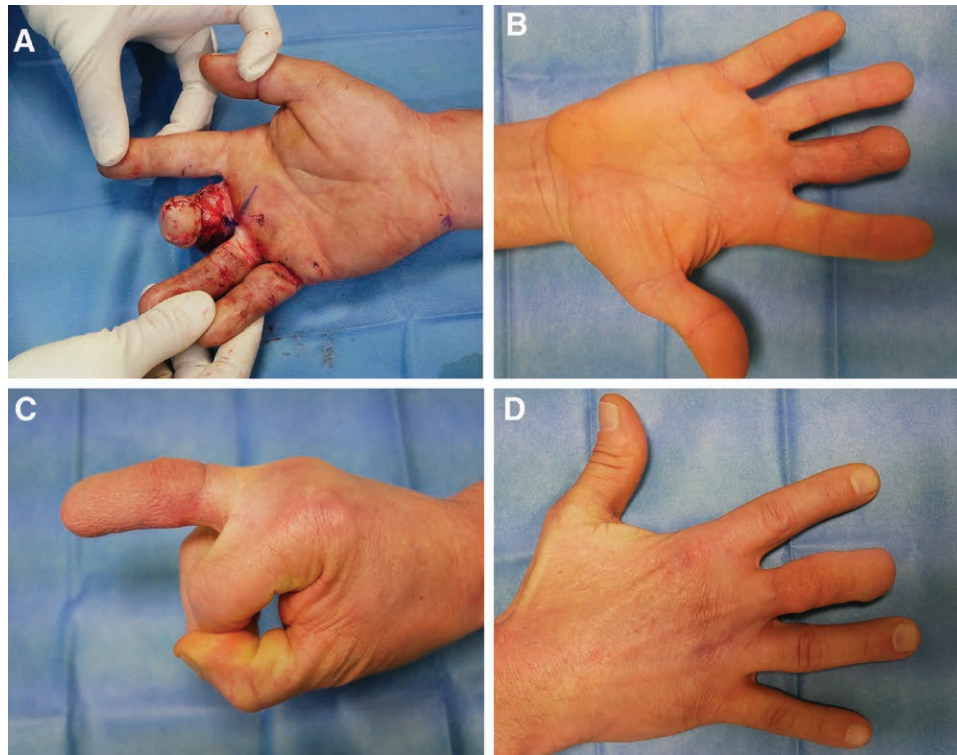


Fig. 5. Results of case described in Figure 2. A, The immediate postoperative result. B–D, illustration of the outcome after 7 months.

nerve of the forearm is included and the residual sensory deficit in the donor site is minimal, thanks to the presence of multiple cutaneous nerves in this area.^{23,32,33} So far we have not raised a neurotized PUPF, and we aim to preserve the medial cutaneous nerve of the forearm.

This flap is suitable for raising under regional anaesthetic from the ipsilateral forearm. The ulnar forearm offers an excellent donor site for finger resurfacing, providing thin and hairless skin. It also has the advantage that flaps from this region can be harvested under regional anaesthesia if the ipsilateral forearm is selected as donor site. The contraindications for this flap would be a scarred proximal forearm and patients in which the ulnar artery is the sole vascular supply to the hand.

Our study is limited by the small sample included. So far, we have not encountered any flap failures, being able to preserve length in each of the reconstructed digits. The main disadvantage of this flap is the small diameter of the perforator, which requires exacting supermicrosurgical

skills to perform the anastomosis. Harvesting a superficial vein of wider caliber can partially overcome this difficulty, offering an alternative drainage route for this flap. Another drawback is that flaps wider than 6 cm are not usually possible to close primarily. We have routinely used an acellular dermal matrix in these situations, but a skin graft is also a reasonable alternative.

CONCLUSIONS

The free proximal ulnar perforator flap is a viable option for the reconstruction of digital defects. The skin of the proximal forearm is well suited for this purpose as it is thin, pliable, and hairless. Morbidity at the donor site level has been low, as there is no need to harvest a portion of the ulnar artery. Adequate microsurgical training

Table 3. Postoperative Follow-up for the Patients Included in this Series

	Complications	Length of Stay (days)	Follow up (mo)	PRWHE Score
1	None	5	22	12.5
2	None	7	21	3
3	None	6	21	6.5
4	None	36	21	21.5
5	None	5	19	19
6	None	5	7	21.5

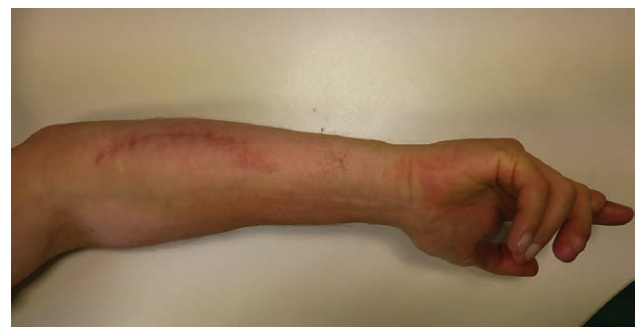

Fig. 6. Donor site at 3 months follow-up.

is required to anastomose small vessels. The residual scars on the forearm are well concealed.

Dr. Luigi Troisi, MD, PhD, FEBOPRAS

Head of the Reconstructive Microsurgery Service
University Department of Hand Surgery & Rehabilitation
San Giuseppe Hospital IRCCS MultiMedica Group
Via San Vittore 12
20123 Milan
Italy

ACKNOWLEDGEMENTS

The authors acknowledge the contribution of University Department of Hand Surgery & Rehabilitation (San Giuseppe Hospital – IRCCS MultiMedica Group Milan) physiotherapists, which have a fundamental role in our patients' rehabilitation. They have kindly helped us measure the functional outcomes regarding the patients mentioned in this study.

INFORMED CONSENT

Written informed consent was obtained from the patients for their anonymized information to be published in this article.

REFERENCES

- Kutler W. A new method for finger tip amputation. *J Am Med Assoc.* 1947;133:29.
- Moberg E. Aspects of sensation in reconstructive surgery of the upper extremity. *J Bone Joint Surg Am Vol.* 1964;46:817–825.
- Atasoy E, Ioakimidis E, Kasdan ML, et al. Reconstruction of the amputated finger tip with a triangular volar flap. A new surgical procedure. *J Bone Joint Surg Am.* 1970;52:921–926.
- Foucher G, Khouri RK. Digital reconstruction with island flaps. *Clin Plast Surg.* 1997;24:1–32.
- Foucher G, Braun JB. A new island flap transfer from the dorsum of the index to the thumb. *Plast Reconstr Surg.* 1979;63:344–349.
- Gurdin M, Pangman WJ. The repair of surface defects of fingers by trans-digital flaps. *Plastic Reconst Surg (1946).* 1950;5:368–371.
- Tang JB, Elliot D, Adani R, et al. Repair and reconstruction of thumb and finger tip injuries: a global view. *Clin Plast Surg.* 2014;41:325–359.
- Turner A, Ragowanni R, Hanna J, et al. Microvascular soft tissue reconstruction of the digits. *J Plast Reconstr Aesthet Surg.* 2006;59:441–450.
- Quaba AA, Davison PM. The distally-based dorsal hand flap. *Br J Plast Surg.* 1990;43:28–39.
- Büchler U, Frey HP. Retrograde posterior interosseous flap. *J Hand Surg Am.* 1991;16:283–292.
- Bakhach J, Sentucq-Rigal J, Mouton P, et al. The dorsoradial flap: A new flap for hand reconstruction. Anatomical study and clinical applications. *Annales de Chirurgie Plastique Esthétique.* 2006;51:53–60.
- Kim JT, Koo BS, Kim SK. The thin latissimus dorsi perforator-based free flap for resurfacing. *Plast Reconstr Surg.* 2001;107:374–382.
- Koshima I, Urushibara K, Inagawa K, et al. Free medial plantar perforator flaps for the resurfacing of finger and foot defects. *Plast Reconstr Surg.* 2001;107:1753–1758.
- Atzei A, Pignatti M, Udali G, et al. The distal lateral arm flap for resurfacing of extensive defects of the digits. *Microsurgery.* 2007;27:8–16.
- Pan ZH, Jiang PP, Wang JL. Posterior interosseous free flap for finger re-surfacing. *J Plast Reconstr Aesthet Surg.* 2010;63:832–837.
- Jeon BJ, Yang JW, Roh SY, et al. Microsurgical reconstruction of soft-tissue defects in digits. *Injury.* 2013;44:356–360.
- Horta R, Silva P, Costa-Ferreira A, et al. Microsurgical soft-tissue hand reconstruction: an algorithm for selection of the best procedure. *J Hand Microsurg.* 2016;03:73–77.
- Hung MH, Huang KF, Chiu HY, et al. Experience in reconstruction for small digital defects with free flaps. *Ann Plast Surg.* 2016;76(Suppl 1):S48–S54.
- Mateev MA, Trunov L, Hyakusoku H, et al. Analysis of 22 posterior ulnar recurrent artery perforator flaps: a type of proximal ulnar perforator flap. *Eplasty.* 2009;10:e2.
- Kim SW, Jung SN, Sohn WI, et al. Ulnar artery perforator free flap for finger resurfacing. *Ann Plast Surg.* 2013;71:72–75.
- Xiao C, Bao Q, Wang T, et al. Clinical application and outcome of the free ulnar artery perforator flap for soft-tissue reconstruction of fingers in five patients. *Plast Reconstr Surg.* 2013;131:132e–133e.
- Sun C, Hou ZD, Wang B, et al. An anatomical study on the characteristics of cutaneous branches-chain perforator flap with ulnar artery pedicle. *Plast Reconstr Surg.* 2013;131:329–336.
- Wei Y, Shi X, Yu Y, et al. Vascular anatomy and clinical application of the free proximal ulnar artery perforator flaps. *Plast Reconstr Surg Glob Open.* 2014;2:e179.
- Mathy JA, Moaveni Z, Tan ST. Perforator anatomy of the ulnar forearm fasciocutaneous flap. *J Plast Reconstr Aesthet Surg.* 2012;65:1076–1082.
- MacDermid JC, Tottenham V. Responsiveness of the disability of the arm, shoulder, and hand (DASH) and patient-rated wrist/hand evaluation (PRWHE) in evaluating change after hand therapy. *J Hand Ther.* 2004;17:18–23.
- Lovie MJ, Duncan GM, Glasson DW. The ulnar artery forearm free flap. *Br J Plast Surg.* 1984;37:486–492.
- Christie DR, Duncan GM, Glasson DW. The ulnar artery free flap: the first 7 years. *Plast Reconstr Surg.* 1994;93:547–551.
- Koshima I, Iino T, Fukuda H, et al. The free ulnar forearm flap. *Ann Plast Surg.* 1987;18:24–29.
- Arnstein PM, Lewis JS. Free ulnar artery forearm flap: a modification. *Br J Plast Surg.* 2002;55:356–357.
- Cherubino M, Corno M, Valdatta L, et al. Thumb reconstruction with thin proximal ulnar perforator free flap. *J Hand Surg Am.* 2017;42:e133–e138.
- Kim JT, Kim SW. Perforator flap versus conventional flap. *J Korean Med Sci.* 2015;30:514–522.
- Jawad AS, Harrison DH. The island sensate ulnar artery flap for reconstruction around the elbow. *Br J Plast Surg.* 1990;43:695–698.
- Bertelli JA, Kaleli T. Retrograde-flow neurocutaneous island flaps in the forearm: anatomic basis and clinical results. *Plast Reconstr Surg.* 1995;95:851–859.