

Compressive optic neuropathy: A unique presentation of Sweet syndrome

Sir,

A 29-year-old man presented to the Eye Department of our hospital with sudden-onset painless blurring of vision of his left eye, which worsened over 3 days. Four years prior to this, he presented with fever and tender skin lesions and, after being extensively worked-up, was diagnosed with Sweet syndrome based on a positive skin biopsy and hematological investigations. This fulfilled the criteria of classical Sweet syndrome as described by Von den Driesch.^[1] He was treated with oral prednisolone for 2 weeks and discharged well. There were no recurrences of this in 4 years. The patient's presenting visual acuity was 20/20 and 20/200 in his right and left eyes, respectively. Pupillary examination showed a left relative afferent pupillary defect.

The white cell count was raised to $20 \times 10^9/L$ (normal $4-11 \times 10^9/L$), and was predominantly neutrophilic, 80% (normal 40-70%). The erythrocyte sedimentation rate (ESR) was 63 mm/h and C-reactive protein was 5.8 mg/dL (normal 0-0.8 mg/dL). Peripheral blood film showed leucocytosis with neutrophilia. Computed tomography (CT) of the brain and orbit showed a lesion measuring 1.3 cm x 1.0 cm x 3.1 cm compressing the left optic nerve [Fig. 1]. The bone around the optic canal was not eroded by the inflammatory lesion.

The provisional diagnosis of compressive optic neuropathy as a result of a neutrophilic lesion in Sweet syndrome was made. Immediately, intravenous methylprednisolone 250 mg QDS for 3 days was commenced. This was followed by oral

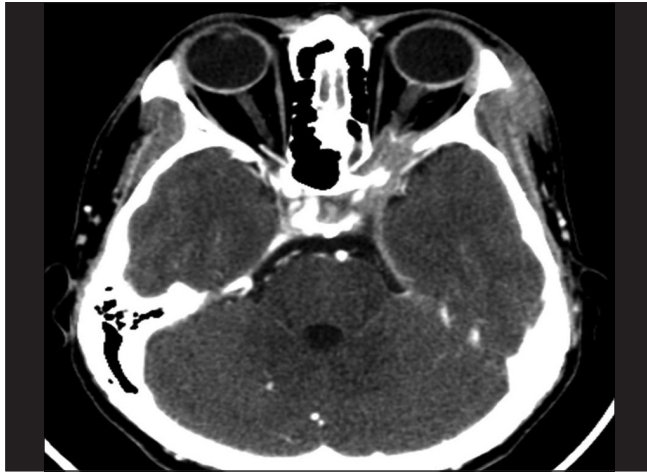


Figure 1: Computed tomography scan showing compression of the left optic nerve

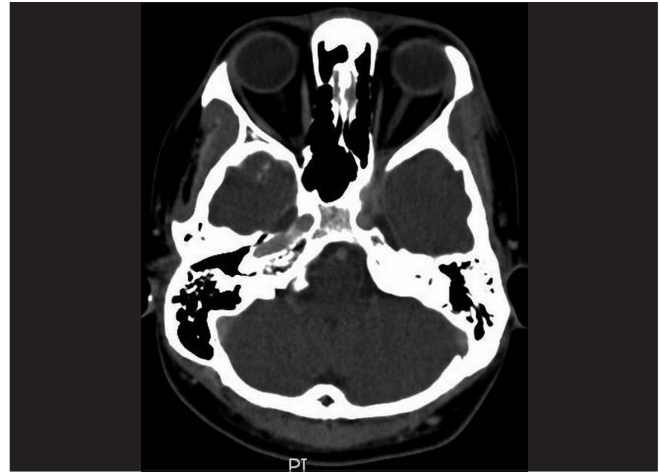


Figure 2: Computed tomography scan at 6 days posttreatment showing regression of the orbital lesion

prednisolone at 1 mg/kg/body weight for 11 days, which was then tapered off over 6 months. His left eye vision recovered to 20/20 at Day 4, with complete resolution of the left afferent pupillary defect. Repeated white cell counts and inflammatory indices on Day 7 returned to normal after treatment was begun. Serial computed tomography scans also showed regression of the orbital lesion [Fig. 2].

Ocular involvement in Sweet syndrome patients has been reported to vary from 7 to 72%.^[2] Patients may present with ocular inflammation that can involve any segment of the eye.^[3]

Our patient represented a diagnostic challenge as he did not have skin lesions at the current presentation. The orbital lesion was not biopsied due to its location. The rapidity of the patient’s symptoms pointed toward an inflammatory lesion. With the exclusion of other diseases and the patient’s previous history of Sweet syndrome, we postulated that the cause was a mass of neutrophilic infiltration secondary to a recurrence of Sweet syndrome, which compressed the left optic nerve. There has been a report of a case of nodular scleritis that developed without the skin lesions of Sweet syndrome months after the patient was diagnosed to have Sweet syndrome and after the skin lesions had resolved.^[4] The initial appearance of a dermatosis-related skin lesion is known to precede the diagnosis of a Sweet syndrome-associated hematological malignancy by as long as 11 years.^[5] It is safe to conclude that these patients have a tendency to develop recurrences of this spectrum of disease within their lifetime, which do not necessarily present with the cutaneous lesions. Corticosteroids remain the frontline treatment for Sweet disease. In this instance, intravenous corticosteroid was chosen as rapid resolution of the compressive optic neuropathy, and was necessary to prevent permanent visual loss. The dramatic improvement of the patient’s compressive optic neuropathy upon the commencement of systemic corticosteroids further supported our diagnosis of an orbital lesion secondary to Sweet syndrome.

This case describes a unique ocular manifestation of Sweet syndrome, and highlights the possible occurrence of compressive optic neuropathy in Sweet syndrome.

*Chiang Ling Koay, Fiona Lee Min Chew,
Kheng Yaw Chong, Visvaraja Subrayan*

Department of Ophthalmology, Faculty of Medicine,
University Malaya, Kuala Lumpur, Malaysia

Correspondence to: Prof. Dr. Visvaraja Subrayan,
Department of Ophthalmology, Faculty of Medicine,
University Malaya, 50603 Kuala Lumpur, Malaysia.
E-mail: dvisva@hotmail.com

References

1. Von den Driesch P. Sweet’s syndrome (acute febrile neutrophilic dermatosis). *J Am Acad Dermatol* 1994;31:535-56.
2. Philip RC. Sweet’s syndrome – A comprehensive review of an acute febrile neutrophilic dermatosis. *Orphanet J Rare Dis* 2007;2:34.
3. Gottlieb CC, Mishra A, Belliveau D, Green P, Heathcote JG. Ocular involvement in acute febrile neutrophilic dermatosis (Sweet syndrome): New cases and review of the literature. *Surv Ophthalmol* 2008;53:219-26.
4. Wong MH, Su DH, Loh RS. Nodular Scleritis and Sweet Syndrome. *Clin Experiment Ophthalmol* 2007;35:858-60.
5. Cohen PR, Kurzrock R. Sweet’s syndrome and cancer. *Clin Dermatol* 1993;11:149-57.

Access this article online	
Quick Response Code:	Website: www.ijo.in
	DOI: 10.4103/0301-4738.97562