

The importance of use of appropriate anticoagulant in atrial fibrillation after gastric bypass surgery



Mohamed Farhan Nasser, MD, Zahra Khaled, MD, Ahmad Jabri, MD, Saima Karim, DO, FHRS

From the Heart and Vascular Institute, MetroHealth Medical Center / Case Western Reserve University, Cleveland, Ohio.

Introduction

Atrial fibrillation (AF) is one of the most common arrhythmias encountered in clinical practice, especially in aging populations. Common risk factors associated with AF are left ventricular hypertrophy, older age, obesity, left atrial size, obstructive sleep apnea, and alcohol use. Chronic obstructive pulmonary disease, hypertension, valvular heart disease, and diabetes mellitus are independent predictors of AF.¹ One of the consequences of having AF is the possibility of thromboembolism. Current guidelines recommend anticoagulation to prevent thromboembolism in patients who have one non-sex-related AF risk factor (CHADS₂VASC of 1 in male and 2 in female patients).² There are a myriad of options for anticoagulation today. Direct-acting oral anticoagulants (DOAC) are being increasingly used owing to ease of administration and a decreased bleeding risk.

Rivaroxaban is a direct factor Xa inhibitor that is commonly used to prevent strokes in patients with nonvalvular AF. Guidelines suggest the use of DOACs over warfarin in patients with nonvalvular AF owing to similar risk of stroke prevention and better therapeutic safety.² However, patients with significantly altered gastrointestinal (GI) tracts from bariatric surgeries and extremely obese patients (body mass index [BMI] > 40 kg/m²) were not included in the phase III studies that assessed DOAC efficacy and safety.^{3,4}

We describe a case of a patient with a history of gastric bypass surgery and morbid obesity who presented with AF and developed left atrial appendage (LAA) dense echo contrast or “sludge” while on rivaroxaban.

Case report

A 57-year-old woman with a history of AF (which started 6 years prior to presentation), morbid obesity with a weight of 187 kg (411 lb), and a BMI of 55 kg/m² who had

KEYWORDS Bariatric surgery; DOAC; Morbid obesity; Rivaroxaban; Warfarin (Heart Rhythm Case Reports 2021;7:354–356)

Conflict of Interest Disclosures: None. **Funding:** None. **Address reprint requests and correspondence:** Dr Mohamed Farhan Nasser, Heart and Vascular Center, MetroHealth Medical Center, Case Western Reserve University, 2500 MetroHealth Dr, Cleveland, OH 44109. E-mail address: mnasser1@metrohealth.org.

KEY TEACHING POINTS

- Warfarin is the preferred choice of anticoagulation in patients with morbid obesity or altered gastrointestinal absorption, such as after gastric bypass surgery.
- Direct-acting oral anticoagulants (DOACs) are commonly used as anticoagulants given their ease of administration, equivalent reduction in stroke, and lesser bleeding risk than vitamin K antagonists in generalized populations. However, further studies are needed to evaluate appropriate dose, efficacy in reduction of thromboembolic events, and bleeding risk of DOACs in morbidly obese or post-gastric bypass patient subsets.
- Chromogenic anti-factor Xa levels and dilute thrombin time can be checked to evaluate for presence of anti-Xa inhibitors. However, there are no established cut-off thresholds for bleeding or thrombosis.

undergone a Roux-en-Y gastric bypass surgery (RYGB) was admitted with complaints of exertional dyspnea. Her electrocardiogram showed AF with rapid ventricular response with a heart rate of 124 beats per minute. She had acute congestive heart failure with jugular venous distention, bilateral pitting pedal edema, B-type natriuretic peptide of greater than 1500 ng/L, and a chest radiograph showing perihilar congestion. She was managed with intravenous diltiazem to achieve heart rate control, intravenous heparin for anticoagulation, and intravenous furosemide for diuresis. She was also started on lisinopril and hydralazine for hypertension. A transthoracic echocardiogram showed an ejection fraction of 55%, normal right ventricular size and function, moderate tricuspid regurgitation, and moderate pulmonary hypertension with a pulmonary artery pressure of 45 mm Hg. A transesophageal echocardiogram (TEE) during this

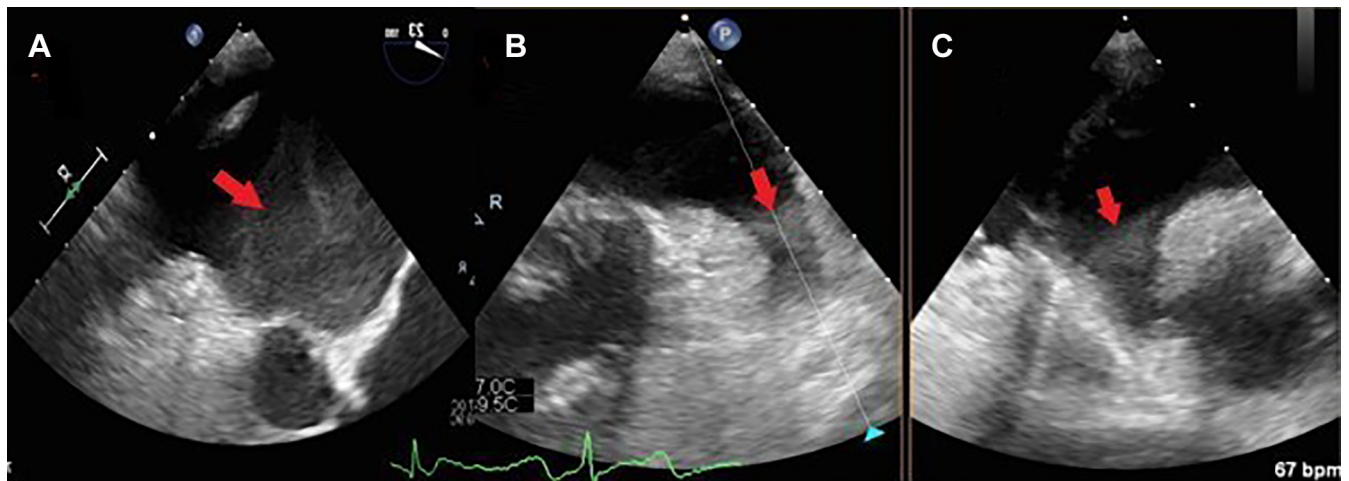


Figure 1 Transesophageal echocardiogram (TEE) images. **A:** TEE of the left atrium showing marked echo contrast (arrow). **B,C:** TEE of the left atrial appendage in orthogonal planes showing “sludge” (arrow).

admission did not show a left atrial or LAA thrombus or echo contrast, and she underwent successful synchronized cardioversion to normal sinus rhythm.

She had frequent symptomatic paroxysms of AF post cardioversion; thus she was started on dofetilide 500 mcg twice a day, which had to be discontinued owing to significant QTc prolongation despite lowering the dose. She refused warfarin owing to the lack of reliable transportation to the anticoagulation clinic for serial international normalized ratios (INRs), as she lived in a remote area. After an extensive discussion regarding the risks and benefits of the use of rivaroxaban, given her BMI and her prior history of RYGB, she still opted for anticoagulation with rivaroxaban 20 mg daily. She was subsequently discharged with a 30-day event monitor.

She was evaluated in the outpatient electrophysiology clinic 3 months after her initial discharge owing to recurrent palpitations and acute diastolic heart failure exacerbation despite reporting medication adherence. Her event monitor showed persistent AF. She was offered an AF ablation. A preprocedure TEE showed echo contrast in the left atrium and severe dense spontaneous echo contrast (“sludge”) in the LAA, as shown in Figure 1. She had a protracted hospitalization for diuresis, and she was bridged from intravenous heparin to warfarin with a therapeutic INR goal of 2–3 after stopping rivaroxaban.

She was readmitted 4 weeks after the discovery of left atrial/LAA echo contrast for another diastolic heart failure exacerbation owing to persistent AF. A TEE was performed for the third time, now with therapeutic INRs, and showed resolution of her previously noted sludge. She underwent a successful AF ablation and was continued on warfarin to maintain an INR of 2–3, in addition to her diltiazem and furosemide. She has not experienced any further episodes of AF or diastolic heart failure exacerbations since her ablation over 1 year ago.

Discussion

DOACs are often preferred to vitamin K antagonists for nonvalvular AF owing to ease of administration, similar thromboembolic risk, and lesser risk of bleeding.² However, patients with morbid obesity and altered GI tracts were not included in the phase III studies regarding use of DOACs. Rivaroxaban was compared with warfarin for AF in ROCKET-AF, but only 13.6% had a BMI ≥ 35 kg/m² and only 28.5% of patients weighed more than 90 kg.^{4,5} Two retrospective studies have compared use of DOACs with warfarin in patients with BMI > 40 kg/m² and weight > 120 kg. One small study evaluated 64 patients and showed risk of strokes and bleeding risk in the DOAC group was comparable to that of warfarin.⁶ Another larger study showed similar results when rivaroxaban was compared to warfarin.⁷

Pharmacokinetic (PK) and pharmacodynamic (PD) data can also provide an idea about influences of body weight on drug concentration and volume of distribution. Two small studies assessed the effect of obesity on PK/PD with rivaroxaban. Peak plasma concentrations of once-daily dosing of rivaroxaban when given to patients weighing > 120 kg as compared to patients weighing 70–80 kg showed that plasma concentration and half-life of rivaroxaban were not affected by change in weight.⁸ However, a second study used data from patients with deep vein thrombosis from the ODIX-DVT and EINSTEIN DVT trials to create a PK model for rivaroxaban, which showed that volume of distribution was increased in people with higher weight.⁹ PK and PD data regarding dabigatran and apixaban also showed that these anticoagulants had a lower trough level, higher volume of distribution, and lower peak concentration in high-body-weight patients. Overall these data suggest that higher body weight can lead to lower peak concentrations and lower drug exposure for DOACs. Given the lack of randomized controlled trials in morbidly obese patients and the available PK/PD data, the International Society on Thrombosis and

Haemostasis (ISTH) recommends against use of DOACs in morbidly obese (BMI > 40 and weight > 120 kg) patients.⁴

In the absence of randomized controlled data, theoretical information about the location of DOAC absorption can be helpful in its clinical use after bariatric surgery. Bariatric surgery alters the GI tract, subsequently affecting the absorption and metabolism of DOACs. In RYGB, the stomach is modified to create a pouch, which is then connected to the jejunum, hence bypassing the location where the DOACs are absorbed. Rivaroxaban is known to be primarily absorbed in the stomach, with some absorption in the duodenum and little absorption in the distal small intestine.¹⁰ In comparison, other DOACs have the majority of their absorption both in the stomach and in the proximal small intestine. Hence, other DOACs were not considered alternate methods of anticoagulation in this patient. The location of DOAC absorption in distal stomach is preserved after a gastric sleeve, but there is limited literature that has evaluated the use of DOACs only in gastric sleeve patients. A small retrospective study assessed peak drug levels of apixaban, dabigatran, and rivaroxaban after bariatric surgery. It showed that peak drug levels of apixaban and dabigatran were in the expected range, but the patients on rivaroxaban had lower levels than predicted.¹¹ A phase I clinical trial evaluated PD/PK parameters of rivaroxaban 1 day before and 3 days after bariatric surgery. It showed that bariatric surgery did not affect the PK of rivaroxaban.¹² However, this study only evaluated 2 individual days of dosing instead of long-term monitoring, as AF requires long-term anticoagulation with potentially varying levels of absorption over time in patients with gastric bypass.

Anti-factor Xa chromogenic assays can be measured to evaluate for presence of factor Xa inhibitors and dilute thrombin time for the presence of dabigatran. These assays may have utility in patients with extreme body weights and altered GI tracts. Considering that there are no established cut-off values that predict thrombosis risks, lab ranges need validation in further studies. The European Heart Rhythm Association does not recommend routine monitoring of these assays.¹³ The ability to monitor therapeutic levels of warfarin provides an advantage over DOACs in patients who are morbidly obese and those who have had bariatric surgery.

This report highlights the need for prospective studies that evaluate and compare the use of DOACs and warfarin in patients that are overweight and/or have altered GI tracts from a prior bariatric surgery.

Conclusion

Rivaroxaban may not have adequately anticoagulated our patient owing to morbid obesity and decreased GI absorption

with altered volume of distribution after RYGB. The role of DOACs in this patient population should be further studied in adequately powered randomized controlled trials; and until then, we believe it would be reasonable to use warfarin for those who are morbidly obese or have undergone prior bariatric surgery. There is added utility of monitoring therapeutic levels with INR in these particular situations.

Acknowledgment

Written and verbal informed consent for publication has been obtained from the individual being reported on, in line with the COPE best practice guidelines, and the individual who is being reported on is aware of the possible consequences of that reporting.

References

- Lau DH, Nattel S, Kalman JM, Sanders P. Modifiable risk factors and atrial fibrillation. *Circulation* 2017;136:583–596.
- January CT, Wann LS, Calkins H, et al. 2019 AHA/ACC/HRS Focused Update of the 2014 AHA/ACC/HRS Guideline for the Management of Patients With Atrial Fibrillation: A Report of the American College of Cardiology/American Heart Association Task Force on Clinical Practice Guidelines and the Heart Rhythm Society in Collaboration With the Society of Thoracic Surgeons. *Circulation* 2019;140:e125–e151.
- Hakeam HA, Al-Sanea N. Effect of major gastrointestinal tract surgery on the absorption and efficacy of direct acting oral anticoagulants (DOACs). *J Thromb Thrombolysis* 2017;43:343–351.
- Martin K, Beyer-Westendorf J, Davidson BL, Huisman MV, Sandset PM, Moll S. Use of the direct oral anticoagulants in obese patients: guidance from the SSC of the ISTH. *J Thromb Haemost* 2016;14:1308–1313.
- Patel MR, Mahaffey KW, Garg J, et al. Rivaroxaban versus warfarin in nonvalvular atrial fibrillation. *N Engl J Med* 2011;365:883–891.
- Kido K, Ngorsuraches S. Comparing the efficacy and safety of direct oral anticoagulants with warfarin in the morbidly obese population with atrial fibrillation. *Ann Pharmacother* 2019;53:165–170.
- Peterson ED, Ashton V, Chen Y-W, Wu B, Spyropoulos AC. Comparative effectiveness, safety, and costs of rivaroxaban and warfarin among morbidly obese patients with atrial fibrillation. *Am Heart J* 2019;212:113–119.
- Kubitza D, Becka M, Zuehlsdorf M, Mueck W. Body weight has limited influence on the safety, tolerability, pharmacokinetics, or pharmacodynamics of rivaroxaban (BAY 59-7939) in healthy subjects. *J Clin Pharmacol* 2007;47:218–226.
- Mueck W, Lensing AWA, Agnelli G, Décousus H, Prandoni P, Misselwitz F. Rivaroxaban. *Clin Pharmacokinet* 2011;50:675–686.
- Martin KA, Lee CR, Farrell TM, Moll S. Oral anticoagulant use after bariatric surgery: a literature review and clinical guidance. *Am J Med* 2017;130:517–524.
- Rottenstreich A, Barkai A, Arad A, Raccach BH, Kalish Y. The effect of bariatric surgery on direct-acting oral anticoagulant drug levels. *Thromb Res* 2018;163:190–195.
- Kröll D, Stimmann G, Vogt A, et al. Pharmacokinetics and pharmacodynamics of single doses of rivaroxaban in obese patients prior to and after bariatric surgery. *Br J Clin Pharmacol* 2017;83:1466–1475.
- Heidbuechel H, Verhamme P, Alings M, et al. Updated European Heart Rhythm Association Practical Guide on the use of non-vitamin K antagonist anticoagulants in patients with non-valvular atrial fibrillation. *Europace* 2015;17:1467–1507.