

Update on the renal toxicity of iodinated contrast drugs used in clinical medicine

Michele Andreucci¹
Teresa Faga¹
Raffaele Serra²
Giovambattista De Sarro³
Ashour Michael¹

¹Renal Unit, Department of Health Sciences, ²Interuniversity Center of Phlebology and Educational Program in Clinical and Experimental Biotechnology, Department of Medical and Surgical Sciences, ³Pharmacology Unit, Department of Health Sciences, Magna Graecia University, Catanzaro, Italy

Abstract: An important side effect of diagnostic contrast drugs is contrast-induced acute kidney injury (CI-AKI; a sudden decrease in renal function) occurring 48–72 hours after injection of a contrast drug that cannot be attributed to other causes. Its existence has recently been challenged, because of some retrospective studies in which the incidence of AKI was not different between subjects who received a contrast drug and those who did not, even using propensity score matching to prevent selection bias. For some authors, only patients with estimated glomerular filtration rate <30 mL/min/1.73 m² are at significant risk of CI-AKI. Most agree that when renal function is normal, there is no CI-AKI risk. Many experimental studies, however, are in favor of the existence of CI-AKI. Contrast drugs have been shown to cause the following changes: renal vasoconstriction, resulting in a rise in intrarenal resistance (decrease in renal blood flow and glomerular filtration rate and medullary hypoxia); epithelial vacuolization and dilatation and necrosis of proximal tubules; potentiation of angiotensin II effects, reducing nitric oxide (NO) and causing direct constriction of descending vasa recta, leading to formation of reactive oxygen species in isolated descending vasa recta of rats microperfused with a solution of iodixanol; increasing active sodium reabsorption in the thick ascending limbs of Henle's loop (increasing O₂ demand and consequently medullary hypoxia); direct cytotoxic effects on endothelial and tubular epithelial cells (decrease in release of NO in vasa recta); and reducing cell survival, due to decreased activation of Akt and ERK1/2, kinases involved in cell survival/proliferation. Prevention is mainly based on extracellular volume expansion, statins, and *N*-acetylcysteine; conflicting results have been obtained with nebulivolol, furosemide, calcium-channel blockers, theophylline, and hemodialysis.

Keywords: renal failure, ARF, acute kidney injury, AKI, contrast media, intracellular signaling

Introduction

Iodinated contrast drugs are used in clinical medicine to visualize internal organs, since one of the properties of iodine is its high-contrast density. This property makes these drugs useful to increase the visibility of the urinary tract (excretory urography or intravenous [IV] pyelography) of vascular structures (angiography) in computed tomography (CT) scans of internal organs; it also allows important therapeutic maneuvers, such as angioplasty and coronary interventions. The use of contrast drugs has been growing in recent years, mainly due to the increase in life span and consequently more frequent diagnostic needs in older patients with more comorbid conditions (eg, long-standing or severe hypertension, long-standing or severe diabetes, and chronic renal failure).

We are aware that all drugs used in clinical practice have some side effects in addition to therapeutic efficacy; only when their efficacy prevails over the side effects are

Correspondence: Michele Andreucci
Renal Unit, Department of Health Sciences, Salvatore Venuta Campus, Magna Graecia University, Viale Europa, Catanzaro 88100, Italy
Tel +39 0961 364 7301
Email andreucci@unicz.it

we allowed to use them. The same is valid for contrast drugs, the use of which is not therapeutic, but diagnostic: they have some side effects. Unfortunately, we are obliged to use them in many, often severe, clinical conditions to reach a diagnosis. Therefore, to overcome the problem, we must try to reduce their severity by choosing less nephrotoxic contrast drugs and by pretreating and treating patients when using them.

Iodinated contrast drugs

Iodinated contrast drugs have different osmolalities. According to their osmolality, we can divide contrast drugs into three groups: 1) ionic high-osmolar contrast media (HOCM; eg, iohalamate) have an osmolality (1,500–1,800 mOsm/kg) five to eight times plasma osmolality; 2) nonionic low-OCM (LOCM; eg, iohexol) have an osmolality (600–850 mOsm/kg) two to three times plasma osmolality; and 3) nonionic iso-OCM (IOCM; eg, iodixanol) have an osmolality (~290 mOsm/kg) similar to that of plasma.¹ HOCM are more cytotoxic in vitro on proximal tubular cells than LOCM or IOCM. The use of LOCM rather than HOCM reduces nephrotoxicity in patients with renal failure. Therefore, HOCM are used less frequently.^{2,3}

Possible side effects of contrast drugs

Unwanted effects of contrast drugs may vary from mild inconvenience (such as mild itching or cutaneous reactions) to more severe reactions (such as allergic effects, delayed allergic reactions, or anaphylactic reactions) including a life-threatening emergency. For these, we refer to the literature.⁴⁻⁶ With the advent of nonionic LOCM in the 1980s, most adverse events became relatively mild and required no medical treatment.

Contrast-induced acute kidney injury

A very important unwanted effect of the use of contrast drugs is acute kidney injury (AKI), ie, a sudden decrease of renal function due to renal damage.⁷ AKI secondary to contrast drugs is called contrast-induced AKI (CI-AKI; or contrast-induced nephropathy [CIN]); it is actually an iatrogenic AKI. This relatively frequent renal complication is due to the following factors.

Intravenous or intra-arterial injection of a contrast drug

There is widespread (and long-standing) recognition that the risk of CI-AKI is greater with intra-arterial than IV

administration. This would be due to higher contrast-drug concentration in the intrarenal vessels,⁸ particularly when the intra-arterial injection is suprarenal.⁹ Under these conditions, in fact, there is a very high concentration of contrast drug. Nyman et al¹⁰ totally disagreed, mainly because of a lack of comparative trials on the risk of CI-AKI between intra-arterial and IV procedures. More recent literature provides increasing evidence of very limited/no demonstrable CI-AKI with the IV route.¹¹⁻¹³

Main route of excretion by the kidneys

After intravascular injection, the drug is diluted in the bloodstream (this allows the visualization of vessels of liver, spleen, pancreas, and kidneys, etc) and immediately distributed throughout the extracellular fluid. Being poorly bound to serum albumin, the contrast drug is freely filtered by renal glomeruli and excreted by the kidneys.

CI-AKI is defined as any case of AKI occurring 48–72 hours after intravascular injection of a contrast drug that cannot be attributed to other causes. It is more frequent in aged patients,¹⁴⁻¹⁷ those with diabetes, and in patients with renal insufficiency (<60 mL/min/1.73 m² glomerular filtration rate [GFR]), and is usually nonoliguric and frequently asymptomatic, such that often its diagnosis is missed. It peaks on the third to fifth day, and returns to normality within 10–14 days. It is usually indicated as an increase in serum creatinine by 0.5 mg/dL or greater, or by a decrease to 30–60 mL/min of GFR obtained with special formulas from serum creatinine (estimated GFR [eGFR]).^{5,18-20}

The incidence of CI-AKI in subjects undergoing a radiological examination with an iodinated contrast drug is low (2%) if renal function is normal (eGFR >45 mL/min/1.73 m²).²¹ However, it has been reported that in 10% of patients with renal failure exposed to contrast drugs for coronary angiography, a severe oliguric acute renal failure occurred that led to dialysis or death.²² Recent studies have questioned whether CI-AKI in patients with chronic renal insufficiency really does exist.^{23,24} Another study also concluded that no significant increase in CI-AKI occurs after LOCM administration in critically ill patients.²⁵

There have been many retrospective studies (usually carried out in more than 20,000 and sometimes 50,000 adult patients over a 10-year period) to demonstrate that the incidence of AKI was not different between subjects who had received an iodinated contrast drug and control subjects who had not.^{13,26-29} McDonald et al²⁹ have also demonstrated that the use of contrast drugs was not associated with higher risk

of AKI, dialysis, or death, even in patients usually indicated at high risk of CI-AKI (because of diabetes, congestive heart failure, or chronic renal failure). However, patients with CI-AKI had a higher rate of dialysis or death. In another retrospective study, the same authors divided more than 41,000 patients on the basis of their baseline eGFR into four groups: >90, 60–80, 30–50, and less than 30 mL/min/1.73 m². They concluded that there was an increased risk of AKI with the decrease in eGFR; but there was no difference between patients exposed and patients unexposed to contrast drugs, even in those with eGFR <30 mL/min/1.73 m².³⁰

As such, in the last few years the existence of CI-AKI has been challenged on the basis of the aforementioned retrospective studies demonstrating no effect of contrast drugs on incidence of AKI compared with control patients who had not been treated with contrast drugs. Davenport et al³¹ recently underlined the many drawbacks of these retrospective clinical studies. The main criticism was the creation of the control group of patients not treated with contrast drugs, for whom selection bias was frequent. For instance, it may not be unusual to include in control groups (not treated with contrast drugs) patients who have multiple comorbidities and for this reason had been excluded from the group receiving contrast drugs. To reduce this selection bias, Parsons³² suggested the use of an advanced statistical technique: propensity score matching.

As stated by Davenport et al,³¹ it is surprising that through the propensity score-matching technique they found that contrast drugs represented an independent nephrotoxic risk factor in patients with severe and progressive chronic renal failure,^{26,27} whereas McDonald et al²⁸ had not, despite using the same technique. Davenport et al³¹ recognized that either their studies had a systematic bias favoring inclusion in the contrast-drug group of patients with a tendency to have AKI or in the McDonald et al study the propensity score-matching technique was less effective. The conclusions of the authors of these studies were: according to McDonald et al,²⁸ there is no risk of AKI with contrast drugs; and according to Davenport et al,³¹ only patients with eGFR <30 mL/min/1.73 m² are at significant risk of CI-AKI, while patients with eGFR 30–44 mL/min/1.73 m² are at borderline risk of AKI. The two groups of authors agreed that when renal function is normal, there is no risk of CI-AKI.

Thomsen and Stacul³³ asked the question: “Have we spent almost 40 years trying to find the way to prevent a disease (CI-AKI) that does not exist and is only the expression of normal fluctuation of a parameter (creatinine) used for its diagnosis, at least in patients with moderately reduced renal

function?”³⁴ However, they added that it is too early to decide that CI-AKI does not exist, at least in patients with severe renal failure.

We should underline that patients having contrast-enhanced CT exams would receive prophylaxis treatment that would decrease the incidence of AKI, whereas in patients not receiving contrast prophylaxis would not be given, thereby increasing the incidence of AKI. Taken together, these differences would tend to minimize the differences between the contrast group of patients and the control group. In retrospective studies suggesting similar incidence of AKI in patients undergoing contrast-enhanced and those taking unenhanced CT exams, a bias may have been created by the prophylaxis carried out in patients receiving the contrast. Prophylaxis, in fact, would decrease the incidence of AKI. In patients who did not receive contrast, prophylaxis was not given, thereby increasing the incidence of AKI. Taken together, these differences would tend to minimize the differences between the contrast group of patients and the control group.

Prospective studies on CI-AKI are difficult to perform in humans for ethical reasons. This is not a problem in experimental animals. Many experimental studies have been in favor of the existence of CI-AKI. Contrast drugs have been shown to be nephrotoxic, regardless of their osmolality, by causing the changes outlined in the following sections.

Renal hemodynamics

The intravascular injection of a contrast drug causes rapid renal vasodilatation followed by long vasoconstriction that results in a rise of intrarenal vascular resistance, with a decrease in renal blood flow (RBF) and a fall in filtration fraction.^{1,35–38} Liu et al³⁹ carried out an experimental study on isolated afferent and efferent glomerular arterioles of mice to figure out the effects of the iodinated contrast drug iodixanol on arteriolar tone of afferent and efferent arterioles.

The arterioles were isolated from mice and perfused with iodixanol (23 mg iodine/mL) for 20 minutes, followed by angiotensin II administration. Arterioles perfused with the vehicle solution without the contrast drug functioned as control. The diameters of the afferent arterioles perfused with iodixanol were significantly reduced from 9.2 to 8.3 μm, while in control arterioles diameters increased from 8.7 to 9.3 μm. The inhibition of nitric oxide synthase increased iodixanol-induced constriction. The authors also observed impaired nitric oxide bioavailability and enhanced angiotensin II response following iodixanol perfusion. In efferent arterioles, instead, their basal diameters and response to angiotensin II were not affected by iodixanol. The decrease

in nitric oxide bioavailability and increase in concentration of superoxide explain the increased tone and reactivity in afferent arterioles perfused with iodixanol. The authors concluded that the constricting effect of iodixanol in vitro on the afferent arterioles explains the reduction in RBF and GFR by contrast drugs observed in vivo.

Therefore, hemodynamic changes by contrast drugs are responsible for a decrease in RBF and GFR on one hand, and on the other for medullary hypoxia in a medullary area where O₂ supply is already low (Figure 1). Under normal conditions, nitric oxide (NO), prostaglandins, and adenosine adjust tubular transport of sodium to adapt to this low O₂ supply.⁴⁰ A reduced blood supply due to vasoconstriction, and increasing sodium reabsorption in the descending limb of Henle's loop due to an increased sodium delivery to the distal tubule will alter this mechanism, thereby causing more severe hypoxia (Figure 1).

Adenosine also seems to play an important role in CI-AKI. Normal dogs given iohexol have been shown to have

renal vasodilatation following activation of adenosine A₂ receptors, with an increase in RBF. The injection of iohexol in dogs with reduced renal function activates A₂ and A₁: A₂ activation is associated with the initial renal vasodilatation, and activation of A₁ causes the subsequent longstanding vasoconstriction⁴¹ (Figure 1). On the basis of this observation, theophylline and aminophylline (adenosine-receptor antagonists) would have protective effects against contrast drugs. Unfortunately, while theophylline does prevent further impairment of renal function by contrast drugs in dogs with renal insufficiency,⁴¹ conflicting results have been obtained in humans: some articles have reported beneficial effects,^{42,43} while others have not.^{44,45}

Tubular epithelial vacuolization and necrosis

Rats and many other laboratory animals tolerate high doses of contrast drugs without any impairment of renal function. Jensen et al⁴⁶ proposed an animal model of CI-AKI in rats for

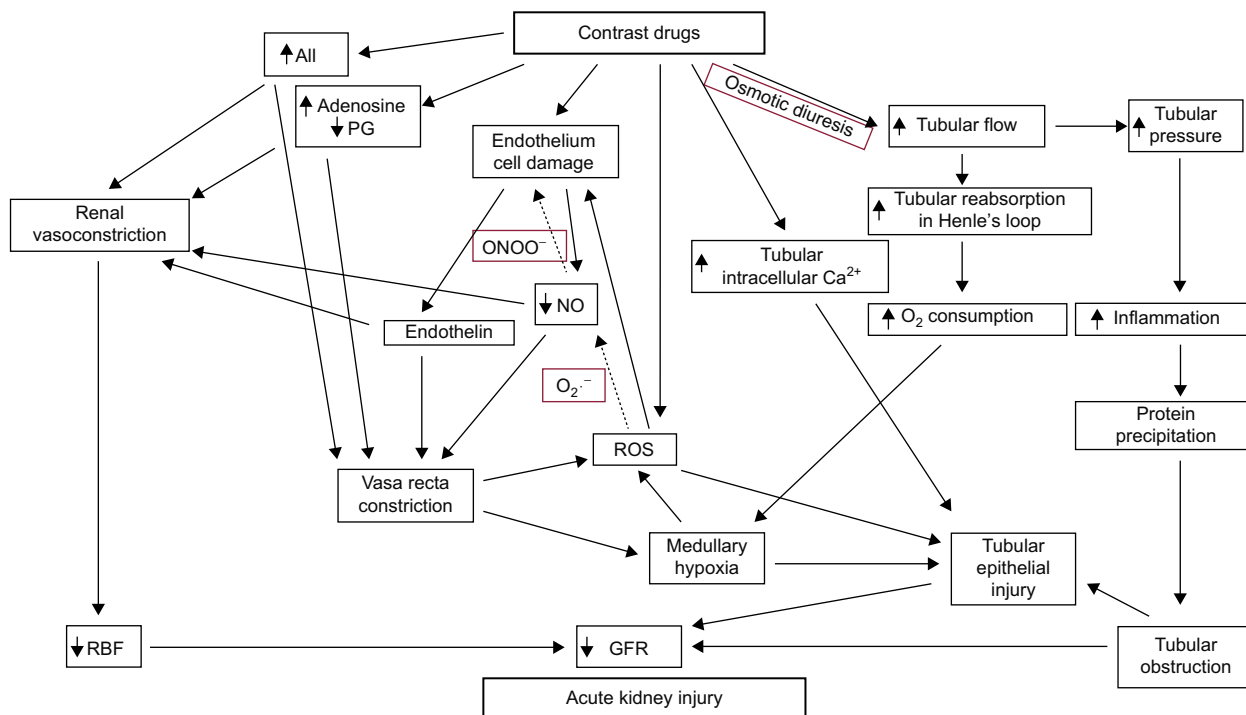


Figure 1 After intravascular injection, contrast drugs cause immediate and short-term renal vasodilatation. **Notes:** Vasodilatation is very soon followed by renal vasoconstriction that causes 1) a decrease in renal blood flow (RBF) and glomerular filtration rate (GFR) and 2) vasa recta constriction (favored by increased effects of angiotensin II, adenosine, and endothelin), with consequent medullary hypoxia. Though contrast drugs are rapidly filtered by renal glomeruli and excreted with urine, their high osmolality will cause osmotic diuresis. This is responsible for an increase in sodium delivery to the medullary ascending limb of Henle's loop and consequent increase in sodium reabsorption. However, in this medullary area there is already significant O₂ demand due to the low blood supply. The increased O₂ consumption due to increased sodium reabsorption will cause significant medullary hypoxia with epithelial tubular injury that further decreases the GFR; a contribution to this obstruction is made by proinflammatory cytokines and complement activation that lead to protein precipitation. The latter injury is also due to a direct cytotoxic effect of contrast drugs, because of their high concentration in the tubular lumen due to the reabsorption of tubular fluid in the proximal tubules. The endothelial cells directly damaged by contrast drugs will lead to formation of reactive oxygen species (ROS) that will decrease nitric oxide, thereby contributing to vasa recta constriction and medullary hypoxia. Renal medullary hypoxia itself leads to formation of ROS. The final result will be an important decrease in GFR. Adapted from Andreucci M, Faga T, Pisani A, et al. Pathogenesis of acute renal failure induced by iodinated radiographic contrast media. *Austin J Nephrol Hypertens.* 2014;1(1):1005.³⁶

Abbreviations: All, angiotensin II; NO, nitric oxide; PG, prostaglandin; ONOO⁻, peroxynitrite anion.

studying the different toxicities of different contrast drugs. Sprague Dawley rats were treated with gentamicin (70 mg/kg body weight [BW]) to cause relatively mild renal damage. Normal rats received physiological saline infusion (control group). One group of the gentamicin-treated rats was then given a single dose of ioversol (6 g/kg BW); a second group of the gentamicin-treated rats was not. Histopathology of the kidneys of untreated rats (control with physiological saline) revealed no histopathological kidney damage. Gentamicin + ioversol rats and gentamicin-only rats had similar incidence and severity of hyaline droplets in the proximal tubular epithelium. Rats treated with gentamicin + ioversol demonstrated an incidence and severity of inflammation greater than the gentamicin group. Vacuolization, dilatation, and necrosis of proximal tubules were observed only in rats treated with gentamicin + ioversol.

Potential of angiotensin II effects, reduction of NO bioavailability and direct constriction of medullary descending vasa recta: formation of reactive oxygen species

Sendeski et al⁴⁷ demonstrated *in vitro* in isolated outer medullary descending vasa recta of rats microperfused with a solution of iodixanol that this contrast drug directly constricted these vessels by 52%, reduced NO, and increased the vasoconstrictor response to angiotensin II. The consequence of this constriction *in vivo* will be severe local hypoxia³⁶ (Figure 1). The same authors demonstrated an important role for reactive oxygen species (ROS) in constricting medullary vasa recta following contrast-drug administration; in fact, the superoxide dismutase mimetic Tempol reduced the vasoconstriction by iodixanol.^{36,47}

It is also known that in normal kidneys, epithelial tubular transport leads to ROS formation, particularly in the medullary thick ascending limb of Henle's loop, where the dense mitochondrial population is the main source for the generation of superoxide anions ($O_2^{\cdot-}$), and hydroxyl radicals ($\cdot OH$) by NAD(P)H-oxidase.^{48,49} The injection of a contrast drug causes an increase in ROS formation and oxidative stress that exerts direct injury to endothelial and epithelial cell membranes in vascular and tubular structures, respectively, which leads to cellular apoptosis and necrosis and increased medullary hypoxia⁴⁹ (Figure 1).

More recently Pisani et al^{49,50} demonstrated that recombinant manganese superoxide dismutase given to rats that were under diatrizoate treatment reduced renal oxidative stress,

thereby preventing reduction in GFR and occurrence of renal histopathological lesions observed after contrast-drug administration. Another vasoconstrictive agent, endothelin, is released by the damaged endothelial cells, thereby contributing to medullary vasoconstriction and consequent hypoxia.⁵¹ Renal medullary hypoxia itself leads to the formation of ROS^{52,53} (Figure 1).

The decrease in NO observed after injection of contrast drugs may also be due to the reaction of NO with ROS, in particular superoxide.^{49,54} This reaction causes the formation of peroxynitrite,⁵⁵ which causes severe damage to endothelial cells. In conclusion, studies in experimental animals and in humans have demonstrated that contrast drugs cause a rise in ROS generation, decrease in NO, potentiation of angiotensin II effects, and direct constriction of medullary descending vasa recta, thereby contributing to the occurrence of CI-AKI⁴⁹ (Figure 1).

Renal active sodium transport

Active sodium reabsorption occurs in S_3 segments of proximal renal tubules of the outer medulla and in the medullary thick ascending limbs of Henle's loop, in a medullary area where O_2 delivery is poor even in normal conditions, due to the long distance from vasa recta, while O_2 demand is high due to active sodium reabsorption. After intravascular injection, the contrast drug is filtered by the glomeruli in Bowman's capsule and then excreted with urine. Its high osmolality will create osmotic diuresis. The latter increases the delivery of sodium to Henle's loop, causing a rise in sodium reabsorption and consequently in O_2 consumption. The result will be more severe medullary hypoxia³⁶ (Figure 1).

Direct renal tubular cytotoxic effects

Iodinated contrast drugs have direct cytotoxic effects on endothelial cells and tubular epithelial cells that have been attributed to the free iodine in the solution of the contrast drug.⁵⁴ The damage to endothelial cells has been studied by scanning electron microscopy that allowed visualization of cell shrinkage, fenestration of the endothelial layer, and formation of microvilli (blebbing) on the cell membrane, nuclear protrusion, and cellular apoptosis.² Damaged and apoptotic endothelial cells reduce the release of NO in the medullary vasa recta.^{54,56,57}

Damage to epithelial tubular cells by contrast drugs is severe, because of the high concentration of these drugs in the tubular fluid due to important water reabsorption in the proximal tubules. Studies *in vitro* in isolated tubular segments of rat kidney and cultured cells have demonstrated a

disruption of cell integrity and apoptosis following treatment with contrast drugs.^{3,58,59} Heinrich et al³ studied the cytotoxic effects of different contrast drugs on renal tubular cells in vitro. They concluded that iomeprol (LOCM) and iodixanol (IOCM) were not different at equal iodine concentrations in their toxicity on renal proximal tubular epithelial cells in vitro.⁶⁰

Intracellular signaling pathways involved in cell survival and death

Important results have been obtained by in vitro studies on primary human tubular cells and on HK2 cells exposed to contrast drugs.⁶¹ Andreucci et al⁶² demonstrated reduced cell survival due to decreased activation of Akt and ERK1/2, which are kinases that are known to be involved in cell survival/proliferation; this was alleviated by transfecting the HK2 cells with a constitutively active form of Akt. Even a white grape (*Vitis vinifera*) juice extract may alleviate toxicity on human renal proximal tubular (HK2) cells treated with a contrast drug, through modulation of signaling molecules.⁶³ The same authors have given evidence that in human renal tubular cells, contrast drugs affect the activation/deactivation of: transcription factors like FoxO3a and STAT3, which control the genes that are involved in apoptosis and cell proliferation; and other molecules known to be modulated by oxidative stresses, with some differences having been noted between low-osmolar and iso-osmolar contrast drugs.^{64–69} Experimental animal studies performed in vivo and in vitro have suggested that iodinated contrast drugs can induce caspase-mediated apoptosis of tubular epithelial cells.⁵⁷ Activation of shock proteins and concurrent inhibition of cytoprotective enzymes and prostaglandins may also cause contrast drug-induced apoptosis.^{70,71}

Pathogenesis of CI-AKI

On the basis of what has been demonstrated (and reported herein) by clinical studies in humans, but mainly by experimental studies in vivo and in vitro, the complex mechanisms by which contrast drugs cause AKI are summarized in Figure 1.⁷²

Prevention of CI-AKI

Discontinuation of other nephrotoxic drugs

Nephrotoxic drugs, such as aminoglycosides, vancomycin, amphotericin B, metformin, and nonsteroidal anti-inflammatory drugs, should be discontinued in patients receiving contrast drugs. It should be noted that metformin (an

oral antihyperglycemic drug for treating type 2 diabetes) stimulates intestinal production of lactic acid, is excreted unchanged by the kidneys, is retained in AKI, and may cause severe lactic acidosis that can be fatal. It has to be discontinued 12 hours before the contrast drug and not resumed until at least 36 hours after the procedure.⁷³ With regard to angiotensin-converting enzyme inhibitors (ACEIs) and angiotensin-receptor blockers (ARBs), according to many authors, patients with chronic renal failure under treatment with ACEIs or ARBs are at high risk of CI-AKI,^{74–80} particularly those of advanced age.⁸¹ According to KDIGO (Kidney Disease – Improving Global Outcomes) guidelines for the Acute Kidney Injury Work Group, there is insufficient evidence in favor of discontinuation of these drugs in patients undergoing injection of contrast drugs.⁸²

Choice of contrast drug

The first measure for prevention is the correct choice of contrast drug: a preference for IOCM has been suggested, since clinical studies have proven that the nephrotoxicity of iodixanol is lower than that of LOCM;⁸³ the lowest possible dose has to be used, and repetitive injection of the drug within the same procedure needs to be avoided. We should mention, however, that multiple meta-analyses of randomized clinical trials have failed to demonstrate differences between IOCM and LOCM.^{60,84} However, it has been pointed out that the relative renal safety of the low-osmolar iodixanol may vary with the different type of low-osmolar contrast agent, with a reduction in CI-AKI observed compared with iohexol/ioxaglate, but no difference noted when compared with iopromide/iopamidol/ioversol.⁸⁴

Intravenous volume expansion

Prevention is undoubtedly based on IV extracellular volume (ECV) expansion.^{5,83,85} This is obtained by IV infusion of 0.9% saline at an infusion rate of 1 mL/kg BW/hour that should begin 6–12 hours before the injection of the contrast drug and continue for up to 12–24 hours after the injection.⁸⁶ In patients undergoing cardiac catheterization, assessment of their volume status and left ventricular end-diastolic pressure-guided fluid administration has been shown to be useful in preventing CI-AKI without problems of excessive ECV expansion.⁸⁵

ECV expansion by IV infusion of saline has usually been considered more protective against CI-AKI than oral hydration.^{87,88} Trivedi et al⁸⁸ demonstrated in patients undergoing cardiac catheterization that the occurrence of CI-AKI 24 hours following contrast-drug injection was reduced in those

undergoing ECV expansion with IV normal saline than in those allowed only unrestricted oral fluid.

Surprisingly, a systematic review and meta-analysis of six randomized controlled trials involving 512 patients undergoing a contrast-enhanced procedure over 10 years, carried out by Hiremath et al⁸⁹ to compare oral versus IV ECV expansion demonstrated that oral hydration may be as effective as IV ECV expansion for CI-AKI. The rationale for IV saline infusion is based on the inhibition of reabsorption in the proximal tubules that is caused by ECV expansion, thereby increasing urine output; this will decrease the contact time of the contrast drug with the epithelial cells of the descending limb of Henle's loop, thereby reducing the toxic effects of the drug on these tubular cells.^{90,91} However, simple oral hydration through the inhibition of ADH will decrease water reabsorption in the collecting ducts, ie, distally to Henle's loop; and thus the protective effect on the epithelium of Henle's loop cannot take place.

Some authors have found better results with the use of sodium bicarbonate rather than sodium chloride.⁹²⁻¹⁰¹ A procedure would be administration of a bolus of 3 mL/kg BW/hour for 1 hour of a solution of sodium bicarbonate 154 mEq/L before the injection of contrast drug, followed by 1 mL/kg/hour for 6 hours.⁹⁴ However, other authors have disagreed, since they did not find any better benefit with sodium bicarbonate.¹⁰²⁻¹⁰⁵

The rationale for using sodium bicarbonate rather than sodium chloride is a further beneficial effect, in addition to ECV expansion: the increased urinary excretion of bicarbonate would decrease urine acidification, thereby reducing the production and increasing the neutralization of ROS.^{92,96,97,106,107} Attention should be paid when proceeding to ECV expansion that urine output is appropriate and the cardiovascular conditions allow it.⁸⁶ European Renal Best Practice¹⁰⁸ "recommends volume expansion with either isotonic sodium chloride or sodium bicarbonate solutions, rather than no volume expansion, in patients at increased risk for CIN". There is controversy on the usefulness of many therapeutic procedures to prevent CI-AKI: statins, *N*-acetylcysteine (NAC), furosemide, nebivolol, calcium channel blockers, theophylline, and hemodialysis.^{24,109,110}

Statins

Promising results have been obtained with the use of statins (HMG-CoA reductase inhibitors). Several clinical trials have demonstrated that statins protect patients undergoing coronary angiography against CI-AKI.^{87,111,112} Singh et al¹¹² have recently conducted a meta-analysis involving nine randomized controlled trials with 5,143 patients, 2,559 of

whom received statins and 2,584 placebo, all undergoing contrast-drug injection. All patients received standard ECV expansion, and in four studies NAC was added. Of the nine studies, six had patients with GFR <60 mL/min/1.73 m² and two excluded patients with GFR <70 mL/min/1.73 m². Results showed that statin pretreatment induced a significant reduction in risk of CI-AKI, demonstrating a protective effect of statins against CI-AKI in patients with normal renal function and in patients with impaired renal function (there was no significant difference in the degree of beneficial effect of statins on CI-AKI prevention between the two groups), and in patients cotreated with NAC. The authors concluded that statins (irrespective of the type of statin: simvastatin 40 mg, atorvastatin 80 mg, rosuvastatin 10 or 40 mg) have to be used to protect against CI-AKI in patients undergoing diagnostic or interventional procedures involving contrast drugs independently of the type of contrast drug used. Patti et al¹¹³ demonstrated that a short-term high dose of atorvastatin (80 mg, 12 hours before intervention followed by a further 40 mg preprocedure dose) decreased the incidence of CI-AKI in patients undergoing percutaneous coronary interventions.

What is the mechanism(s) of the protective effects of statins against the nephrotoxicity of contrast drugs? We have mentioned that contrast drugs directly constrict medullary descending vasa recta by 52%, reduce NO, and increase vasoconstrictor response to angiotensin II, and that endothelin, released by the damaged endothelial cells, contributes to medullary vasoconstriction and consequent hypoxia. According to Bonetti et al,¹¹⁴ statins decrease the vasoconstricting response to angiotensin and the synthesis of endothelin, thereby preventing renal hypoperfusion and medullary hypoxia. We have also mentioned that contrast drugs increase the incidence and severity of inflammation, with formation of ROS and proinflammatory cytokines, and complement activation. This leads proteins to precipitate, thereby causing tubular obstruction.¹¹⁵ Statins have antioxidant and anti-inflammatory properties and reduce endothelin secretion; these may be the mechanisms for CI-AKI prevention by statins.^{116,117}

Dashti-Khavidaki et al¹¹¹ published a review of all studies performed in vitro and in vivo evaluating the use of statins to prevent the nephrotoxicity of contrast drugs. They concluded that 1) chronic users of statins are less prone to CI-AKI compared with statin nonusers, 2) high doses of statins reduced the incidence of CI-AKI in statin nonusers, 3) the renoprotective effect of statins occurs in patients with normal kidney function or with mildly reduced renal function, and 4) the renoprotective effect of statins is not observed in patients with moderate-to-severe renal dysfunction.

In addition to their well known cholesterol-lowering activity, statins have pleiotropic effects: antioxidative, anti-inflammatory, and antithrombotic.^{118,119} They have been shown to have nephroprotective effects, eg, it has been demonstrated that they reduce ischemic–reperfusion renal injury in laboratory animals because of their antioxidant and anti-inflammatory activity.¹²⁰

N-acetylcysteine

The most widely used drug to prevent CI-AKI is NAC. As we have seen, an important role for ROS has been implicated in the nephrotoxicity caused by contrast drugs. Therefore, it has been suggested that antioxidants could be useful in preventing CI-AKI.⁸⁷ NAC would have a double-protective effect: in addition to its free radical-scavenger property, it may also increase the vasodilating effect of nitric oxide.^{48,121}

Brown et al¹²² conducted a meta-analysis to evaluate NAC in combination with sodium bicarbonate (NaHCO₃) for the prevention of CI-AKI. They concluded that combination prophylaxis with NAC and NaHCO₃ reduced the occurrence of CI-AKI. According to Chousterman et al,¹²³ however, the incidence of CI-AKI does not seem to be influenced by NAC, except if small changes in creatinine only are considered. Also, Alioglu et al¹²⁴ studied 113 patients (49 patients in an NAC group and 64 patients in a control group) with normal-to-subnormal GFR undergoing cardiovascular procedures. Patients in the NAC group received 600 mg NAC twice a day (on the day before and on the day of the cardiovascular procedure). They concluded that oral NAC administration did not reduce the incidence of cystatin C-based CI-AKI or serum creatinine-based CI-AKI in patients undergoing cardiovascular procedures.

A meta-analysis performed by Gonzales et al¹²⁵ did not support the efficacy of NAC to prevent CIN, and showed that those trials supporting a beneficial effect of NAC were due to an effect on serum creatinine independent of true changes in GFR. Many other meta-analyses have been published since 2003 with conflicting results.⁸⁷ An experimental study on human embryonic kidney cells demonstrated that contrast drugs (ionic HOCM ioxithalamate, nonionic LOCM iopromide, and IOCM iodixanol) caused a reduction in cell viability at 24 hours; pretreatment with NAC improved cell survival.¹²⁶ NAC may be given as an oral dose of 600 mg twice daily (day before and day of the procedure) or an IV dose of 150 mg/kg half an hour before the procedure or 50 mg/kg administered for 4 hours.¹²⁷

Furosemide

The use of the diuretic furosemide has been suggested for protecting the kidney against contrast drugs, based on its effects in reducing active tubular reabsorption (thereby reducing

O₂ consumption and medullary hypoxia) and in increasing urine output (thereby decreasing the contact time of contrast drugs with the tubular epithelium and consequently reducing epithelial damage). To prevent salt depletion, adequate fluid replacement is necessary. Marenzi et al¹²⁸ suggested delivery of IV fluid at an amount exactly matched to the volume of urine produced by the patient under the effect of furosemide. This procedure is performed easily by RenalGuard[®], a special device that would guide the physician in achieving high urine output without hypovolemia.¹²⁹ With the help of RenalGuard[®], in fact, physicians can deliver IV fluid at an amount exactly matched to the volume of urine produced by the patient under the effect of furosemide.

Nebivolol

A β₁-adrenergic receptor antagonist, nebivolol (5 mg/day for 1 week or 5 mg every 24 hours for 4 days) has been proven in patients with renal dysfunction undergoing coronary angiography to protect against CI-AKI, possibly acting via its antioxidant properties and NO-mediated vasodilating action.^{130–134}

Calcium-channel blockers

Calcium-channel blockers have been suggested to have protective effects against CI-AKI. The rationale is based on the fact that while in normal subjects, the Na⁺–Ca²⁺ exchanger pumps Ca²⁺ outside the renal tubular epithelial cells to keep intracellular Ca²⁺ low, under the effect of contrast drugs the Na⁺–Ca²⁺ exchanger can reversibly extrude Na⁺ for Ca²⁺ influx, thereby leading to intracellular Ca²⁺ overload, which is considered a key factor in ischemic cell injury and in CI-AKI.^{135–137} (Figure 1). Conflicting results have been obtained with calcium-channel blockers. Some authors have found a protective effect,^{138–140} while others have not.^{140–142}

Theophylline and aminophylline

After contrast-drug injection, there is an increase in urinary adenosine. Therefore, the adenosine antagonists theophylline and aminophylline were expected to have protective effects against contrast drugs. However, results have been conflicting: some articles were in favor,^{42,43,143,144} others not.^{44,45}

Hemodialysis

It has been demonstrated that in patients with chronic renal failure, different types of hemodialysis may remove contrast drugs from the blood, and that high-flux hemodialysis and hemodiafiltration do it more effectively than low-flux hemodialysis or hemofiltration.¹⁴⁵ However, prophylactic hemodialysis in patients with reduced renal function does not

diminish the incidence of CI-AKI.^{109,146,147} European Renal Best Practice¹⁰⁸ does “not recommend using prophylactic intermittent hemodialysis or hemofiltration for the purpose of prevention of CI-AKI”.

Risk-estimation equations to predict risk of CI-AKI

Risk assessment of CI-AKI before percutaneous coronary intervention is important, since it would allow prophylactic measures.¹⁴⁸ Undoubtedly, many risk factors for CI-AKI have been identified. These include diabetes, renal function impairment (particularly in diabetic patients), salt depletion and dehydration, congestive heart failure, age ≥ 70 years, and concurrent use of nephrotoxic drugs.^{5,109} However, the cumulative risk of their combination is unknown. That is why Mehran et al¹⁴⁹ developed a risk score for CI-AKI after percutaneous coronary intervention.

Many tools to predict the risk of CI-AKI have been reported in the literature. No consensus, however, exists on the best and most effective ones.¹⁵⁰ After reviewing the literature on the scoring tools used to predict the risk of CI-AKI, Raingruber et al¹⁵¹ selected the Mehran risk-scoring tool, which they judged the most comprehensive, reliable, and well tested. Mehran et al¹⁴⁹ compared 4,989 patients with a control group of 2,786 patients. Multivariate logistic regression was used to identify independent predictors of CI-AKI with $P < 0.0001$. Factors used to determine the risk score were hypotension (< 80 mmHg, requiring inotropic support with medications), use of an intra-aortic balloon pump, congestive heart failure, history of pulmonary edema, chronic kidney disease, diabetes mellitus, age > 75 years, anemia, and volume of contrast medium. These variables were assigned a weighted integer; the sum of the integers was a total risk score for each patient.

Bartholomew et al¹⁵² studied 20,479 patients who had undergone percutaneous coronary intervention. Their weighted-score variables were: creatinine clearance ≤ 60 mL/min (two scores), urgent percutaneous coronary intervention (two scores), intra-aortic balloon-pump use (two scores), diabetes mellitus (one score), congestive heart failure (one score), hypertension (one score), peripheral vascular disease (one score), and volume of contrast medium ≥ 260 mL (one score). The incidence of CI-AKI after percutaneous coronary intervention increased with each unit increase in score ($P < 0.0001$). With a score ≤ 1 , there was no CI-AKI after percutaneous coronary intervention. About 26% of patients with scores ≥ 9 developed CI-AKI after percutaneous coronary intervention ($P < 0.0001$).

Maioli et al¹⁵³ developed a simplified scoring system to predict CI-AKI before elective coronary angiography

and percutaneous coronary intervention. Their weighted-score variables were: age ≥ 73 years (one score), diabetes mellitus (two scores), left ventricular ejection fraction $\leq 45\%$ (two scores), baseline serum creatinine ≥ 1.5 mg/dL (two scores), baseline creatinine clearance ≤ 44 mL/min (two scores), posthydration serum creatinine \geq prehydration serum creatinine (two scores), and one procedure effected within the past 72 hours (three scores). A kidney-failure-risk equation (eight variables) is available on the website https://www.qxmd.com/calculate/calculator_125/kidney-failure-risk-equation-8-variable.

Acknowledgment

We acknowledge the Italian Medicines Agency (Agenzia Italiana del Farmaco, AIFA) for its generous financial support within the independent drug research program: Studio multiregionale di Farmacovigilanza attiva per valutazione di sicurezza ed appropriatezza prescrittiva ed aderenza alla Terapia di Farmaci biologici impiegati in Centri Regionali di Dermatologia, Gastroenterologia e Reumatologia.

Disclosure

The authors report no conflicts of interest in this work.

References

- Katzberg RW. Urography into the 21st century: new contrast media, renal handling, imaging characteristics, and nephrotoxicity. *Radiology*. 1997;204(2):297–312.
- Gospos C, Freudenberg N, Staubesand J, Mathias K, Papacharlampos X. The effect of contrast media on the aortic endothelium of rats. *Radiology*. 1983;147(3):685–688.
- Heinrich MC, Kuhlmann MK, Grgic A, Heckmann M, Kramann B, Uder M. Cytotoxic effects of ionic high-osmolar, nonionic monomeric, and nonionic iso-osmolar dimeric iodinated contrast media on renal tubular cells in vitro. *Radiology*. 2005;235(3):843–849.
- Idée JM, Pines E, Prigent P, Corot C. Allergy-like reactions to iodinated contrast agents: a critical analysis. *Fundam Clin Pharmacol*. 2005;19(3):263–281.
- Andreucci M, Solomon R, Tasanarong A. Side effects of radiographic contrast media: pathogenesis, risk factors, and prevention. *Biomed Res Int*. 2014;2014:741018.
- Singh J, Daftary A. Iodinated contrast media and their adverse reactions. *J Nucl Med Technol*. 2008;36(2):69–74; quiz 76–67.
- Dirkes S. Acute kidney injury: not just acute renal failure anymore? *Crit Care Nurse*. 2011;31(1):37–50.
- Dong M, Jiao Z, Liu T, Guo F, Li G. Effect of administration route on the renal safety of contrast agents: a meta-analysis of randomized controlled trials. *J Nephrol*. 2012;25(3):290–301.
- Katzberg RW, Barrett BJ. Risk of iodinated contrast material-induced nephropathy with intravenous administration. *Radiology*. 2007;243(3):622–628.
- Nyman U, Almen T, Jacobsson B, Aspelin P. Are intravenous injections of contrast media really less nephrotoxic than intra-arterial injections? *Eur Radiol*. 2012;22(6):1366–1371.
- Newhouse JH, Kho D, Rao QA, Starren J. Frequency of serum creatinine changes in the absence of iodinated contrast material: implications for studies of contrast nephrotoxicity. *AJR Am J Roentgenol*. 2008;191(2):376–382.

12. Katzberg RW, Newhouse JH. Intravenous contrast medium-induced nephrotoxicity: is the medical risk really as great as we have come to believe? *Radiology*. 2010;256(1):21–28.
13. McDonald JS, McDonald RJ, Comin J, et al. Frequency of acute kidney injury following intravenous contrast medium administration: a systematic review and meta-analysis. *Radiology*. 2013;267(1):119–128.
14. Andreucci VE, Fuiano G, Russo D, Andreucci M. Vasomotor nephropathy in the elderly. *Nephrol Dial Transplant*. 1998;13 Suppl 7:17–24.
15. Andreucci VE, Russo D, Cianciaruso B, Andreucci M. Some sodium, potassium and water changes in the elderly and their treatment. *Nephrol Dial Transplant*. 1996;11 Suppl 9:9–17.
16. Andreucci M. [Radiographic contrast nephropathy]. *G Ital Nefrol*. 2014;31(5):1–24. Italian.
17. Andreucci M. Side effects of radiographic contrast media. *Biomed Res Int*. 2014;2014:872574.
18. Andreucci M, Faga T, Sabbatini M, Pisani A, Russo D, Michael A. How to prevent contrast-induced nephropathy in clinical practice. *J Clin Nephrol Res*. 2014;1(1):1002.
19. Thomsen HS, Morcos SK. Contrast media and the kidney: European Society of Urogenital Radiology (ESUR) guidelines. *Br J Radiol*. 2003;76(908):513–518.
20. Mehran R, Nikolsky E. Contrast-induced nephropathy: definition, epidemiology, and patients at risk. *Kidney Int Suppl*. 2006;(100):S11–S15.
21. Solomon R. Contrast-induced acute kidney injury: is there a risk after intravenous contrast? *Clin J Am Soc Nephrol*. 2008;3(5):1242–1243.
22. Scanlon PJ, Faxon DP, Audet AM, et al. ACC/AHA guidelines for coronary angiography. *J Am Coll Cardiol*. 1999;33(6):1756–1824.
23. Hoffmann U, Fischereder M, Krüger B, Drobnik W, Krämer BK. The value of N-acetylcysteine in the prevention of radiocontrast agent-induced nephropathy seems questionable. *J Am Soc Nephrol*. 2004;15(2):407–410.
24. Roh S, Laroia A. Practicing safe use of nonionic, low-osmolality iodinated contrast. *Appl Radiol*. 2015;44(7):16–19.
25. Ehrmann S, Badin J, Savath L, et al. Acute kidney injury in the critically ill: is iodinated contrast medium really harmful? *Crit Care Med*. 2013;41(4):1017–1026.
26. Davenport MS, Khalatbari S, Cohan RH, Dillman JR, Myles JD, Ellis JH. Contrast material-induced nephrotoxicity and intravenous low-osmolality iodinated contrast material: risk stratification by using estimated glomerular filtration rate. *Radiology*. 2013;268(3):719–728.
27. Davenport MS, Khalatbari S, Dillman JR, Cohan RH, Caoili EM, Ellis JH. Contrast material-induced nephrotoxicity and intravenous low-osmolality iodinated contrast material. *Radiology*. 2013;267(1):94–105.
28. McDonald RJ, McDonald JS, Bida JP, et al. Intravenous contrast material-induced nephropathy: causal or coincident phenomenon? *Radiology*. 2013;267(1):106–118.
29. McDonald RJ, McDonald JS, Carter RE, et al. Intravenous contrast material exposure is not an independent risk factor for dialysis or mortality. *Radiology*. 2014;273(3):714–725.
30. McDonald JS, McDonald RJ, Carter RE, Katzberg RW, Kallmes DF, Williamson EE. Risk of intravenous contrast material-mediated acute kidney injury: a propensity score-matched study stratified by baseline-estimated glomerular filtration rate. *Radiology*. 2014;271(1):65–73.
31. Davenport MS, Cohan RH, Khalatbari S, Ellis JH. The challenges in assessing contrast-induced nephropathy: where are we now? *AJR Am J Roentgenol*. 2014;202(4):784–789.
32. Parsons LS. Performing a 1:N case-control match on propensity score. 2004. Available from: <http://www2.sas.com/proceedings/sugi29/165-29.pdf>. Accessed March 6, 2017.
33. Thomsen HS, Stacul F. CIN: can we forget it? *Acta Radiol*. 2014;55(9):1027–1030.
34. Azzouz M, Romsing J, Thomsen HS. Fluctuations in eGFR in relation to unenhanced and enhanced MRI and CT outpatients. *Eur J Radiol*. 2014;83(6):886–892.
35. Detrenis S, Meschi M, Musini S, Savazzi G. Lights and shadows on the pathogenesis of contrast-induced nephropathy: state of the art. *Nephrol Dial Transplant*. 2005;20(8):1542–1550.
36. Andreucci M, Faga T, Pisani A, Sabbatini M, Michael A. Pathogenesis of acute renal failure induced by iodinated radiographic contrast media. *Austin J Nephrol Hypertens*. 2014;1(1):1005.
37. Katzberg RW, Morris TW, Schulman G, et al. Reactions to intravenous contrast media – part II: acute renal response in euvolemic and dehydrated dogs. *Radiology*. 1983;147(2):331–334.
38. Aspelin P, Aubry P, Fransson SG, Strasser R, Willenbrock R, Berg KJ. Nephrotoxic effects in high-risk patients undergoing angiography. *N Engl J Med*. 2003;348(6):491–499.
39. Liu ZZ, Viegas VU, Perlewitz A, et al. Iodinated contrast media differentially affect afferent and efferent arteriolar tone and reactivity in mice: a possible explanation for reduced glomerular filtration rate. *Radiology*. 2012;265(3):762–771.
40. Heyman SN, Rosen S, Rosenberger C. Renal parenchymal hypoxia, hypoxia adaptation, and the pathogenesis of radiocontrast nephropathy. *Clin J Am Soc Nephrol*. 2008;3(1):288–296.
41. Arakawa K, Suzuki H, Naitoh M, et al. Role of adenosine in the renal responses to contrast medium. *Kidney Int*. 1996;49(5):1199–1206.
42. Erley CM, Duda SH, Rehfuß D, et al. Prevention of radiocontrast-media-induced nephropathy in patients with pre-existing renal insufficiency by hydration in combination with the adenosine antagonist theophylline. *Nephrol Dial Transplant*. 1999;14(5):1146–1149.
43. Huber W, Ilgmann K, Page M, et al. Effect of theophylline on contrast material-nephropathy in patients with chronic renal insufficiency: controlled, randomized, double-blinded study. *Radiology*. 2002;223(3):772–779.
44. Abizaid AS, Clark CE, Mintz GS, et al. Effects of dopamine and aminophylline on contrast-induced acute renal failure after coronary angioplasty in patients with preexisting renal insufficiency. *Am J Cardiol*. 1999;83(2):260–263.
45. Shammam NW, Kapalis MJ, Harris M, McKinney D, Coyne EP. Aminophylline does not protect against radiocontrast nephropathy in patients undergoing percutaneous angiographic procedures. *J Invasive Cardiol*. 2001;13(11):738–740.
46. Jensen H, Doughty RW, Grant D, Myhre O. A modified model of gentamicin induced renal failure in rats: toxicological effects of the iodinated X-ray contrast media ioversol and potential usefulness for toxicological evaluation of iodinated X-ray contrast media. *Exp Toxicol Pathol*. 2013;65(5):601–607.
47. Sendeski M, Patzak A, Pallone TL, Cao C, Persson AE, Persson PB. Iodixanol, constriction of medullary descending vasa recta, and risk for contrast medium-induced nephropathy. *Radiology*. 2009;251(3):697–704.
48. Heyman SN, Rosen S, Khamaisi M, Idée JM, Rosenberger C. Reactive oxygen species and the pathogenesis of radiocontrast-induced nephropathy. *Invest Radiol*. 2010;45(4):188–195.
49. Pisani A, Riccio E, Andreucci M, et al. Role of reactive oxygen species in pathogenesis of radiocontrast-induced nephropathy. *Biomed Res Int*. 2013;2013:868321.
50. Pisani A, Sabbatini M, Riccio E, et al. Effect of a recombinant manganese superoxide dismutase on prevention of contrast-induced acute kidney injury. *Clin Exp Nephrol*. 2014;18(3):424–431.
51. Heyman SN, Clark BA, Kaiser N, et al. Radiocontrast agents induce endothelin release in vivo and in vitro. *J Am Soc Nephrol*. 1992;3(1):58–65.
52. Giaccia AJ, Simon MC, Johnson R. The biology of hypoxia: the role of oxygen sensing in development, normal function, and disease. *Genes Dev*. 2004;18(18):2183–2194.
53. Sabbatini M, Santillo M, Pisani A, et al. Inhibition of Ras/ERK1/2 signaling protects against postischemic renal injury. *Am J Physiol Renal Physiol*. 2006;290(6):F1408–F1415.
54. Sendeski MM. Pathophysiology of renal tissue damage by iodinated contrast media. *Clin Exp Pharmacol Physiol*. 2011;38(5):292–299.
55. Pacher P, Beckman JS, Liaudet L. Nitric oxide and peroxynitrite in health and disease. *Physiol Rev*. 2007;87(1):315–424.

56. Quintavalle C, Brenca M, De Micco F, et al. In vivo and in vitro assessment of pathways involved in contrast media-induced renal cells apoptosis. *Cell Death Dis.* 2011;2:e155.
57. Lee HC, Chang JG, Yen HW, Liu IH, Lai WT, Sheu SH. Ionic contrast media induced more apoptosis in diabetic kidney than nonionic contrast media. *J Nephrol.* 2011;24(3):376–380.
58. Hardiek K, Katholik RE, Ramkumar V, Deitrick C. Proximal tubule cell response to radiographic contrast media. *Am J Physiol Renal Physiol.* 2001;280(1):F61–F70.
59. Michael A, Faga T, Pisani A, et al. Molecular mechanisms of renal cellular nephrotoxicity due to radiocontrast media. *Biomed Res Int.* 2014;2014:249810.
60. Heinrich MC, Häberle L, Müller V, Bautz W, Uder M. Nephrotoxicity of iso-osmolar iodixanol compared with nonionic low-osmolar contrast media: meta-analysis of randomized controlled trials. *Radiology.* 2009;250(1):68–86.
61. Andreucci M. [Contrast media and nephrotoxicity: a molecular conundrum]. *G Ital Nefrol.* 2011;28(4):355. Italian.
62. Andreucci M, Fuiano G, Presta P, et al. Radiocontrast media cause dephosphorylation of Akt and downstream signaling targets in human renal proximal tubular cells. *Biochem Pharmacol.* 2006;72(10):1334–1342.
63. Andreucci M, Faga T, Pisani A, et al. Reversal of radiocontrast medium toxicity in human renal proximal tubular cells by white grape juice extract. *Chem Biol Interact.* 2015;229:17–25.
64. Andreucci M, Faga T, Russo D, et al. Differential activation of signaling pathways by low-osmolar and iso-osmolar radiocontrast agents in human renal tubular cells. *J Cell Biochem.* 2014;115(2):281–289.
65. Andreucci M, Lucisano G, Faga T, et al. Differential activation of signaling pathways involved in cell death, survival and inflammation by radiocontrast media in human renal proximal tubular cells. *Toxicol Sci.* 2011;119(2):408–416.
66. Andreucci M, Faga T, Pisani A, Sabbatini M, Michael A. Acute kidney injury by radiographic contrast media: pathogenesis and prevention. *Biomed Res Int.* 2014;2014:362725.
67. Andreucci M, Faga T, Lucisano G, et al. Mycophenolic acid inhibits the phosphorylation of NF- κ B and JNKs and causes a decrease in IL-8 release in H₂O₂-treated human renal proximal tubular cells. *Chem Biol Interact.* 2010;185(3):253–262.
68. Andreucci M, Fuiano G, Presta P, et al. Downregulation of cell survival signalling pathways and increased cell damage in hydrogen peroxide-treated human renal proximal tubular cells by alpha-erythropoietin. *Cell Prolif.* 2009;42(4):554–561.
69. Andreucci M, Michael A, Kramers C, et al. Renal ischemia/reperfusion and ATP depletion/repletion in LLC-PK₁ cells result in phosphorylation of FKHR and FKHL1. *Kidney Int.* 2003;64(4):1189–1198.
70. Cunha MA, Schor N. Effects of gentamicin, lipopolysaccharide, and contrast media on immortalized proximal tubular cells. *Ren Fail.* 2002;24(6):687–690.
71. Peer A, Averbukh Z, Berman S, Modai D, Averbukh M, Weissgarten J. Contrast media augmented apoptosis of cultured renal mesangial, tubular, epithelial, endothelial, and hepatic cells. *Invest Radiol.* 2003;38(3):177–182.
72. Andreucci M, Faga T, Riccio E, Sabbatini M, Pisani A, Michael A. The potential use of biomarkers in predicting contrast-induced acute kidney injury. *Int J Nephrol Renovasc Dis.* 2016;9:205–221.
73. Thomson K. Safe use of radiographic contrast media. *Aust Prescr.* 2010;33(1):19–22.
74. Kalyesubula R, Bagasha P, Perazella MA. ACE-I/ARB therapy prior to contrast exposure: what should the clinician do? *Biomed Res Int.* 2014;2014:423848.
75. Neyra JA, Shah S, Mooney R, Jacobsen G, Yee J, Novak JE. Contrast-induced acute kidney injury following coronary angiography: a cohort study of hospitalized patients with or without chronic kidney disease. *Nephrol Dial Transplant.* 2013;28(6):1463–1471.
76. Schoolwerth AC, Sica DA, Ballermann BJ, Wilcox CS. Renal considerations in angiotensin converting enzyme inhibitor therapy: a statement for healthcare professionals from the Council on the Kidney in Cardiovascular Disease and the Council for High Blood Pressure Research of the American Heart Association. *Circulation.* 2001;104(16):1985–1991.
77. Cirit M, Toprak O, Yesil M, et al. Angiotensin-converting enzyme inhibitors as a risk factor for contrast-induced nephropathy. *Nephron Clin Pract.* 2006;104(1):c20–c27.
78. Kiski D, Stepper W, Brand E, Breithardt G, Reinecke H. Impact of renin-angiotensin-aldosterone blockade by angiotensin-converting enzyme inhibitors or AT-1 blockers on frequency of contrast medium-induced nephropathy: a post-hoc analysis from the Dialysis-versus-Diuresis (DVD) trial. *Nephrol Dial Transplant.* 2010;25(3):759–764.
79. Rim MY, Ro H, Kang WC, et al. The effect of renin-angiotensin-aldosterone system blockade on contrast-induced acute kidney injury: a propensity-matched study. *Am J Kidney Dis.* 2012;60(4):576–582.
80. Umruddin Z, Moe K, Superdock K. ACE inhibitor or angiotensin II receptor blocker use is a risk factor for contrast-induced nephropathy. *J Nephrol.* 2012;25(5):776–781.
81. Onuigbo MA, Onuigbo NT. Does renin-angiotensin aldosterone system blockade exacerbate contrast-induced nephropathy in patients with chronic kidney disease? A prospective 50-month Mayo Clinic study. *Ren Fail.* 2008;30(1):67–72.
82. [No authors listed]. KDIGO clinical practice guideline for acute kidney injury. *Kidney Int Suppl.* 2012;2(1):1–138.
83. Laville M, Juillard L. Contrast-induced acute kidney injury: how should at-risk patients be identified and managed? *J Nephrol.* 2010;23(4):387–398.
84. Reed M, Meier P, Tamhane UU, Welch KB, Moscucci M, Gurm HS. The relative renal safety of iodixanol compared with low-osmolar contrast media: a meta-analysis of randomized controlled trials. *JACC Cardiovasc Interv.* 2009;2(7):645–654.
85. Brar SS, Aharonian V, Mansukhani P, et al. Haemodynamic-guided fluid administration for the prevention of contrast-induced acute kidney injury: the POSEIDON randomised controlled trial. *Lancet.* 2014;383(9931):1814–1823.
86. Mueller C. Prevention of contrast-induced nephropathy with volume supplementation. *Kidney Int Suppl.* 2006;(100):S16–S19.
87. Davenport MS, Cohan RH, Ellis JH. Contrast media controversies in 2015: imaging patients with renal impairment or risk of contrast reaction. *AJR Am J Roentgenol.* 2015;204(6):1174–1181.
88. Trivedi HS, Moore H, Nasr S, et al. A randomized prospective trial to assess the role of saline hydration on the development of contrast nephrotoxicity. *Nephron Clin Pract.* 2003;93(1):C29–C34.
89. Hiremath S, Akbari A, Shabana W, Fergusson DA, Knoll GA. Prevention of contrast-induced acute kidney injury: is simple oral hydration similar to intravenous? A systematic review of the evidence. *PLoS One.* 2013;8(3):e60009.
90. Ellis JH, Cohan RH. Prevention of contrast-induced nephropathy: an overview. *Radiol Clin North Am.* 2009;47(5):801–811.
91. Solomon R, Dauerman HL. Contrast-induced acute kidney injury. *Circulation.* 2010;122(23):2451–2455.
92. Zoungas S, Ninomiya T, Huxley R, et al. Systematic review: sodium bicarbonate treatment regimens for the prevention of contrast-induced nephropathy. *Ann Intern Med.* 2009;151(9):631–638.
93. Merten GJ, Burgess WP, Gray LV, et al. Prevention of contrast-induced nephropathy with sodium bicarbonate: a randomized controlled trial. *JAMA.* 2004;291(19):2328–2334.
94. Masuda M, Yamada T, Mine T, et al. Comparison of usefulness of sodium bicarbonate versus sodium chloride to prevent contrast-induced nephropathy in patients undergoing an emergent coronary procedure. *Am J Cardiol.* 2007;100(5):781–786.
95. Ozcan EE, Guner S, Akdeniz B, et al. Sodium bicarbonate, N-acetylcysteine, and saline for prevention of radiocontrast-induced nephropathy: a comparison of 3 regimens for protecting contrast-induced nephropathy in patients undergoing coronary procedures – a single-center prospective controlled trial. *Am Heart J.* 2007;154(3):539–544.
96. Navaneethan SD, Singh S, Appasamy S, Wing RE, Sehgal AR. Sodium bicarbonate therapy for prevention of contrast-induced nephropathy: a systematic review and meta-analysis. *Am J Kidney Dis.* 2009;53(4):617–627.
97. Tamura A, Goto Y, Miyamoto K, et al. Efficacy of single-bolus administration of sodium bicarbonate to prevent contrast-induced nephropathy in patients with mild renal insufficiency undergoing an elective coronary procedure. *Am J Cardiol.* 2009;104(7):921–925.

98. Hoste EA, De Waele JJ, Gevaert SA, Uchino S, Kellum JA. Sodium bicarbonate for prevention of contrast-induced acute kidney injury: a systematic review and meta-analysis. *Nephrol Dial Transplant*. 2010;25(3):747–758.
99. Joannidis M, Schmid P, Wiedermann CJ. Prevention of contrast media-induced nephropathy by isotonic sodium bicarbonate: a meta-analysis. *Wien Klin Wochenschr*. 2008;120(23–24):742–748.
100. Pakfetrat M, Nikoo MH, Malekmakan L, et al. A comparison of sodium bicarbonate infusion versus normal saline infusion and its combination with oral acetazolamide for prevention of contrast-induced nephropathy: a randomized, double-blind trial. *Int Urol Nephrol*. 2009;41(3):629–634.
101. Jang JS, Jin HY, Seo JS, et al. Sodium bicarbonate therapy for the prevention of contrast-induced acute kidney injury: a systematic review and meta-analysis. *Circ J*. 2012;76(9):2255–2265.
102. Brar SS, Shen AY, Jorgensen MB, et al. Sodium bicarbonate vs sodium chloride for the prevention of contrast medium-induced nephropathy in patients undergoing coronary angiography: a randomized trial. *JAMA*. 2008, 300(9):1038–1046.
103. Brar SS, Hiremath S, Dangas G, Mehran R, Brar SK, Leon MB. Sodium bicarbonate for the prevention of contrast induced-acute kidney injury: a systematic review and meta-analysis. *Clin J Am Soc Nephrol*. 2009;4(10):1584–1592.
104. Shavit L, Korenfeld R, Lifschitz M, Butnaru A, Slotki I. Sodium bicarbonate versus sodium chloride and oral N-acetylcysteine for the prevention of contrast-induced nephropathy in advanced chronic kidney disease. *J Interv Cardiol* 2009;22(6):556–563.
105. Vasheghani-Farahani A, Sadigh G, Kassaian SE, et al. Sodium bicarbonate plus isotonic saline versus saline for prevention of contrast-induced nephropathy in patients undergoing coronary angiography: a randomized controlled trial. *Am J Kidney Dis*. 2009;54(4):610–618.
106. Reddan D, Laville M, Garovic VD. Contrast-induced nephropathy and its prevention: what do we really know from evidence-based findings? *J Nephrol*. 2009;22(3):333–351.
107. Burgess WP, Walker PJ. Mechanisms of contrast-induced nephropathy reduction for saline (NaCl) and sodium bicarbonate (NaHCO₃). *Biomed Res Int*. 2014;2014:510385.
108. Fliser D, Laville M, Covic A, et al. A European Renal Best Practice (ERBP) position statement on the Kidney Disease Improving Global Outcomes (KDIGO) clinical practice guidelines on acute kidney injury – part 1: definitions, conservative management and contrast-induced nephropathy. *Nephrol Dial Transplant*. 2012;27(12):4263–4272.
109. Andreucci M, Faga T, Pisani A, Sabbatini M, Russo D, Michael A. Prevention of contrast-induced nephropathy through a knowledge of its pathogenesis and risk factors. *ScientificWorldJournal*. 2014;2014:823169.
110. Thomsen HS, Morcos SK, Barrett BJ. Contrast-induced nephropathy: the wheel has turned 360 degrees. *Acta Radiol*. 2008;49(6):646–657.
111. Dashti-Khavidaki S, Moghaddas A, Heydari B, Khalili H, Lessan-Pezeshki M. Statins against drug-induced nephrotoxicity. *J Pharm Pharm Sci*. 2013;16(4):588–608.
112. Singh N, Lee JZ, Huang JJ, et al. Benefit of statin pretreatment in prevention of contrast-induced nephropathy in different adult patient population: systematic review and meta-analysis. *Open Heart*. 2014;1(1):e000127.
113. Patti G, Ricottini E, Nusca A, et al. Short-term, high-dose atorvastatin pretreatment to prevent contrast-induced nephropathy in patients with acute coronary syndromes undergoing percutaneous coronary intervention (from the ARMYDA-CIN [Atorvastatin for Reduction of Myocardial Damage During Angioplasty-Contrast-Induced Nephropathy] trial. *Am J Cardiol*. 2011;108(1):1–7.
114. Bonetti PO, Lerman LO, Napoli C, Lerman A. Statin effects beyond lipid lowering: are they clinically relevant? *Eur Heart J*. 2003;24(3):225–248.
115. Goldenberg I, Matetzky S. Nephropathy induced by contrast media: pathogenesis, risk factors and preventive strategies. *CMAJ*. 2005;172(11):1461–1471.
116. Wierzbicki AS, Poston R, Ferro A. The lipid and non-lipid effects of statins. *Pharmacol Ther*. 2003;99(1):95–112.
117. Zager RA, Johnson AC, Hanson SY. Radiographic contrast media-induced tubular injury: evaluation of oxidant stress and plasma membrane integrity. *Kidney Int*. 2003;64(1):128–139.
118. Schachter M. Chemical, pharmacokinetic and pharmacodynamic properties of statins: an update. *Fundam Clin Pharmacol*. 2005;19(1):117–125.
119. Epstein M, Campese VM. Pleiotropic effects of 3-hydroxy-3-methylglutaryl coenzyme A reductase inhibitors on renal function. *Am J Kidney Dis*. 2005;45(1):2–14.
120. Sharyo S, Yokota-Ikeda N, Mori M, et al. Pravastatin improves renal ischemia-reperfusion injury by inhibiting the mevalonate pathway. *Kidney Int*. 2008;74(5):577–584.
121. Safirstein R, Andrade L, Vieira JM. Acetylcysteine and nephrotoxic effects of radiographic contrast agents: a new use for an old drug. *N Engl J Med*. 2000;343(3):210–212.
122. Brown JR, Block CA, Malenka DJ, O'Connor GT, Schoolwerth AC, Thompson CA. Sodium bicarbonate plus N-acetylcysteine prophylaxis: a meta-analysis. *JACC Cardiovasc Interv*. 2009;2(11):1116–1124.
123. Chousterman BG, Bouadma L, Moutereau S, et al. Prevention of contrast-induced nephropathy by N-acetylcysteine in critically ill patients: different definitions, different results. *J Crit Care*. 2013;28(5):701–709.
124. Alioglu E, Saygi S, Turk U, et al. N-acetylcysteine in preventing contrast-induced nephropathy assessed by cystatin C. *Cardiovasc Ther*. 2013;31(3):168–173.
125. Gonzales DA, Norsworthy KJ, Kern SJ, et al. A meta-analysis of N-acetylcysteine in contrast-induced nephrotoxicity: unsupervised clustering to resolve heterogeneity. *BMC Med*. 2007;5:32.
126. Lee HC, Sheu SH, Liu IH, et al. Impact of short-duration administration of N-acetylcysteine, probucol and ascorbic acid on contrast-induced cytotoxicity. *J Nephrol*. 2012;25(1):56–62.
127. Baker CS, Wragg A, Kumar S, De Palma R, Baker LR, Knight CJ. A rapid protocol for the prevention of contrast-induced renal dysfunction: the RAPPID study. *J Am Coll Cardiol*. 2003;41(12):2114–2118.
128. Marenzi G, Ferrari C, Marana I, et al. Prevention of contrast nephropathy by furosemide with matched hydration: the MYTHOS (Induced Diuresis with Matched Hydration Compared to Standard Hydration for Contrast Induced Nephropathy Prevention) trial. *JACC Cardiovasc Interv*. 2012;5(1):90–97.
129. Briguori C, Visconti G, Focaccio A, et al. Renal Insufficiency after Contrast Media Administration Trial II (REMEDIAL II): RenalGuard system in high-risk patients for contrast-induced acute kidney injury. *Circulation*. 2011;124(11):1260–1269.
130. Avcı E, Yeşil M, Bayata S, Postacı N, Arikan E, Cirit M. The role of nebivolol in the prevention of contrast-induced nephropathy in patients with renal dysfunction. *Anadolu Kardiyol Derg*. 2011;11(7):613–617.
131. Gunebakmaz O, Kaya MG, Koc F, et al. Does nebivolol prevent contrast-induced nephropathy in humans? *Clin Cardiol*. 2012;35(4):250–254.
132. Veverka A, Nuzum DS, Jolly JL. Nebivolol: a third-generation β -adrenergic blocker. *Ann Pharmacother*. 2006;40(7–8):1353–1360.
133. Sule SS, Frishman W. Nebivolol: new therapy update. *Cardiol Rev*. 2006;14(5):259–264.
134. Toprak O, Cirit M, Tanrisev M, et al. Preventive effect of nebivolol on contrast-induced nephropathy in rats. *Nephrol Dial Transplant*. 2008;23(3):853–859.
135. Yang D, Yang D, Jia R, Tan J. Na⁺/Ca²⁺ exchange inhibitor, KB-R7943, attenuates contrast-induced acute kidney injury. *J Nephrol*. 2013;26(5):877–885.
136. Duan SB, Liu FY, Luo JA, et al. Nephrotoxicity of high- and low-osmolar contrast media: the protective role of amlodipine in a rat model. *Acta Radiol*. 2000;41(5):503–507.
137. Yang D, Yang D. Role of intracellular Ca²⁺ and Na⁺/Ca²⁺ exchanger in the pathogenesis of contrast-induced acute kidney injury. *Biomed Res Int*. 2013;2013:678456.

138. Neumayer HH, Junge W, Küfner A, Wenning A. Prevention of radiocontrast-media-induced nephrotoxicity by the calcium channel blocker nitrendipine: a prospective randomised clinical trial. *Nephrol Dial Transplant*. 1989;4(12):1030–1036.
139. Russo D, Testa A, Volpe LD, Sansone G. Randomised prospective study on renal effects of two different contrast media in humans: protective role of a calcium channel blocker. *Nephron*. 1990;55(3):254–257.
140. Spångberg-Viklund B, Berglund J, Nikonoff T, Nyberg P, Skau T, Larsson R. Does prophylactic treatment with felodipine, a calcium antagonist, prevent low-osmolar contrast-induced renal dysfunction in hydrated diabetic and nondiabetic patients with normal or moderately reduced renal function? *Scand J Urol Nephrol*. 1996;30(1):63–68.
141. Solomon R, Werner C, Mann D, D'Elia J, Silva P. Effects of saline, mannitol, and furosemide to prevent acute decreases in renal function induced by radiocontrast agents. *N Engl J Med*. 1994;331(21):1416–1420.
142. Khoury Z, Schlicht JR, Como J, et al. The effect of prophylactic nifedipine on renal function in patients administered contrast media. *Pharmacotherapy*. 1995;15(1):59–65.
143. Erley CM, Duda SH, Schlepckow S, et al. Adenosine antagonist theophylline prevents the reduction of glomerular filtration rate after contrast media application. *Kidney Int*. 1994;45(5):1425–1431.
144. Katholi RE, Taylor GJ, McCann WP, et al. Nephrotoxicity from contrast media: attenuation with theophylline. *Radiology*. 1995;195(1):17–22.
145. Schindler R, Stahl C, Venz S, Ludat K, Krause W, Frei U. Removal of contrast media by different extracorporeal treatments. *Nephrol Dial Transplant*. 2001;16(7):1471–1474.
146. Lehnert T, Keller E, Gondolf K, Schäffner T, Pavenstädt H, Scholmeyer P. Effect of haemodialysis after contrast medium administration in patients with renal insufficiency. *Nephrol Dial Transplant*. 1998;13(2):358–362.
147. Vogt B, Ferrari P, Schönholzer C, et al. Prophylactic hemodialysis after radiocontrast media in patients with renal insufficiency is potentially harmful. *Am J Med*. 2001;111(9):692–698.
148. Nyman U, Björk J, Aspelin P, Marenzi G. Contrast medium dose-to-GFR ratio: a measure of systemic exposure to predict contrast-induced nephropathy after percutaneous coronary intervention. *Acta Radiol*. 2008;49(6):658–667.
149. Mehran R, Aymong ED, Nikolsky E, et al. A simple risk score for prediction of contrast-induced nephropathy after percutaneous coronary intervention: development and initial validation. *J Am Coll Cardiol*. 2004;44(7):1393–1399.
150. Skelding KA, Best PJ, Bartholomew BA, Lennon RJ, O'Neill WW, Rihal CS. Validation of a predictive risk score for radiocontrast-induced nephropathy following percutaneous coronary intervention. *J Invasive Cardiol*. 2007;19(5):229–233.
151. Raingruber B, Kirkland-Walsh H, Chahon N, Kellermann M. Using the Mehran risk scoring tool to predict risk for contrast medium-induced nephropathy in patients undergoing percutaneous angiography. *Crit Care Nurse*. 2011;31(1):e17–e22.
152. Bartholomew BA, Harjai KJ, Dukkipati S, et al. Impact of nephropathy after percutaneous coronary intervention and a method for risk stratification. *Am J Cardiol*. 2004;93(12):1515–1519.
153. Maioli M, Toso A, Gallopin M, et al. Preprocedural score for risk of contrast-induced nephropathy in elective coronary angiography and intervention. *J Cardiovasc Med*. 2010;11(6):444–449.

Drug, Healthcare and Patient Safety

Publish your work in this journal

Drug, Healthcare and Patient Safety is an international, peer-reviewed open access journal exploring patient safety issues in the healthcare continuum from diagnostic and screening interventions through to treatment, drug therapy and surgery. The journal is characterized by the rapid reporting of reviews, original research, clinical, epidemiological and

post-marketing surveillance studies, risk management, health literacy and educational programs across all areas of healthcare delivery. The manuscript management system is completely online and includes a very quick and fair peer-review system. Visit <http://www.dovepress.com/testimonials.php> to read real quotes from published authors.

Submit your manuscript here: <https://www.dovepress.com/drug-healthcare-and-patient-safety-journal>

Dovepress