

## Case report

## Tectonic corneal lamellar grafting for surgically-induced necrotizing scleritis after strabismus surgery: Case report &amp; literature review



Radha Ram\*

Texan Eye, 1700 S Mopac, Austin, TX, USA

## ARTICLE INFO

## Keywords:

Surgically induced necrotizing scleritis  
 Corneal graft  
 Strabismus  
 Gout  
 Subconjunctival abscess  
 Optical coherence tomography

## ABSTRACT

**Purpose:** To report the first case of infectious surgically-induced necrotizing scleritis following strabismus surgery which was treated successfully with a tectonic corneal graft.

**Observations:** We report a case of surgically-induced necrotizing scleritis after strabismus surgery in a 61-year-old gentleman with gout and a subconjunctival abscess. Surgical drainage of the subconjunctival abscess led to a diagnosis of scleral melt which was subsequently treated with a tectonic corneal graft along with aggressive medical management. Over the following eight months, the patient showed no signs of endophthalmitis, graft necrosis, nor graft dehiscence, and serial anterior segment optical coherence tomography imaging demonstrated anatomic stability.

**Conclusions and importance:** This case offers further insights into a rare but vision-threatening and potentially life-threatening diagnosis. In conjunction with aggressive local and systemic treatment, tectonic lamellar keratoplasty provides good therapeutic and tectonic results for scleral necrosis after strabismus surgery. This case also demonstrates the importance of screening for associated systemic risk factors in any patient with scleritis for appropriate, targeted therapy.

## 1. Introduction

Surgically-induced necrotizing scleritis (SINS) is a rare but serious complication of ocular surgery. Though the majority of SINS cases occur after cataract surgery and pterygium excision, SINS has been reported after all types of ocular surgeries.<sup>1–3</sup> Its occurrence after strabismus surgery is rare but has been reported in both adults and children.<sup>4–11</sup> The treatment of SINS includes immunosuppressive agents, antibiotics, and/or tectonic reconstruction. Most of the reported cases of necrotizing scleritis were controlled with steroids with or without surgical debridement. Tectonic reconstruction with the use of corneal grafting for SINS has not been well documented. We report a case of SINS after strabismus surgery that was successfully treated with a tectonic corneal graft.

## 2. Case report

A 61-year-old man presented with an acute onset of severe eye pain and discharge in his right eye. He had undergone uncomplicated strabismus surgery for a large-angle, sensory exotropia ten days prior and had recently discontinued his post-operative antibiotic-steroid eye drops.

Past ocular history was significant for advanced glaucoma, strabismus surgery performed in childhood, and his recent uncomplicated strabismus surgery which was a re-recession and re-resection of the horizontal muscles of the right eye. He had a long history of being monocular due to advanced glaucoma in the right eye. His past medical history and review of systems were negative. The patient denied fevers, joint pain, rashes, and headaches. He was on ocular hypotensive eye drops for advanced glaucoma and was not on any systemic medications. He smoked one pack of cigarettes per day and consumed alcohol daily.

On examination, best-corrected visual acuity was hand motion vision in the right eye and 20/20 vision in the left eye, which was the same visual acuity he had prior to his most recent strabismus surgery. He was orthotropic with normal ductions. Slit lamp examination of the right eye demonstrated a subconjunctival abscess adjacent to the medial rectus muscle associated with a small conjunctival epithelial defect and a trace amount of mucopurulent discharge. There were no signs of intraocular inflammation.

Mucopurulent material from the subconjunctival abscess was easily drained through the surgical wound at the slit lamp and sent for cultures. Cultures grew methicillin-resistant *Staphylococcus aureus* (MRSA) that was sensitive to clindamycin and vancomycin. Over the ensuing week, the patient gradually improved on oral clindamycin and topical

\* Texan Eye, 1700 S Mopac, Austin, TX, 78704, USA.  
 E-mail address: [RadhaRamMD@gmail.com](mailto:RadhaRamMD@gmail.com).

<https://doi.org/10.1016/j.ajoc.2018.04.025>

Received 13 January 2018; Received in revised form 12 April 2018; Accepted 25 April 2018  
 Available online 01 May 2018

2451-9936/ © 2018 The Author. Published by Elsevier Inc. This is an open access article under the CC BY-NC-ND license (<http://creativecommons.org/licenses/by-nc-nd/4.0/>).

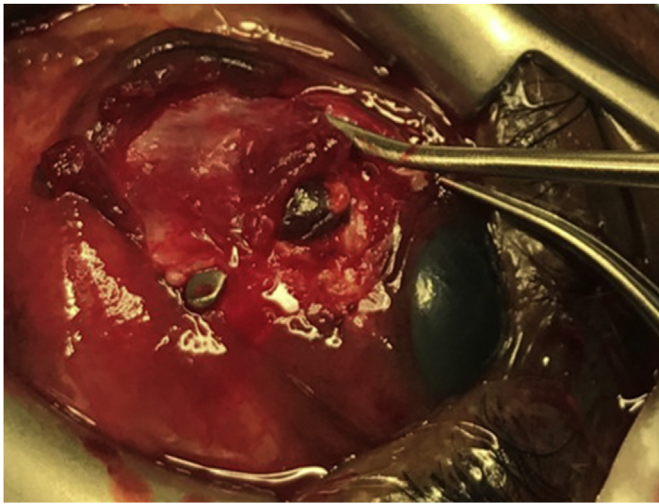


Fig. 1. Intraoperative photograph showing exposed uveal tissue anterior to the medial rectus muscle.

fortified vancomycin along with serial drainages in the clinic.

A few days after finishing his fourteen-day course of oral clindamycin, the severe right eye pain returned. On exam, there was a recurrence of a subconjunctival elevation with no visible mucopurulent discharge. The cornea, anterior chamber, iris, vitreous, and retina remained stable with no signs of intraocular inflammation. Since the mass returned despite maximal antimicrobial therapy, the patient was taken to the operating room for surgical drainage.

Intraoperatively, after the limbal conjunctival incision was reopened, exposed uveal tissue anterior to the medial rectus muscle insertion was discovered (Fig. 1). A diagnosis of necrotizing scleritis was made and was assumed to be the most likely cause of the patient's severe pain. The devitalized scleral tissue surrounding the scleral melt was removed, fibrotic tissue was debulked and cultured, and a split-thickness corneal graft was fashioned to fit the scleral defect. The graft used was glycerol-preserved, pre-cut, partial thickness corneal allograft tissue, consisting of corneal epithelium and stroma, prepared by VisionGraft. Since optical clarity was not required, a full-thickness graft

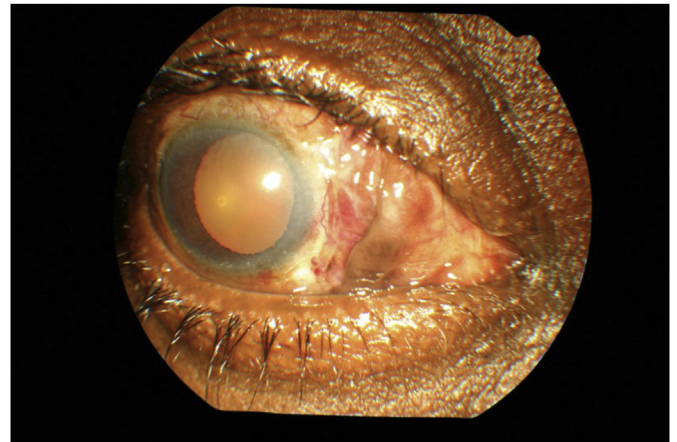


Fig. 3. External photograph of the right eye ten days after implantation of the tectonic corneal patch graft.



Fig. 4. External photograph of alignment and cosmesis eight months after implantation of the tectonic corneal patch graft.

with viable endothelium was unnecessary. The graft was secured to the area of scleral perforation with interrupted nonabsorbable sutures. The conjunctiva was draped over the corneal graft to prevent postoperative graft melt, and subconjunctival vancomycin was injected.

Cultures from the surgery showed no growth and the patient underwent a systemic work-up. Laboratory evaluation revealed a normal complete blood count, rapid plasma reagin, anti-neutrophil cytoplasmic antibody, serum lysozyme, angiotensin-converting enzyme, hepatitis C panel, sedimentation rate, antinuclear antibody, rheumatoid factor, and

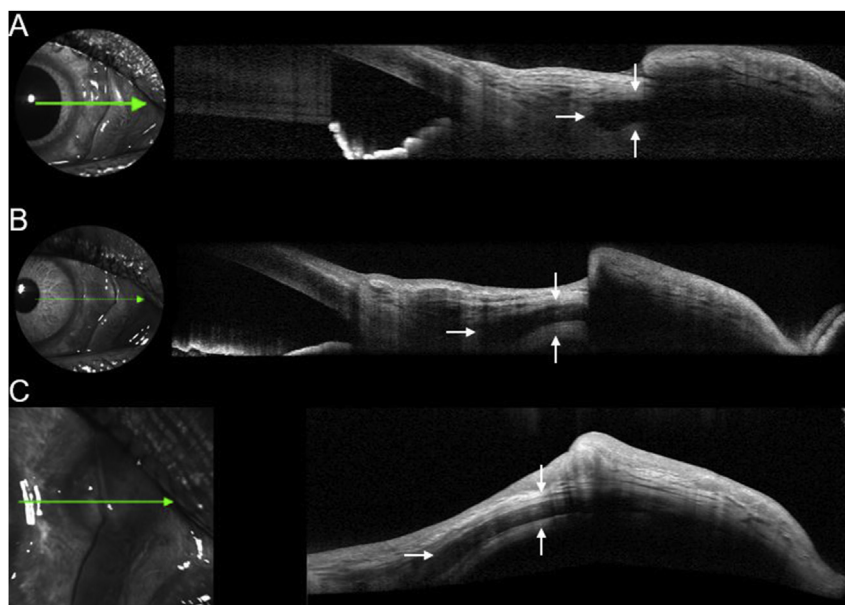


Fig. 2. Anterior segment optical coherence tomography demonstrating stable positioning of the graft at post-operative day ten (A), post-operative month one (B), and post-operative month eight (C). The white arrows indicate the margins of the graft.

**Table 1**  
Reported cases of SINS following strabismus surgery<sup>a</sup>.

Author, Year	Age at time of diagnosis (years)/sex	Infection	Systemic disease	Therapy	Time span between surgery and SINS
Mahmood et al., 2002	51/F	No	None identified	Systemic immunosuppressives	51 years
Lai et al., 2005	52/F				48 years
Kearney et al., 2007	1/F	Yes	None identified	Topical + systemic antibiotics alone	2 days
Tamhanker & Volpe, 2008	88/F	Yes	None identified	Systemic immunosuppressives	5 days
Streho et al., 2008	71/M	No	Thyroid disease	Antibiotic + immunosuppressives	14 days
Huang et al., 2013	58/F	No	Thyroid disease	Corneal graft, no systemic steroids	21 days
Christakopoulos et al., 2014	69/F	No	Granulomatosis with polyangiitis	Systemic immunosuppressives, visceration (NLP prior to surgery)	7 months
Akbari et al., 2016	28/F	No	None identified	Systemic immunosuppressives	30 days
Rajamani et al., 2017	9/M	No	Varadi Papp syndrome and congenital fibrosis of the extraocular muscles	Oral vitamin C and topical N-acetylcysteine 10%	30 days
Present case	61/M	Yes	Gout	Systemic immunosuppressives + corneal graft	10 days

<sup>a</sup> Results of literature review of articles published after the year 2000.

quantiFERON-TB Gold. The patient did have an increased uric acid level (7.8mg/dL, range 3.4–7.0), suggesting a diagnosis of gout. On further questioning, the patient admitted to a prior diagnosis of gout in the past but had discontinued his gout medications since he had been asymptomatic for several months.

Complete remission of the scleral inflammation was observed on systemic steroids and allopurinol over the following week. In addition to clinical improvement, the patient demonstrated radiographic improvement on anterior segment optical coherence tomography imaging (Fig. 2). Over the following eight months, the patient remained in good health with good alignment, stable vision, and no signs or symptoms of graft necrosis, graft dehiscence, nor endophthalmitis (Figs. 3 and 4).

### 3. Discussion

This is a rare case of infectious SINS treated with a tectonic corneal lamellar graft after strabismus surgery in a patient with gout. This case illustrates the difficulty in identifying a rare complication that masquerades as and may be triggered by an infection; the importance of evaluating for contributory systemic pathologies; and a novel technique for repair.

Little is known about the pathophysiology of SINS. In our particular patient, it is impossible to know with certainty whether the cause of the necrosis was infectious or autoimmune. Many believe SINS is a surgically-induced local granulomatous inflammatory process adjacent to the surgical wound that can be initiated by both infectious and non-infectious triggers. Several reports have hypothesized that infection can trigger the release of inflammatory mediators that eventually results in scleral necrosis.<sup>11–14</sup> Others have hypothesized that SINS can be precipitated by ischemia-exposed tissue antigens that sensitize the immune system, resulting in a delayed hypersensitivity response, and that this may lead to secondary infection.<sup>2,15</sup> Though there are several theories on the pathogenesis of SINS, all theories agree that SINS is an immune-mediated process that responds to immunosuppressive therapy.

While many patients with SINS are systemically healthy, a meticulous diagnostic workup of potentially fatal systemic diseases is necessary. According to Doshi et al.,<sup>1</sup> rheumatoid arthritis and granulomatosis with polyangiitis (formerly known as Wegener's granulomatosis) were the most commonly identified systemic diseases associated with SINS in general. Thyroid disease was the most commonly identified systemic disease associated with SINS after strabismus surgery.<sup>5,6,10</sup> SINS has been associated with gout in three cases in the literature, all of which were diagnosed after pterygium surgery.<sup>1</sup> The present case is the first case of SINS associated with gout after strabismus surgery.

The treatment of post-operative necrotizing scleritis almost always requires systemic immunosuppressive therapy and only sometimes

requires surgical intervention. When surgical intervention is necessary, preserved sclera is one of the most common materials used.<sup>16</sup> Ti and Tan<sup>3</sup> reported the use of lamellar keratoplasty in patients with scleral melting after pterygium excision. Scleral melting presented one month to 20 years following surgery, therapeutic and tectonic success was achieved in 19 of the 20 cases, six cases were associated with an infection, and the remaining 14 cases were non-infectious in etiology. Of note, one of these patients had gout and none of the organisms cultured were MRSA.

A literature review reveals that there have been only nine other reported cases of SINS following strabismus surgery since the year 2000. Seven of the nine patients were female, the age at diagnosis ranged from one to 71 years, and the latency period between surgery and diagnosis of SINS ranged from five days to 51 years (Table 1). Huang et al.<sup>5</sup> described the only other case of SINS following strabismus surgery that required a corneal graft; unlike our patient, their patient was female, had thyroid orbitopathy, and had no infection. Like our patient, their case had a favorable outcome with tectonic corneal grafting for SINS.

In our case, corneal tissue proved advantageous for several reasons. First, corneal tissue was readily available in the ambulatory surgical center setting. Second, as suggested by Ti and Tan, corneal tissue is thicker and has a higher rigidity than scleral tissue, possibly reducing the risk of re-melting and graft ectasia.<sup>3</sup> Third, cornea's more tightly packed lamellar construction likely allows it to be more resistant to infection.<sup>3</sup> The higher radius of curvature and transparent nature of cornea make it less cosmetically desirable than sclera initially; however, subsequent graft opacification over time causes resolution of the previously visible dark choroid.<sup>3</sup> Furthermore, corneal lamellar grafting, in conjunction with aggressive topical and systemic therapy was an effective and accessible measure to help treat progressive scleral necrosis while simultaneously preserving the structural integrity of the globe in our patient. The use of novel imaging modalities like anterior segment optical coherence tomography assisted in monitoring the continued health of the patient.

### 4. Conclusions

In summary, the diagnosis and management of SINS is challenging. In conjunction with aggressive local and systemic treatment, tectonic lamellar keratoplasty provides good therapeutic and tectonic results for scleral necrosis after strabismus surgery. This case also illustrates the importance of screening for associated systemic risk factors, distinguishing between infected and noninfected cases, and aggressively treating surgically-induced necrotizing scleritis medically and surgically.

### Patient consent

Consent to publish the case report was obtained. This report does not contain any personal information that could lead to the identification of the patient.

### Acknowledgements and disclosures

#### Funding

No funding or grant support.

#### Conflicts of interest

The author has no financial disclosures.

#### Authorship

All authors attest that they meet the current ICMJE criteria for Authorship.

### Acknowledgements

None.

### Appendix A. Supplementary data

Supplementary data related to this article can be found at <http://dx.doi.org/10.1016/j.ajoc.2018.04.025>.

### References

1. Doshi RR, Haroscopos GJ, Schwab IR, et al. The spectrum of postoperative scleral necrosis. *Surv Ophthalmol*. 2013;58:620–633.
2. O'Donoghue E, Lightman S, Tuft S, Watson P. Surgically induced necrotizing sclerokeratitis (SINS)- precipitating factors and response to treatment. *Br J Ophthalmol*. 1992;76:17–21.
3. Ti SE, Tan DT. Tectonic corneal lamellar grafting for severe scleral melting after pterygium surgery. *Ophthalmology*. 2003;110:1126–1136.
4. Gross SA, von Noorden GK, Jones DB. Necrotizing scleritis and transient myopia following strabismus surgery. *Ophthalmic Surg*. 1993;24:839–841.
5. Huang CY, Lin HC, Yang ML. Necrotizing scleritis after strabismus surgery in thyroid eye disease. *J AAPOS*. 2013 Oct;17(5):535–536.
6. Kaufman LM, Folk ER, Miller MT, et al. Necrotizing scleritis following strabismus surgery for thyroid ophthalmopathy. *J Pediatr Ophthalmol Strabismus*. 1989;26:236–238.
7. Kearney FM, Blaikie AJ, Gole GA. Anterior necrotizing scleritis after strabismus surgery in a child. *J AAPOS*. 2007;11:197–198.
8. Lai T, Leibovitch I, Zadeh R, et al. Surgically induced necrotizing scleritis occurring 48 years after strabismus surgery. *J Pediatr Ophthalmol Strabismus*. 2005;42:180–182.
9. Mahmood S, Suresh PS, Carley F, et al. Surgically induced necrotizing scleritis: report of a case presenting 51 years following strabismus surgery. *Eye*. 2002;16:503–504.
10. Strehlo M, Roussat B, Bouaziz T, et al. Bilateral necrotizing scleritis following strabismus surgery for thyroid ophthalmopathy. *J Pediatr Ophthalmol Strabismus*. 2008;45:43–46.
11. Tamhankar MA, Volpe NJ. Atypical necrotizing scleritis after strabismus surgery. *J AAPOS*. 2008;12:190–192.
12. Lyne AJ, Lloyd-Jones D. Necrotizing scleritis after ocular surgery. *Trans Ophthalmol Soc U K*. 1979 Apr;99(1):146–149.
13. Perez VL, Azar DT, Foster CS. Sterile corneal melting and necrotizing scleritis after cataract surgery in patients with rheumatoid arthritis and collagen vascular disease. *Semin Ophthalmol*. 2002 Sep-Dec;17(3-4):124–130.
14. Rich RM, Smiddy WE, Davis JL. Infectious scleritis after retinal surgery. *Am J Ophthalmol*. 2008 Apr;145(4):695–699.
15. Lin CP, Shih MH, Tsai MC. Clinical experiences of infectious scleral ulceration: a complication of pterygium operation. *Br J Ophthalmol*. 1997 Nov;81(11):980–983.
16. Nguyen QD, Foster CS. Scleral patch graft in the management of necrotizing scleritis. *Int Ophthalmol Clin*. 1999 Winter;39(1):109–131.