

Research Article

Prediction of Causative Genes in Inherited Retinal Disorders from Spectral-Domain Optical Coherence Tomography Utilizing Deep Learning Techniques

Yu Fujinami-Yokokawa ^{1,2}, Nikolas Pontikos ^{1,3,4}, Lizhu Yang,^{1,5,6} Kazushige Tsunoda,¹ Kazutoshi Yoshitake,⁷ Takeshi Iwata ⁷, Hiroaki Miyata,^{2,8} Kaoru Fujinami ^{1,3,4} and on behalf of Japan Eye Genetics Consortium^{1,7}

¹Laboratory of Visual Physiology, Division of Vision Research, National Institute of Sensory Organs, National Hospital Organization Tokyo Medical Center, Tokyo 152-8902, Japan

²Graduate School of Health Management, Keio University, Tokyo 160-0016, Japan

³UCL Institute of Ophthalmology, London EC1V 9EL, UK

⁴Moorfields Eye Hospital, London EC1V 2PD, UK

⁵Peking Union Medical College Hospital, Peking Union Medical College and Chinese Academy of Medical Sciences, Beijing 100006, China

⁶Department of Ophthalmology, Keio University of Medicine, Tokyo 160-0016, Japan

⁷Division of Molecular and Cellular Biology, National Institute of Sensory Organs, National Tokyo Medical Center, Tokyo 152-8902, Japan

⁸Department of Health Policy and Management, School of Medicine, Keio University, Tokyo 160-8582, Japan

Correspondence should be addressed to Kaoru Fujinami; k.fujinami@ucl.ac.uk

Received 3 December 2018; Accepted 11 March 2019; Published 9 April 2019

Academic Editor: Lawrence S. Morse

Copyright © 2019 Yu Fujinami-Yokokawa et al. This is an open access article distributed under the Creative Commons Attribution License, which permits unrestricted use, distribution, and reproduction in any medium, provided the original work is properly cited.

Purpose. To illustrate a data-driven deep learning approach to predicting the gene responsible for the inherited retinal disorder (IRD) in macular dystrophy caused by *ABCA4* and *RP1L1* gene aberration in comparison with retinitis pigmentosa caused by *EYS* gene aberration and normal subjects. **Methods.** Seventy-five subjects with IRD or no ocular diseases have been ascertained from the database of Japan Eye Genetics Consortium; 10 *ABCA4* retinopathy, 20 *RP1L1* retinopathy, 28 *EYS* retinopathy, and 17 normal patients/subjects. Horizontal/vertical cross-sectional scans of optical coherence tomography (SD-OCT) at the central fovea were cropped/adjusted to a resolution of 400 pixels/inch with a size of $750 \times 500 \text{ pix}^2$ for learning. Subjects were randomly split following a 3:1 ratio into training and test sets. The commercially available learning tool, Medic mind was applied to this four-class classification program. The classification accuracy, sensitivity, and specificity were calculated during the learning process. This process was repeated four times with random assignment to training and test sets to control for selection bias. For each training/testing process, the classification accuracy was calculated per gene category. **Results.** A total of 178 images from 75 subjects were included in this study. The mean training accuracy was 98.5%, ranging from 90.6 to 100.0. The mean overall test accuracy was 90.9% (82.0–97.6). The mean test accuracy per gene category was 100% for *ABCA4*, 78.0% for *RP1L1*, 89.8% for *EYS*, and 93.4% for Normal. Test accuracy of *RP1L1* and *EYS* was not high relative to the training accuracy which suggests overfitting. **Conclusion.** This study highlighted a novel application of deep neural networks in the prediction of the causative gene in IRD retinopathies from SD-OCT, with a high prediction accuracy. It is anticipated that deep neural networks will be integrated into general screening to support clinical/genetic diagnosis, as well as enrich the clinical education.

1. Introduction

Inherited retinal disorder (IRD) that has been lacking effective treatment is a leading cause of blindness in developed countries [1–5], affecting around 1 in 3000 people worldwide. The successful identification of the causative genes for retinal dystrophies with next generation sequencing technologies has increased the number of associated genes and disease-causing variants; to date, over 250 genes and 300 genes and loci have been identified (RetNet: <https://sph.uth.edu/retnet/sum-dis.htm>). Emerging treatment approaches, such as gene replacement therapy, pharmacological agents, regenerative therapies, retina prosthesis, and others, have increased the therapeutic potential for IRDs [6, 7].

Recently, large cohort studies have provided powerful information to determine clinical manifestations of IRD, such as fundus appearance and morphological findings, and characteristic morphological features caused by specific genes in macular dystrophy are well established [8–14]. For instance, typical cases with *ABCA4* retinopathy show disruption of photoreceptor layers with thinned sensory retina at the macula, and cases with *RP1L1* retinopathy demonstrate blurring of photoreceptor ellipsoid zone (EZ) and loss of photoreceptor interdigitation zone (IZ) [8, 11, 15–22].

On the contrary, it has been challenging to make a diagnosis at general ophthalmology clinics without IRD specialists since detailed and specific phenotypic assessment is unavailable because of the limited information due to the rarity of IRD. Recently, applications of artificial intelligence (AI) including deep neural network have been increasingly developed for screening/predicting several common retinal diseases from fundus images or spectral-domain optical coherence tomographic (SD-OCT) images [23–28]. However, such characterization/classification using automatic image analysis methods has not been developed in orphan retinal diseases.

The purpose of our study was to illustrate a data-driven deep learning approach to predict the causative genes of IRD in macular dystrophy caused by *ABCA4* and *RP1L1* in comparison with retinitis pigmentosa caused by *EYS* gene aberration and normal subjects.

2. Materials and Methods

The protocol of this study adhered to the tenets of the Declaration of Helsinki and was approved by the Ethics Committee of the participating institutions: National Institute of Sensory Organs (NISO), National Hospital Organization, and Tokyo Medical Center (Reference number: R15-037). A signed informed consent was obtained from all patients.

For the purpose of this study, two most prevalent genes for macular dystrophies and one most prevalent gene for retinitis pigmentosa were selected from the dataset of Japan Eye Genetics Consortium (JEGC): proportion of *ABCA4* retinopathy, *RP1L1* retinopathy, and *EYS* retinopathy were 5.5%, 8.5%, and 15.9%, respectively.

In total, 75 patients/subjects with molecularly confirmed IRD or no ocular diseases have been ascertained from the JEGC database [11]: 10 patients with *ABCA4* retinopathy, 20 patients with *RP1L1* retinopathy, 28 with *EYS* retinopathy, and 17 normal subjects. SD-OCT images are obtained with three OCT devices (Cirrus HD-OCT; Carl Zeiss Meditec, Dublin, CA, USA, Spectralis OCT; Heidelberg Engineering, Franklin, MA, USA; Swept Source OCT DRI OCT-1 Atlantis, Topcon Corporation, Tokyo, Japan).

Horizontal and vertical cross-sectional scans of SD-OCT at the central fovea of both eyes were cropped and adjusted to a spatial resolution of 400 pixels/inch with a size of 750 × 500 pix² for deep learning. Four gene categories were defined based on the clinical and genetic diagnosis; *ABCA4*, *RP1L1*, *EYS*, and Normal (Figure 1). After preparation of SD-OCT images for four gene categories, patients/subjects were randomly split following a 3:1 ratio into training and test sets.

The commercially available deep learning web tool, Medic Mind (<https://www.medicmind.tech/>), was applied to this four-class classification program [29]. The classification accuracy, sensitivity, and specificity were calculated during the learning process. The process was repeated four times with random assignment of subjects to training and test sets to control for selection bias, given the relatively small sample size. For each training/testing process, the classification accuracy was calculated per gene category.

3. Results and Discussion

A total of 178 images from 75 patients/subjects with IRD/Normal were included in this study. The detailed training and test results of deep learning performance in prediction of causative genes in IRD are presented in Table 1.

The mean training accuracy of the four repeated experiments was 96.9% and ranged from 90.6% to 100.0%. The mean sensitivity was 100% for *ABCA4*, 88.1 (66.7–100%) for *RP1L1*, 97.7 % (90.9–100%) % for *EYS*, and 100% for Normal. Sufficient training accuracy over 66.7% was obtained. The mean test accuracy of the four repeated experiments was 90.3%, ranging from 82.0% to 97.6%. The test accuracy per gene category was 100% for *ABCA4* and ranged from 66.7 to 87.5% for *RP1L1*, 82.4 to 100% for *EYS*, and 73.7 to 100% for Normal according to the four repeated experiments.

The test accuracy of *ABCA4* and Normal was considerably higher than that of *RP1L1* and *EYS*, which suggests overfitting. Four (10.5%) out of 38 with an original diagnosis of *RP1L1* were classified as *EYS*, two (5.3%) with *RP1L1* were classified as Normal, and one (2.6%) with original *RP1L1* was classified as *ABCA4* (Figure 2). Two (3.6%) out of 56 with an original diagnosis of *EYS* were classified as *ABCA4*, two (3.6%) with original *EYS* were classified as *RP1L1*, and two (3.6%) with *EYS* were classified as Normal.

The potential efficacy of the automatic screening/diagnostic system of IRD from SD-OCT has been illustrated. To the best of our knowledge, this is the first report of utilizing deep learning technology in retinal orphan disorders.

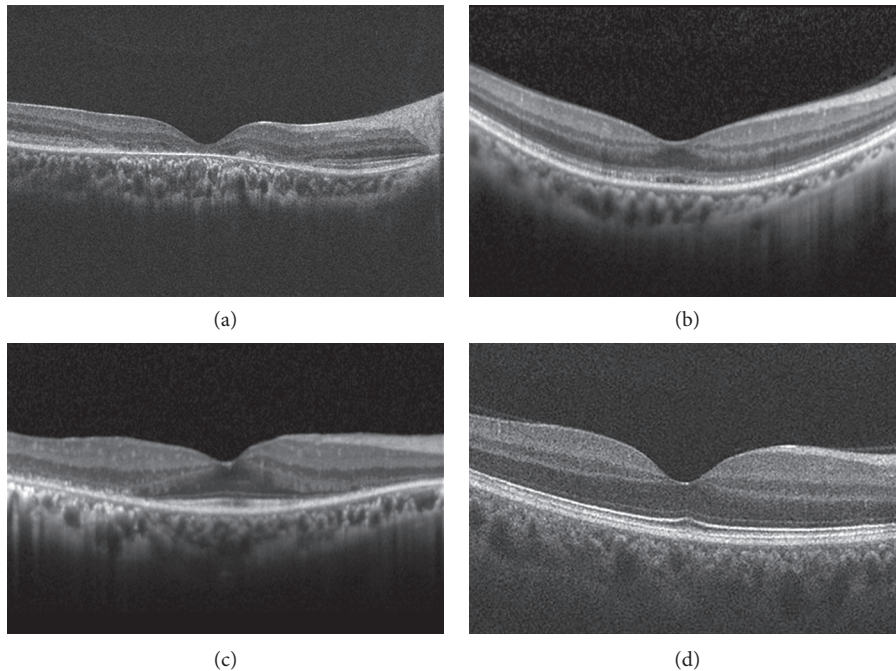


FIGURE 1: Spectral-domain optical coherence tomographic (SD-OCT) images of four categories in prediction of causative genes in inherited retinal disorders. For the purpose of this study, two most prevalent genes (*ABCA4*, *RP1L1*) for macular dystrophies and one most prevalent gene (*EYS*) for retinitis pigmentosa were selected from the dataset of Japan Eye Genetics Consortium. Characteristic morphological features are demonstrated in each spectral-domain optical coherence tomographic (SD-OCT) image. *ABCA4*: disruption of photoreceptor layers with thinned sensory retina at the macula. *RP1L1*: blurring of photoreceptor ellipsoid zone and loss of photoreceptor interdigitation zone at the macula. *EYS*: disruption of photoreceptor layers with thinned sensory retina at the paramacular with relatively preserved structure at the macula. Normal: normal retinal structures.

Since IRD exhibits strong gene-characteristic morphological features which are less influenced by environmental factors, these present an ideal application of AI to assist medical diagnosis. Furthermore, in general, deducing IRD is not hard at general ophthalmology clinics, as the family history, specific chief complaints, and symmetric findings are unique; complex diagnosis, therefore, with such demographic information and AI-guided assessment for SD-OCT could assist properly identifying patients with IRD.

Application of AI in common diseases such as diabetic retinopathy and age-related macular degeneration manifests huge impacts/effects on improvement of medical care and saving the cost. This study further supports the extended utility of AI in relatively common IRD (covering 30% of total IRD), which has a huge impact not only on ocular diseases but also on other orphan disorders.

Interestingly, the predicted classification of *ABCA4* and classification of Normal were highly accurate in this study, while there were still some difficulties in classifying *RP1L1* and *EYS* retinopathies. This may be because the characteristic features of *RP1L1* retinopathy with blurring of EZ and loss of IZ are hard to be detected from image analysis, and the disrupted zone of some *EYS* retinopathy might lie outside of the observed field in SD-OCT images.

There are several limitations in this study. The cohort size of this study was relatively small both in control and affected groups, and target ethnicity was only Japanese, in which larger cohort studies with data from various ethnicities could

expand the potential utility of our approach. In our study, comparison analysis of the variation in diagnoses by human and AI prediction was not performed due to the limited data resources, which could delineate the usefulness and weakness of our approach. There are limitations to AI classifiers which are trained to only distinguish between a finite number of predefined classes for which we have sufficient training data. However, as we know, there are over 300 genes that can cause IRD; therefore, the four-class classifier we have developed here cannot be usefully applied in practice to predict a gene from an SD-OCT of a patient with a novel gene diagnosis. It would however be expected that our algorithm would return probabilities close to 25% (1/4) if presented with an SD-OCT which does not fit any of the four classes. Instead, another more clinically applicable approach may be to train several one-or-rest classifiers to distinguish one gene from all others. These could then be applied successively to an SD-OCT to assess which gene diagnosis is the best fitting. However, this would require training several classifiers and would require a sufficient number of cases for each gene classifier, which might not be possible for the rarer IRDs. There is also a current interpretability limitation to AI classifiers which use deep learning. This field remains an active research area, and we intend to explore approaches such as saliency and occlusion maps to highlight what parts of an SD-OCT are important to the classification decision.

Our approach could be extended to other retinopathy-associated genes/loci, of which they are over 300. The

TABLE 1: Summary of deep learning performance in prediction of causative genes in inherited retinal disorders.

Experiment 1.	Training results				Test 1.	Test results				Total number of images included in this study							
	Number of images	Sensitivity (%)	Specificity (%)	Accuracy (%)		Original category	RP1L1	EYS	Normal		Total						
Original classification of genetic diagnosis	ABCA4	15	100	100	—	ABCA4	4	1	—	5	100	ABCA4	19				
	RP1L1	29	85.7	100	—	RP1L1	—	7	—	7	87.5	RP1L1	37				
	EYS	43	100	95	—	Predicted category of genetic diagnosis	—	—	14	—	100	EYS	57				
	Normal	49	100	100	—	genetic diagnosis	—	—	—	16	100	Normal	65				
	Total	136	—	—	96.9	Total	4	8	14	16	42	Total	178				
Training results																	
Experiment 2.	Number of images	Sensitivity (%)	Specificity (%)	Accuracy (%)	Test 2.	Original category	RP1L1	EYS	Normal	Total	Accuracy (%)	Total number of images included in this study					
	ABCA4	13	100	100		—	ABCA4	6	2	1			—	9	100	ABCA4	19
	RP1L1	26	100	100		—	RP1L1	—	9	1			2	12	82	RP1L1	37
	EYS	43	100	100		—	Predicted category of genetic diagnosis	—	—	12			3	15	85.7	EYS	57
	Normal	46	100	100		—	genetic diagnosis	—	—	—			14	14	73.7	Normal	65
Total	128	—	—	100	Total	6	11	14	19	50	82	Total	178				
Training results																	
Experiment 3.	Number of images	Sensitivity (%)	Specificity (%)	Accuracy (%)	Test 3.	Original category	RP1L1	EYS	Normal	Total	Accuracy (%)	Total number of images included in this study					
	ABCA4	15	100	96.6		—	ABCA4	4	—	1			—	5	100	ABCA4	19
	RP1L1	31	66.7	100		—	RP1L1	—	4	—			—	4	66.7	RP1L1	37
	EYS	45	90.9	90.5		—	Predicted category of genetic diagnosis	—	2	10			—	12	90.9	EYS	57
	Normal	49	100	100		—	genetic diagnosis	—	—	—			16	16	100	Normal	65
Total	140	—	—	90.6	Total	4	6	11	16	37	91.9	Total	178				
Training results																	
Experiment 4.	Number of images	Sensitivity (%)	Specificity (%)	Accuracy (%)	Test 4.	Original category	RP1L1	EYS	Normal	Total	Accuracy (%)	Total number of images included in this study					
	ABCA4	14	100	100		—	ABCA4	5	—	—			—	5	100	ABCA4	19
	RP1L1	25	100	100		—	RP1L1	—	10	1			—	11	76.9	RP1L1	37
	EYS	40	100	100		—	Predicted category of genetic diagnosis	—	—	14			—	14	82.4	EYS	57
	Normal	51	100	100		—	genetic diagnosis	—	2	2			14	18	100	Normal	65
Total	130	—	—	100	Total	5	13	17	14	49	89.8	Total	178				

In total, 75 subjects with molecularly confirmed inherited retinal disorders or no ocular diseases have been ascertained: 10 with *ABCA4* retinopathy, 20 patients with *RP1L1* retinopathy, 28 with *EYS* retinopathy, and 17 normal subjects. After preparation of spectral-domain optical coherence tomographic (SD-OCT) images for four gene categories, subjects were randomly split following a 3 : 1 ratio into training and test sets. The commercially available deep learning web tool, Medic Mind, was applied to this four-class classification problem. The classification accuracy, sensitivity, and specificity were calculated during the learning process, and the process was repeated four times with randomly assigned training/test sets to control for selection bias. For each training/testing process, the classification accuracy was calculated per gene category.

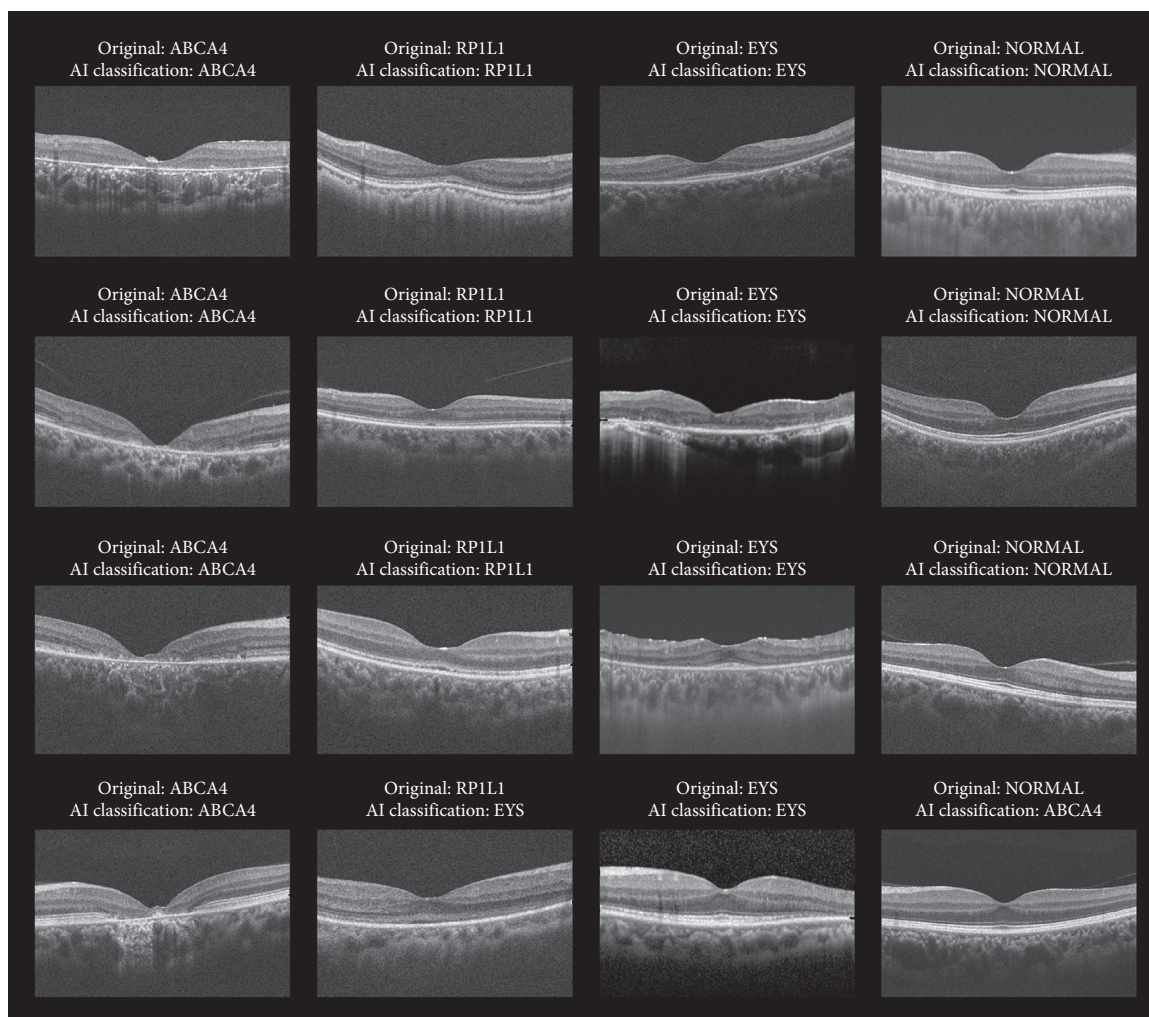


FIGURE 2: Test results of deep learning in 4 representative cases with original diagnosis of ABCA4, RP1L1, EYS, and Normal. A data-driven deep learning approach to predicting the gene causing the inherited retinal disorders in macular dystrophy caused by ABCA4 and RP1L1 in comparison with retinitis pigmentosa caused by EYS and normal subjects was performed with Medic Mind (URL: <https://www.medicmind.tech/>). The mean overall test accuracy was 90.9% (82.0–97.6). The test accuracy per gene category was 100% for ABCA4, 78.0% (66.7–87.5) for RP1L1, 89.8% (82.4–100) for EYS, and 93.4% (73.7–100) for Normal. AI = artificial intelligence.

challenge lies in obtaining sufficiently large training datasets for the rarest forms of IRD and in distinguishing similar morphological changes within the same mechanism group/cascade (e.g., generalized rod dysfunction, generalized cone dysfunction, and confined macular dysfunction). Further comprehensive studies in larger cohorts, in combination with other phenotypic modalities such as fundus appearance, fluorescein angiography, visual fields, and electrophysiological findings, and imaging performed at different time points in the progression of disease should improve the performance of these prediction algorithms.

4. Conclusions

This study highlighted a novel application of deep neural networks in the prediction of the major causative genes (30%) in IRD retinopathies from SD-OCT, with a mean prediction accuracy of 90%. It is anticipated that deep neural networks will be integrated into general screening to support

clinical diagnosis, suggest a causative gene to guide genetic screening, as well as enrich clinical education of orphan retinal disease.

Data Availability

Raw data were generated in the Japan Eye Genetics Consortium database and obtained with permission of the Japan Eye Genetics Consortium at <https://niso.kankakuki.go.jp/opkarte/>. Derived data supporting the findings of this study are available from the corresponding author on request.

Disclosure

Yu Fujinami-Yokokawa and Nikolas Pontikos are the co-first authors. The funding sources had no role in the design and conduct of the study; collection, management, analysis, and interpretation of the data; preparation, review, or

approval of the manuscript; and decision to submit the manuscript for publication.

Conflicts of Interest

All authors have completed and submitted the ICMJE Form for Disclosure of Potential Conflicts of Interest. Individual investigators who participated in the sponsored project(s) are not directly compensated by the sponsor but may receive salary or other support from the institution to support their effort on the project(s). Kaoru Fujinami is a paid consultant of Astellas Pharma Inc, Kubota Pharmaceutical Holdings Co., Ltd, Acucela Inc., and Novartis AG. Kaoru Fujinami reports personal fees from Astellas Pharma Inc, Kubota Pharmaceutical Holdings Co., Ltd., Acucela Inc., SANTEN Company Limited, Foundation Fighting Blindness, Foundation Fighting Blindness Clinical Research Institute, Japanese Ophthalmology Society, and Japan Retinitis Pigmentosa Society. Laboratory of Visual Physiology, Division for Vision Research, National Institute of Sensory Organs, National Hospital Organization, Tokyo Medical Center, Tokyo, is supported by grants from Astellas Pharma Inc (NCT03281005), outside the submitted work.

Authors' Contributions

Yu Fujinami-Yokokawa and Nikolas Pontikos contributed equally to this work.

Acknowledgments

Yu Fujinami-Yokokawa was supported by grants from Grant-in-Aid for Young Scientists of the Ministry of Education, Culture, Sports, Science and Technology, Japan (18K16943). Nikolas Pontikos was funded by the NIHR Moorfields Biomedical Research Center. Kaoru Fujinami was supported by grants from Grant-in-Aid for Young Scientists (A) of the Ministry of Education, Culture, Sports, Science and Technology, Japan (16H06269), Grant-in-Aid for Scientists to support international collaborative studies of the Ministry of Education, Culture, Sports, Science and Technology, Japan (16KK01930002), National Hospital Organization Network Research Fund (H30-NHO-2-12), Foundation Fighting Blindness ALAN LATIES CAREER DEVELOPMENT PROGRAM (CF-CL-0416-0696-UCL), Health Labour Sciences Research Grant, the Ministry of Health Labour and Welfare. (201711107A), and Great Britain Sasakawa Foundation Butterfield Awards. We are grateful to Dr. Xiao Liu and Dr. Gavin Arno, National Institute of Sensory Organs, National Tokyo Medical Center, Japan, for their help in clinical and genetic data analysis. We thank Professor Andrew Webster and Professor Michel Michaelides, UCL Institute of Ophthalmology associated with Moorfields Eye Hospital, UK, and Professor Yozo Miyake, Aichi Medical University, Japan, for insightful comments. We also thank all the collaborators of the Japan Eye Genetics Consortium (<http://www.jegc.org/>) and the East Asia Inherited Retinal Disease Society (<https://www.fujinamik.com/east-asia-inherited-retinal-disease>) for data

collection. We thank Medic Mind for supporting the analytic process of this study.

References

- [1] N. Kumaran, M. E. Pennesi, P. Yang et al., "Leber congenital amaurosis/early-onset severe retinal dystrophy overview," in *GeneReviews*(R), M. P. Adam et al., Ed., Seattle, WA, USA, 2018.
- [2] N. Kumaran, A. T. Moore, R. G. Weleber, and M. Michaelides, "Leber congenital amaurosis/early-onset severe retinal dystrophy: clinical features, molecular genetics and therapeutic interventions," *British Journal of Ophthalmology*, vol. 101, no. 9, pp. 1147–1154, 2017.
- [3] N. Hirji, J. Aboshiha, M. Georgiou, J. Bainbridge, and M. Michaelides, "Achromatopsia: clinical features, molecular genetics, animal models and therapeutic options," *Ophthalmic Genetics*, vol. 39, no. 2, pp. 149–157, 2018.
- [4] L. Sheck, W. I. L. Davies, P. Moradi et al., "Leber congenital amaurosis associated with mutations in CEP290, clinical phenotype, and natural history in preparation for trials of novel therapies," *Ophthalmology*, vol. 125, no. 6, pp. 894–903, 2018.
- [5] J. J. L. Tee, A. J. Smith, A. J. Hardcastle, and M. Michaelides, "RPGR-associated retinopathy: clinical features, molecular genetics, animal models and therapeutic options," *British Journal of Ophthalmology*, vol. 100, no. 8, pp. 1022–1027, 2016.
- [6] J. Smith, D. Ward, M. Michaelides, A. T. Moore, and S. Simpson, "New and emerging technologies for the treatment of inherited retinal diseases: a horizon scanning review," *Eye*, vol. 29, no. 9, pp. 1131–1140, 2015.
- [7] H. P. N. Scholl, R. W. Strauss, M. S. Singh et al., "Emerging therapies for inherited retinal degeneration," *Science Translational Medicine*, vol. 8, no. 368, p. 368rv6, 2016.
- [8] K. Fujinami, K. Tsunoda, G. Hanazono et al., "Fundus autofluorescence in autosomal dominant occult macular dystrophy," *Archives of Ophthalmology*, vol. 129, no. 5, pp. 597–602, 2011.
- [9] K. Fujinami, N. Lois, A. E. Davidson et al., "A longitudinal study of stargardt disease: clinical and electrophysiologic assessment, progression, and genotype correlations," *American Journal of Ophthalmology*, vol. 155, no. 6, pp. 1075–1088, 2013.
- [10] K. Fujinami, J. Zernant, R. K. Chana et al., "Clinical and molecular characteristics of childhood-onset Stargardt disease," *Ophthalmology*, vol. 122, no. 2, pp. 326–334, 2015.
- [11] K. Fujinami, S. Kameya, S. Kikuchi et al., "Novel-RP1L1 Variants and genotype-photoreceptor microstructural phenotype Associations in cohort of Japanese patients with occult macular dystrophy," *Investigative Ophthalmology and Visual Science*, vol. 57, no. 11, pp. 4837–46, 2016.
- [12] K. Fujinami, N. Lois, R. Mukherjee et al., "A longitudinal study of Stargardt disease: quantitative assessment of fundus autofluorescence, progression, and genotype correlations," *Investigative Ophthalmology and Visual Science*, vol. 54, no. 13, pp. 8181–90, 2013.
- [13] X. Kong, R. W. Strauss, M. Michaelides et al., "Visual acuity loss and associated risk factors in the retrospective progression of stargardt disease study (ProgStar report No. 2)," *Ophthalmology*, vol. 123, no. 9, pp. 1887–97, 2016.
- [14] R. W. Strauss, A. Ho, B. Muñoz et al., "The natural history of the progression of atrophy secondary to stargardt disease (ProgStar) studies," *Ophthalmology*, vol. 123, no. 4, pp. 817–828, 2016.

- [15] K. Fujinami, P. I. Sergouniotis, A. E. Davidson et al., "The clinical effect of homozygous ABCA4 alleles in 18 patients," *Ophthalmology*, vol. 120, no. 11, pp. 2324–2331, 2013.
- [16] K. Fujinami, P. I. Sergouniotis, A. E. Davidson et al., "Clinical and molecular analysis of Stargardt disease with preserved foveal structure and function," *American Journal of Ophthalmology*, vol. 156, no. 3, pp. 487–501, 2013.
- [17] D. Zobor, G. Zobor, S. Hipp et al., "Phenotype variations caused by mutations in the RP1L1 gene in a large mainly German cohort," *Investigative Ophthalmology and Visual Science*, vol. 59, no. 7, pp. 3041–3052, 2018.
- [18] S. Kikuchi, S. Kameya, K. Gocho et al., "Cone dystrophy in patient with homozygous RP1L1 mutation," *BioMed Research International*, vol. 2015, p. 545243, 2015.
- [19] A. E. Davidson, P. I. Sergouniotis, D. S. Mackay et al., "RP1L1 Variants are associated with a spectrum of inherited retinal diseases including retinitis pigmentosa and occult macular dystrophy," *Human Mutation*, vol. 34, no. 3, pp. 506–514, 2013.
- [20] S. J. Ahn, J. Ahn, K. H. Park, and S. J. Woo, "Multimodal imaging of occult macular dystrophy," *JAMA Ophthalmology*, vol. 131, no. 7, pp. 880–90, 2013.
- [21] S. J. Ahn, S. I. Cho, J. Ahn, S. S. Park, K. H. Park, and S. J. Woo, "Clinical and genetic characteristics of Korean occult macular dystrophy patients," *Investigative Ophthalmology & Visual Science*, vol. 54, no. 7, pp. 4856–63, 2013.
- [22] S. J. Park, S. J. Woo, K. H. Park, J.-M. Hwang, and H. Chung, "Morphologic photoreceptor abnormality in occult macular dystrophy on spectral-domain optical coherence tomography," *Investigative Ophthalmology and Visual Science*, vol. 51, no. 7, pp. 3673–9, 2010.
- [23] J. De Fauw, J. R. Ledsam, B. Romera-Paredes et al., "Clinically applicable deep learning for diagnosis and referral in retinal disease," *Nature Medicine*, vol. 24, no. 9, pp. 1342–1350, 2018.
- [24] N. Ramachandran, S. C. Hong, M. J. Sime, and G. A. Wilson, "Diabetic retinopathy screening using deep neural network," *Clinical & Experimental Ophthalmology*, vol. 46, no. 4, pp. 412–416, 2018.
- [25] U. Schmidt-Erfurth, A. Sadeghipour, B. S. Gerendas et al., "Artificial intelligence in retina," *Progress in Retinal and Eye Research*, vol. 67, pp. 1–29, 2018.
- [26] D. S. W. Ting, L. R. Pasquale, L. Peng et al., "Artificial intelligence and deep learning in ophthalmology," *British Journal of Ophthalmology*, vol. 103, no. 2, pp. 167–175, 2019.
- [27] T. K. Redd, J. P. Campbell, J. M. Brown et al., "Evaluation of a deep learning image assessment system for detecting severe retinopathy of prematurity," *British Journal of Ophthalmology*, 2018.
- [28] M. Treder, J. L. Laueremann, and N. Eter, "Deep learning-based detection and classification of geographic atrophy using a deep convolutional neural network classifier," *Graefes' Archive for Clinical and Experimental Ophthalmology*, vol. 256, no. 11, pp. 2053–2060, 2018.
- [29] C. H. Stevenson, S. C. Hong, and K. C. Ogbuehi, "Development of an artificial intelligence system to classify pathology and clinical features on retinal fundus images," *Clinical and Experimental Ophthalmology*, 2018.