

Coronary plaque morphology on multi-modality imaging and periprocedural myocardial infarction after percutaneous coronary intervention☆



Akira Sato*, Kazutaka Aonuma

Cardiovascular Division, Faculty of Medicine, University of Tsukuba, Japan

ARTICLE INFO

Article history:

Received 1 November 2015

Accepted 4 March 2016

Available online 17 March 2016

Keywords:

Coronary imaging

Percutaneous coronary intervention

Periprocedural myocardial infarction

Vulnerable plaque

ABSTRACT

Percutaneous coronary intervention (PCI) may be complicated by periprocedural myocardial infarction (PMI) as manifested by elevated cardiac biomarkers such as creatine kinase (CK)-MB or troponin T. The occurrence of PMI has been shown to be associated with worse short- and long-term clinical outcome. However, recent studies suggest that PMI defined by biomarker levels alone is a marker of atherosclerosis burden and procedural complexity but in most cases does not have independent prognostic significance. Diagnostic multi-modality imaging such as intravascular ultrasound, optical coherence tomography, coronary angiography, near-infrared spectroscopy, multidetector computed tomography, and magnetic resonance imaging can be used to closely investigate the atherosclerotic lesion in order to detect morphological markers of unstable and vulnerable plaques in the patients undergoing PCI. With the improvement of technical aspects of multimodality coronary imaging, clinical practice and research are increasingly shifting toward defining the clinical implication of plaque morphology and patients' outcomes. There were numerous published data regarding the relationship between pre-PCI lesion subsets on multi-modality imaging and post-PCI biomarker levels. In this review, we discuss the relationship between coronary plaque morphology estimated by invasive or noninvasive coronary imaging and the occurrence of PMI. Furthermore, this review underlies that the value of the multimodality coronary imaging approach will become the gold standard for invasive or noninvasive prediction of PMI in clinical practice.

© 2016 The Authors. Published by Elsevier Ireland Ltd. This is an open access article under the CC BY-NC-ND license (<http://creativecommons.org/licenses/by-nc-nd/4.0/>).

1. Introduction

Invasive coronary angiography (ICA) has been used as the gold standard for the diagnosis of coronary narrowing and clinical decision making for coronary interventions. However, coronary angiography has several limitations, including the substantial interpretation variability of visual estimates and assessment of lesion severity for diffuse atherosclerotic lesions and intermediate-severity lesions [1,2]. Percutaneous coronary intervention (PCI) has been one of the standard revascularization procedures for patients with significant coronary artery disease. PCI may be complicated by periprocedural myocardial infarction (PMI) as manifested by elevated cardiac biomarkers such as creatine kinase (CK)-MB or troponin T. The occurrence of PMI has been shown to be associated with worse short- and long-term clinical outcome [3–5]. However, recent studies suggest that PMI defined by biomarker levels alone is a marker of atherosclerosis burden and procedural complexity but in most cases does not have independent prognostic significance

[6–8]. With the improvement of technical aspects of multimodality coronary imaging, clinical practice and research are increasingly shifting toward defining the clinical implication of plaque morphology and patients' outcomes. In this review, we discuss the relationship between coronary plaque morphology estimated by invasive or noninvasive coronary imaging and the occurrence of PMI.

2. Periprocedural myocardial infarction after PCI

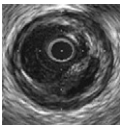
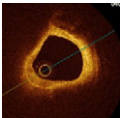


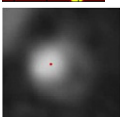
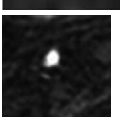
Cardiac troponin I (cTnI) and cTnT are the biomarkers of choice for the diagnosis of myocardial damage, because they are the most sensitive and cardiac-specific biomarkers currently available. The recently published third universal definition of MI attempts to provide some guidance by defining PMI in patients with normal (<99th percentile upper reference limit (URL)) baseline cTn concentrations as an elevation of $>5 \times$ URL within 48 h of the procedure together with either (i) evidence of prolonged (>20 min) ischaemia as demonstrated by chest pain; (ii) ischaemic ST changes or new pathological Q waves; (iii) angiographic evidence of a flow-limiting complication, such as loss of patency of a side branch, persistent slow-flow or no-reflow, embolization; or (iv) imaging evidence of new loss of viable myocardium or new regional wall motion abnormality [9]. Porto et al. found that the cause of periprocedural

☆ Grant support: None.

* Corresponding author at: Cardiovascular Division, Faculty of Medicine, University of Tsukuba, 1-1-1 Tennodai, Tsukuba, Ibaraki, Japan.

E-mail address: asato@md.tsukuba.ac.jp (A. Sato).

Table 1
Characteristics of various imaging modalities for analysis of coronary plaque for the detection of PMI.

Modalities	Images	Characteristics of plaque
IVUS		Grayscale: plaque burden, ruptured plaque, attenuated plaque VH: necrotic core area or volume IB: lipid volume iMAP: necrotic tissue volume
OCT		Ruptured plaque TCFA (large lipid core and a thin fibrous cap)
Coronary angiography		Intensive yellow plaque Ruptured plaque
NIRS		Lipid-core plaque (LCP) with a maxLCBI (4 mm) ≥ 500
MDCT		Low-attenuation, positive remodeling, spotty calcification Ring-like appearance
MRI		High-intensity plaque detected in non-contrast T1WI

PMI = periprocedural myocardial infarction, IVUS = intravascular ultrasound, VH = virtual histology, IB = integrated backscatter, OCT = optical coherence tomography, TCFA = thin-cap fibroatheroma, CAS = coronary angiography, NIRS = near-infrared spectroscopy, LCBI = lipid core burden index, MDCT = multi-detector computed tomography, MRI = magnetic resonance imaging.

myocardial necrosis after PCI was the impairment of flow in coronary side branches and distal embolization of atheromatous or thrombotic materials [10]. Park et al. have demonstrated that the side-branch occlusion was the most common cause (57.3%) for the mechanism of PMI, and other reasons included slow- or no-reflow, flow-limiting dissection, and distal embolization [11]. The slow-flow, no re-flow phenomenon, or PMI after PCI has been associated with distal embolization, especially of plaque debris, and with unfavorable clinical outcomes [12,13]. Therefore, pre-PCI plaque composition on coronary imaging may have an impact on myocardial infarction during PCI (Table 1).

Table 2
Coronary plaque characteristics on IVUS for prediction of PMI.

Author	Number of patients	Events rate (%)	Imaging result	Odds ratio (95% CI)
Mehran et al. [14]	2256	CK-MB $\geq 1 \times$ ULN (25.7%)	Plaque burden	1.14 (1.07–1.82)
Fujii et al. [15]	62	CK-MB $> 3 \times$ ULN (15%)	Ruptured plaque	$P = 0.03$
Kawamoto et al. [16]	44	HITS with Doppler guidewire > 12 (29.5%)	Necrotic core area (VH, mm ²)	4.41 (1.03–18.81)
Hong et al. [17]	80	TnT $> 3 \times$ ULN (47.5%)	Necrotic core area (VH, mm ²)	1.318 (1.090–1.594)
Uetani et al. [18]	114	TnT $> 3 \times$ ULN (11.4%)	Lipid volume (IB, mm ³)	0.011 (0.004–0.016)
Higuchi et al. [19]	33	TnT $> 5 \times$ ULN (36.3%)	Necrotic tissue volume (iMAP, mm ³)	1.026 (1.004–1.048)
Utunomiya et al. [20]	95	Slow flow (11.6%)	Necrotic plaque volume (iMAP, mm ³)	n/a

PMI = periprocedural myocardial infarction, CI = confidence interval, IVUS = intravascular ultrasound, CK-MB = creatine kinase, ULN = upper limit of normal, TnT = troponin T, VH = virtual histology, IB = integrated backscatter.

3. Invasive imaging for prediction of PMI

Diagnostic multi-modality imaging can be used to closely investigate the atherosclerotic lesion in order to detect morphological markers of unstable and vulnerable plaques in the patients undergoing invasive coronary angiography and PCI. There were numerous published data regarding the relationship between pre-PCI lesion subsets on multi-modality imaging and post-PCI biomarker levels.

3.1. Intravascular ultrasound (IVUS) (Table 2)

IVUS is widely used to assess coronary artery morphometry. Virtual histology (HV) IVUS, integrated backscatter (IB) IVUS, and iMAP IVUS are available radio frequency analysis in clinical practice. Mehran et al. [14] studied 2256 consecutive patients who underwent PCI of 2780 native coronary lesions and had pre-PCI IVUS imaging; both a greater lesion and reference segment plaque burden were associated with post-PCI creatine kinase-MB elevation. Fujii et al. [15] compared creatine kinase-MB release after stent implantation in 62 patients with IVUS-detected ruptured plaques with 62 matched control patients; patients with ruptured plaques had higher creatine kinase-MB release rates than control patients, and independent predictors of post-PCI creatine kinase-MB elevation were presence of ruptured plaque and unstable angina. Grayscale IVUS has significant limitations in assessing plaque composition, and radiofrequency-derived histopathological analysis by IVUS may provide quantitative information on plaque composition. VH-IVUS has demonstrated that large necrotic cores are related to distal embolization and post-PCI cTn elevation [16,17]. The VH-IVUS may play an important role in detecting which lesions are high risks for myocardial necrosis after PCI. Uetani et al. [18] investigated 114 consecutive patients who received elective stent implantations following IB-IVUS analysis regarding the association between quantitative analysis of the plaques of target lesions and the risk of post-procedural myocardial injury after stenting. Lipid and fibrous volumes correlated with post-procedural cardiac biomarkers, and the lipid volume fraction (lipid volume/total plaque volume) also correlated with post-procedural TnT and CK-MB. Lipid volume and volume fraction were concluded to be independent predictors of post-procedural myocardial injury. The innovative radiofrequency-based analysis of tissue characterization by IVUS (iMAP-IVUS) analyses also demonstrated that necrotic tissue volume is a potent predictor of PMI [19]. In a study of 95 consecutive patients with stable angina or ACS patients with slow flow after PCI had significantly higher absolute necrotic plaque volumes (43.3 mm³ versus 20.1 mm³; $P = 0.0004$), as detected by iMAP IVUS [20].

Table 3
Coronary plaque characteristics on OCT for prediction of PMI.

Author	Number of patients	Events rate (%)	Imaging result	Odds ratio (95% CI)
Yonetsu et al. [22]	125	CK-MB $\geq 1 \times$ ULN (28%)	TCFA	4.68 (1.88–11.64)
Lee et al. [23]	135	CK-MB $\geq 1 \times$ ULN (26.7%)	Ruptured plaque	2.92 (1.21–7.06)
Lee et al. [24]	131	Tnl $> 3 \times$ ULN (23.7%)	TCFA ($< 70 \mu\text{m}$)	10.47 (3.74–29.28)
Lee et al. [25]	206	Tnl $> 5 \times$ ULN (41%)	TCFA ($< 70 \mu\text{m}$)	2.89 (1.22–6.86)
Kini et al. [33]	110	Tnl $> 3 \times$ ULN (9%)	TCFA	0.896 (0.799–0.962)
		Tnl $> 5 \times$ ULN (7.3%)		0.907 (0.809–0.975)

PMI = periprocedural myocardial infarction, CI = confidence interval, IVUS = intravascular ultrasound, CK-MB = creatine kinase, ULN = upper limit of normal, Tnl = troponin I, TCFA = thin-cap fibroatheroma.

3.2. Optical coherence tomography (OCT) (Table 3)

OCT is a high-resolution method for imaging plaque characteristics (approximately 10- μm resolution) and can be used to determine fibrous cap thickness and the presence of TCFA [21]. Yonetsu et al. [22] demonstrated that the presence of OCT-derived TCFA (OR 4.68, 95% CI 1.88–11.64, $P = 0.001$) were independent predictors of post-PCI CK-MB elevation. Lee et al. [23] demonstrated that IVUS-derived echo attenuation (EA) (odds ratio [OR]: 3.49; 95% confidence interval [CI]: 1.53 to 7.93; $P = 0.003$) and OCT-derived ruptured plaque (OR: 2.92; 95% CI: 1.21 to 7.06; $P = 0.017$) were independent predictors of post-PCI CK-MB elevation. Atherosclerotic plaques with EA were associated with characteristics considered to be high risk or unstable. OCT examination showed an additive predictive value to the presence of EA for post-PCI CK-MB elevation. They also demonstrated that post-PCI MI (hazard ratio, 3.67; 95% confidence interval, 1.39 to 9.65; $P = 0.009$) and ejection fraction (hazard ratio, 0.96; 95% confidence interval, 0.92 to 0.99; $P = 0.029$) were independent predictors of adverse cardiovascular events during follow-up, and the presence of OCT-defined thin-cap fibroatheroma can predict post-PCI MI in patients treated with elective stent implantation, who may require adjunctive therapy after otherwise successful PCI [24]. More recently, Lee et al. [25] demonstrated that the presence of subclinical cTnl elevation at admission was not uncommon and was associated with OCT-derived unstable plaque morphology in patients undergoing elective PCI, and may help to identify patients with stable angina pectoris at high risk for periprocedural myocardial injury.

3.3. Coronary angiography (Table 4)

In 57 consecutive patients with NSTEMI-ACS who underwent preinterventional angiography, the presence of coronary thrombus detected with angiography to be the only independent factor associated with elevated troponin T levels in patients with NSTEMI-ACS (odds ratio, 22.1; 95% CI, 2.59 to 188.42; $P = 0.0046$) [26]. Mizote et al. demonstrated that no-reflow phenomenon was most frequently ($P < 0.05$) observed in patients with angioscopically defined ruptured plaque at culprit lesion treated without distal protection in 81 AMI patients [27]. In 42 consecutive patients with stable angina undergoing elective coronary stenting, coronary angiography demonstrated that intense yellow culprit plaque coloration was closely associated with TnT elevation and flow complications following elective coronary stenting.

Table 4
Coronary plaque characteristics on coronary angiography for prediction of PMI.

Author	Number of patients	Events rate (%)	Imaging result	Odds ratio (95% CI)
Okamoto et al. [26]	57	TnT ≥ 0.1 ng/mL (52%)	Coronary thrombus	22.1 (2.59 to 188.42)
Mizote et al. [27]	110	No/slow flow (19.4%)	Ruptured plaque	n/a
Murakami et al. [28]	42	TnT ≥ 0.03 ng/mL (52%)	Intense yellow plaque	0.26 (2.25–1243.9)
		Transient no flow (23%)		

PMI = periprocedural myocardial infarction, CI = confidence interval, TnT = troponin T.

Angioscopically-observed intense yellow coloration may therefore predict high-risk plaque for periprocedural myocardial injury [28].

3.4. Near-infrared spectroscopy (NIRS) (Table 5)

Intracoronary NIRS was a method validated to rapidly identify coronary lipid-core plaque (LCP) [29]. In a study of 30 patients undergoing NIRS before PCI, CK-MB increase > 3 times ULN was observed in 27% of patients with > 1 yellow block versus in none of the patients without a yellow block within the stented lesion ($P = 0.02$) [30]. Goldstein et al. [31] analyzed the relationship between the presence of a large LCP (detected by NIRS) and periprocedural MI. Periprocedural MI occurred in 7 of 14 patients (50%) with a maxLCBI (lipid-core burden index) (4 mm) ≥ 500 , compared with 2 of 48 patients (4.2%) patients with a lower maxLCBI (4 mm) ($P = 0.0002$). NIRS provides rapid, automated detection of extensive LCPs that are associated with a high risk of periprocedural MI, presumably due to embolization of plaque contents during coronary intervention. Recently, Kang et al. [32] demonstrated that NIRS-LRP was more accurate than IVUS for predicting plaque containing a necrotic core or a large lipid pool, and the combination was more accurate than either alone. Kini et al. reported that the direct comparison was made among OCT, IVUS, and NIRS in regard to relationship of parameter finding and occurrence of PMI. They retrospectively analyzed 110 patients who underwent OCT, IVUS, and NIRS, and demonstrated that OCT-based fibrous cap thickness is the most important predictor of PMI. In the absence of information about cap thickness, NIRS lipid core or IVUS plaque burden best determined the likelihood of the periprocedural event [33]. Furthermore, Stone et al. examined that NIRS and IVUS were performed at baseline, and lesions with a maximal lipid core burden index over any 4-mm length (maxLCBI_{4 mm}) ≥ 600 were randomized to PCI with versus without a distal protection filter. Plaque characterization by NIRS identifies lipid-rich lesions with an increased likelihood of periprocedural MI after stent implantation, presumably due to distal embolization. However, in this pilot randomized CANARY Trial (Coronary Assessment by Near-infrared of Atherosclerotic Rupture-prone Yellow), the use of a distal protection filter did not prevent PMI after PCI of lipid-rich plaques [34].

4. Non-invasive imaging for prediction of PMI

With the development of multidetector computed tomography (MDCT), it is possible not only to detect coronary artery stenosis but

Table 5
Coronary plaque characteristics on NIRS for prediction of PMI.

Author	Number of patients	Events rate (%)	Imaging result	Odds ratio (95% CI)
Raghunathan et al. [30]	30	CK-MB > 3 × ULN (10%)	≥ 12-mm yellow blocks	n/a
Goldstein et al. [31]	62	TnI or CK-MB > 3 × ULN (14.5%)	maxLCBI _{4 mm} ≥ 500	12 (3.3–48)
Kini et al. [33]	110	TnI > 3 × ULN (9%) TnI > 5 × ULN (7.3%)	maxLCBI _{4 mm}	1.003 (1.000–1.006) (All OCT findings excluded)
Stone et al. [34]	85	TnI or T > 3 × ULN (24.7%)	maxLCBI _{4 mm} ≥ 600	n/a

PMI = periprocedural myocardial infarction, CI = confidence interval, CK-MB = creatine kinase, ULN = upper limit of normal, TnI = troponin I, NIRS = near-infrared spectroscopy, LCBI = lipid core burden index.

also to evaluate coronary plaque quality and quantity such as can be done with IVUS and OCT [35,36]. Furthermore, the introduction of 256-slice, 320-detector scanner, and dual-source CT (DSCT) developed to significantly improve faster scan times, wider volume coverage, and high spatial resolution [37]. In addition to MDCT, magnetic resonance imaging (MRI) may also provide a noninvasive assessment of the risk for prediction of PMI.

4.1. MDCT (Table 6)

There are several published data regarding the relation between pre-PCI plaque composition by MDCT and post-PCI cardiac biomarker levels. Nakagawa et al. reported that patients who experienced transient no-reflow during PCI had lower plaque CT density values in culprit lesions [38]. Uetani et al. demonstrated that post-procedural myocardial injury was associated with the volume and fraction of low-attenuation plaques by MDCT [39]. Our group showed that CT attenuation value of <55 Hounsfield units (HU) was associated with post-PCI cTnT elevation [40]. Positive remodeling and spotty calcification were also significant predictors of post-PCI cTnT elevation. Furthermore, the presence of all 3 CT characteristics (CT attenuation value <55 HU, remodeling index >1.05, and spotty calcification) showed a high positive predictive value (PPV) of 94%, and their absence showed a high negative predictive value (NPV) of 90%. Kodama et al. demonstrated that CTA-verified circumferential plaque calcification (CPC) with low-attenuation plaque and positive remodeling were determinants of slow-flow phenomenon (SF) during PCI [41]. The conditional logistic regression analysis revealed that CPC, plaque density, and dyslipidemia were the predictors of SF, with CPC being the strongest (odds ratio: 79; 95% confidence interval: 8 to 783, $P < 0.0001$). These data suggest that it would be

worthwhile to consider the identification of these vulnerable plaques by MDCT before PCI. If the plaque has the characteristics of low plaque density, positive remodeling, and spotty calcification, a plan for prevention of post-PCI cTnT elevation can be made before the PCI procedure. Nishio et al. [42] showed that both findings of LAP and PR on MDCT were highly sensitive for predicting plaque debris embolization.

4.2. MRI (Table 7)

Recently, non-contrast T1-weighted imaging (T1WI) has emerged as a novel noninvasive imaging modality when searching for vulnerable coronary plaque, and high-intensity plaque (HIP) detected in non-contrast T1WI has been considered to be vulnerable coronary plaque [43,44]. Asaumi et al. [45] published data on the association between HIP and PCI-related myocardial injury with smaller sample size ($n = 57$) and cutoff point of PMR to be 1.3. We also investigated the association between the presence of HIP and the incidence of myocardial injury after PCI. A total of 77 patients with stable angina were imaged with non-contrast T1WI by using a 1.5-T magnetic resonance system (HIP and non-HIP group, $N = 31$ and 46 patients) [46]. We defined HIP as a signal intensity of coronary plaque to cardiac muscle ratio (PMR) of ≥ 1.4. High-sensitive cardiac troponin-T (hs-cTnT) was measured at baseline and 24 h after PCI. HIP was associated with the characteristics of ultrasound attenuation and positive remodeling on intravascular ultrasound. Although baseline hs-cTnT was similar between the groups, increase of hs-cTnT was significantly greater in the HIP versus non-HIP group (0.065 [0.023–0.304] vs 0.017 [0.005–0.026], $P < 0.001$). PMI (an elevation of hs-cTnT > 5 × 99th percentile upper reference limit) occurred more frequently in the HIP than non-HIP group (58.1% vs 10.9%, $P < 0.001$), and the cut-off value of PMR found to be 1.44 for predicting

Table 6
Coronary plaque characteristics on MDCT for prediction of PMI.

Author	Number of patients	Events rate (%)	Imaging result	Odds ratio (95% CI)
Nakazawa et al. [38]	51	Transient no flow (17.6%)	CT value: 67.0 ± 10.1 (HU) Ring-like appearance: 55.6%	0.96 (0.91–0.99) n/a
Uetani et al. [39]	189	TnT > 3 × ULN (31.2%)	CT value: <50 (HU) RI: 1.10 ± 0.21 Calcification: 33.7%	3.07 (1.48–6.35)
Watabe et al. [40]	107	Transient no flow (7.5%) TnT > 3 × ULN (33.6%)	CT value: 43 (26.5–75.7) ^a (HU) RI: 1.20 ± 0.18 Spotty (50%) Ring-like appearance: 31%	4.54 (1.36–15.9) 4.27 (1.30–14.8)
Kodama et al. [41]	40	Slow flow (50%)	CT value: 23.5 (9.5–40) ^a (HU) RI: 1.5 (1.3–1.8) ^a CPC (63%) Ring-like appearance: 10%	0.977 (0.959–0.995) 79 (8–783)
Nishio et al. [42]	55	Slow flow (20%)	CT value: <40 (HU) RI: >1.05 Ring-like appearance: 36%	n/a

Values are presented as mean ± SD except as noted.

PMI = periprocedural myocardial infarction, MDCT = multi-detector computed tomography, TnT = troponin T, ULN = upper limit of normal, HU = Hounsfield units, CPC = circumferential plaque calcification, n/a = not applicable, RI = remodeling index.

^a Median and interquartile range.

Table 7
Coronary plaque characteristics on MRI for prediction of PMI.

Author	Number of patients	Events rate (%)	Imaging results	Odds ratio (95% CI)
Asami et al. [45]	57	Transient no flow (7.5%) TnI > 5 × ULN (33.6%) Slow flow (15.6%)	HIP (PMR ≥ 1.3)	12.0 (3.2–52.2)
Hoshi et al. [46]	77	TnT > 5 × ULN (29.8%)	HIP (PMR ≥ 1.4)	5.63 (1.28–24.7)

Values are presented as mean ± SD except as noted.

PMI = periprocedural myocardial infarction, MDCT = multi-detector computed tomography, TnT = troponin T, ULN = upper limit of normal, HIP = high intensity plaque, PMR = plaque to cardiac muscle ratio.

PMI (sensitivity 78.3%, specificity 81.5%). In multivariate analysis, PMR ≥ 1.4 was a significant predictor of PMI (odds ratio 5.63, 95% confidence interval 1.28–24.7, $P = 0.022$). HIP on non-contrast T1WI was characterized as vulnerable coronary plaque on IVUS and was associated with higher incidence of PMI.

5. Clinical implications

Patel et al. has performed similar review regarding the comparison on coronary imaging for prediction of PMI, and raised several discussions about procedural safety and merit, modification of PCI strategy [47]. Intracoronary imaging is generally a safe procedure, and may allow PCI optimization to reduce the risk of PMI from causes other than distal embolization, such as side branch occlusion or incomplete lesion coverage. However, the low specificity of these modalities for the prediction of distal embolization and PMI suggests that routine intracoronary imaging may be a low-yield strategy. PMI is associated with increased future mortality. The mechanisms and risk factors associated with PMI vary. At present, there are more issues unanswered than answered such as complexity of coronary lesions, prognosis, risk stratification and optimally management strategy related to PMI event. Kini et al. were the first to demonstrate the superiority of OCT-defined TCFA compared with other imaging modalities such as IVUS and NIRS for prediction of PMI [33]. The OCT-based fibrous cap thickness is the most important predictor of PMI. The CANARY trial demonstrated that plaques responsible for PMI were lipid rich and had a large plaque burden and a small MLA evaluated by NIRS, and the use of a distal embolic protection filter did not reduce the rate of PMI after stenting of lipid-rich plaques [34]. Therefore, the next step to prevent PMI would be a trial comparing patients with the presence of OCT TCFA in the vessel undergoing intervention randomized to either distal protection or control.

Recently, noncontrast T1WI provided clinically and procedurally important information on high-risk features of coronary plaques without exposure to ionizing radiation and contrast media. Our study is unique in detailed description of IVUS correlating with HIP on T1WI and consequent clinical significance [46]. The other step to prevent PMI would be a trial comparing patient with the presence of HIP on T1WI in the vessel undergoing intervention randomized to either distal protection or control.

6. Medical treatment on PMI after PCI

Several therapeutic strategies, including statins, antithrombotic agents [45] and β -blockers [46] have been suggested to reduce PMI. The incidence of PMI has been reduced more effectively by high-dose statin than by low-dose statin in statin-naive patients. Statins are regarded as an important agent for the prevention of PMI. Takano et al. [47] demonstrated that low-dose rosuvastatin was sufficient for patients who are already taking statins. A meta-analysis of Wang et al. [48] demonstrated that in 24 RCTs with a total of 5526 patients, high-dose statin pretreatment was associated with 59% relative reduction in PMI (odds ratio [OR]: 0.41; 95% confidence interval [CI]: 0.34–0.49; $P < 0.00001$) and 39% relative reduction in MACE (OR: 0.61; 95% CI:

0.45–0.83; $P < 0.002$). The benefit of high-dose statin pretreatment on MACE was significant for statin-naive patients (OR: 0.69; 95% CI: 0.50–0.95; $P < 0.02$) and prior low dose statin-treated patients (OR: 0.28; 95% CI: 0.12–0.65; $P < 0.003$); and for patients with acute coronary syndrome (OR: 0.52; 95% CI: 0.34–0.79; $P < 0.003$), but not for patients with stable angina (OR: 0.71; 95% CI 0.45–1.10; $P = 0.12$).

7. Conclusion

With further improvements in imaging technology, invasive or non-invasive coronary imaging becomes accurate detection of coronary plaques in clinical practice. Assessment of both coronary stenosis and plaque morphology has great potential application to further advance the prediction of PMI. Further large studies will be needed to confirm that multi-modality imaging approach will become the gold standard for evaluation of coronary plaque morphology predicting PMI in clinical examinations.

Conflict of interest

The authors report no relationships that could be construed as a conflict of interest.

References

- [1] C.W. White, C.B. Wright, D.B. Doty, L.F. Hiratzka, C.L. Eastham, D.G. Harrison, M.L. Marcus, Does visual interpretation of the coronary arteriogram predict the physiologic importance of a coronary stenosis? *N. Engl. J. Med.* 310 (1984) 819–824.
- [2] M.L. Marcus, D.G. Harrison, C.W. White, D.D. McPherson, R.F. Wilson, R.E. Kerber, Assessing the physiologic significance of coronary obstructions in patients: importance of diffuse undetected atherosclerosis, *Prog. Cardiovasc. Dis.* 31 (1988) 39–56.
- [3] A. Prasad, B.J. Gersh, M.E. Bertrand, et al., Prognostic significance of periprocedural versus spontaneously occurring myocardial infarction after percutaneous coronary intervention in patients with acute coronary syndromes: an analysis from the ACUTY (Acute Catheterization and Urgent Intervention Triage Strategy) trial, *J. Am. Coll. Cardiol.* 54 (2009) 477–486.
- [4] M.B. Nienhuis, J.P. Ottervanger, H.J. Bilo, B.D. Dikkeschei, F. Zijlstra, Prognostic value of troponin after elective percutaneous coronary intervention: a meta-analysis, *Catheter. Cardiovasc. Interv.* 71 (2008) 318–324.
- [5] N.D. Brunetti, Di Biase M. Quagliara, Troponin ratio and risk stratification in subjects with acute coronary syndrome undergoing percutaneous coronary intervention, *Eur. J. Intern. Med.* 19 (2008) 435–442.
- [6] A. Prasad, C.S. Rihal, R.J. Lennon, M. Singh, A.S. Jaffe, Holmes Dr Jr, Significance of periprocedural myonecrosis on outcomes after percutaneous coronary intervention: analysis of preintervention and postintervention troponin T levels in 5487 patients, *Circ. Cardiovasc. Interv.* 1 (2008) 10–19.
- [7] C. Cavallini, P. Verdecchia, S. Savonitto, G. Arraiz, R. Violini, Z. Olivari, P. Rubartelli, S. De Servi, M. Plebani, G. Steffenino, P. Sbarzaglia, D. Ardissino, Italian Atherosclerosis Thrombosis and Vascular Biology and Society for Invasive Cardiology-GISE Investigators, Prognostic value of isolated troponin I elevation after percutaneous coronary intervention, *Circ. Cardiovasc. Interv.* 3 (2010) 431–435.
- [8] A. Jeremias, N.S. Kleiman, D. Nassif, W.H. Hsieh, M. Pencina, K. Mares, M. Parikh, D.E. Cutlip, R. Waksman, S. Goldberg, P.B. Berger, D.J. Cohen, Prevalence and prognostic significance of preprocedural cardiac troponin elevation among patients with stable coronary artery disease undergoing percutaneous coronary intervention results from the evaluation of drug eluting stents and ischemic events registry, *Circulation* 118 (2008) 632–638.
- [9] K. Thygesen, J.S. Alpert, A.S. Jaffe, M.L. Simoons, B.R. Chaitman, H.D. White, Third universal definition of myocardial infarction, *J. Am. Coll. Cardiol.* 60 (2012) 1581–1598.
- [10] I. Porto, J.B. Selvanayagam, W.J. Van Gaal, et al., Plaque volume and occurrence and location of periprocedural myocardial necrosis after percutaneous coronary intervention: insights from delayed-enhancement magnetic resonance imaging,

- thrombolysis in myocardial infarction myocardial perfusion grade analysis, and intravascular ultrasound, *Circulation* 114 (2006) 662–669.
- [11] D.W. Park, Y.H. Kim, S.C. Yun, J.M. Ahn, J.Y. Lee, W.J. Kim, S.J. Kang, S.W. Lee, C.W. Lee, S.W. Park, S.J. Park, Frequency, causes, predictors, and clinical significance of periprocedural myocardial infarction following percutaneous coronary intervention, *Eur. Heart J.* 34 (2013) 1662–1669.
- [12] D.N. Feldman, L. Kim, A.G. Rene, R.M. Minutello, G. Bergman, S.C. Wong, Prognostic value of cardiac troponin-I or troponin-T elevation following nonemergent percutaneous coronary intervention: a meta-analysis, *Catheter. Cardiovasc. Interv.* 77 (2011) 1020–1030.
- [13] M. Mueller, M. Vafaie, M. Biener, E. Giannitsis, H.A. Katus, Cardiac troponin T: from diagnosis of myocardial infarction to cardiovascular risk prediction, *Circ. J.* 77 (2013) 1653–1661.
- [14] R. Mehran, G. Dangas, G.S. Mintz, A.J. Lansky, A.D. Pichard, L.F. Satler, K.M. Kent, G.W. Stone, M.B. Leon, Atherosclerotic plaque burden and CK-MB enzyme elevation after coronary interventions: intravascular ultrasound study of 2256 patients, *Circulation* 101 (2000) 604–610.
- [15] K. Fujii, S.G. Carlier, G.S. Mintz, et al., Creatine kinase-MB enzyme elevation and long-term clinical events after successful coronary stenting in lesions with ruptured plaque, *Am. J. Cardiol.* 95 (2005) 355–359.
- [16] T. Kawamoto, H. Okura, Y. Koyama, et al., The relationship between coronary plaque characteristics and small embolic particles during coronary stent implantation, *J. Am. Coll. Cardiol.* 50 (2007) 1635–1640.
- [17] Y.J. Hong, G.S. Mintz, S.W. Kim, et al., Impact of plaque composition on cardiac troponin elevation after percutaneous coronary intervention: an ultrasound analysis, *J. Am. Coll. Cardiol. Img.* 2 (2009) 458–468.
- [18] T. Uetani, T. Amano, H. Ando, K. Yokoi, K. Arai, M. Kato, N. Marui, M. Nanki, T. Matsubara, H. Ishii, H. Izawa, T. Murohara, The correlation between lipid volume in the target lesion, measured by integrated backscatter intravascular ultrasound, and post-procedural myocardial infarction in patients with elective stent implantation, *Eur. Heart J.* 29 (2008) 1714–1720.
- [19] Y. Higuchi, T. Hiro, T. Takayama, T. Kanai, T. Kawano, D. Fukamachi, M. Sudo, T. Nishida, K. Iida, S. Saito, A. Hirayama, Impact of coronary plaque burden and composition on periprocedural myocardial infarction and coronary flow reserve after percutaneous coronary intervention, *Int. Heart J.* 55 (2014) 391–396.
- [20] M. Utsunomiya, H. Hara, K. Sugi, M. Nakamura, Relationship between tissue characteristics with 40 MHz intravascular ultrasound imaging and slow flow during coronary intervention, *EuroIntervention* 7 (2011) 340–346.
- [21] I.K. Jang, G.J. Tearney, B. MacNeill, et al., In vivo characterization of coronary atherosclerotic plaque by use of optical coherence tomography, *Circulation* 111 (2005) 1551–1555.
- [22] T. Yonetsu, T. Kakuta, T. Lee, K. Takahashi, G. Yamamoto, Y. Iesaka, H. Fujiwara, M. Isobe, Impact of plaque morphology on creatine kinase-MB elevation in patients with elective stent implantation, *Int. J. Cardiol.* 146 (2011) 80–85.
- [23] T. Lee, T. Kakuta, T. Yonetsu, K. Takahashi, G. Yamamoto, Y. Iesaka, H. Fujiwara, M. Isobe, Assessment of echo-attenuated plaque by optical coherence tomography and its impact on post-procedural creatine kinase-myocardial band elevation in elective stent implantation, *J. Am. Coll. Cardiol. Interv.* 4 (2011) 483–491.
- [24] T. Lee, T. Yonetsu, K. Koura, K. Hishikari, T. Murai, T. Iwai, T. Takagi, Y. Iesaka, H. Fujiwara, M. Isobe, T. Kakuta, Impact of coronary plaque morphology assessed by optical coherence tomography on cardiac troponin elevation in patients with elective stent implantation, *Circ. Cardiovasc. Interv.* 4 (2011) 378–386.
- [25] T. Lee, T. Murai, T. Yonetsu, A. Suzuki, K. Hishikari, Y. Kanaji, J. Matsuda, M. Araki, T. Niida, M. Isobe, T. Kakuta, Relationship between subclinical cardiac troponin I elevation and culprit lesion characteristics assessed by optical coherence tomography in patients undergoing elective percutaneous coronary intervention, *Circ. Cardiovasc. Interv.* (4) (2015), <http://dx.doi.org/10.1161/CIRCINTERVENTIONS.114.001727> (Apr; pii: e001727).
- [26] K. Okamoto, M. Takano, S. Sakai, F. Ishibashi, R. Uemura, T. Takano, K. Mizuno, Elevated troponin T levels and lesion characteristics in non-ST-elevation acute coronary syndromes, *Circulation* 109 (2004) 465–470.
- [27] I. Mizote, Y. Ueda, T. Ohtani, M. Shimizu, Y. Takeda, T. Oka, M. Tsujimoto, A. Hirayama, M. Hori, K. Kodama, Distal protection improved reperfusion and reduced left ventricular dysfunction in patients with acute myocardial infarction who had angiographically defined ruptured plaque, *Circulation* 112 (2005) 1001–1007.
- [28] D. Murakami, M. Takano, M. Yamamoto, T. Inami, S. Inami, K. Okamoto, T. Ohba, Y. Seino, K. Mizuno, Intense yellow culprit plaque coloration is closely associated with troponin-T elevation and flow complications following elective coronary stenting, *J. Atheroscler. Thromb.* 18 (2011) 906–913.
- [29] S. Waxman, S.R. Dixon, P. L'Allier, J.W. Moses, J.L. Petersen, D. Cutlip, J.C. Tardif, R.W. Nesto, J.E. Muller, M.J. Hendricks, S.T. Sum, C.M. Gardner, J.A. Goldstein, G.W. Stone, M.W. Krucoff, In vivo validation of a catheter-based near-infrared spectroscopy system for detection of lipid core coronary plaques: initial results of the SPECTACL study, *J. Am. Coll. Cardiol. Img.* 2 (2009) 858–868.
- [30] D. Raghunathan, A.R. Abdel-Karim, A.C. Papayannis, M. daSilva, O.M. Jeroudi, B.V. Rangan, S. Banerjee, E.S. Brilakis, Relation between the presence and extent of coronary lipid core plaques detected by near-infrared spectroscopy with postpercutaneous coronary intervention myocardial infarction, *Am. J. Cardiol.* 107 (2011) 1613–1618.
- [31] J.A. Goldstein, B. Maini, S.R. Dixon, E.S. Brilakis, C.L. Grines, D.G. Rizik, E.R. Powers, D.H. Steinberg, K.A. Shunk, G. Weisz, P.R. Moreno, A. Kini, S.K. Sharma, M.J. Hendricks, S.T. Sum, S.P. Madden, J.E. Muller, G.W. Stone, M.J. Kern, Detection of lipid-core plaques by intracoronary near-infrared spectroscopy identifies high risk of periprocedural myocardial infarction, *Circ. Cardiovasc. Interv.* 4 (2011) 429–437.
- [32] S.J. Kang, G.S. Mintz, J. Pu, S.T. Sum, S.P. Madden, A.P. Burke, K. Xu, J.A. Goldstein, G.W. Stone, J.E. Muller, R. Virmani, A. Maehara, Combined IVUS and NIRS detection of fibroatheromas: histopathological validation in human coronary arteries, *J. Am. Coll. Cardiol. Img.* 8 (2015) 184–194.
- [33] A.S. Kini, S. Motoyama, Y. Vengrenyuk, J.E. Feig, J. Pena, U. Baber, A.M. Bhat, P. Moreno, J.C. Kovacic, J. Narula, S.K. Sharma, Multimodality intravascular imaging to predict periprocedural myocardial infarction during percutaneous coronary intervention, *J. Am. Coll. Cardiol. Interv.* 8 (2015) 937–945.
- [34] G.W. Stone, A. Maehara, J.E. Muller, D.G. Rizik, K.A. Shunk, O. Ben-Yehuda, P. Genereux, O. Dressler, R. Parvataneni, S. Madden, P. Shah, E.S. Brilakis, A.S. Kini, C.A.N.A.R.Y. Investigators, Plaque characterization to inform the prediction and prevention of periprocedural myocardial infarction during percutaneous coronary intervention: the CANARY trial (Coronary Assessment by Near-infrared of Atherosclerotic Rupture-prone Yellow), *J. Am. Coll. Cardiol. Interv.* 8 (2015) 927–936.
- [35] A.W. Leber, A. Knez, F. von Ziegler, A. Becker, K. Nikolou, S. Paul, B. Wintersperger, M. Reiser, C.R. Becker, G. Steinbeck, P. Boekstegers, Quantification of obstructive and nonobstructive coronary lesions by 64-slice computed tomography: a comparative study with quantitative coronary angiography and intravascular ultrasound, *J. Am. Coll. Cardiol.* 46 (2005) 147–154.
- [36] M. Kashiwagi, A. Tanaka, H. Kitabata, H. Tsujioka, H. Kataiwa, K. Komukai, T. Tanimoto, K. Takemoto, S. Takarada, T. Kubo, K. Hirata, N. Nakamura, M. Mizukoshi, T. Imanishi, T. Akasaka, Feasibility of noninvasive assessment of thin-cap fibroatheroma by multidetector computed tomography, *J. Am. Coll. Cardiol. Img.* 2 (2009) 1412–1419.
- [37] K.H. Schuleri, R.T. George, A.C. Lardo, Applications of cardiac multidetector CT beyond coronary angiography, *Nat. Rev. Cardiol.* 6 (2009) 699–710.
- [38] G. Nakazawa, K. Tanabe, Y. Onuma, S. Yachi, J. Aoki, H. Yamamoto, Y. Higashikuni, A. Yagishita, H. Nakajima, K. Hara, Efficacy of culprit plaque assessment by 64-slice multidetector computed tomography to predict transient no-reflow phenomenon during percutaneous coronary intervention, *Am. Heart J.* 155 (2008) 1150–1157.
- [39] T. Uetani, T. Amano, A. Kunimura, S. Kumagai, H. Ando, K. Yokoi, T. Yoshida, B. Kato, M. Kato, N. Marui, M. Nanki, T. Matsubara, H. Ishii, H. Izawa, T. Murohara, The association between plaque characterization by CT angiography and post-procedural myocardial infarction in patients with elective stent implantation, *J. Am. Coll. Cardiol. Img.* 3 (2010) 19–28.
- [40] H. Watabe, A. Sato, D. Akiyama, Y. Kakefuda, T. Adachi, E. Ojima, T. Hoshi, N. Murakoshi, T. Ishizu, Y. Seo, K. Aonuma, Impact of coronary plaque composition on cardiac troponin elevation after percutaneous coronary intervention in stable angina pectoris: a computed tomography analysis, *J. Am. Coll. Cardiol.* 59 (2012) 1881–1889.
- [41] T. Kodama, T. Kondo, A. Oida, S. Fujimoto, J. Narula, Computed tomographic angiography-verified plaque characteristics and slow-flow phenomenon during percutaneous coronary intervention, *J. Am. Coll. Cardiol. Interv.* 5 (2012) 636–643.
- [42] M. Nishio, Y. Ueda, K. Matsuo, M. Tsujimoto, H. Hao, M. Asai, et al., Association of target lesion characteristics evaluated by coronary computed tomography angiography and plaque debris distal embolization during percutaneous coronary intervention, *Circ. J.* 78 (2014) 2203–2208.
- [43] T. Kawasaki, S. Koga, N. Koga, T. Noguchi, H. Tanaka, H. Koga, T. Serikawa, Y. Orita, S. Ikeda, T. Mito, Y. Goto, Y. Shintani, A. Tanaka, T. Fukuyama, Characterization of hyperintense plaque with noncontrast T1-weighted cardiac magnetic resonance coronary plaque imaging: comparison with multislice computed tomography and intravascular ultrasound, *J. Am. Coll. Cardiol. Img.* 2 (2009) 720–728.
- [44] T. Noguchi, T. Kawasaki, A. Tanaka, S. Yasuda, Y. Goto, M. Ishihara, K. Nishimura, Y. Miyamoto, K. Node, N. Koga, High-intensity signals in coronary plaques on noncontrast T1-weighted magnetic resonance imaging as a novel determinant of coronary events, *J. Am. Coll. Cardiol.* 63 (2014) 989–999.
- [45] Y. Asaumi, T. Noguchi, Y. Morita, R. Fujiwara, T. Kanaya, T.A. Matsuyama, T. Kawasaki, M. Fujino, T. Yamane, T. Nagai, T. Miyagi, H. Ishibashi-Ueda, M. Higashi, Y. Komori, M. Ishihara, H. Ogawa, S. Yasuda, High-intensity plaques on noncontrast T1-weighted imaging as a predictor of periprocedural myocardial injury, *J. Am. Coll. Cardiol. Img.* 8 (2015) 741–743.
- [46] T. Hoshi, A. Sato, D. Akiyama, D. Hiraya, S. Sakai, M. Shindo, K. Mori, M. Minami, K. Aonuma, Coronary high-intensity plaque on T1-weighted magnetic resonance imaging and its association with myocardial injury after percutaneous coronary intervention, *Eur. Heart J.* 36 (2015) 1913–1922.
- [47] V.G. Patel, K.M. Brayton, G.S. Mintz, A. Maehara, S. Banerjee, E.S. Brilakis, Intracoronary and noninvasive imaging for prediction of distal embolization and periprocedural myocardial infarction during native coronary artery percutaneous intervention, *Circ. Cardiovasc. Imaging* 6 (2013) 1102–1114.