

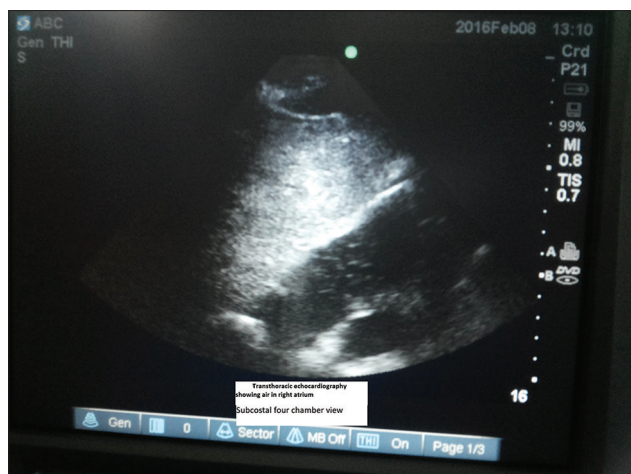
## Venous air/oxygen embolism due to hydrogen peroxide in anal fistulectomy

Hydrogen peroxide, an oxidizing agent, is frequently used in the cleansing of wound due to its germicidal properties. It is also used by surgeons in anal fistulectomy to locate the internal opening of the fistula in addition to its action in bubbling out foreign materials and debris. However, it may lead to air/oxygen embolism when irrigated into a closed body cavity.<sup>[1]</sup> Here, we present a case of air/oxygen embolism due to hydrogen peroxide in anal fistulectomy that was managed successfully.

A 39-year-old male ASA 1 was scheduled to undergo anal fistulectomy. Saddle block anesthesia was provided using 1.2 ml of 0.5% hyperbaric bupivacaine. After 15 minutes of saddle block, the patient was put in the lithotomy position. Per rectal examination was done by the surgeons. The external opening was at six o' clock position and the internal opening could not be felt. The external fistula opening was probed with a lubricated blunt malleable fistula probe that could be

pushed up to 2 cm in intersphincteric plane. He remained hemodynamically stable. The probe was removed and a 6 FG feeding tube was inserted through the external opening into the tract and 10 ml of 1.5% hydrogen peroxide was pushed with the aim to locate the internal opening. The internal opening could not be located and hydrogen peroxide did not return from the external opening as well.

At this time, suddenly the patient developed respiratory distress with the respiratory rate at 40/min and started coughing. He started complaining of chest pain which was crushing in character. Heart rate increased from 80/min to 140/min and blood pressure fell to 90/60 mm Hg. EtCO<sub>2</sub> decreased from 35 to 20 mm Hg and oxygen saturation fell to 85%. Chest auscultation revealed bilateral bronchospasm. The operative procedure was deferred and the patient was put in the Trendelenburg position with 100% oxygen. Sublingual sorbitrate was given and hydrocortisone 100 mg and deriphyllin were administered intravenously. In view of non-return of hydrogen peroxide from the fistula tract, the possibility of air/oxygen embolism was considered. Within 15 minutes, urgent transthoracic echocardiography using a portable ultrasound machine was done which showed air in the right atrium confirming the diagnosis of embolism [Figure 1].



**Figure 1:** Transthoracic echocardiography showing air in right atrium subcostal four chamber view

PA pressure was 56 mm Hg and the right atrium and the right ventricle were dilated. The patient was treated symptomatically. A repeat echocardiography after half an hour showed no air in the right atrium. The patient was kept under observation for 24 hours and then discharged from the hospital.

Administration of hydrogen peroxide into closed space or body cavities from which the release of oxygen has no egress can lead to catastrophic complications.<sup>[2]</sup> Each ml of 3% hydrogen peroxide produces 10 ml of oxygen. The possible mechanism of embolism is likely to be perforation of a plexus vein and injection of bubbles into plexus vein leading to a decrease in the cardiac output. Bubbles can traverse the lungs to cause systemic embolization including embolism to the coronary and cerebral arteries. The classic signs of air embolism are hypotension, precordial mill wheel murmur, and decrease in EtCO<sub>2</sub> along with a decrease in the oxygen saturation. Precordial auscultation for mill wheel murmur, transoesophageal echocardiography, transthoracic echocardiography, and the measurement of pulmonary artery pressure and right ventricular output can be used for diagnosis. We suspected air embolism due to sudden alteration in the hemodynamic variables, decrease in EtCO<sub>2</sub>, and oxygen saturation, further confirmed by transthoracic echocardiography which showed air in right atrium. There were no signs and symptoms of systemic embolization.

The management of air embolism includes rinsing the point of gas entry with saline, placing the patient in the Trendelenburg and left lateral position to trap gas in the apex of the ventricle, administration of 100% oxygen, and maintaining hemodynamic

stability along with symptomatic management.<sup>[1]</sup> We managed the patient successfully using these measures.

Gas embolism produced by hydrogen peroxide irrigation of an anal fistula during anesthesia has been reported in an 8-month-old infant by Tsai *et al.*<sup>[2]</sup> In addition, gas embolism has been reported during irrigation of surgical field with hydrogen peroxide in cervical spine surgery and enterocutaneous fistula.<sup>[3,4]</sup> However, in these, undiluted hydrogen peroxide was used. Although we used diluted hydrogen peroxide, still gas embolism occurred.

This case highlights the catastrophic complication of using diluted hydrogen peroxide in a closed cavity like anal fistula and that the team working in the operating room should be aware of this potential fatal complication.

### Declaration of patient consent

The authors certify that they have obtained all appropriate patient consent forms. In the form the patient(s) has/have given his/her/their consent for his/her/their images and other clinical information to be reported in the journal. The patients understand that their names and initials will not be published and due efforts will be made to conceal their identity, but anonymity cannot be guaranteed.

### Financial support and sponsorship

Nil.

### Conflicts of interest

There are no conflicts of interest.

**Shashi Kiran, Sanjay Marwah<sup>1</sup>, Teena Bansal, Neha Gupta<sup>2</sup>**

Departments of Anaesthesiology and Critical Care and <sup>1</sup>Surgery, University of Health Sciences, Rohtak, Haryana, <sup>2</sup>Department of Anaesthesia, KGMC, Lucknow, Uttar Pradesh, India

**Address for correspondence:** Dr. Teena Bansal, Department of Anaesthesiology and Critical Care, University of Health Sciences, Rohtak - 124 001, Haryana, India.  
E-mail: aggarwalteenu@rediffmail.com


### References

1. Sastre JA, Prieto MA, Garzon JC, Muriel C. Left-sided cardiac gas embolism produced by hydrogen peroxide: Intraoperative diagnosis using transesophageal echocardiography. *Anesth Analg* 2001;93:1132-4.
2. Tsai S, Lee T, Mok MS. Gas embolism produced by hydrogen peroxide irrigation of an anal fistula during anesthesia.

- Anesthesiology 1985;63:316-7.
3. Morikawa H, Mima H, Fujita H, Mishima S. Oxygen embolism due to hydrogen peroxide irrigation during cervical spine surgery. *Can J Anaesth* 1995;42:231-3.
  4. Jones PM, Segal SH, Gelb AW. Venous oxygen embolism produced by injection of hydrogen peroxide into an enterocutaneous fistula. *Anesth Analg* 2004;99:1861-3.

---

This is an open access journal, and articles are distributed under the terms of the Creative Commons Attribution-NonCommercial-ShareAlike 4.0 License, which allows others to remix, tweak, and build upon the work non-commercially, as long as appropriate credit is given and the new creations are licensed under the identical terms.

Access this article online	
<b>Quick Response Code:</b>	<b>Website:</b> www.joacp.org
	<b>DOI:</b> 10.4103/joacp.JOACP_11_18
<b>How to cite this article:</b> Kiran S, Marwah S, Bansal T, Gupta N. Venous air/oxygen embolism due to hydrogen peroxide in anal fistulectomy. <i>J Anaesthesiol Clin Pharmacol</i> 2018;34:555-7.	
© 2019 Journal of Anaesthesiology Clinical Pharmacology   Published by Wolters Kluwer - Medknow	