

Received: 2019.12.01  
Accepted: 2019.12.27  
Published: 2020.01.16

# Risk Factors for Asymptomatic Intracranial Small Aneurysm Rupture Determined by Electrocardiographic-Gated 4D Computed Tomographic (CT) Angiography

Authors' Contribution:  
Study Design A  
Data Collection B  
Statistical Analysis C  
Data Interpretation D  
Manuscript Preparation E  
Literature Search F  
Funds Collection G

BCDE 1 **Yan Gu\***  
BCDE 1 **Yonggang Zhang\***  
BCDF 1 **Meng Luo**  
BCDF 2 **Hongwei Zhang**  
BCDF 2 **Xiguang Liu**  
ABCG 1 **Chongchang Miao**

1 Department of Radiology, The First People's Hospital of Lianyungang, Lianyungang, Jiangsu, P.R. China  
2 Department of Neurosurgery, The First People's Hospital of Lianyungang, Lianyungang, Jiangsu, P.R. China

\* Yan Gu and Yonggang Zhang contributed equally to this work and should be considered co-first authors

**Corresponding Author:** Chongchang Miao, e-mail: 18961326819@189.cn

**Source of support:** This study received funding from the General Scientific Research Project of Jiangsu Provincial Health Commission (H2018091) and the General Scientific Research Project of Lianyungang Municipal Health and Family Planning Commission (201801)

**Background:** To study the risk predictors of intracranial asymptomatic small aneurysm rupture by electrocardiographic (ECG)-gated 4D-CT angiography (4D-CTA).





**Material/Methods:** A total of 168 patients with intracranial aneurysms <7 mm who underwent 4D-CTA examinations were retrospectively analyzed and divided into a ruptured group and an unruptured group. The original scanning data of all cases were reconstructed to obtain 20 groups of data in 5% time intervals in the cardiac cycle. After processing with 3D workstation software, 20 sets of images and dynamic images were achieved. The morphological characteristics and clinical features of the 2 groups of aneurysms were analyzed through univariate analysis, then logistic regression analysis was performed for the meaningful indicators. Finally, the optimum diagnostic cut-off point was calculated by ROC curve analysis.

**Results:** Univariate analysis showed that sex, smoking history, vascular bifurcation point, pulsation point appearance, aneurysm height, aspect ratio (AR), and size ratio (SR) were significantly different ( $P < 0.05$ ) between the ruptured group and unruptured group. Multivariate regression analysis indicated that the pulsation points (OR=8.188, 95% CI: 3.984–17.198) and high SR values (OR=5.325, 95% CI: 1.503–18.867) were independent predictors of asymptomatic small aneurysm rupture. When the SR value was higher than 1.65, the area below the ROC curve was 0.723, the diagnostic sensitivity was 75%, and the specificity was 80%.

**Conclusions:** The occurrence of pulsation points and SR values >1.65 were independent predictors for the rupture of asymptomatic small intracranial aneurysms <7 mm in diameter.

**MeSH Keywords:** **Angiography • Intracranial Aneurysm • Rupture**

**Full-text PDF:** <https://www.medscimonit.com/abstract/index/idArt/921835>

 2599  2  3  27



## Background

Aneurysms with a diameter of less than 7 mm usually cause no symptoms and are most often diagnosed as asymptomatic aneurysms [1]. In a large-scale study of the natural history of aneurysms, ISUIA used 7 mm as a new cut-off value and defined an aneurysm with a diameter <7 mm as a small aneurysm in an attempt to classify small aneurysms with low rupture risks [2]. A prospective study following patients with aneurysms <7 mm but without SAH history found that no aneurysm ruptures occurred within 2.4 years [3]. A study in Finland suggested that the high-risk factors for aneurysm rupture are diameters >7 mm, female sex, and smoking, and the rupture risk of small aneurysms <7 mm was extremely low [4]. Most researchers believe that the larger the aneurysm, the greater the risk of rupture [5]. However, some studies have shown that small aneurysms also have a high possibility of rupture [6]. In a 1.5-year follow-up of patients with small aneurysms <7 mm [7], FIA discovered that the aneurysm rupture rate was 1.2% per year, which was 17 times higher than that of aneurysms with similar sizes and locations in the ISUIA study. In a study conducted in Japan that included 529 aneurysm cases, rupture was found in 19 cases within 2.5 years, and 5 of the 19 had diameters <7 mm. These results indicate that among all ruptured aneurysm cases followed, patients with aneurysms <7 mm accounted for 26% of the ruptures. Due to the controversy about the rupture risk of aneurysms with diameters <7 mm, it is necessary to identify factors that predict the rupture risks of asymptomatic small aneurysms.

In the past, many studies have been conducted on the rupture risks of intracranial aneurysms [9–13], which included the hemodynamic and clinical features of aneurysms. Because an aneurysm is a morphologically-related disease and the blood in the aneurysm is the same as the blood in the parent artery, which flows with the pulsation of the artery, the morphology of an aneurysm is not fixed. Most of the previous morphological studies on aneurysms analyzed static data based on three-dimensional computed tomographic angiography (3D-CTA) and lacked dynamic data. Therefore, using dynamic four-dimensional computed tomographic angiography (4D-CTA) to study the morphology of aneurysms may be more meaningful for investigations of the risk of aneurysm rupture. We used 4D-CTA to analyze the risk factors for asymptomatic small aneurysm rupture from the perspective of dynamic changes in intracranial aneurysms, aiming to assist clinical neurosurgeons to design the most appropriate personalized treatment plans for patients with unruptured intracranial asymptomatic small aneurysms.

## Material and Methods

### Subjects

This study retrospectively analyzed patients with intracranial aneurysms who underwent 4D-CTA examinations in our hospital from June 2014 to June 2018.

The inclusion criteria were: (1) intracranial saccular aneurysms with a large diameter <7 mm; (2) aneurysms, including ruptured and unruptured single aneurysms and unruptured multiple aneurysms; and (3) all 4D-CTA images that showed a clear edge of the aneurysm, in agreement with the diagnostic criteria.

The exclusion criteria were: (1) secondary intracranial aneurysms, such as traumatic aneurysms and infectious aneurysms; (2) intracranial aneurysms combined with other cerebrovascular malformations; (3) poor aneurysm images, which made accurate measurement difficult (including vasospasm); (4) atypical aneurysms with hard-to-measure shapes; and (5) dissecting aneurysms.

Finally, 168 aneurysms from 168 patients were included in the study. There were 65 males aged 11 to 78 years old with an average age of  $57 \pm 11$  years and 103 females aged from 18 to 82 years with an average age of  $54 \pm 13$  years.

According to whether the aneurysm was ruptured or not, all cases were divided into 2 groups – ruptured and unruptured.

There were 102 cases in the ruptured group, including 16 internal carotid aneurysms, 22 middle cerebral aneurysms, 27 anterior communicating aneurysms, 25 posterior communicating aneurysms, and 12 basal aneurysms.

Sixty-six cases were assigned to the unruptured group, including 12 internal carotid aneurysms, 15 middle cerebral aneurysms, 19 anterior communicating aneurysms, 14 posterior communicating aneurysms, and 6 basal aneurysms.

There were 14 multiple aneurysms, including 1 ruptured multiple aneurysm and 13 unruptured multiple aneurysms.

In the ruptured group, 12 basal aneurysms out of 102 aneurysms were treated with interventional embolization, and the other anterior circulation aneurysms were treated with clamping by lateral orbital approach. If the aneurysm is found to be difficult to clamp during the operation, the parent artery can be temporarily blocked for less than 10 min.

Among 66 unruptured aneurysms, 23 aneurysms with pulsation points were found for the first time in 4D-CTA; 7 of these 23 aneurysms were treated at the request of patients within

1 week after examination, 5 aneurysms underwent clamping, and 2 patients underwent interventional embolization.

The follow-up time was half a year after the first discovery, if there is no change of volume, and next follow-up time can be once a year. If an aneurysm is found to increase in size during follow-up, clamping or interventional embolization is recommended. Of the 16 aneurysms with pulsation points, 5 aneurysms were enlarged during follow-up. Among 43 aneurysms with no pulsation points, only 1 aneurysm showed an increase during follow-up.

### Scanning method

A German Siemens Somatom Definition Flash Function CT scanner with 120 kV tube voltage and 110 mA tube current was employed in this study. The scan mode used was a simulated coronary CTA scan and the scanner was connected to an ECG monitor. A double-tube syringe was used to inject 40 ml iohexol non-ionic contrast agent (organic iodine, 370 g/L, Hengrui Pharmaceutical Co., Jiangsu) and 20 ml saline through the elbow vein, at an injection rate of 4.5 mL/s. As soon as the intracranial artery image was observed, continuous volume scanning was manually triggered to scan the RR interval. When the scanning was complete, the raw data were reconstructed to obtain 20 sets of data at 5% time intervals in the cardiac cycle. The data were input into the 3D processing software of the German Flash DSCT image post-processing workstation to generate 20 static and dynamic images of the intracranial arterial cycle [14]. The diameters of the aneurysms were recorded as the average measurements from 20 images.

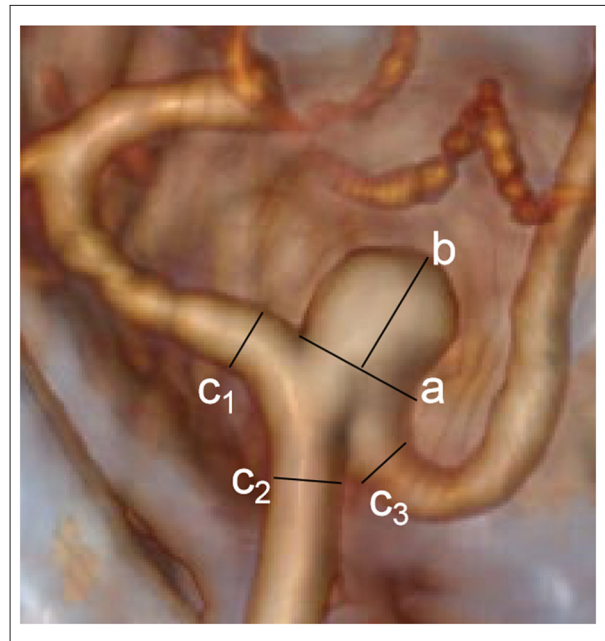
The scan dose was expressed by the effective dose (ED), the volume CT dose index (CTDIvol), and the dose-length product (DLP). The ED value was calculated by multiplying the DLP and the head CT conversion index 0.021 [15].

### Definition aneurysm indicators

The aneurysm neck referred to the line connecting the aneurysm with the parent artery. The aneurysm height referred to the line connecting the highest point of the bottom of the aneurysm to the midpoint of the aneurysm neck (Figure 1). The aspect ratio (AR) was defined as aneurysm height/aneurysm neck.

The aneurysm size referred to the largest value among the maximum width of the aneurysm and the aneurysm height. The maximum width of an aneurysm was defined as the length of the lines perpendicular to the aneurysm height connecting the 2 sidewalls of the aneurysm.

The size ratio (SR) was defined as the aneurysm height/diameter of the parent artery. The diameter of the parent artery



**Figure 1.** 50% phase diagram of 20 dynamic images obtained from 4D-CTA (four-dimensional CT angiography) of the aortic aneurysm located at the M1 segment of the middle cerebral artery. Line A represents the neck, line B represents the height of the aneurysm, c1, c2, c3... represent the diameter of the parent artery, which is the largest diameter within 5 mm from the proximal neck.

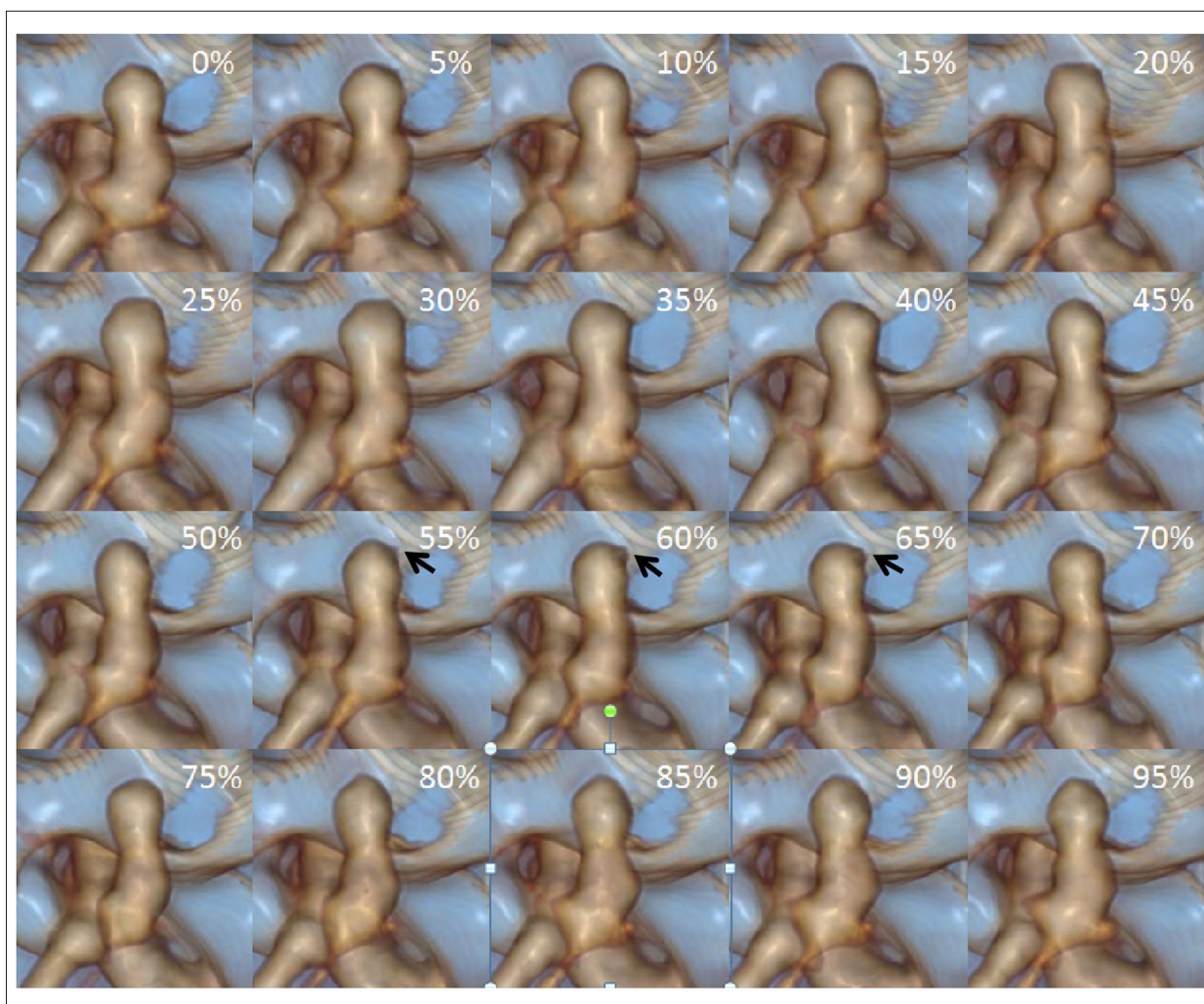
was the average diameter of all vessels connected to the aneurysm, i.e.,  $(c1+c2+c3...cn)/n$  [16] (Figure 1). The diameter of the parent aneurysm was the largest diameter of the parent artery near the aneurysm neck within 5 mm.

The pulsation point of the aneurysm was the small vesicle-like or pointed protrusions located at the same place in the aneurysm, observed in 3 or more consecutive images among the 20 dynamic images of a cardiac cycle (Figure 2).

Each aneurysm image was observed and measured by 2 neuroimaging physicians with 13 years and 25 years of working experience, respectively. The average of the 2 measurements was used for the analyses.

### Statistical analyses

Statistical analyses were performed by SPSS 16.0 software. The measurements with normal distribution are shown as  $\text{means} \pm \text{SD}$ . The independent-sample *t* test was used to compare the 2 groups of aneurysms. The chi-squared test was used to analyze the frequency data between the 2 groups. Based on the results of univariate analysis, the statistically significant variables between the 2 groups were screened and further



**Figure 2.** A 48-year-old female in the ruptured group with an anterior communicating aneurysm. 0% to 95% represents 20 phases in the 4D-CTA. In these 20 dynamic images, the pulsation point at the bottom of the aneurysm was observed in 3 consecutive images at 55%, 60%, and 65% (black arrow). The ratio of the aneurysm height to the diameter of the parent artery was 2.6.

analyzed via multivariate logistic regression. Multivariate logistic regression with the forward mode, using  $\alpha=0.05$  as the test level, was utilized to calculate the odds ratio (OR) and its 95% confidence interval (CI).  $P<0.05$  indicated statistically significant differences.

## Results

### Image and dose of radioactive reagent

The CT dose (CTDI vol) was  $11.8\pm 2.0$  mGy and the DLP was  $122\pm 19$  mGy $\times$ cm. The ED used was  $0.3\pm 0.1$  mSv.

### Characteristics of small aneurysms in the ruptured group and unruptured group

Univariate analysis showed that female sex, smoking history, growth at the bifurcation point, pulsation point, AR, and SR presented statistically significant differences between the 2 groups ( $P<0.05$ ), while age, height, blood pressure, type 2 diabetes, family history, multiple aneurysm history, drinking history, location, size, aneurysm neck, and aneurysm height were not significantly different between the 2 groups ( $P>0.05$ ) (Table 1).

Multivariate regression analysis of significantly different variables revealed that the existence of a pulsation point (OR=8.188, 95% CI: 3.984–17.198) and a larger SR value (OR=5.325, 95% CI: 1.503–18.867) were 2 independent predictive values (Figures 2, 3) for the rupture of aneurysms (Table 2).

**Table 1.** Characteristics of intracranial asymptomatic small aneurysms between ruptured group and unruptured group.

Characteristic (n = 168)	Ruptured group (n=102)	Unruptured group (n=66)	P value
Age, mean±SD, y	58±10	55±12	0.057
Sex, n (%)			0.036
Male	33 (32.4)	32 (48.5)	
Female	69 (67.6)	34 (51.5)	
Hypertension, n (%)	62 (60.8)	33 (50.0)	0.168
Type 2 diabetes mellitus, n (%)	36 (35.3)	26 (39.4)	0.591
History of smoking, n (%)	59 (57.8)	22 (33.3)	0.002
Family history, n (%)	26 (25.5)	13 (19.7)	0.385
Multiple aneurysms, n (%)	17 (16.7)	8 (12.1)	0.419
Drinking history, n (%)	51 (50.0)	28 (42.4)	0.337
Location, n (%)			0.950
Posterior communicating artery, n	25 (24.5)	14 (21.2)	
Middle cerebral artery, n	22 (21.6)	15 (22.7)	
Anterior communicating artery, n	27 (26.5)	19 (28.8)	
Internal carotid artery, n	16 (15.7)	12 (18.2)	
Basilar artery, n	12 (11.8)	6 (9.1)	
Vascular bifurcation point, n	72 (70.6)	34 (51.5)	0.012
Pulsation point appearance, n	86 (84.3)	23 (34.8)	0.001
Aneurysm size, mean±SD, mm	4.27±1.37	4.17±1.42	0.653
Aneurysm neck, mean±SD, mm	2.50±0.87	2.66±0.80	0.224
Aneurysm height, mean±SD, mm	4.26±1.38	4.15±1.44	0.615
AR, mean±SD, mm	1.78±0.41	1.60±0.45	0.010
SR, mean±SD, mm	1.76±0.35	1.57±0.24	0.001

Smoking history refers to smoking  $\geq 1$  per day, and continuous smoking  $\geq$  half a year. Drinking history refers to the average weekly drinking of liquor  $\geq 150$  g or beer  $\geq 1500$  g l the last 3 years. AR – aspect ratio; SR – size ratio.

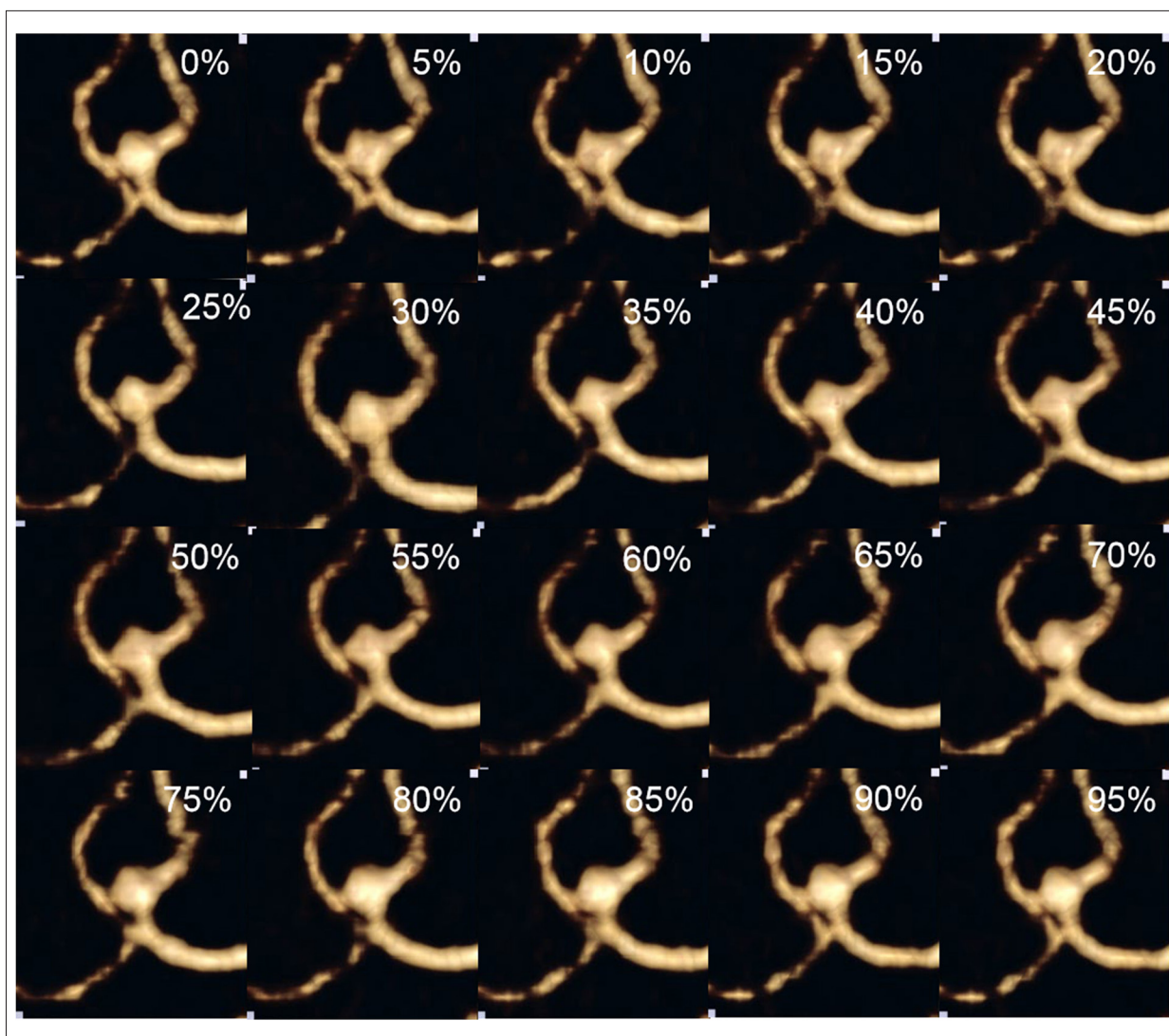
Further analysis of the SR value based on the ROC curve revealed that the area under the curve was 0.723. When the SR value was  $>1.65$ , the sensitivity for diagnosing the risk of small aneurysm rupture was 75%, with a diagnostic specificity of 80%.

## Discussion

Currently, no economically and clinically effective method has been identified to predict the risk of an intracranial aneurysm rupture, especially for small aneurysms with diameters  $<7$  mm, which are often diagnosed incidentally, without symptoms. A study in a Japanese population showed that small aneurysms accounted for 30% of all ruptured aneurysms [17].

Morphology has provided an important basis on which to study the risk of aneurysm rupture, but most CTA studies of aneurysm morphology have been based on static data generated by 3D-CTA. Because the blood in the aneurysm moves and changes along with the systolic and diastolic heartbeats, it may be more useful to dynamically investigate the morphological changes of intracranial aneurysms. Unlike 3D-CTA, ECG-gated 4D-CTA can observe morphological changes in aneurysms within a cardiac cycle. However, few studies have used 4D-CTA to monitor intracranial aneurysms [18–21], and no research has been conducted on the risk of intracranial asymptomatic small aneurysm rupture.

Through the ECG-gated 4D-CTA scans of intracranial asymptomatic unruptured small aneurysms, the present study found that the existence of aneurysm pulsation points and an SR



**Figure 3.** A 69-year-old male in the unruptured group with an anterior communicating aneurysm. 0% to 95% represents 20 phases in the 4D-CTA. In these 20 dynamic images, no pulsation point was observed and the ratio of the aneurysm height to the diameter of the parent artery was 1.3.

**Table 2.** Analysis of risk factors for asymptomatic small aneurysm rupture in multivariable logistic regression.

Variable	B	OR (95% CI)	P value
Pulsation point appearance	2.103	8.188 (3.898~17.198)	0.001
SR	1.672	5.325 (1.503~18.867)	0.010

OR – odds ratio; SR – size ratio.

value >1.65 were independent predictive factors for the rupture risk of asymptomatic small aneurysms with diameters <7 mm.

The pulsation point in a cardiac cycle is a morphological indicator that reflects the dynamic change of an aneurysm at a weak point in the aneurysm wall. Degenerative wall remodeling and inflammatory and non-physiological hemodynamics

of the aneurysm wall have been shown to be associated with ruptured intracranial aneurysms [22,23]. The blood flow pattern within the aneurysm is varied and complex and generates different shear forces and pressures on the aneurysm wall. These unbalanced and persistent hemodynamic abnormalities lead to a variety of vascular remodeling forms, such as endothelial cell damage, smooth muscle cell migration and disorder, and

inflammatory cell infiltration, resulting in weak areas in the wall of aneurysms, which will appear in the diastolic cardiac phase as bulging in the aneurysm, called the pulsation point. The long-term effects of the combined forces eventually lead to rupture of the wall at the pulsation point. In this study, there were significantly more pulsation points in the ruptured group than in the unruptured group, and there was an independent predictive value for the risk of aneurysm rupture in multivariate analysis. In our opinion, in the ruptured group, the rupture locations of the aneurysms were at the weakest parts of the aneurysm walls. After an aneurysm ruptures, a small blood clot can adhere to the rupture spot. Although the blood clot could temporarily protect the ruptured spot, it is weaker than the other parts of the wall. As blood moves through the aneurysm, a pulsation point forms at the blood clot. A ruptured aneurysm without a pulsation point might be caused by the formation of a large blood clot or a thrombus in the rupture. When the pressure induced by the large blood clot on the wall of an aneurysm is equal to the combined shear force and pressure induced by blood flow, no pulsation point is formed. We attributed small unruptured aneurysms to those whose walls that had not been weakened by the combined force of blood flow; therefore, no pulsation point was formed. Conversely, small unruptured aneurysms with pulsation points might identify small aneurysms at a risk for rupture. We concluded from an earlier follow-up study on the rupture risk of aneurysms that unruptured aneurysms with pulsation points represented high risks of rupture. For these types of aneurysms, early risk warning could facilitate critically-needed early treatment [14].

The SR value is an indicator of the relationship between the size of an intracranial aneurysm and the peripheral blood vessels. This study found that SR was an independent predictive factor for the rupture risk of small aneurysms. The greater the SR value, the greater the risk of rupture. The reason may be that under the same intravascular pressure, the wall pressure of smaller blood vessels is higher and an increase in wall pressure may lead to the formation of an aneurysm or even rupture. Some studies found that aneurysms with similar sizes but smaller parent vessels were more likely to rupture [24–26]. A prospective study from Japan [27] discovered that the rupture risk of small aneurysms was not significantly correlated with its size and location, but was closely related to

the SR value. The greater the SR value, the higher the rupture risk, which was consistent with our results. Due to the different inclusion criteria used by Chinese and international studies, there is no uniform standard for the diagnostic threshold of SR. In this study, the diagnostic threshold of SR was 1.65.

In addition, univariate analysis of AR, female sex, smoking, and growth at the bifurcation showed a correlation with the rupture of intracranial asymptomatic small aneurysms, whereas multivariate analysis showed that these factors were not independent predictive factors. These results indicated that factors such as age, sex, and AR value were not good predictive factors for the rupture risk of intracranial asymptomatic small aneurysms or that the correlation between them was not strong. Specifically, in comparison with predictive values of pulsation point and SR, these values were clearly weaker.

There are limitations to this study. First, the inclusion criteria for aneurysms excluded vasospasm, since it is too difficult to evaluate with the naked eye. This may have added some errors into the study. Second, this study did not include a comparison of hemodynamics. Third, this study was based on the data collected in a single medical center and only ruptured and unruptured aneurysms were compared. Since the morphology of an aneurysm can change after rupture, our results could be biased. In addition, our sample size was small. In the future, we may conduct additional studies with expanded sample sizes.

## Conclusions

In summary, the existence of pulsation points and SR value  $>1.65$  were identified as independent predictive factors for the rupture risk of intracranial asymptomatic small aneurysms with diameters  $<7$  mm. Furthermore, the results highlighted the importance of evaluating the rupture risk of aneurysms. Studies with large sample sizes and multiple centers are needed for further joint research on dynamic CTA images, hemodynamics, and histopathology.

## Conflicts of interest

None.

## References:

1. Thompson BG, Brown RD Jr, Amin-Hanjani S et al: Guidelines for the management of patients with unruptured intracranial aneurysms: A Guideline for healthcare professionals from the American Heart Association/American Stroke Association. *Stroke*, 2015; 46: 2368–400
2. Wiebers DO, Whisnant JP, Huston J 3<sup>rd</sup> et al: Unruptured intracranial aneurysms: Natural history, clinical outcome, and risks of surgical and endovascular treatment. *Lancet*, 2003; 362: 103–10
3. Chien A, Liang F, Sayre J et al: Enlargement of small, asymptomatic, unruptured intracranial aneurysms in patients with no history of subarachnoid hemorrhage: The different factors related to the growth of single and multiple aneurysms. *J Neurosurg*, 2013; 119: 190–97
4. Korja M, Lehto H, Juvela S: Lifelong rupture risk of intracranial aneurysms depends on risk factors: A prospective finnish cohort study. *Stroke*, 2014; 45: 1958–63
5. Connolly ES Jr, Rabinstein AA, Carhuapoma JR et al: Guidelines for the management of aneurysmal subarachnoid hemorrhage: A guideline for healthcare professionals from the American Heart Association/American Stroke Association. *Stroke*, 2012; 43: 1711–37
6. Juvela S, Porras M, Poussa K: Natural history of unruptured intracranial aneurysms: Probability of and risk factors for aneurysm rupture. *J Neurosurg*, 2008; 108: 1052–60
7. Broderick JP, Brown RD Jr, Sauerbeck L et al: Greater rupture risk for familial as compared to sporadic unruptured intracranial aneurysms. *Stroke*, 2009; 40: 1952–57
8. Sonobe M, Yamazaki T, Yonekura M et al: Small unruptured intracranial aneurysm verification study: SUAVE study, Japan. *Stroke*, 2010; 41: 1969–77
9. Feng X, Wang L, Guo E et al: Passive smoking is not associated with risk of intracranial aneurysm rupture in non-smoking women. *World Neurosurg*, 2017; 107: 716–23
10. Kleinloog R, de Mul N, Verweij BH et al: Risk factors for intracranial aneurysm rupture: A systematic review. *Neurosurgery*, 2018; 82: 431–40
11. Juvela S, Korja M: Intracranial aneurysm parameters for predicting a future subarachnoid hemorrhage: A long-term follow-up study. *Neurosurgery*, 2017; 81: 432–40
12. Hao M, Ma J, Huang Q et al: Morphological parameters of digital subtraction angiography 2D image in rupture risk profile of small intracranial aneurysms: A pilot study. *J Neurol Surg A Cent Eur Neurosurg*, 2016; 77: 25–30
13. Mehan WA Jr, Romero JM, Hirsch JA et al: Unruptured intracranial aneurysms conservatively followed with serial CT angiography: Could morphology and growth predict rupture? *J Neurointerv Surg*, 2014; 6: 761–66
14. Gu Y, Xu L, Hu CH et al: Monitoring dynamic morphological changes with ECG-gated 4D-CTA to predict intraoperative rupture of intracranial aneurysms. *J Comput Assist Tomogr*, 2018; 42: 286–92
15. Costello JE, Cecava ND, Tucker JE et al: CT radiation dose: Current controversies and dose reduction strategies. *Am J Roentgenol*, 2013; 201: 1283–90
16. Rahman M, Smietana J, Hauck E et al: Size ratio correlates with intracranial aneurysm rupture status: A prospective study. *Stroke*, 2010; 41: 916–20
17. Kassell NF, Torner JC: Size of intracranial aneurysms. *Neurosurgery*, 1983; 12: 291–97
18. Hayakawa M, Katada K, Anno H et al: CT angiography with electrocardiographically gated reconstruction for visualizing pulsation of intracranial aneurysms: Identification of aneurysmal protuberance presumably associated with wall thinning. *Am J Neuroradiol*, 2005; 26: 1366–69
19. Hayakawa M, Maeda S, Sadato A et al: Detection of pulsation in ruptured and unruptured cerebral aneurysms by electrocardiographically gated 3 dimensional computed tomographic angiography with a 320-row area detector computed tomography and evaluation of its clinical usefulness. *Neurosurgery*, 2011; 69: 843–51
20. Hayakawa M, Tanaka T, Sadato A et al: Detection of pulsation in unruptured cerebral aneurysms by ECG-gated 3D-CT angiography (4D-CTA) with 320-row area detector CT (ADCT) and follow-up evaluation results: Assessment based on heart rate at the time of scanning. *Clin Neuroradiol*, 2014; 24: 145–50
21. Gu Y, Zhang YG, Luo M et al: Dynamic volume change rate and aspect ratio are correlated to the formation of an irregular morphology of unruptured intracranial aneurysms. *J Comput Assist Tomogr*, 2019; 43: 294–99
22. Cebal J, Ollikainen E, Chung BJ et al: Flow conditions in the intracranial aneurysm lumen are associated with inflammation and degenerative changes of the aneurysm wall. *Am J Neuroradiol*, 2017; 38: 119–26
23. Meng H, Tutino VM, Xiang J et al: High WSS or low WSS? Complex interactions of hemodynamics with intracranial aneurysm initiation, growth, and rupture: Toward a unifying hypothesis. *Am J Neuroradiol*, 2014; 35: 1254–62
24. Hoffman H, Toshkezi G, Swarnkar A et al: A retrospective comparison of sac and lobe morphology between ruptured and unruptured intracranial aneurysms. *J Clin Neurosci*, 2019; 60: 88–92
25. Wang GX, Liu J, Chen YQ et al: Morphological characteristics associated with the rupture risk of mirror posterior communicating artery aneurysms. *J Neurointerv Surg*, 2018; 10: 995–98
26. Futami K, Nambu I, Kitabayashi T et al: Inflow hemodynamics evaluated by using four-dimensional flow magnetic resonance imaging and the size ratio of unruptured cerebral aneurysms. *Neuroradiology*, 2017; 59: 411–18
27. Kashiwazaki D, Kuroda S: Size ratio can highly predict rupture risk in intracranial small (<5 mm) aneurysms. *Stroke*, 2013; 44: 2169–73