

CASE REPORT

Pneumococcal pulmonary valve endocarditis

Apostolos Vrettos¹, Paula Mota¹, James Nash², Iain Thorp³, Max Baghai⁴ and Adam Marzetti³

¹Cardiology, East Kent Hospitals University NHS Foundation Trust, William Harvey Hospital, Ashford, UK

²Microbiology, East Kent Hospitals University NHS Foundation Trust, William Harvey Hospital, Ashford, UK

³Echocardiography, East Kent Hospitals University NHS Foundation Trust, William Harvey Hospital, Ashford, UK

⁴Cardiothoracic Surgery, King's College London School of Medical Education, London, UK

Correspondence should be addressed to A Vrettos

Email
dr.vrettos@hotmail.com

Summary

Pulmonary valve endocarditis is a rare type of infective endocarditis (IE). *Streptococcus pneumoniae* is a pathogen that is uncommonly associated with IE. A 50 year-old male was referred to us after an incidental echocardiographic finding of a pulmonary valve vegetation. The patient had a recent admission for drainage of a scrotal abscess from which *S. pneumoniae* was isolated, complicated by hospital acquired pneumonia and pulmonary embolism. Analysis using polymerase chain reaction of the surgically resected mass revealed signs of 16S ribosomal DNA consistent with *S. pneumoniae* infection. This was an extremely rare case of pneumococcal pulmonary valve IE presenting entirely asymptotically in the absence of any known risk factors.

Key Words

- ▶ pulmonary valve
- ▶ endocarditis
- ▶ *Streptococcus pneumoniae*

Learning points:

- *Streptococcus pneumoniae* endocarditis can present with very few symptoms or even entirely asymptotically, as in this case.
- Pulmonary valve endocarditis can affect healthy patients, even in the absence of any known predisposing risk factors or pre-existing heart conditions.
- An echocardiogram may be considered following severe infection with sepsis by pneumococci, to screen for vegetations that could evolve silently over the following weeks.

Background

This report describes a case of pulmonary valve endocarditis due to *Streptococcus pneumoniae*, presenting entirely asymptotically in a healthy individual. This case carries significant educational messages and promotes clinical knowledge and diagnostic reasoning by:

- Presenting a case that is unique.
- Clearly presenting our dilemmas and clinical questions in this rare case of infective endocarditis, for the management of which there is no clear guidance.

- Relating echocardiographic images with high-quality intra-operative images of the vegetation and the perforated pulmonary valve cusp causing significant regurgitation.

Case presentation

A 50 year-old male was referred to the Cardiology Department as a suspected case of endocarditis after the

incidental finding of an echogenic mass on the pulmonary valve seen in an outpatient echocardiogram (Fig. 1). This patient had presented three months prior to this admission with pain and swelling in the left testicle for 4 days, which was confirmed to be an epididymo-orchitis on an ultrasound scan and was treated with oral ciprofloxacin for 10 days, anti-inflammatories and scrotal support. About two weeks later, the patient re-presented with fever and rigors, persistent testicular pain and swelling. Exploration revealed a left hemiscrotal abscess, which was drained and *S. pneumoniae* was isolated from the pus. Moreover, a urine antigen test was positive for *S. pneumoniae* antigen. The patient was treated as an inpatient with clindamycin IV for 8 days and ciprofloxacin orally for another 6 days. Repeated blood cultures came back as negative. This admission was further complicated by a left lower lobe pneumonia and bilateral pulmonary emboli (Fig. 2), which was treated with levofloxacin, tazocin and meropenem IV. The patient was also started on rivaroxaban 20 mg daily in consultation with the respiratory team.

Investigation

An echocardiogram revealed mild pericardial effusion, with a maximum depth of 18 mm around the left ventricular posterior wall (Fig. 2). A repeat echocardiogram about one week later showed some improvement in the pericardial effusion, with a greatest maximum depth of 14 mm. Both scans did not show any vegetations. The patient recovered fully and was discharged home with an outpatient follow-up echocardiogram. Six weeks later, the follow-up echocardiogram revealed a suspicious

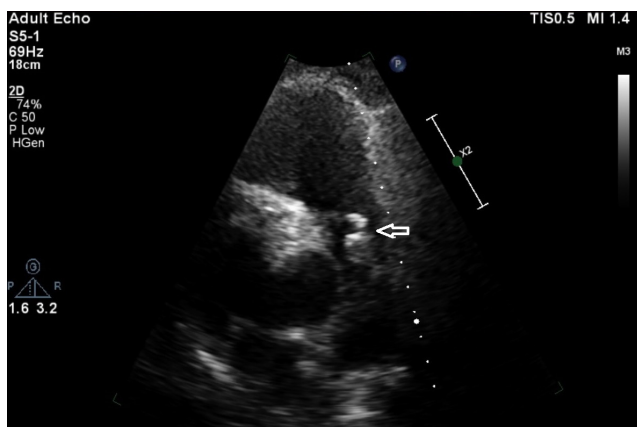


Figure 1
An echogenic mass on the pulmonary valve seen in the outpatient echocardiogram.

echogenic mass, which was very mobile and appeared to be attached to the pulmonary valve causing turbulent flow and flow acceleration (Fig. 1). It was 21.4×18 mm in largest dimensions. This finding warranted admission for suspected pulmonary valve endocarditis (PVE). There was no history of congenital heart disease, valvulopathy or previous infective endocarditis, and no risk factors of immunosuppression. On examination, the patient was completely asymptomatic, with no fever, night sweats or any other constitutional symptoms. There were no stigmata of infective endocarditis. All observations were normal, and there was no evidence of sepsis. The patient's latest blood tests showed a hemoglobin of 119 g/L, white cell count of 6.3×10⁹/L, neutrophils of 3.50×10⁹/L and a CRP of 21 mg/L. Urea, electrolytes and the liver function tests were within normal limits. Repeated blood cultures came back as negative. Additional tests for the HACEK micro-organisms as well as serology for Q-fever, Bartonella and Whipple's disease were requested, which all came back as negative. The patient also tested negative for HIV infection. A repeat CT pulmonary angiogram did not reveal any new pulmonary emboli and showed partial resolution of the previously identified ones. In view of the typical appearance of the vegetation on the echocardiogram, as well as the presence of pulmonary arterial emboli, we decided that it was very likely that this was a case of infective endocarditis causing septic emboli. Therefore, the patient was started on amoxicillin and gentamicin IV as per local microbiology protocol. The patient was then transferred to a tertiary cardiothoracic center where the patient underwent a transoesophageal echocardiogram (TOE) and then surgical resection of the mass. The TOE showed a severely deformed pulmonary valve with a large vegetation attached on the valve and severe pulmonary regurgitation (Fig. 3). Intraoperatively, the pulmonary valve was destroyed with a large vegetation attached to it and a perforated left pulmonary valve cusp causing severe regurgitation was also revealed (Fig. 4).

Treatment and outcome

A 25 mm stentless bioprosthesis was implanted in the pulmonary position. The procedure was uneventful and a post-operative TOE did not show any regurgitation. Valve cultures came back as negative but polymerase chain reaction showed signs of 16S ribosomal DNA (rDNA) consistent with *S. pneumoniae* infection. The patient made a good recovery and was discharged home on IV antibiotics: cefuroxime 2 g IV for 2 weeks post discharge.

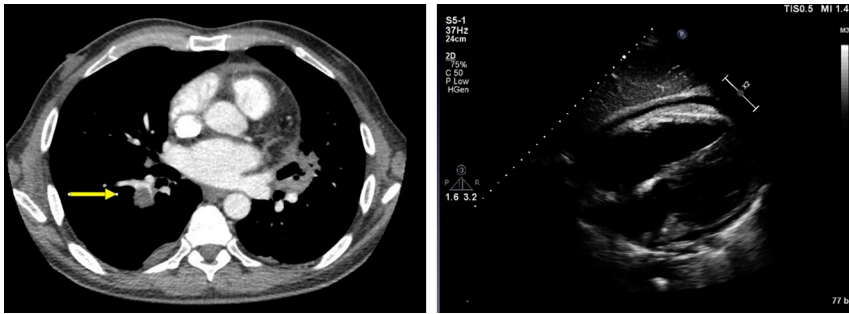


Figure 2
Pulmonary embolism on CTPA (left). Pericardial effusion around the left ventricular posterior wall (right).

Discussion

This is a rare case of PVE with a very uncommon clinical course and causative organism. There are many puzzling features that challenged our diagnostic reasoning, such as:

- What was the entry point of the organism? Potential entry sites could have been: the testicular abscess, the venous access used for IV antibiotics or a pneumonia causing chest sepsis.
- Whether pneumonia was primary or secondary to septic emboli.
- Whether there were any concomitant thrombotic emboli; the repeat CT pulmonary angiogram did not identify any further emboli, but the patient had already been started on rivaroxaban following the first episode of bilateral pulmonary embolism; however, the fact that there were still residual vascular occlusive images six weeks later might suggest vegetation material.
- Why the vegetation appears to have grown, while the patient was afebrile, having been treated with microbiology guided antibiotics?
- Whether the potential embolic risk of such large vegetation was important enough to warrant surgical intervention in the absence of signs of infection.
- Could we be certain of having achieved full sterilization of the vegetation? Should we restart antibiotics in an asymptomatic male with no evidence of infection?

In the first two admissions due to epididymo-orchitis, there was nothing to suggest the presence of infective endocarditis clinically, as well as in the two inpatient echocardiograms (done after the development of pulmonary emboli), which only showed some pericardial effusion. Cultures from the testicular abscess as well as a urine antigen test, revealed infection with *S. pneumoniae*, which is a rare causative organism of epididymo-orchitis (1). The patient's course was complicated by chest sepsis, but no causative organism was identified in his blood and sputum cultures. Infective endocarditis was suspected following the incidental finding of a large vegetation on an outpatient echocardiogram six weeks later, which had been arranged in order to monitor for the resolution of the pericardial effusion and also based on the history of bilateral pulmonary emboli. Clinically, the patient was completely asymptomatic. According to the modified Duke's criteria, at this point in time, the patient fulfilled 1 major (positive echocardiogram) and one minor (septic pulmonary infarcts) criteria. This classified as a possible case of infective endocarditis. We felt that the multiple and prolonged courses of IV and oral antibiotics received for the epididymo-orchitis and chest sepsis could have contributed to partial sterilization of the vegetation, the lack of systemic symptoms and the repeated negative blood cultures. We decided to commence treatment for infective endocarditis pending further discussion with the cardiothoracic surgeons with a view to obtaining a biopsy of the mass in order to establish a definite diagnosis. In

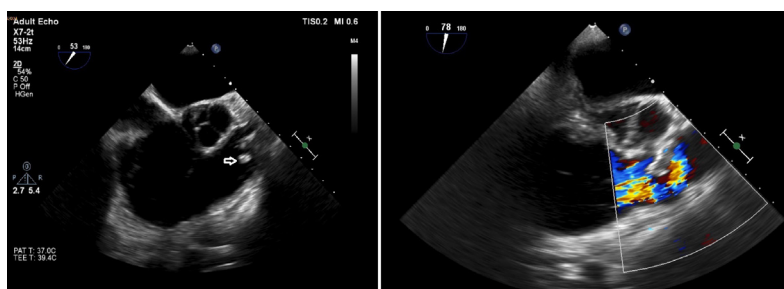


Figure 3
TOE echo showing disruption of the architecture of the pulmonary valve and a swinging vegetation attached to it (left). Pulmonary valve regurgitation was also demonstrated (right).

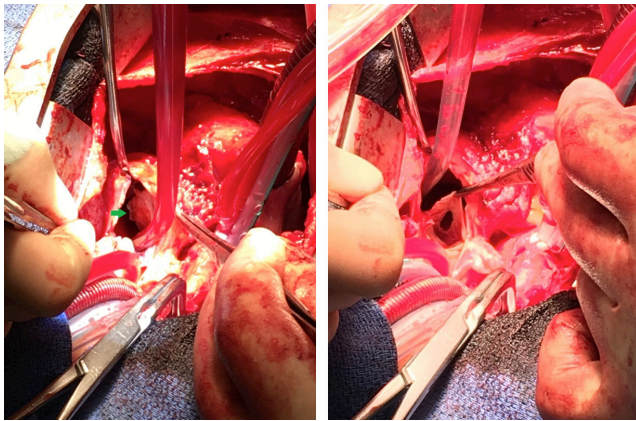


Figure 4
Intraoperative photograph of gross surgical findings demonstrating the large vegetation (arrow) attached to the pulmonary valve (left).
Intraoperative photograph showing a perforated left pulmonary valve cusp (right).

view of the size of the vegetation, the embolic risk had to be considered. The ESC guidelines for the management of infective endocarditis do not clearly state the role of surgery when the pulmonary valve is infected (2). After discussion with our cardiothoracic surgical colleagues, it was decided to proceed with urgent inpatient surgical resection of the mass. The results from the histological analysis of the sample confirmed the presence of infective endocarditis. Interestingly, the PCR analysis of the valve tissue revealed *S. pneumoniae* 16S rDNA, which was the same causative organism as the one identified in the scrotal pus and the one that was suggested from the positive urine antigen test. With that evidence, the patient now fulfilled the Duke's criteria of infective endocarditis.

The entry point of the offending organism was another puzzling feature in this case. Although the scrotal abscess could potentially be the entry point of the infection, there has never been a report of streptococcal endocarditis secondary to testicular infection. Primary pneumococcal orchitis is also extremely rare. In fact, during the course of pneumococcal septicemia due to endocarditis, bacteria may reach many sites where they can multiply and produce purulent lesions. Pneumococcal arthritis, vertebral osteomyelitis, ophthalmitis and orchitis may be produced this way (1). However, in our case, there was no evidence of endocarditis at the time of the first illness due to epididymo-orchitis (the patient had 2 inpatient echocardiograms, which did not reveal any obvious vegetations). Right-sided infective endocarditis presenting with systemic illness and testicular swelling, orchitis and pulmonary emboli due to *Staphylococcus aureus* tricuspid endocarditis has been reported once (3), but there are

no reports of a similar presentation of a pneumococcal PVE. Our study is the only one linking orchitis with pneumococcal PVE. *S. pneumoniae* is a very rare causative organism of infective endocarditis (4), and in the majority of the cases, there is some underlying condition predisposing to infective endocarditis; this was unlikely in our case, as the patient had no known risk factors. Secondly, PVE is also very rare and typically occurs in 1.5–2% of patients hospitalized with IE (5). It is usually associated with simultaneous involvement of other valves (6), commonly in the context of an underlying structural heart disease. A total of 70 cases of isolated PVE have been reported between 1979 and 2013 (6). Clinical manifestations of PVE commonly affect the respiratory system owing to pulmonary septic embolization. Intravenous drug abuse, alcoholism, sepsis, immunosuppression and catheter-related infections or other unique aetiologies account for the majority of predisposing factors, as well as infection with *Neisseria gonorrhoea* which appears to have a particular affinity for the pulmonary valve (7, 8, 9, 10). Pulmonary valve endocarditis in structurally normal hearts, as in this patient, is an extremely rare entity.

Right-sided IE usually involves the tricuspid valve rather than the pulmonary valve (11). This is possibly due to the lower pressure gradient across the pulmonary valve that leads to less shear stress (7), therefore causing less valvular damage. The clinical course of PVE tends to be less typical than that of left-sided IE and the final diagnosis of PVE may be delayed. Typical signs of IE may be absent as in this case, but in the majority of the cases, the patients present with symptoms and signs of sepsis. Four to six weeks of intravenous antibiotics are the primary mode of treatment. Abscess formation, valve obstruction or severe regurgitation, large vegetations at risk of emboli formation and persistence of the infection despite antibiotic treatment would warrant surgery (12). Surgery for PVE is recommended in patients with persisting vegetations >10mm after one or more clinical or silent embolic events despite appropriate antibiotic treatment, although it is generally not advisable in the IVUD population (12). Surgery undertaken for the prevention of embolism must be performed very early, during the first few days following initiation of antibiotic therapy, as the risk of embolism is highest at this time (13). As with all right-sided IE, PVE has a better prognosis than left-sided IE and most of the cases respond well to appropriate antibiotic therapy (14).

In conclusion, this is the first confirmed case of pneumococcal pulmonary valve endocarditis, following pneumococcal orchitis, presenting entirely

asymptotically in the absence of any known predisposing risk factors. An extensive literature review could not identify any similar case. It suggests that an echocardiogram may be recommended following severe infection with sepsis by pneumococci, to screen for vegetations that could evolve silently over the following weeks.

Declaration of interest

The authors declare that there is no conflict of interest that could be perceived as prejudicing the impartiality of this case report.

Funding

This research did not receive any specific grant from any funding agency in the public, commercial or not-for-profit sector.

Patient consent

Written informed consent has been obtained from the patient.

Author contribution statement

Dr Apostolos Vrettos performed a literature review and wrote up the case. Dr Paula Mota, Dr James Nash, Iain Thorp, Max Baghai and Adam Marzetti assisted with the literature review and provided expert input on their relevant fields (Cardiology, Microbiology, Echocardiography and Cardiac Surgery).

References

- 1 Cox T, Warrell D & Firth J 2003 *Oxford Textbook of Medicine*, vol 1, p 468. Oxford, UK: Oxford University Press.
- 2 Habib G, Lancellotti P, Antunes MJ, Bongiorni MG, Casalta JP, Del Zotti F, Dulgheru R, El Khoury G, Erba PA, Iung B, *et al.* 2015 2015 ESC Guidelines for the management of infective endocarditis: the task force for the management of infective endocarditis of the European Society of Cardiology (ESC). Endorsed by: European Association for Cardio-Thoracic Surgery (EACTS), the European Association of Nuclear Medicine (EANM). *European Heart Journal* **36** 3075–3128. (doi:10.1093/eurheartj/ehv319)
- 3 Nandakumar R & Raju G 1997 Isolated tricuspid valve endocarditis in non-addicted patients: a diagnostic challenge. *American Journal of Medical Sciences* **314** 207–212. (doi:10.1016/s0002-9629(15)40196-x)
- 4 Aronin SI, Mukherjee SK, West JC & Cooney EL 1998 Review of pneumococcal endocarditis in adults in the penicillin era. *Clinical Infectious Diseases* **26** 165–171. (doi:10.1086/516279)
- 5 Cassling RS, Rogler WC & McManus BM 1985 Isolated pulmonic valve infective endocarditis: a diagnostically elusive entity. *American Heart Journal* **109** 558–567. (doi:10.1016/0002-8703(85)90563-0)
- 6 Chowdhury MA & Moukarbel GV 2016 Isolated pulmonary valve endocarditis. *Cardiology* **133** 79–82. (doi:10.1159/000440857)
- 7 Tekin R, Acet H & Ertas F 2012 An unusual case of endocarditis: isolated pulmonary valve endocarditis in patient with patent ductus arteriosus. *Journal of Medical Cases* **3** 340–343. (doi:10.4021/jmc600w)
- 8 Glew T, Feliciano M, Finkielstein D, *et al.* 2015 Pulmonic valve repair in a patient with isolated pulmonic valve endocarditis and sickle cell disease. *Case Reports in Cardiology* **2015** 732073. (doi:10.1155/2015/732073)
- 9 Nishanth KR, Seshadri S, Pandit V & Krishnanand N 2013 Isolated pulmonary valve endocarditis in a patient with aplastic anaemia. *BMJ Case Reports* **2013** bcr2013008769. (doi:10.1136/bcr-2013-008769)
- 10 Schroeder RA 2005 Pulmonic valve endocarditis in a normal heart. *Journal of the American Society of Echocardiography* **18** 197–198. (doi:10.1016/j.echo.2004.08.006)
- 11 Frontera JA & Gradon JD 2000 Right-side endocarditis in injection drug users: review of proposed mechanisms of pathogenesis. *Clinical Infectious Diseases* **30** 374–379. (doi:10.1086/313664)
- 12 Nishimura RA, Otto CM, Bonow RO, Carabello BA, Erwin JP 3rd, Guyton RA, O’Gara PT, Ruiz CE, Skubas NJ, Sorajja P, *et al.* 2014 2014 AHA/ACC Guideline for the management of patients with valvular heart disease: executive summary: a report of the American College of Cardiology/American Heart Association Task. *Circulation* **129** 2440–2492. (doi:10.1161/CIR.0000000000000029)
- 13 Thuny F, Di Salvo G, Belliard O, Avierinos JF, Pergola V, Rosenberg V, Casalta JP, Gouvenet J, Derumeaux G, Iarussi D, *et al.* 2005 Risk of embolism and death in infective endocarditis: prognostic value of echocardiography: a prospective multicenter study. *Circulation* **112** 69–75. (doi:10.1161/CIRCULATIONAHA.104.493155)
- 14 Edmond JJ, Eykyn SJ & Smith LD 2001 Community acquired staphylococcal pulmonary valve endocarditis in non-drug users: case report and review of the literature. *Heart* **86** E17. (doi:10.1136/heart.86.6.e17)

Received 30 May 2017

Accepted 20 June 2017

Accepted Preprint published online 20 June 2017