

## ORIGINAL RESEARCH

# The Impact of EndoAnchor Penetration on Endograft Structure: First Report of Explant Analysis

Jonathan Grandhomme<sup>a,b</sup>, Nabil Chakfe<sup>a,b</sup>, Arindam Chaudhuri<sup>a,c</sup>, Thomas R. Wyss<sup>d</sup>, Roberto Chiesa<sup>e</sup>, Julien Chakfe<sup>a</sup>, Delphine Dion<sup>a</sup>, Frédéric Heim<sup>f</sup>, Anne Lejay<sup>a,b,g,\*</sup>

<sup>a</sup> Groupe Européen de Recherche sur les Prothèses appliquées à la Chirurgie Vasculaire, Strasbourg, France

<sup>b</sup> Department of Vascular Surgery and Renal Transplantation, Nouvel Hôpital Civil, Strasbourg, France

<sup>c</sup> Department of Vascular Surgery, Bedford Hospital NHS Trust, Bedford, UK

<sup>d</sup> Department of Cardiovascular Surgery, Inselspital, Bern University Hospital, University of Bern, Bern, Switzerland

<sup>e</sup> Department of Vascular Surgery, University Vita-Salute, San Raffaele, Italy

<sup>f</sup> Université de Haute Alsace, Mulhouse, France

<sup>g</sup> Department of Physiology and Respiratory Functional Explorations, Nouvel Hôpital Civil, Strasbourg, France

**Objective:** The adjunctive use of Heli-FX EndoAnchors (EAs) in endovascular aneurysm repair has been proposed for the treatment or prevention of type Ia endoleaks. The aim of this study was to evaluate the impact of the penetration of EAs on endograft textile structure from two aortic endografts that had been explanted for persistent type Ia endoleak despite the implantation of EAs.

**Methods:** An Aorfix aortic endograft was implanted in an 85 year old man. Six months later, six EAs were implanted for Ia endoleak. The endograft was explanted as an emergency seven months later for aneurysm rupture. An Endurant II aortic endograft was implanted in an 80 year old man. Seven EAs were implanted 24 months later for type Ia endoleak. A proximal cuff extension with bilateral renal and superior mesenteric artery chimneys was performed 18 months later to treat a persistent type Ia endoleak. Endograft explantation was performed six months later owing to persistent type Ia endoleak and aneurysm sac enlargement. Explant analysis in both cases was performed at GEPROVAS.

**Results:** Systematic analysis of both explants, including the 13 EAs, revealed the following lesions: (1) alteration of textile structure directly linked to several penetrations of the fabric with the same EA and tears of the textile fibres in two cases; (2) tears of the binding threads as the EA had passed through them in five cases; and (3) interactions between EA and endograft stents in four cases.

**Conclusion:** The site of EA penetration into the endograft might contribute to endograft fabric damage and to a loss of stability of the endograft at the level of the aortic neck.

© 2020 The Author(s). Published by Elsevier Ltd on behalf of European Society for Vascular Surgery. This is an open access article under the CC BY-NC-ND license (<http://creativecommons.org/licenses/by-nc-nd/4.0/>).

Article history: Received 13 June 2020, Revised 19 July 2020, Accepted 14 August 2020,

**Keywords:** Abdominal, Aortic aneurysm, Endoleak, Endovascular procedures

## INTRODUCTION

Endovascular aortic aneurysm repair efficacy is known to be significantly linked to proximal sealing and fixation. This usually implies a sufficient neck length in order to avoid type Ia endoleak. Instructions for use (IFU) recommend at least 15 mm for most devices, although it can be decreased to 10 mm for some endograft models, such as the Endurant (Medtronic, Santa Rosa, CA, USA) or the Incraft (Cordis,

Baar, Switzerland) devices. Recently, the Endurant device IFU included primary adjunctive deployment of Heli-FX EndoAnchors (EAs) for short necks (4–10 mm), in order to obtain better device fixation.<sup>1</sup> The use of EAs has been shown to be feasible and safe, with at least comparable early outcomes to the latest generation of stent grafts.<sup>2,3</sup> However, the rate of type Ia endoleak after secondary fixation remains about 22.6% and adverse events include EA fractures, EA dislocation, or EA entrapment.<sup>2</sup> Moreover, current evidence lacks long term follow up and perhaps case controlled trials are recommended for EA use in routine practice, although this is already integrated in some.<sup>3,4</sup>

As the principle of the EA technique is penetration of the endograft structure with a screw, it seems right to assess the risk of a potential deleterious impact on the materials,

\* Corresponding author. Department of Vascular Surgery and Kidney Transplantation, Les Hôpitaux Universitaires de Strasbourg, B.P. 426, 67091 Strasbourg Cedex, France.

E-mail address: [anne.lejay@chru-strasbourg.fr](mailto:anne.lejay@chru-strasbourg.fr) (Anne Lejay).

2666-688X/© 2020 The Author(s). Published by Elsevier Ltd on behalf of European Society for Vascular Surgery. This is an open access article under the CC BY-NC-ND license (<http://creativecommons.org/licenses/by-nc-nd/4.0/>).

<https://doi.org/10.1016/j.ejvsf.2020.08.002>

in order to identify factors that could influence the long term stability of the devices that might lead to a failure or complications.

The aim of this study was to evaluate the impact of EA penetration on endograft textile structure from two aortic endografts that had been explanted for persistent type Ia endoleak, despite the implantation of EAs.

### Reports

The first case was of a 24 mm diameter Aorfix (Lombard, Didcot, UK) aortic endograft that was implanted in an 85 year old man for a 75 mm diameter abdominal aortic aneurysm (AAA) with 60° neck angulation. Computed tomography angiography (CTA) at six months revealed a type Ia endoleak with an increase in aneurysm sac diameter due to endograft proximal malapposition. Six EAs were implanted. Completion angiography did not show any residual type Ia endoleak. Seven months later, the patient presented with AAA rupture. The aortic wall was cut at the margins of the EAs and explantation of the proximal part of the endograft followed by an aortobi-iliac prosthetic bypass was performed as an emergency. The post-operative course was uneventful.

The second case was of a 25 mm proximal diameter Endurant II aortic endograft implanted in an 80 year old man with a 61 mm diameter AAA. Follow up CTA at 24 months revealed a type Ia endoleak with an increase in aneurysm sac diameter due to endograft malapposition. Seven EAs were implanted. Follow up CTA at 18 months showed recurrence of a type Ia endoleak with an increase in aneurysm sac diameter. A proximal cuff extension with bilateral renal and superior mesenteric artery chimneys was performed. Follow up CTA at six months showed persistence of the type Ia endoleak, with continued significant aneurysm sac enlargement. The aortic wall was cut at the margins of the EAs and explantation of the proximal part of the endograft with visceral arterial revascularisation and aorto-aortic bypass was performed. The post-operative course was uneventful.

After explantation, both specimens were sent to GEPROVAS, as a part of a European retrieval programme.

### RESULTS

After explantation, the specimens were submitted to a standardised protocol for evaluation ([Supplementary Material](#)) starting with naked eye examination followed by digital image capture (Nikon D5100, Nikon France, Champigny sur Marne, France). The specimens were then cleaned using a papaine based enzymatic cleaning process at 60°C, allowing complete digestion of the aortic wall. After cleaning, the specimens were rinsed using distilled water and additional pictures were taken with a Keyence VHX 600 digital microscope (Keyence France, Courbevoie, France).

The first case consisted in the bifurcated body of an endograft where six EAs had been implanted ([Fig. 1A](#)). Each EA was seen on the endograft and named from EA1 to EA6. The second case consisted of the bifurcated body of an

endograft where seven EAs had been implanted ([Fig. 1B](#)). Only four EAs were seen on the endograft; each EA was named from EA7 to EA10. Three EAs were detached during the cleaning process and the visible holes were designated H1, H2, and H3.

Observations made on each EA are reported in [Table 1](#). Three different types of interactions were observed: between EA and endograft fabric; between EA and ligature threads fixing the stents; and between EA and stents. Concerning EA—endograft fabric interactions, eight of the 10 EAs penetrated the fabric only once, while two EAs passed three and five times, respectively, through the fabric, because there were three and five holes, respectively, in the vicinity of the same single EA. Some fibre breakages and opening of the textile structure were observed ([Fig. 2A](#)). Concerning the interaction of the EAs and ligatures, four EAs passed through the stitches, creating thread dissociations and filament ruptures ([Fig. 2B](#)). Concerning EA—stent interactions, in three of the 10 cases the EAs penetrated close to the stent; in one case the EA made close contact with the external part of the stent and in one case an EA linked the suprarenal bare stent to the first stent of the first covered stent of the endograft ([Fig. 2C](#)). In this case, major wearing lesions on both the EAs and endograft stent were observed.

The three holes identified after cleaning demonstrated an enlargement of the textile structure and some partial rupture of the fibres, one of which showed alteration of a line of stitches ([Fig. 2D](#)).

### DISCUSSION

To the authors' knowledge this is the first report on explanted endografts, including EAs, and it was seen that the use of an EA could alter the structure of the endograft in different ways.

In the majority of cases, the EA penetrated the fabric far from the stents and the stitches with only one fabric penetration. The penetration, evaluated in degrees, showed variable penetration up to 810°. However, that the explantation could have modified this degree of penetration cannot be excluded. Interestingly, in two cases the EA passed three and five times through the fabric, respectively, meaning that the screw passed first through the fabric and did not immediately penetrate the arterial wall but re-entered the fabric from outside (once in one case and twice in the other case) before penetrating the arterial wall. This can potentially be explained by several mechanisms: slipping of the EA on the graft because of a lack of strength during the apposition of the delivery system; because of difficulties penetrating the arterial wall related to local factors such as calcification; or multiple attempts at deploying the EAs in the same area, as can happen.


However, when the EA was inserted close to particularly important structures, such as the stents and the ligature threads, it was found that these interactions could lead to structural lesions of the threads with rupture of filaments and of the stents with wearing lesions. This is particularly

true when the EA fixed the two crests of the stents together. Moreover, these interactions could lead to a concentration of stresses on areas that were initially independently mobile and able to absorb initial mobility that become closely linked. However, the long term effect of this cannot be hypothesised as expert users are aware that EAs sometimes brush past stent metal during deployment.

The EA IFU recommends distributing the EA implants as regularly as possible around the circumference of the sealing stent,<sup>1</sup> with recent recommendations to use columnar endostapling for hostile neck anatomy.<sup>3,5</sup> Even though the delivery system allows accurate placement, it may be difficult to know where exactly the tip of the screw will engage in terms of fabric and stent metal.



A



B






**Figure 1.** (A) First explant after cleaning, showing six EndoAnchors (EA; named EA1 – EA6) in place. (B) Second explant after cleaning, showing four EAs (named EA7 – EA10) in place and three holes (H1 – H3), as three EAs came off during the cleaning process.

**Table 1.** Macroscopic view (50×) of each EndoAnchor (EA; named EA1 – EA10); two holes (H1 and H2) left by EA detached during the cleaning process along with the characteristics of their path through the endograft and one lesion (L1).

Picture	Number of penetrations	Angle of penetration	Relation with stitches	Relation with stent
EA1 	1	630°	Passed through a thread	No contact
EA2 	5	540°	No contact	No contact
EA3 	1	540°	Passed through one thread	Penetrated close to the stent and in close contact on its external side
EA4 	1	540°	No contact	No contact
EA5 	3	810°	Passed through two thread	Linked to the stent by the suture thread
EA6 	1	540°	No contact	No contact
EA7 	1	270°	No contact	No contact
EA8 	1	540°	Passed through one thread	Penetrated at the contact of the stent and close connection with it

*Continued*

Table 1-continued

Picture	Number of penetrations	Angle of penetration	Relation with stitches	Relation with stent
EA9 	1	630°	No contact	In close contact to the suprarenal stent and first row of the endograft stent, signs of wearing on both stents and EA
EA10 	1	630°	No contact	No contact
H1 	1	-	No contact	
H2 	1	-	No contact	
H3 	1	-	Passed through one thread	Penetrated close to a stent

Consequently, the risk of penetrating the endograft structure close to the ligature threads and/or the stents is not negligible and can sometimes immediately result in maldeployment issues such as migration and on table EA fracture.

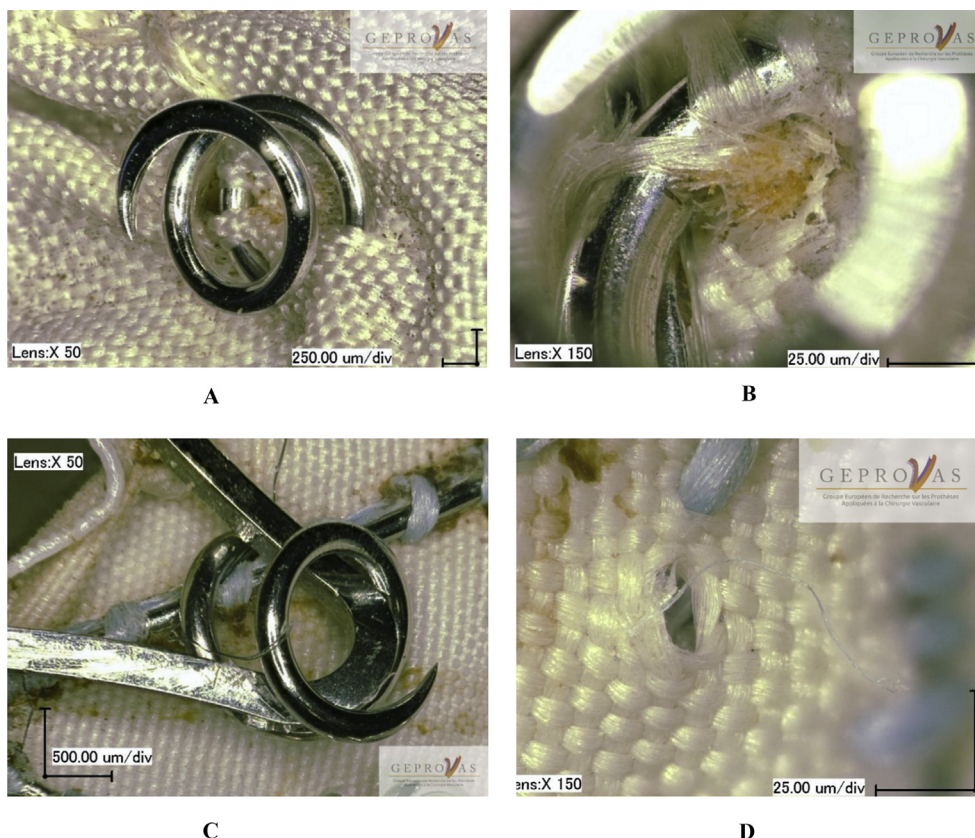
The observations showed that deleterious interactions of the EA could occur in some instances and both cases were explanted for type Ia endoleaks. It does not necessarily mean that these failures were directly related to deleterious interactions.

Following studies on endograft displacement forces after endostapling,<sup>6</sup> Goudekettig *et al.* demonstrated in an experimental study that circumferential placement increases endograft displacement resistance.<sup>7</sup> These results directly suggest that good positioning and deployment of the anchor requires specialised skills and a trained team, with experts suggesting a multiplanar approach for hostile necks.<sup>3,5</sup> However, the design of these studies did not integrate the long term cyclic load, but focused on traction resistance that results in exposure to forces much higher than *in vivo* forces and did not

integrate the arterial cyclic load, which created the lesions observed. However, it is worth considering that optimal EA deployment achieves good aorto-graft apposition, reinforcing the suggestion of the protective effect of EAs even with continued aortic neck dilatation,<sup>3,8</sup> which may be an effect of both static (radial force) and cyclic (haemodynamic) loading.

This suggests that even if EAs might be promising treatment for some patients, they should be used carefully and strictly following the manufacturer's IFU. In the first case, EAs 4, 5, and 6 were deployed too low and were probably not engaging the aorta at all. The principle of circumferential EA deployment was not followed. EA deployment needs to be accurately planned out, because "blind" placement might lead to persistent complications requiring complex open revisional surgery in high risk patients.<sup>3</sup> Clinical studies, especially long term, are therefore needed to assess the safety and efficiency of this system on short neck aneurysms.<sup>3,9</sup>

The main interest of a retrieval programme of explanted prostheses is to allow the analysis of a significant number



**Figure 2.** (A) Multiple passes of the EndoAnchor (EA; EA2) through the fabric causing alteration of the textile structure (Keyence magnification 50×). (B) Partial rupture of a textile mesh due to the EA passing (EA3) through the endograft stitches (Keyence magnification 150×). (C) EA9 passing close to the suprarenal stent (Keyence magnification 50×). (D) Mesh enlargement and partial rupture of the fibres on hole (H2; Keyence magnification 150×).

of prostheses, in order to describe the ageing characteristics of the different models of devices and to learn about the concept itself. However, a study based on a retrieval programme has unavoidable limitations that must be taken into consideration when interpreting the results as one may consider that the probability of finding structural lesions on endografts explanted for a complication is higher than on uncomplicated endografts. Moreover, that lesions could have been created during the explantation of the endograft and therefore are a result of manipulation rather than damage resulting from EA deployment and fixation must be considered.<sup>10</sup> The ideal specimen for analysis would result from the autopsy of a patient who died of unrelated causes. Finally, the time between EA placement and explantation is short. Further studies are therefore needed in order to assess the long term effects of EAs on textile.

### Conclusion

This study confirms the necessity of following up new technologies through explant analysis programmes and provides insights on the impact of EAs on endografts, depending on where the EAs enter through the fabric. Close follow up of patients treated with EAs remains necessary and further studies focusing on these interactions under cyclic load are still required.

### FUNDING

The authors are indebted to the Eurometropole de Strasbourg and the Région Grand'Est for their financial support.

### CONFLICT OF INTEREST

None.

### ACKNOWLEDGMENTS

The authors acknowledge the European Society of Vascular Surgery and the Société Française de Chirurgie Vasculaire et Endovasculaire, who support the explant analysis program.

### APPENDIX A. SUPPLEMENTARY DATA

Supplementary data related to this article can be found at <https://doi.org/10.1016/j.ejvsf.2020.08.002>.

### REFERENCES

- 1 Medtronic. Aptus Heli-FX and Helo-FX thoracic endoanchor systems, comprising the Heli-FX guides, heli-FX applicators, EndoAnchor implants, and EndoAnchor Cassettes. Available at: [http://manuals.medtronic.com/content/dam/emanuals/cardio/M967540A001\\_Rev1A\\_view.pdf](http://manuals.medtronic.com/content/dam/emanuals/cardio/M967540A001_Rev1A_view.pdf) [Accessed 14 August 2020].
- 2 Qamhawi Z, Barge TF, Makris GC, Patel R, Wigham A, Anthony S, et al. A systematic review of the use of

- endoanchors in endovascular aortic aneurysm repair. *Eur J Vasc Endovasc Surg* 2020;vol. 59:P748–56.
- 3 Chaudhuri A, Kim HK, Reyes Valdivia A. Improved mid-term outcomes using standard devices and EndoAnchors for endovascular repair of abdominal aortic aneurysms with hyperangulated necks. *Cardiovasc Interv Radiol* 2020;**43**:971–80.
  - 4 Schlosser FJV, de Vries J, Chaudhuri A. Is it time to insert EndoAnchors in routine EVAR? *Eur J Vasc Endovasc Surg* 2017;**53**:458–9.
  - 5 Chaudhuri A. Commentary: is an ounce of EndoAnchors worth more than many pounds for reintervention? *J Endovasc Ther* 2019;**26**:101–4.
  - 6 Melas N, Perdikides T, Saratzis A, Saratzis N, Kiskinis D, Deaton DH. Helical EndoStaples enhance endograft fixation in an experimental model using human cadaveric aortas. *J Vasc Surg* 2012;**55**:1726–33.
  - 7 Goudeketting SR, Vermeulen JJM, van Noort K, Te Riet OG, Scholten G, Kuipers H, et al. Effect of different EndoAnchor configurations on aortic endograft displacement resistance: an experimental study. *J Endovasc Ther* 2019;**26**:704–13.
  - 8 Tassiopoulos AK, Monastiriotis S, Jordan WD, Muhs BE, Ouriel K, de Vries JP. Predictors of early aortic neck dilatation after endovascular aneurysm repair with EndoAnchors. *J Vasc Surg* 2017;**66**:45–52.
  - 9 Wanhainen A, Verzini F, Van Herzeele I, Allaire E, Bown M, Cohnert T, et al. Editor's choice — European Society for Vascular Surgery (ESVS) 2019 clinical practice guidelines on the management of abdominal aorto-iliac artery aneurysms. *Eur J Vasc Endovasc Surg* 2019;**57**:8–93.
  - 10 Lejay A, Colvard B, Magnus L, Dion D, Georg Y, Papillon J, et al. Explanted vascular and endovascular graft analysis: where do we stand and what should we do? *Eur J Vasc Endovasc Surg* 2018;**55**:567–76.