



Case Report

Stress Perfusion Cardiac Magnetic Resonance Imaging With a 3.0-Tesla Scanner for Myocardial Viability in a Patient With a Conditional Pacemaker

Pouya Motazedian, MD,^a Graeme Prospero-Porta, MD, MSc,^a Mobeen Ahmed, MBBS,^b Moiz Hafeez, MD, MSc,^c Naem Merchant, MD,^b and Bobak Heydari, MD, MPH^{c,d}

^a University of Ottawa Heart Institute, University of Ottawa, Ottawa, Ontario, Canada

^b Division of Radiology, University of Calgary, Calgary, Alberta, Canada

^c Cumming School of Medicine, University of Calgary, Calgary, Alberta, Canada

^d Division of Cardiology, Department of Cardiac Sciences, Stephenson Cardiac Imaging Centre, University of Calgary, Calgary, Alberta, Canada

ABSTRACT

Cardiac magnetic resonance (CMR) imaging provides images with high spatial and temporal resolution, with high diagnostic and prognostic performance. An abundance of data indicate the safety and efficacy of noncardiac magnetic resonance imaging at both 1.5 Tesla (T) and 3T in patients with cardiac implantable electronic devices (CIEDs). Safety and efficacy have also been evaluated for stress perfusion (SP)-CMR for patients with CIEDs, using 1.5T scanners, but no previous reports have been made of SP-CMR using 3T scanners. Herein, we report a case of a patient with a CIED who successfully and safely underwent SP-CMR imaging using a 3T scanner.

RÉSUMÉ

L'imagerie par résonance magnétique cardiaque (IRMC) procure des images à haute résolution spatiale et temporelle en plus d'offrir une capacité diagnostique et pronostique élevée, mais une multitude de données mettent en lumière l'innocuité et l'efficacité de l'imagerie non cardiaque réalisée au moyen d'appareils d'IRM produisant un champ magnétique de 1,5 ou de 3 teslas (T) chez des patients porteurs d'un dispositif cardiaque électronique implantable (DCEI). L'innocuité et l'efficacité de l'évaluation de la perfusion à l'effort (EPE) par IRMC ont aussi été évaluées chez des patients porteurs d'un DCEI au moyen d'appareils produisant un champ magnétique de 1,5 T, mais pas au moyen d'appareils produisant un champ magnétique de 3 T. Nous rapportons ici le cas d'un patient porteur d'un DCEI ayant subi avec succès et en toute sécurité une EPE par IRMC réalisée au moyen d'un appareil produisant un champ magnétique de 3 T.

Growing evidence supports the safety and image quality of cardiac magnetic resonance imaging (CMR) with cardiac implantable electronic devices (CIEDs), but current evidence is limited to 1.5-Tesla (T) scanners and noncardiac 3T studies.^{1,2} Although 3T scanners have superior diagnostic performance for identifying myocardial ischemia compared to 1.5T scanners, imaging artifacts from CIEDs are also greatest at higher field strengths, limiting their prior use.³ We present a case of successful stress perfusion

(SP)-CMR to determine myocardial viability using a 3T scanner in a patient with a CIED.

Case

A 78-year-old diabetic man with a Medtronic A3SR01 (Medtronic, Minneapolis, MN) single-lead pacemaker presented to our cardiology clinic with new-onset heart failure. Echocardiography demonstrated a reduced left ventricular ejection fraction (LVEF) of 35%, using the Simpson's biplane method with apical hypokinesis, and a thallium nuclear perfusion study reported a LVEF of 47% without inducible ischemia. Despite the thallium results, invasive coronary angiography was conducted and demonstrated an 80% occlusion of the mid-left anterior descending artery, and 100% occlusion of the left circumflex artery, with unsuccessful angioplasty of the latter lesion. The patient was referred for SP-CMR for assessment of myocardial ischemia and viability in consideration for coronary artery bypass grafting.

Received for publication January 4, 2022. Accepted February 17, 2022.

Ethics Statement: The patient provided informed consent to undergo cardiac magnetic resonance imaging at 3.0 Tesla with a conditional pacemaker and to publish this case report.

Corresponding author: Dr Bobak Heydari, Foothills Medical Centre, SSB #0700, 1403 – 29 St NW, Calgary, Alberta T2N 2T9, Canada. Tel.: +1-403-944-1825; fax: +1-403-944-8510.

E-mail: bobby.heydari@ucalgary.ca

See page 584 for disclosure information.

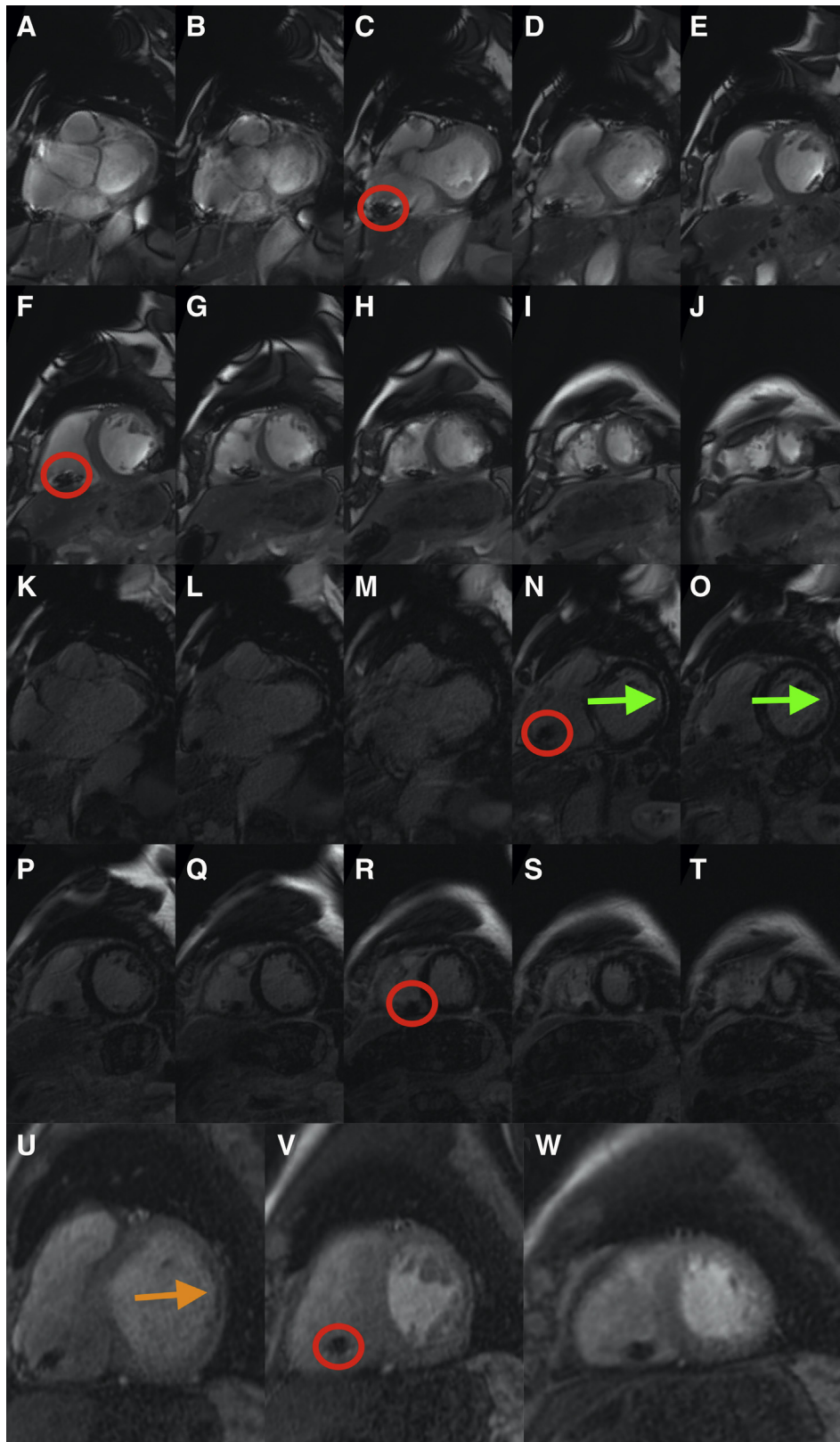



Figure 1. 3.0-Tesla stress perfusion cardiac magnetic resonance imaging with a cardiac implantable electronic device. (**A-J**) Steady state free precession left ventricular short-axis stack minor susceptibility artifact in the (**D-I**) inferolateral wall. (**K-T**) Magnitude late gadolinium enhancement demonstrating non-transmural subendocardial myocardial scar in the basal and mid-anterolateral segments (bright endocardium **highlighted by green arrows**) and (**U-W**) first-pass stress perfusion imaging showing a small defect (dark subendocardium **highlighted by orange arrow**) within the basal and mid-anterolateral segment. The right ventricular pacing wire artifact can be seen in the posterior segment of the right ventricular cavity (**circled in red**).

Novel Teaching Points

- SP-CMR imaging at 3T may be safe in patients with conditional pacemakers.
- Excellent image quality, with nonsignificant artifacts at 3T, can be achieved in a patient with a conditional pacemaker.
- CMR imaging at 3T may be considered in patients with CIEDs.

Prior to the SP-CMR, the patient was confirmed to be non-pacemaker dependent, and his device was placed in magnetic resonance imaging SureScan mode. SP-CMR was conducted with a Siemens Prisma 3T scanner (Siemens, Munich, Germany) for standard 2-, 3-, and 4-chamber steady state free precession (SSFP) views and precontrast short tau inversion recovery (STIR). Stress perfusion was conducted using 140 µg/kg/min adenosine infusion with heart rate increasing from 60 to 80 beats per minute. Gadolinium (Gadovist; Bayer, Leverkusen, Germany) contrast was administered as a 0.1 mmol/kg bolus for both stress and rest first-pass perfusion using gradient-recalled echo sequence. This process was followed by short-axis SSFP cine and late-gadolinium enhancement (LGE) imaging.

SP-CMR demonstrated an LVEF of 41% with wall-motion abnormalities within the mid-anterolateral segment, and respective subendocardial LGE. LGE also demonstrated a nonischemic mid-wall striae pattern in the basal infero-septal segment. On first-pass stress perfusion CMR, the basal to mid-anterolateral segment findings were consistent with a matched perfusion defect (to LGE). Imaging artifacts related to pacing wires of the right ventricle and the susceptibility artifact in the inferolateral wall in the SSFP left ventricular short-axis images did not impact the overall quality or findings of the study (Fig. 1; Video 1 , view video online). Important to note is that the inferolateral susceptibility artifact was not present on perfusion or LGE images. Overall, findings were consistent with a chronic left circumflex infarct and a moderately viable myocardium overlapping with a non-ischemic, non-infiltrative dilated cardiomyopathy. After the SP-CMR, the device was interrogated and reprogrammed to its original settings. Based on the presence of viable myocardium, the patient underwent coronary artery bypass grafting with a saphenous vein graft to the first obtuse marginal artery and left internal thoracic artery to the left anterior descending artery. The patient's LVEF, measured by Simpson's biplane method, recovered to 51% after revascularization and guideline-directed medical therapy on a follow-up transthoracic echocardiogram 8 months later.

Discussion

The ability of CMR to produce high-quality, radiation-sparing images without exposure to iodinated contrast makes it an attractive modality for evaluation of patients with high pretest probability or known coronary artery disease presenting with heart failure or recurrent chest pain.³ Our case

Table 1. Techniques to reduce B_1 + root mean square

Increased radiofrequency pulse duration
Use of "low specific absorption rate mode"
Increased repetition time without reducing slice number
Reduced slices for set repetition time
Reduced echo train length
Reduced refocusing angle (fast spin-echo sequences)
Reduced flip angle (gradient-recalled echo sequences)
Use gradient recalled echo sequences instead of spin echo or fast spin-echo

Adapted from Faulkner,⁸ with permission from the International Society for Magnetic Resonance in Medicine (ISMRM).

demonstrates that 3T scanners can produce high-quality diagnostic images without compromising artifacts in the presence of CIEDs. To our knowledge, this case is only the second involving 3T CMR in a patient with a CIED, and the first case of SP-CMR. Mark et al. previously reported the success and safety of 3T CMR imaging in a patient with a Medtronic Ensura SureScan DR (Medtronic, Minneapolis, MN) dual-chamber pacemaker for the assessment of myocarditis and infiltrative disease.⁴ Cardiac ¹⁸F-fluorodeoxyglucose positron emission tomography (¹⁸F-FDG-PET) is an alternative modality to identify myocardial viability that can be used in patients with CIEDs without concern for artifacts.⁵ However, both ¹⁸F-FDG-PET and 3T SP-CMR are not available at all cardiovascular centres, and therefore, performing one or the other method, depending on the centre's area of expertise, is beneficial. In Calgary, ¹⁸F-FDG-PET is not readily available for myocardial viability assessment, so SP-CMR is the preferred choice.

Safety of CMR with CIEDs has been questioned in the past, with concern for device failure, tissue heating, mechanical displacement, and antenna radio-frequency energy deposition.^{4,6} Growing evidence supports the safety and image quality of CMR with CIEDs in 1.5T scanners and 3T noncardiac studies.^{1,7} In the absence of formalized studies, whether this theoretical risk manifests clinically in 3T scanners is unclear.

CIED interference, causing an image artifact, increases with greater magnetic and radiofrequency fields.⁶ As the magnetic field is set in 3T scanners, interference can be limited by reducing radiofrequency, which is measured indirectly by specific absorption rate, a measure that has limited reliability due to inter-patient and machine variance, especially in the presence of CIEDs. Thus, current 3T devices measure the flip angle as derivative of B_1 + root mean square (B_1 +RMS), allowing for a more reliable patient-adjusted parameter.^{1,7} Adjusting parameters that reduce B_1 +RMS interference with CIEDs are shown in Table 1.

Growing evidence supports the utility and safety of use of 3T CMR with CIEDs. Reducing radiofrequency and B_1 +RMS can help mitigate the inherently greater interference with 3T scanners. Although this case report details a technically successful and safe use of SP-CMR to identify myocardial ischemia in a patient with a CIED, additional data are required to determine whether SP-CMR at 3T can be offered routinely for all patients with CIEDs.

Funding Sources

The authors have no funding sources to declare.

Disclosures

The authors have no conflicts of interest to disclose.

References

1. van Dijk VF, Delnoy PPHM, Smit JJJ, et al. Preliminary findings on the safety of 1.5 and 3 Tesla magnetic resonance imaging in cardiac pacemaker patients. *J Cardiovasc Electrophysiol* 2017;28:806-10.
2. Primary Panel; Ian Paterson D, White JA, et al. 2021 update on safety of magnetic resonance imaging: joint statement from Canadian Cardiovascular Society/Canadian Society for Cardiovascular Magnetic Resonance/Canadian Heart Rhythm Society. *Can J Cardiol* 2021;37:835-47.
3. Kiaos A, Tziatzios I, Hadjimiltiades S, Karvounis C, Karamitsos TD. Diagnostic performance of stress perfusion cardiac magnetic resonance for the detection of coronary artery disease: a systematic review and meta-analysis. *Int J Cardiol* 2018;252:229-33.
4. Mark SR, Maggie M, Manan V, Jeremy W. Cardiac magnetic resonance with a conditional pacemaker at three Tesla field strength. *Cardiovasc Imag Asia* 2018;2:28-30.
5. Beanlands RS, Nichol G, Huszti E, et al. F-18-fluorodeoxyglucose positron emission tomography imaging-assisted management of patients with severe left ventricular dysfunction and suspected coronary disease: a randomized, controlled trial (PARR-2). *J Am Coll Cardiol* 2007;50:2002-12.
6. Muthalaly RG, Nerlekar N, Ge Y, Kwong RY, Nasis A. MRI in patients with cardiac implantable electronic devices. *Radiology* 2018;289:281-92.
7. Shulman RM, Hunt B. Cardiac implanted electronic devices and MRI safety in 2018—the state of play. *Eur Radiol* 2018;28:4062-5.
8. Faulkner W. New MRI safety labels & devices. *Signals* 2016;5.

Supplementary Material

To access the supplementary material accompanying this article, visit *CJC Open* at <https://www.cjcopen.ca/> and at <https://doi.org/10.1016/j.cjco.2022.02.009>.