

## Original Article

# Epithelial expression of keratinocytes growth factor in oral precancer lesions

Sudha Jimson<sup>1</sup>, S. Murali<sup>2</sup>, Susan L. Zunt<sup>3</sup>, Lawrence I. Goldblatt<sup>3</sup>, Mythily Srinivasan<sup>3</sup>

<sup>1</sup>Department of Oral Pathology, Sree Balaji Dental College and Hospital, Chennai, <sup>2</sup>Department of Oral Pathology, Vinayaka Mission's Sankarachariyar Dental College, Salem, Tamil Nadu, India, <sup>3</sup>Department of Oral Pathology, Medicine and Radiology, Indiana University School of Dentistry, Indianapolis, Indiana, USA

## ABSTRACT

**Background:** Keratinocyte growth factor (KGF) is a potent epithelial mitogen that acts by binding the KGF receptors (KGFRs) expressed on epithelial cells and regulates proliferation and differentiation. The objective of this study was to investigate the expression of KGF in the epithelium in oral precancer.

**Materials and Methods:** Archival tissues of oral submucous fibrosis (SMF) and leukoplakia were assessed for epithelial KGF expression by immunohistochemistry and real-time quantitative polymerase chain reaction.

**Results:** KGF was predominantly expressed in the basal and parabasal cells in the epithelium of SMF tissues. KGF transcript in the epithelial cells increased with increasing severity of epithelial dysplasia in oral leukoplakia.

**Conclusion:** Although widely reported as a product secreted by the mesenchymal cells, our data suggest that the KGF is also expressed in oral epithelial cells much like the expression in ovarian epithelial cells. Based on the localization of KGF in cells at the epithelial mesenchymal junction and that of the reported presence of KGFR in oral keratinocytes, a potential mechanism involving paracrine and autocrine interactions of KGF and KGFR in early stages of oral precancer is postulated.

**Key Words:** Epithelium, keratinocyte growth factor, leukoplakia, oral submucous fibroses

Received: April 2015  
Accepted: November 2015

### Address for correspondence:

Dr. Mythily Srinivasan,  
Indiana University  
School of Dentistry,  
1121 West Michigan Street,  
Indianapolis, IN 46202, USA.  
E-mail: mysriniv@iupui.edu

## INTRODUCTION

Oropharyngeal cancers are among the more common cancers affecting nearly 275,000 globally with two-third of these cases occurring in developing countries.<sup>[1,2]</sup> Despite therapeutic and diagnostic advances, the 5-year survival rate for oral squamous cell carcinoma (SCC) remains at about 50%.<sup>[2,3]</sup> Although most cases are preceded by distinct precancerous lesions, the variable premalignant potential, nonuniformity in risk assessment

and paucity of sensitive markers for malignant transformation contribute to the delayed diagnosis and poor prognosis of oral cancer.<sup>[4,5]</sup>

Oral carcinogenesis is a multistep process that often progresses through a series of histopathological changes from hyperplasia through varying degrees of dysplasia to carcinoma *in-situ* and invasive SCC.<sup>[3,6]</sup> Leukoplakia and submucous fibrosis (SMF) are two

### Access this article online



Website: [www.drj.ir](http://www.drj.ir)  
[www.drjjournal.net](http://www.drjjournal.net)  
[www.ncbi.nlm.nih.gov/pmc/journals/1480](http://www.ncbi.nlm.nih.gov/pmc/journals/1480)

This is an open access article distributed under the terms of the Creative Commons Attribution-NonCommercial-ShareAlike 3.0 License, which allows others to remix, tweak, and build upon the work non-commercially, as long as the author is credited and the new creations are licensed under the identical terms.

**For reprints contact:** [reprints@medknow.com](mailto:reprints@medknow.com)

**How to cite this article:** Jimson S, Murali S, Zunt SL, Goldblatt LI, Srinivasan M. Epithelial expression of keratinocytes growth factor in oral precancer lesions. Dent Res J 2016;13:199-205.

common premalignant changes of the oral mucosa with the later condition primarily prevalent in India and other Southeast Asian countries.<sup>[7,8]</sup> Statistically, SMF has been reported to exhibit higher potential for malignant transformation than leukoplakia.<sup>[9]</sup> At the molecular level, overexpression of growth factors and/or aberrant signaling by growth factor receptors are critical processes in malignant transformation.<sup>[3]</sup>

Keratinocyte growth factor (KGF) also known as fibroblast growth factor (FGF)-7 is a potent epithelial mitogen. KGF acts exclusively through a subset of FGF receptor (FGFR) isoforms (the FGFR2b also referred as KGF receptor [KGFR]) expressed on epithelial cells.<sup>[10,11]</sup> The KGF:KGFR interaction plays critical role in controlling epithelial proliferation and differentiation.<sup>[10]</sup> KGF is predominantly expressed in the mesenchymal cells and stimulates epithelial cells by a paracrine mechanism.<sup>[12,13]</sup> Fibroblasts isolated from normal buccal mucosa, gingiva, or periodontal ligament have been shown to express KGF.<sup>[14,15]</sup> KGFR is the dominant FGFR expressed on normal oral epithelial cells.<sup>[16,17]</sup> Overexpression of KGF by the gingival or periodontal ligament fibroblasts have been shown to induce proliferation of junctional and oral epithelium via paracrine stimulation of epithelial KGFR.<sup>[18]</sup> Increased KGF expression has also been reported in the fibroblasts and inflammatory cell in the connective tissue stroma in oral SCC.<sup>[17,19]</sup>

As opposed to its well-characterized expression in the mesenchymal cells, KGF expression in epithelial cells has been reported in only selected tissues such as the ovary, pancreas, and oral mucosa.<sup>[17,20,21]</sup> The epithelial KGF expression has been shown to be upregulated in chronic inflammatory conditions.<sup>[14]</sup> Increased expression of FGFR2 (KGFR) has been reported in dysplastic oral epithelium.<sup>[22]</sup> Based on the restricted expression of KGFR in the epithelial cells, an autocrine signaling that promote epithelial growth differentiation has been suggested.<sup>[14,15,17]</sup> Oral SCC cell lines and cultured keratinocytes have been shown not only to express KGF, but the expression has been shown to be upregulated by areca nuts and other deleterious agents.<sup>[15-17]</sup> The objective of this study is to examine the expression of KGF in oral epithelium in oral SMF (OSMF) and leukoplakia tissues with epithelial dysplasia. Together with the known expression profile of KGFR, information regarding the expression of KGF will provide insight into the cell-cell interactions that regulate epithelium in oral precancer.

## MATERIALS AND METHODS

### Tissues

Paraffin-embedded archival tissues with the histopathological diagnosis of OSMF or leukoplakias with epithelial dysplasia or oral SCC were chosen from the repositories of the Indiana University School of Dentistry, Indianapolis, IN, USA and the Vinayaka Mission's Sankarachariyar Dental College, Salem, India after obtaining approval from the respective institutions Institutional Review Boards for the use of human tissues for research purposes. Hematoxylin and eosin stained sections were graded for epithelial dysplasia by two histopathologists as mild: Hyperplasia, bulbous reteridges, and nuclear hyperchromatism; moderate: Additionally irregular stratification, increased mitosis and nuclear cytoplasmic ratio; and severe: Aadditionally abnormal mitosis, increased nuclear cytoplasmic ratio and dyskeratosis.<sup>[8,23]</sup> Fifteen tissues each of SMF, mild, moderate, and severe epithelial dysplasia and oral SCC were selected for further analysis. Ten histologically normal tongue and buccal mucosa specimens were obtained as control specimens.

### Immunohistochemistry

Serial 5  $\mu$  thick sections of each SMF and histologically normal tongue specimen were immunostained for KGF.<sup>[15,24]</sup> Staining of normal intestine known to express KGF was used as positive control.<sup>[28]</sup> After deparaffinization and rehydration, the tissue sections were sequentially treated with 3% H<sub>2</sub>O<sub>2</sub> and 3% horse serum albumin in phosphate buffered saline (PBS) to block endogenous peroxidase activity and nonspecific immunoglobulin binding respectively. The tissue sections were then incubated overnight with rabbit polyclonal anti-human KGF primary antibody (Sc 7882: Santa Cruz Biotechnology, Inc., CA, USA) diluted 1:1000 or PBS in negative controls at 4°C. The sections were washed and incubated with biotinylated anti-rabbit IgG secondary antibody diluted 1:2000 for 45 min at room temperature followed by washing and incubation in Vectstain elite ABC reagent (Vector laboratories, CA, USA) for 30 min. The enzyme activity was detected with the chromogen 3-3 diaminobenzidine (DAB) deposition (Vector Laboratories, CA, USA). The sections were counterstained with hematoxylin. After dehydration in graded alcohol and clearing in xylene, the slides were permanently mounted.

### Image analysis

Digital images from each tissue specimen at  $\times 10$  objective lens magnification were analyzed for

positive staining using ImageJ image analysis software (Bethesda, Maryland, USA, [http://rsb.info.nih.gov/ij/download.html]). Lesional tissues were randomly selected for microscopic features of dysplasia. Each image was filtered through the color deconvolution plugin to separate DAB positive staining.<sup>[25]</sup> In each image, the epithelium was selected as the region of interest and analyzed automatically for integrated intensity of brown color representing positive DAB staining. Average integrated intensity of all five areas was obtained for each specimen. The mean integrated intensity per group was then calculated.<sup>[23]</sup>

### Real time polymerase chain reaction

The epithelium of each leukoplakia specimen was dissected using laser capture microdissection. Total RNA extracted from each tissue with RNeasy Mini Kit (QIAGEN, Valencia, CA, USA) was reverse transcribed using iScript complementary DNA (cDNA) synthesis kit (Bio-Rad, CA, USA). Real-time polymerase chain reaction (RT-PCR) was performed using the SYBR Green/ROX qPCR Mastermix (SABiosciences, Frederick, MD, USA) on the ABI Prism 7000 Sequence Detection System (Perkin Elmer Applied Systems, Foster City, CA, USA). Each reaction contains  $2 \times 12.5/\mu\text{l}$  of SYBR Green Mastermix,  $1 \mu\text{l}$  of  $10 \mu\text{M}$  of primers and  $50 \text{ ng}$  of the cDNA, to a total volume of  $25 \mu\text{l}$ . The thermal cycling conditions included an initial denaturation step at  $50^\circ\text{C}$  for  $2 \text{ min}$ ,  $95^\circ\text{C}$  for  $10 \text{ min}$ ,  $40$  cycles at  $95^\circ\text{C}$  for  $15 \text{ s}$ , annealing temperature for  $30 \text{ s}$  and extension at  $72^\circ\text{C}$  for  $30 \text{ s}$ . Amplification of glyceraldehyde 3-phosphate dehydrogenase (GAPDH) and small proline-rich protein 2a (SPRR2a), a gene abundantly expressed in epithelial cells was included as controls for the PCR reaction and epithelial cell origin respectively. The primers used are given in Table 1. The magnitude of change in the messenger RNA was expressed as  $2^{-\Delta\Delta C_t}$ .<sup>[29]</sup>

**Table 1: Primers used for real-time quantitative polymerase chain reaction amplification**

| Gene   | Forward                            | Reverse   |
|--------|------------------------------------|---|
| GAPDH  | 5'-AGCCTTCTCCATG<br>GTGGTGAAGAC-3' | 5'-CGGAGTCAACGG<br>ATTTGGTCG-3' <sup>[26]</sup>   |
| SPRR2a | 5'-AGTGCCAGCAGA<br>AATATCCTCC-3'   | 5'-GAACGAGGTGAG<br>CCAAATATCC-3' <sup>[27]</sup>  |
| KGF    | 5'-TTGTGGCAATCAA<br>AGGGGTG-3'     | 5'-CCTCCGTTGTGTG<br>TCCATTTAGC-3' <sup>[28]</sup> |

GAPDH: Glyceraldehyde 3-phosphate dehydrogenase; SPRR2a: Small proline-rich protein 2a; KGF: Keratinocyte growth factor

### Statistical analysis

The difference in the KGF expression between different groups was determined by the Student's *t*-test.  $P < 0.05$  was considered statistically significant.

## RESULTS

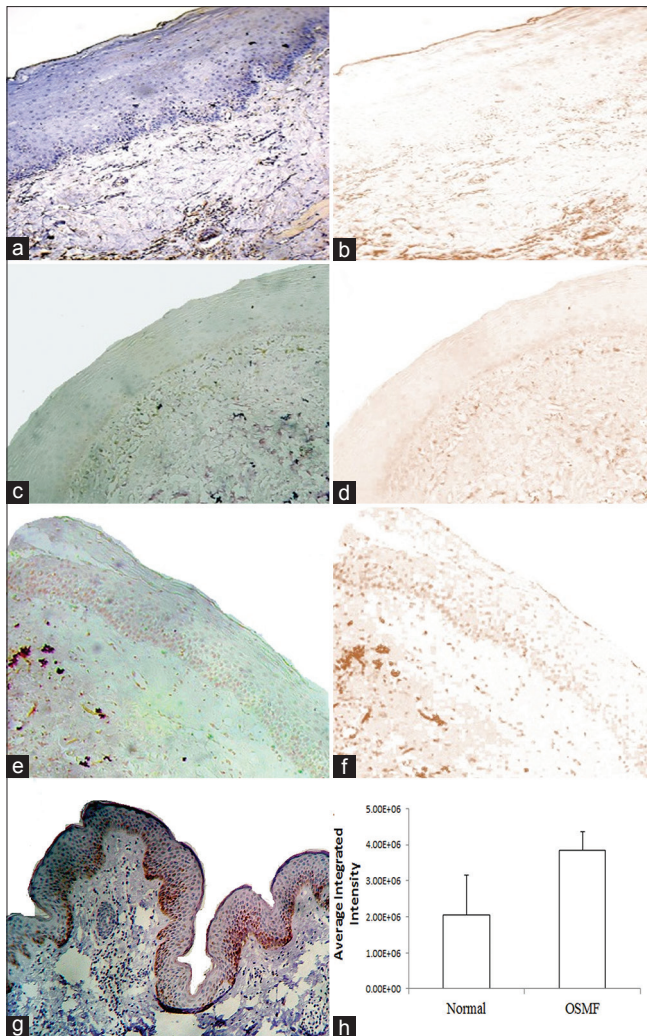
### Expression of keratinocyte growth factor in submucous fibrosis

All the SMF and the representative normal tissues for KGF staining were derived from biopsies of buccal mucosa. Histologically, all SMF tissues exhibited hyperparakeratosis and atrophic epithelium juxtaposed with chronic inflammatory cell infiltration consistent with features of mild epithelial dysplasia. Immunohistochemical staining showed that the KGF expression was observed minimally in the epithelium and predominantly in the connective tissue in normal oral mucosa [Figures 1a, b and 2a, b]. Figure 1c and f are negative controls and Figure 1g is the KGF staining in intestinal mucosa as positive control for KGF. KGF expression was observed in the oral epithelium in OSMF, with greater expression in stratum basale [Figure 1c and d]. Quantitative estimation suggested that the average integrated intensity of KGF staining was significantly higher in the oral epithelium of SMF tissues as compared with that of normal oral epithelium [Figure 1h]. Significant KGF expression was expressed in the subepithelial connective tissue in OSMF. Areca nut extracts, the most prevalent causative factor for OSMF have been shown to mediate transforming growth factor- $\beta$  (TGF- $\beta$ ) secretion by the oral epithelial cells, induce inflammation and upregulate cytokines in the connective tissue. Since cytokines such as TGF- $\beta$  and interleukin-6 can stimulate stromal KGF expression, it is postulated that the observed KGF positivity in the lamina propria of OSMF could be attributed to the inflammation altered microenvironment.

### Expression of keratinocyte growth factor in leukoplakia with epithelial dysplasia

Since none of the SMF tissues in our cohort exhibited histological changes beyond mild epithelial dysplasia, we next investigated archival tissues of oral leukoplakia exhibiting mild, moderate, or severe epithelial dysplasia for KGF expression [Figure 2a-d]. Immunohistochemistry showed that the expression of KGF was increased both in the epithelium and in the connective tissue in leukoplakia with dysplasia and carcinoma as compared with that in normal mucosa [Figure 2e-j]. Quantitative estimation suggested that





**Figure 1:** Immunohistochemical staining and quantitation keratinocyte growth factor in submucous fibrosis epithelium. Photomicrographs of immunostained for keratinocyte growth factor are shown as follows: (a) normal oral mucosa, (c) negative control and (e) representative oral submucous fibrosis tissue showing significant positive staining in the basal cell layer; corresponding deconvoluted images of brown staining color are shown in (b), (d and f), respectively. Staining of normal intestine known to be positive for KGF. Average integrated stain intensity quantitated by ImageJ (h).  $*=P<0.05$  as compared to normal epithelium.

the mean integrated intensity of KGF staining was progressively higher in the epithelium of oral mucosa from normal through mild, moderate, and several dysplasia's to carcinoma [Figure 2k].

#### Keratinocyte growth factor transcript is upregulated in dysplastic oral epithelium

We next investigated whether the increased expression of protein correlate with the transcript for KGF in oral leukoplakia with dysplasia. SPRR2a is a keratinocytes differentiation marker expressed in oral

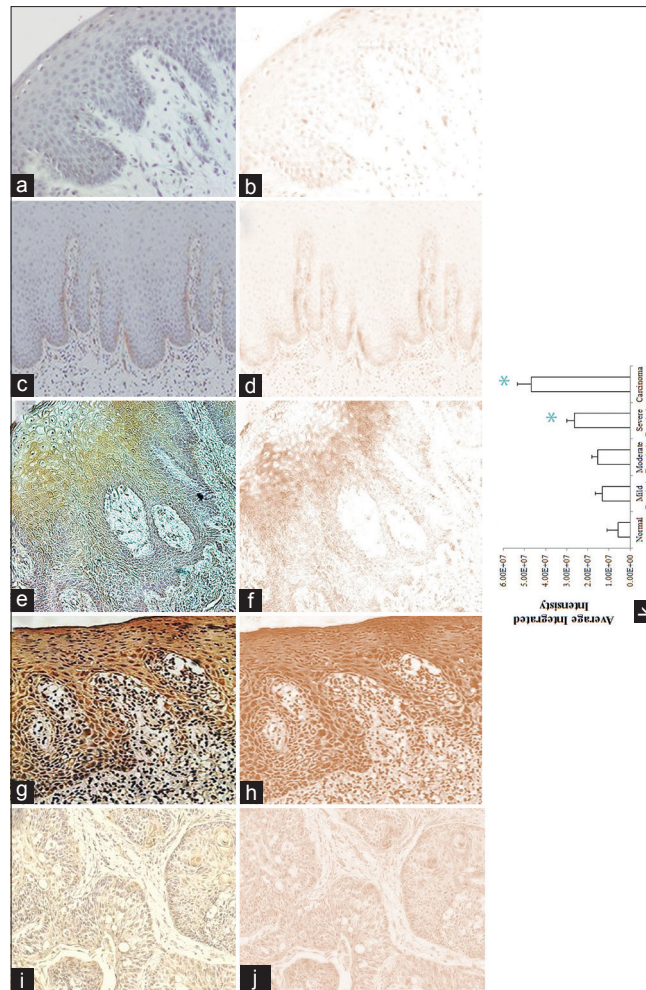
epithelial cells.<sup>[30]</sup> Quantitative RT-PCR suggested that with respect to GAPDH, the epithelial-rich SPRR2a<sup>[30]</sup> was significantly lower in oral epithelium with severe dysplasia and in carcinoma as compared with the expression in normal oral epithelial cells [Figure 3 a and b]. With respect to the epithelial specific SPRR2a, the KGF transcript was significantly higher in leukoplakia with severe epithelial dysplasia and carcinoma as compared with the expression in normal oral epithelial cells [Figure 3a and c]. The relative expression of the KGF transcript in OSMF epithelium was  $0.46 \pm 0.12$  units similar to oral leukoplakia with mild dysplasia and consistent with the histological observation of mild dysplasia (data not shown).

## DISCUSSION

Homeostasis between the proliferation and the differentiation process in oral epithelium is regulated by functional interactions between the growth factor receptors and their cognate ligands.<sup>[26]</sup> Dysregulated growth control that parallels degree of dysplasia is intricately associated with the pathogenesis of epithelial cancers.<sup>[3,13]</sup> Here, we report progressive increase in the epithelial expression of KGF with increasing dysplasia in oral precancer.

The potent cytoprotective and regenerative effects of KGF on epithelial tissues is long recognized and has been taken advantage in clinical applications to alleviate radiation/chemotherapy-induced oral mucositis. The premise is that the KGF produced by the mesenchymal cells in response to cytokines induces paracrine stimulation of epithelial cells via FGFR2b, promote survival and DNA repair.<sup>[27]</sup> KGF/FGF-7 has been shown to be mitogenically active only on epithelial cells derived from a variety of tissues.<sup>[28]</sup>

The epithelial mitogenic potential of KGF has also been implicated in the growth of cancer cells.<sup>[10,27]</sup> For example, the ovarian surface epithelial cells have been shown to express and respond to KGF. Increased expression of KGF in the surface epithelial cells has been suggested to mediate autocrine proliferation and promote uncontrolled cell growth in ovarian cancer.<sup>[21]</sup> In esophageal tissues, weak KGF expression has been observed in the basal cells of normal epithelium and the expression is increased in the cytoplasm of cancerous cells.<sup>[31]</sup> Co-expression of KGF and KGFR in lung adenocarcinoma cells and in pancreatic cancer cells has been associated with increased invasion



**Figure 2:** Immunohistochemical staining of keratinocyte growth factor in oral leukoplakia. Photomicrographs of representative normal (a and b) and oral leukoplakia tissues exhibiting mild (c and d), moderate (e and f), severe (g and h) dysplasia and oral carcinoma (i and j) immunostained for keratinocyte growth factor (a, c, e, g, and i) and the corresponding deconvoluted images (b, d, f, h, and j), respectively. Quantitative estimation of positive staining in the epithelium as determined by the integrated staining intensity measured in ImageJ (k). \* $P < 0.05$  as compared to normal epithelium.

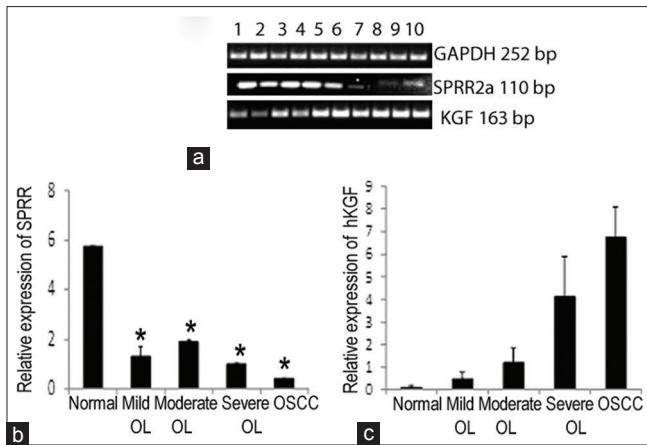
and worsened prognosis.<sup>[20,27]</sup> However, in contrast, a high level of KGFR expression in colonic epithelial cells has been associated with minimally invasive, well-differentiated colorectal carcinoma.<sup>[27,32]</sup>

With respect to oral carcinoma, increased KGF expression has been reported in malignant cancer cells and cell lines.<sup>[17,33]</sup> Tsai *et al.* have reported increased expression of KGF-1 in oral epithelium in OSMF.<sup>[15]</sup> This is consistent with our observation of increased KGF expression in basal and parabasal layers in OSMF and oral leukoplakia with dysplasia. This suggests that much like the mesenchymal cells, the juxtaposed epithelial cells may also upregulate KGF expression in response to cytokine and other stimulating factors. Prominent expression of KGFR has been observed in normal oral epithelium and

is upregulated in chronic inflammation and oral cancer.<sup>[14,16,17]</sup> Our observation of decreased SPRR2a expression with increasing severity of dysplasia suggests a reduced differentiation potential.<sup>[30]</sup> Significant elevation of epithelial KGFR has been reported in severe dysplasia and carcinoma *in-situ* in experimental oral carcinogenesis.<sup>[11,28,34]</sup> Taken together, the observed increase in KGF expression in the epithelium with increasing dysplasia and the reported upregulation of epithelial KGFR in oral precancer suggest that an autocrine KGFR:KGF interaction potentially provides a growth advantage in oral precancer.

In addition to its function in determining the phenotype of the epithelium during development, the epithelial mesenchymal communication plays critical





**Figure 3:** Keratinocyte growth factor transcript is increased in the dysplastic epithelium in oral leukoplakia. Histologically normal oral epithelium and the leukoplakia epithelium with increasing severity of dysplasia dissected by laser capture microdissection were assessed for glyceraldehyde 3-phosphate dehydrogenase, small proline-rich protein 2a and keratinocyte growth factor transcript by real-time polymerase chain reaction using specific primers. Gel electrophoresis of the polymerase chain reaction products. Lanes 1 and 2 represent normal epithelium; lanes 3 and 4, 5 and 6, 7 and 8 and 9 and 10 represent mild, moderate and severe dysplasia and squamous cell carcinoma epithelium respectively (a). Fold changes in the epithelial-rich small proline-rich protein 2a expression with respect to the house keeping gene glyceraldehyde 3-phosphate dehydrogenase (b) and fold changes in the keratinocyte growth factor transcript with respect to small proline-rich protein 2a gene (c). \* $P < 0.05$  as compared to normal epithelium.

role in the homeostatic maintenance and repair of the developed epithelium.<sup>[11]</sup> Based on the location of the KGF producing cells closer to the epithelial mesenchymal junction and that of the KGFR expressing cells in the differentiating cell layers, it is likely that the paracrine loop of the KGF:KGFR interaction contributes to the increased proliferation or hyperplasia and the autocrine interaction sustain the proliferation and promote dysregulated differentiation in oral precancer.<sup>[10,13]</sup> However, a previous study using human head and neck squamous tumor cell lines showed that the recombinant human KGF had little or no proliferative effect and did not affect the radiosensitivity.<sup>[19]</sup> Further studies are needed to delineate the mechanisms of KGF:KGFR interaction in oral carcinogenesis from normal mucosa through stages of epithelial dysplasia to carcinoma. This is particularly critical since considerable interest exists in the therapeutic use of KGF in the management of oral mucositis secondary to cancer treatment.<sup>[27,35]</sup>

## CONCLUSION

KGF is expressed predominantly in the proliferating/basal layers of the epithelium in OSMF. In oral epithelial dysplasia, KGF expression increased in severe dysplasia and carcinoma.

## Financial support and sponsorship

Nil.

## Conflicts of interest

The authors of this manuscript declare that they have no conflicts of interest, real or perceived, financial or non-financial in this article.

## REFERENCES

1. National Cancer Institute. PDQ® Oral Cancer Screening. Bethesda, MD: National Cancer Institute; 2015.
2. Warnakulasuriya S. Global epidemiology of oral and oropharyngeal cancer. *Oral Oncol* 2009;45:309-16.
3. Molinolo AA, Amornphimoltham P, Squarize CH, Castilho RM, Patel V, Gutkind JS. Dysregulated molecular networks in head and neck carcinogenesis. *Oral Oncol* 2009;45:324-34.
4. Reibel J. Prognosis of oral pre-malignant lesions: Significance of clinical, histopathological, and molecular biological characteristics. *Crit Rev Oral Biol Med* 2003;14:47-62.
5. Pitiyage G, Tilakaratne WM, Tavassoli M, Warnakulasuriya S. Molecular markers in oral epithelial dysplasia: Review. *J Oral Pathol Med* 2009;38:737-52.
6. Wu RQ, Zhao XF, Wang ZY, Zhou M, Chen QM. Novel molecular events in oral carcinogenesis via integrative approaches. *J Dent Res* 2011;90:561-72.
7. More CB, Das S, Patel H, Adalja C, Kamatchi V, Venkatesh R. Proposed clinical classification for oral submucous fibrosis. *Oral Oncol* 2012;48:200-2.
8. Warnakulasuriya S, Johnson NW, van der Waal I. Nomenclature and classification of potentially malignant disorders of the oral mucosa. *J Oral Pathol Med* 2007;36:575-80.
9. Pillai R, Balaram P, Reddiar KS. Pathogenesis of oral submucous fibrosis. Relationship to risk factors associated with oral cancer. *Cancer* 1992;69:2011-20.
10. de Giorgi V, Sestini S, Massi D, Ghersetich I, Lotti T. Keratinocyte growth factor receptors. *Dermatol Clin* 2007;25:477-85, vii.
11. Rubin JS, Bottaro DP, Chedid M, Miki T, Ron D, Cheon G, *et al.* Keratinocyte growth factor. *Cell Biol Int* 1995;19:399-411.
12. Ornitz DM, Itoh N. Fibroblast growth factors. *Genome Biol* 2001;2:REVIEWS 3005.1-3005.12.
13. Rubin JS, Bottaro DP, Chedid M, Miki T, Ron D, Cunha GR, *et al.* Keratinocyte growth factor as a cytokine that mediates mesenchymal-epithelial interaction. *EXS* 1995;74:191-214.
14. Li M, Firth JD, Putnins EE. Keratinocyte growth factor-1 expression in healthy and diseased human periodontal tissues. *J Periodontol Res* 2005;40:118-28.
15. Tsai CH, Yang SF, Chen YJ, Chou MY, Chang YC. Raised

- keratinocyte growth factor-1 expression in oral submucous fibrosis *in vivo* and upregulated by arecoline in human buccal mucosal fibroblasts *in vitro*. J Oral Pathol Med 2005;34:100-5.
16. LaRoche WJ, Dirsch OR, Finch PW, Cheon HG, May M, Marchese C, *et al.* Specific receptor detection by a functional keratinocyte growth factor-immunoglobulin chimera. J Cell Biol 1995;129:357-66.
17. Partridge M, Kiguwa S, Luqmani Y, Langdon JD. Expression of bFGF, KGF and FGF receptors on normal oral mucosa and SCC. Eur J Cancer B Oral Oncol 1996;32B: 76-82.
18. Guo L, Yu QC, Fuchs E. Targeting expression of keratinocyte growth factor to keratinocytes elicits striking changes in epithelial differentiation in transgenic mice. EMBO J 1993;12:973-86.
19. Ning S, Shui C, Khan WB, Benson W, Lacey DL, Knox SJ. Effects of keratinocyte growth factor on the proliferation and radiation survival of human squamous cell carcinoma cell lines *in vitro* and *in vivo*. Int J Radiat Oncol Biol Phys 1998;40:177-87.
20. Cho K, Ishiwata T, Uchida E, Nakazawa N, Korc M, Naito Z, *et al.* Enhanced expression of keratinocyte growth factor and its receptor correlates with venous invasion in pancreatic cancer. Am J Pathol 2007;170:1964-74.
21. Parrott JA, Kim G, Mosher R, Skinner MK. Expression and action of keratinocyte growth factor (KGF) in normal ovarian surface epithelium and ovarian cancer. Mol Cell Endocrinol 2000;167:77-87.
22. Wakulich C, Jackson-Boeters L, Daley TD, Wysocki GP. Immunohistochemical localization of growth factors fibroblast growth factor-1 and fibroblast growth factor-2 and receptors fibroblast growth factor receptor-2 and fibroblast growth factor receptor-3 in normal oral epithelium, epithelial dysplasias, and squamous cell carcinoma. Oral Surg Oral Med Oral Pathol Oral Radiol Endod 2002;93:573-9.
23. Srinivasan M, Jewell SD. Evaluation of TGF-alpha and EGFR expression in oral leukoplakia and oral submucous fibrosis by quantitative immunohistochemistry. Oncology 2001;61:284-92.
24. Srinivasan M, Jewell SD. Quantitative estimation of PCNA, c-myc, EGFR and TGF-alpha in oral submucous fibrosis – An immunohistochemical study. Oral Oncol 2001;37:461-7.
25. Safadi RA, Musleh AS, Al-Khateeb TH, Hamasha AA. Analysis of immunohistochemical expression of k19 in oral epithelial dysplasia and oral squamous cell carcinoma using color deconvolution-image analysis method. Head Neck Pathol 2010;4:282-9.
26. Aaronson SA, Rubin JS, Finch PW, Wong J, Marchese C, Falco J, *et al.* Growth factor-regulated pathways in epithelial cell proliferation. Am Rev Respir Dis 1990;142 (6 Pt 2):S7-10.
27. Finch PW, Rubin JS. Keratinocyte growth factor expression and activity in cancer: Implications for use in patients with solid tumors. J Natl Cancer Inst 2006;98:812-24.
28. auf dem Keller U, Krampert M, Kümin A, Braun S, Werner S. Keratinocyte growth factor: Effects on keratinocytes and mechanisms of action. Eur J Cell Biol 2004;83:607-12.
29. Janardhanam SB, Prakasam S, Swaminathan VT, Kodumudi KN, Zunt SL, Srinivasan M. Differential expression of TLR-2 and TLR-4 in the epithelial cells in oral lichen planus. Arch Oral Biol 2012;57:495-502.
30. Gibbs S, Ponc M. Intrinsic regulation of differentiation markers in human epidermis, hard palate and buccal mucosa. Arch Oral Biol 2000;45:149-58.
31. Yoshino M, Ishiwata T, Watanabe M, Matsunobu T, Komine O, Ono Y, *et al.* Expression and roles of keratinocyte growth factor and its receptor in esophageal cancer cells. Int J Oncol 2007;31:721-8.
32. Yoshino M, Ishiwata T, Watanabe M, Komine O, Shibuya T, Tokunaga A, *et al.* Keratinocyte growth factor receptor expression in normal colorectal epithelial cells and differentiated type of colorectal cancer. Oncol Rep 2005;13:247-52.
33. Hille A, Gröger S, Christiansen H, Wolff HA, Volkmer B, Lehmann J, *et al.* Effect of tumour-cell-derived or recombinant keratinocyte growth factor (KGF) on proliferation and radioresponse of human epithelial tumour cells (HNSCC) and normal keratinocytes *in vitro*. Radiat Environ Biophys 2010;49:261-70.
34. Vairaktaris E, Ragos V, Yapijakis C, Derka S, Vassiliou S, Nkenke E, *et al.* FGFR-2 and -3 play an important role in initial stages of oral oncogenesis. Anticancer Res 2006;26:4217-21.
35. Ceccarelli S, Romano F, Angeloni A, Marchese C. Potential dual role of KGF/KGFR as a target option in novel therapeutic strategies for the treatment of cancers and mucosal damages. Expert Opin Ther Targets 2012;16:377-93.