

Graft-vs-Host Disease After Liver Transplantation: A Diagnostic and Management Challenge

Jerry Yung-Lun Chin, MBBS¹, Jiayi Gong, MClInPharm², and Edward Gane, MD, FRACP¹

¹New Zealand Liver Transplant Unit (NZLTU), Auckland City Hospital, Auckland, New Zealand

²Department of Pharmacy, Auckland City Hospital, Auckland, New Zealand

ABSTRACT

A 65-year-old White man underwent deceased donor liver transplant for decompensated liver cirrhosis secondary to alpha-1-antitrypsin deficiency. He developed diarrhea and diffuse maculopapular rash 2 months post-transplant. Skin biopsy revealed necroinflammatory changes related to the superficial dermis. Pancytopenia ensued, complicated by neutropenic sepsis. Chimerism studies confirmed the presence of donor T-lymphocyte macrochimerism (63%). The patient was diagnosed with graft-vs-host disease. After extensive multidisciplinary collaboration, basiliximab was initiated. This resulted in complete symptom resolution and a gradual reduction in T-lymphocyte macrochimerism (12%). The patient was later transitioned to oral ruxolitinib and currently remains in stable condition 16 months after being diagnosed with graft-vs-host disease.

INTRODUCTION

Graft-vs-host disease (GVHD) after liver transplant is an infrequent complication that carries poor prognostication and is associated with 6-month mortality up to 75%.¹ Diagnosis can be challenging because of the nonspecific and often overlapping symptoms that can be observed with other causes. The presence of donor T-lymphocyte macrochimerism is crucial in securing the diagnosis. We present a case of GVHD in liver transplant and our treatment experience with novel immunotherapeutic agents.

CASE REPORT

A 65-year-old White man with decompensated liver cirrhosis secondary to alpha-1-antitrypsin deficiency underwent deceased donor orthotopic liver transplant. He had uneventful postoperative recovery with no rejection and was discharged from hospital on postoperative day 9 with routine immunosuppression consisting of tacrolimus, prednisone, and mycophenolate. Cytomegalovirus (CMV) status was D+/R+, and therefore, the patient did not receive CMV prophylaxis but underwent monitoring for CMV reactivation.

Two months post-transplant, the patient presented with profuse diarrhea up to 15 times per day. He also reported onset of maculopapular truncal rash with relative sparing of limbs (Figure 1). Mycophenolate had been stopped per institutional protocol before the onset of diarrhea. CMV viremia was detected (8,596 IU/mL in plasma). Flexible sigmoidoscopy was performed, which demonstrated diffuse erythema in the left hemicolon with interspersed shallow ulcerations that were biopsied. Histopathology demonstrated the presence of inclusion bodies, suggestive of CMV disease. In addition, crypt “drop out” and cellular apoptosis were observed on histology indicating possible ischemia. The patient was commenced on treatment dose valganciclovir, with only mild improvement of diarrhea. Skin biopsy revealed necrosis of the superficial dermis, including apoptotic keratinocytes and lymphocytic infiltrate in the papillary dermal plexus. He was commenced on topical steroid with mild improvement. Graft function remained normal during this period.

Furthermore, our patient developed pancytopenia and neutropenic sepsis. A second skin biopsy was performed because of persisting rash, which revealed intense destruction of the epidermis with significant lymphocytic infiltration. T-lymphocyte chimerism studies

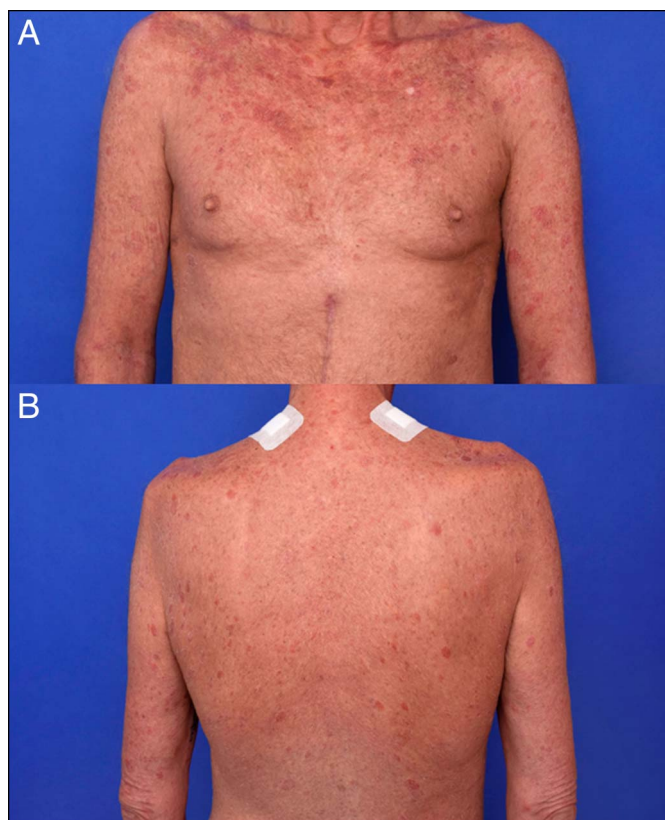

Figure 1. Skin rash involving the trunk with relative sparing of the extremities.

were performed by DNA profile analysis to calculate peak height percentages and the contribution of donor and recipient alleles. This demonstrated the presence of donor T lymphocyte macrochimerism at 63% (normally <1%), ultimately confirming the diagnosis of GVHD associated with liver transplant.

Methylprednisolone was commenced at an initial dose of 120 mg/d and later transitioned to oral steroid and tapered off. Tacrolimus dose was reduced. Basiliximab was initiated at a weekly dose of 20 mg and later titrated down to 20 mg fortnightly. This resulted in rapid improvement of diarrhea and skin rash with eventual resolution (Figure 2). However, our patient experienced further infectious complications, including CMV retinitis, managed with intraocular foscarnet injection. Despite recurrent infections, our patient remained clinically stable. He was transitioned and maintained on twice-daily oral ruxolitinib (10 mg). T-lymphocyte burden continued to downtrend since the initiation of basiliximab, with monthly chimerism studies to monitor treatment response (Figure 3).

DISCUSSION

GVHD is a rare condition after liver transplant, with an estimated incidence of up to 2%. To date, there have been approximately 160 cases reported worldwide on adult liver transplant

recipients.¹ GVHD occurs because of immunocompetent donor cells recognizing recipient cells as foreign and thus resulting in the activation, proliferation, and clonal expansion of donor T-lymphocytes.² This leads to an immune response against the recipient. Proposed risk factors for developing GVHD include older recipient age, human leukocyte antigen class I mismatch, and patients with hepatocellular carcinoma.¹

Most cases occur in the early post-transplant period. The most common clinical features of GVHD after liver transplant include diarrhea, skin rash, and cytopenia. The symptoms are nonspecific, and therefore, considerations need to be given to exclude common etiologies such as infections and drugs. Murali et al proposed a diagnostic algorithm which includes (i) demonstration of the absence of infective etiology, (ii) histological changes consistent with GVHD in the affected organ, and (iii) presence of T-cell macrochimerism (>1%).¹

There remain more questions than answers regarding treatment recommendations. This is predominantly because of a lack of prospective studies with large enough samples. Various treatment regimens have yielded poor outcome with mortality rates as high as over 70%. High-dose intravenous steroids and an increase in calcineurin inhibitor dose have been associated with high mortality, whereas agents such as interleukin-2 antagonists have shown promise, albeit small number. Furthermore, tumor necrosis factor- α inhibitors and rituximab have also been trialed with improved outcomes.¹ Despite seemingly better survival with newer agents, mortality is still substantial

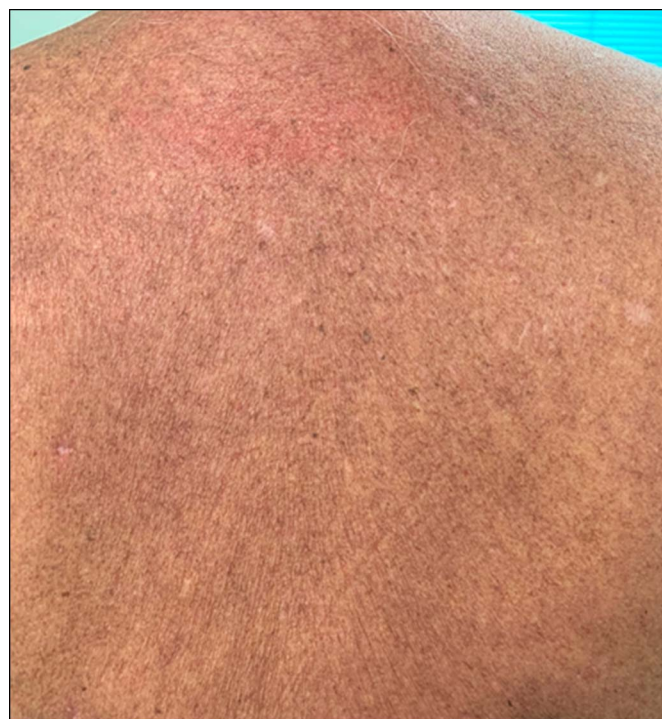

Figure 2. Resolution of skin rash after initiation of basiliximab.

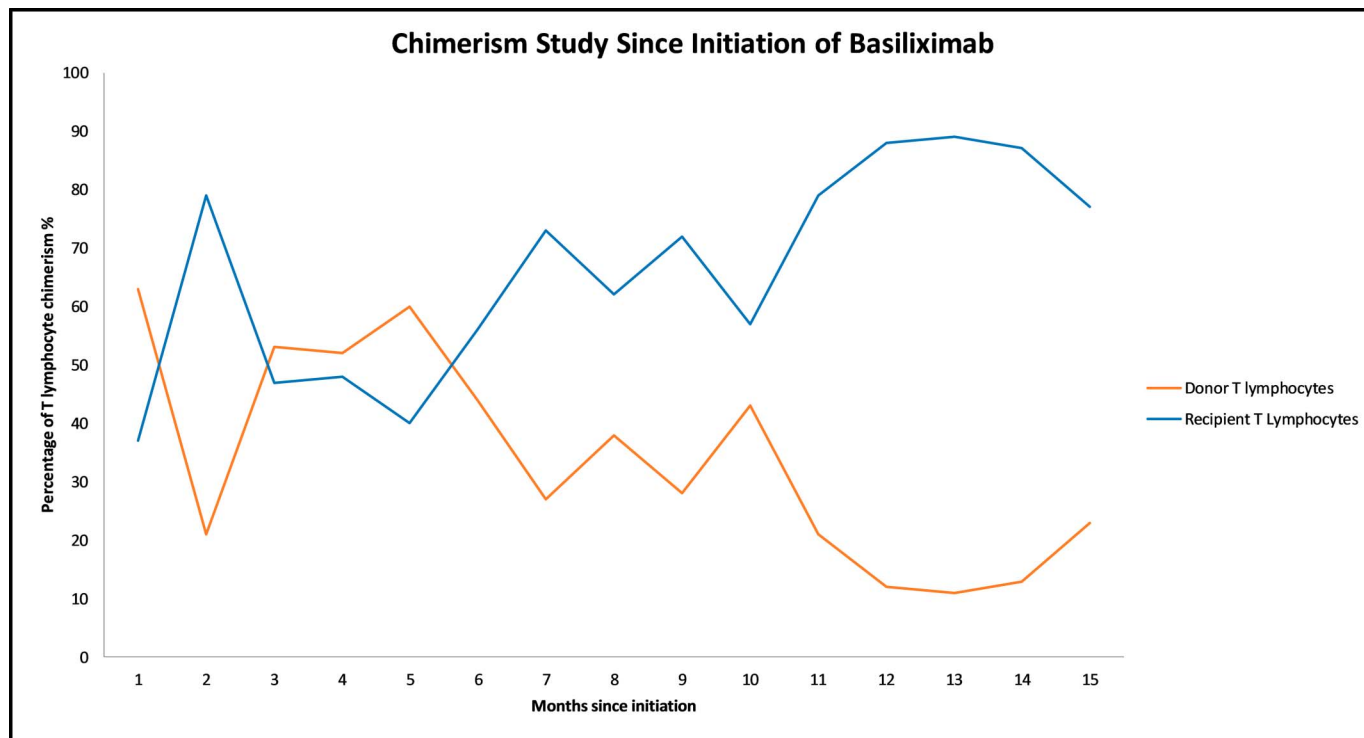


Figure 3. Donor and recipient chimerism since the initiation of basiliximab.

(40%).¹⁻³ Sepsis is the leading cause of mortality in this subset of heavily immunosuppressed patients.

Ruxolitinib is a selective Janus kinase I/II inhibitor that has recently been shown to have suppressive activity against acute and chronic steroid-resistant GVHD after allogeneic hematopoietic stem cell transplant. Two studies have reported treatment response from 50% to 80%.^{4,5} Other cohorts have demonstrated even higher response rates from 70% to 100%.^{6,7} The Food and Drug Administration recently approved ruxolitinib for the treatment of steroid-resistant GVHD. Potential adverse effects relating to ruxolitinib include pancytopenia, electrolyte imbalance (hypokalemia), and peripheral edema.⁸ Recent case series described 3 cases of steroid-resistant GVHD in solid organ transplants managed with ruxolitinib with an initial response.⁹ The first published case report described a complete and sustained remission of GVHD with ruxolitinib monotherapy, with no adverse events noted such as opportunistic infections or myelosuppression.¹⁰

The decision to switch our patient to ruxolitinib was based on the perceived therapeutic advantage in conjunction with patient preference. We believe that switching to ruxolitinib may have a steroid and calcineurin inhibitor sparing effects and able to decrease risks of opportunistic infections while effectively treating GVHD.⁹ Moreover, as an orally administered agent, it carries practical advantage for the patient over intravenous infusions, with less frequent trips to healthcare facilities where he may be exposed to nosocomial organisms.

GVHD is a rare condition with multiorgan involvement. The liver allograft is unaffected. Novel therapeutic agents have shown promise, but long-term efficacy remains unclear. Transplant providers should assume an index of suspicion in early post-transplant patients who present with suspicious symptoms.

DISCLOSURES

Author contributions: JY Chin and J. Gong wrote the manuscript and reviewed the literature and contributed equally to this manuscript. E. Gane revised the manuscript for intellectual content and is the article guarantor.

Financial disclosure: None to report.

Previous presentation: This case was presented at the Australian Gastroenterology Week (AGW); September 8–10, 2019; Adelaide, SA, Australia.

Informed consent was obtained for this case report.

Received May 18, 2020; Accepted August 24, 2020

REFERENCES

- Murali AR, Chandra S, Stewart Z, et al. Graft versus host disease after liver transplantation in adults: A case series, review of literature, and an approach to management. *Transplantation* 2016;12:2661–70.
- Vikrant R, Nicholas ED, Devendra KA. Immunological basis for treatment of graft versus host disease after liver transplant. *Expert Rev Clin Immunol* 2016;12(5):583–93.

3. Markus J, Bukannan A, Kashat B, et al. Contemporary outcomes and risk factors of acute graft-versus-host disease after liver transplant. *Am J Transpl* 2017;17:294.
4. Neumann T, Schneidewind L, Weigel M, et al. Ruxolitinib for therapy of graft-versus-host disease. *Biomed Res Int* 2019;2019:8163780.
5. Zeiser R, Burchert A, Lengerke C, et al. Ruxolitinib in corticosteroid-refractory graft-versus-host disease after allogeneic stem cell transplantation: A multicenter survey. *Leukemia* 2015;29(10):2062–8.
6. Maldonado MS, Villanueva PR, Cotes-Monroy PB, et al. Compassionate use of ruxolitinib in acute and chronic graft versus host disease refractory both to corticosteroids and extracorporeal photopheresis. *Exp Hematol Oncol* 2017;6:32.
7. Assouan D, Lebon D, Charbonnier A, et al. Ruxolitinib as a promising treatment for corticosteroid-refractory graft- versus -host disease. *Br J Haematol* 2018;181(5):687–9.
8. Jagasia M, Ali H, Schoroeder MA, et al. Ruxolitinib in combination with corticosteroids for the treatment of steroid-refractory acute graft-vs-host disease: Results from the phase 2 REACH1 trial. *Biol Blood Marrow Transpl* 2019;25(3):S52.
9. Jacobs MT, Olson M, Ferreira BP, et al. The use of ruxolitinib for acute graft-versus-host disease developing after solid organ transplantation. *Am J Transplant* 2020;20(2):589–92.
10. Endo Y, Oshima G, Hibi T, et al. Achievement of durable and complete remission of graft-versus-host disease after liver transplantation with ruxolitinib: A case report. *Transplantation* 2019;103(11):e375–7.

Copyright: © 2020 The Author(s). Published by Wolters Kluwer Health, Inc. on behalf of The American College of Gastroenterology. This is an open-access article distributed under the terms of the Creative Commons Attribution-Non Commercial-No Derivatives License 4.0 (CCBY-NC-ND), where it is permissible to download and share the work provided it is properly cited. The work cannot be changed in any way or used commercially without permission from the journal.