



Contents lists available at ScienceDirect

## International Journal of Surgery Case Reports

journal homepage: [www.casereports.com](http://www.casereports.com)

## Pediatric open elbow dislocation without fracture: A case report

Gökhan Polat<sup>a</sup>, Gökhan Karademir<sup>a,\*</sup>, Turgut Akgül<sup>a</sup>, Hasan Hüseyin Ceylan<sup>b</sup><sup>a</sup> Istanbul University, Medical Faculty of Istanbul, Department of Orthopedics and Traumatology, Çapa Fatih, 34050 Istanbul, Turkey<sup>b</sup> Sultanciftligi LNB State Hospital, Department of Orthopedics and Traumatology, Sultanciftligi, 34265 Istanbul, Turkey

## ARTICLE INFO

## Article history:

Received 7 August 2014

Received in revised form 23 October 2014

Accepted 24 October 2014

Available online 31 October 2014

## Keywords:

Elbow  
Dislocation  
Fracture  
Pediatric  
Children  
Open

## ABSTRACT

**INTRODUCTION:** Elbow dislocations in children are rare injuries. These injuries are often in the form of complex injuries that is accompanied by the median nerve damage and medial epicondyle fracture in the pediatric age group. Open elbow dislocation without fracture in the pediatric age group has been reported very rarely in the literature.

**PRESENTATION OF CASE:** The purpose of this study is to present an 8-year-old patient who has open elbow dislocation without fracture accompanying with brachial artery injury. In the clinical examination of the patient, there was an open wound in the transverse antecubital region. After repair of brachial artery injury, open reduction was performed under general anesthesia. In the postoperative clinical examination at 6 months, left elbow flexion was 140°, extension was full and there were no deficit in the supination and pronation of the forearm.

**DISCUSSION:** Elbow dislocation without fracture in pediatric patients is a very rare injury. Usually the trauma mechanism of elbow dislocation is falling on outstretched hand with elbow in approximately 30° of flexion. However our patient had fallen on outstretched hand with elbow in full extension. Although this type of trauma mechanism is typical for supracondylar humerus fractures in pediatric age group, in our patient an open posterior elbow dislocation without fracture had occurred.

**CONCLUSION:** Pediatric elbow dislocations are rare injuries and the management of these injuries can be technically demanding due to concurrent neurovascular injuries. An open dislocation without fracture is very rare and it should be treated with immediate intervention, an effective teamwork and good rehabilitation.

© 2014 The Authors. Published by Elsevier Ltd. on behalf of Surgical Associates Ltd. This is an open access article under the CC BY-NC-SA license (<http://creativecommons.org/licenses/by-nc-sa/3.0/>).

## 1. Introduction

Pediatric elbow dislocations are rare injuries, which compose 3–6% of childhood elbow injuries.<sup>8,17</sup> They are often seen in the age groups of 11–15 years.<sup>13</sup> The most common occurrences are posterior elbow dislocations.<sup>9,11,13</sup> Generally pediatric elbow dislocations are complex traumas that are associated with fractures around elbow, medial epicondyle avulsion fractures and median nerve injuries.<sup>6,20</sup> Although they are rare injuries, some studies have been reported in the literature.<sup>8</sup> These studies are mostly about pediatric elbow dislocations with concomitant fractures around elbow.<sup>8,16</sup>

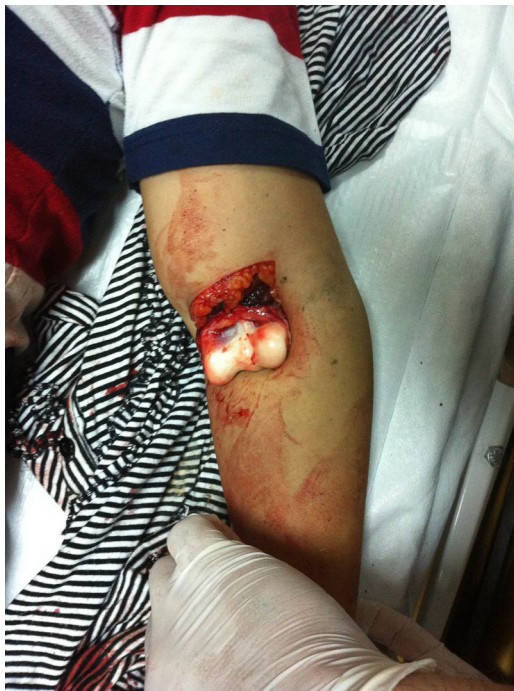The purpose of this study is to present an 8-year-old patient who has open elbow dislocation without fracture accompanying with brachial artery injury.

## 2. Case report

An 8-year-old boy had admitted to our emergency department after falling on his left hand with outstretched upper extremity. The patient had admitted to our clinic 30 min after trauma. In the clinical examination of the patient, there was an open wound in the transverse antecubital region. Distal humerus and articular surface could be seen by looking through the wound (Fig. 1). Although neurological examination showed us no pathology, distal pulses could not be palpated in vascular examination. In the conventional radiographies, a posterior elbow dislocation without accompanying fracture was detected (Fig. 2). Because of the strong possibility of brachial artery injury, the patient had consulted to the vascular surgeon and an emergent surgical intervention had planned for this patient.

\* Corresponding author. Dr. Gökhan Karademir at: Istanbul University, Medical Faculty of Istanbul, Department of Orthopedics and Traumatology, Çapa Fatih. Tel.: +90 212 414 20 00; fax: +90212 410 15 00.

E-mail address: [dr@gokhankarademir.com](mailto:dr@gokhankarademir.com) (G. Karademir).



**Fig. 1.** First visit photograph of the left elbow demonstrates an open wound in the transverse region, distal humerus and articular surface could be seen by looking through the wound.

The patient received emergent surgery under general anesthesia. The transverse incision had lengthened 1 cm and the buttonhole dislocation had released. Following the exploration of the open wound in the elbow, open reduction was performed. Intra-articular debris was washed out. Brachial artery was identified in the open wound without continuity and distal pulses were still impalpable. The vascular surgeon had attended to the surgery and the brachial artery had repaired primarily. After the treatment of vascular pathology, the stability of the elbow was evaluated and the elbow was stable during 0–140° of flexion and extension. Varus and valgus stress tests were negative. Due to the stability of the elbow, we decided to follow this patient with splint instead of an external fixator. The wound was closed in a standard fashion with the approval of vascular surgeon; upper elbow splint was applied at 100°. We did not observe any postoperative vascular or wound complications in the follow-up. After 4 weeks follow-up with splint, using angle adjustable hinge elbow orthotics started controlled active assistive exercises. By the end of the 12th week, the orthotics was removed and movement was completely allowed.

Six months after the operation patient had no any complaints about his elbow. The patient's elbow range of motion,

in supination–pronation arc, has been detected as 80–85° and in extension–flexion arc; range of motion has been detected as 0–140° (Fig. 3). There was no varus–valgus instability. In conventional radiographies, Hastings class II heterotopic ossification was detected between the anterior capsule and the brachialis muscles (Fig. 4).

### 3. Discussion

Elbow dislocations are the most common joint dislocations at pediatric age group.<sup>10,16</sup>

Posterior dislocation is the most common direction for these injuries and mostly there are associated fractures around elbow.<sup>8,9</sup> Elbow dislocation without fracture in pediatric patients is a very rare injury. According to our knowledge there are not numerous similar studies for these rare injuries in the literature.

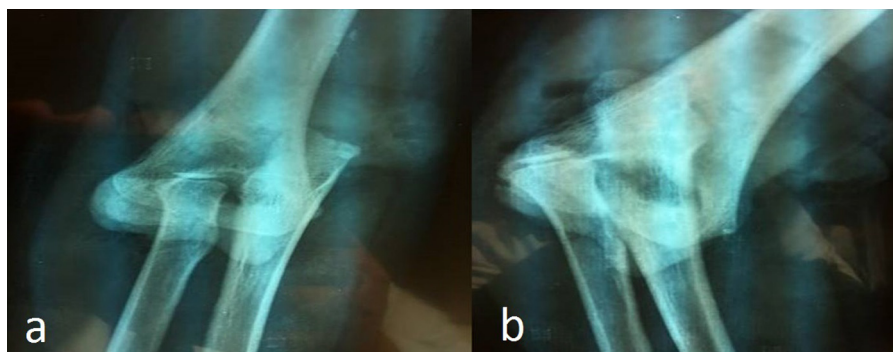
Usually the trauma mechanism of elbow dislocation is falling on outstretched hand with elbow in approximately 30° of flexion.<sup>3</sup> However our patient had fallen on outstretched hand with elbow in full extension. Although this type of trauma mechanism is typical for supracondylar humerus fractures in pediatric age group, in our patient an open posterior elbow dislocation without fracture had occurred.

Concomitant vascular injuries and open dislocations are classified as complex dislocations that are often fracture dislocations. In these complex elbow dislocations there are usually associated fractures like coronoid, radial head and medial epicondyle. Associated pathologies like compartment syndrome, neurological injury (10%) (most often the median nerve), vascular injuries (6–8%), and complications like residual instability and heterotopic ossifications are observed in the treatment of these rare injuries.<sup>1,4</sup>

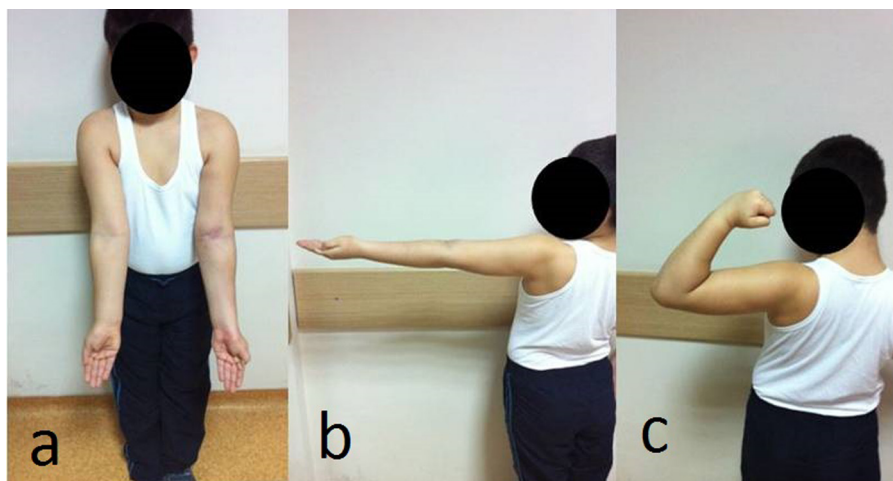
In the literature, complex open elbow dislocations without fracture have not been well described in pediatric population. In the pediatric population, little studies that describing complex elbow fracture dislocations are reported. However pediatric open elbow dislocations without fracture are much more rare.<sup>15,19</sup>

Elbow dislocations frequently occur with medial epicondyle fractures. Sharma et al. presented 12-year-old boy who had a closed posterolateral dislocated elbow with a concurrent Milch type II lateral condyle fracture. They obtained closed reduction in the emergency department under sedation. They subsequently applied open reduction and K-wire fixation for lateral condyle fracture.<sup>17</sup>

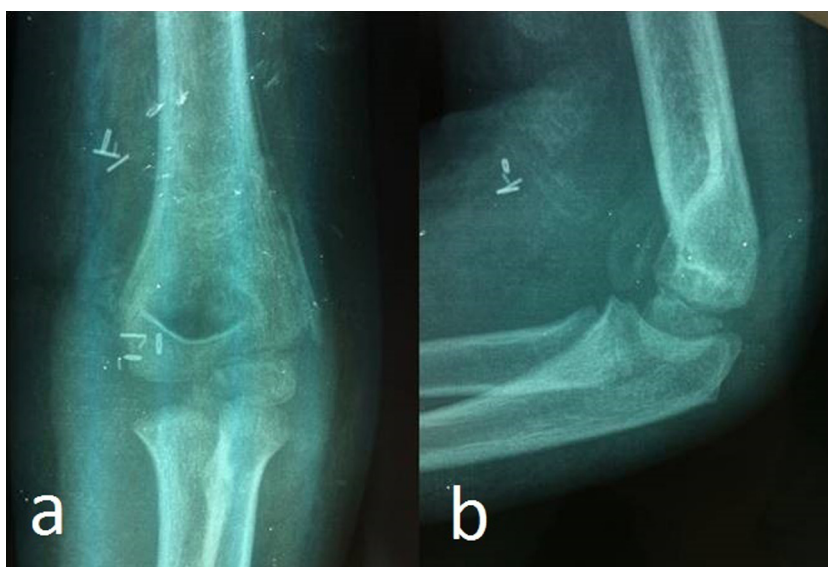
Medial epicondyle avulsion fractures may be associated with complex pediatric elbow dislocations. In some dislocated elbows, the medial epicondyle had avulsed from the apophysis.<sup>2</sup> The clinician should beware of possible entrapment of medial epicondyle in the joint especially after closed reduction.<sup>7,12,14,18</sup> Especially before the ossification of medial epicondyle (under the age of 7), mistaken of this pathology is more possible. Fowles et al. reported



**Fig. 2.** (a) Anteroposterior, (b) lateral view radiograph of the left. Elbow at the first visit, a dislocation was detected at the left elbow.



**Fig. 3.** Six months after the operation, photograph of the left elbow demonstrates (a) supination and (b) extension was full. Elbow range of motion, in (c) flexion–extension arc, has been detected as 0–140°.



**Fig. 4.** (a) Anteroposterior, (b) lateral view radiograph of the left. Elbow at the control visit Hastings class II heterotopic ossification was detected between the anterior capsule and the brachialis muscles.

a mistaken medial epicondyle fracture entrapment in a pediatric patient in 1990.<sup>5</sup>

#### 4. Conclusions

Pediatric elbow dislocations are rare injuries and the management of these injuries can be technically demanding due to concurrent neurovascular injuries. An open dislocation without fracture is very rare and it should be treated with immediate intervention, an effective teamwork and good rehabilitation.

#### Conflict of interest

No financial conflicts of interest.

#### Funding

All authors did not receive any grant supports for this report.

#### Ethical approval

This case report is written based on institutional ethical committee.

#### Author contributions

Gökhan Polat and Gökhan Karademir made study design. Gökhan Polat had performed the surgery with Turgut Akgül. Gökhan Polat and Gökhan Karademir, Hasan H Ceylan helped in English language editing and writing the manuscript. Hasan H Ceylan had taken the photos.

#### References

1. Ayel JE, Bonneville N, Lafosse JM, Pidhorz L, Al Homsy M. Acute elbow dislocation with arterial rupture. Analysis of nine cases. *Orthop Traumatol Surg Res* 2009;**95**(5):343–51, <http://dx.doi.org/10.1016/j.otsr.013.200904>.
2. Bauer S, Dunne B, Whitewood C. Simultaneous bilateral elbow dislocation with bilateral medial epicondyle fractures in a 13-year-old female gymnast with hyperlaxity. *BMJ Case Rep* 2012;**12**, <http://dx.doi.org/10.1136/bcr-2012-006972>.



3. Canale ST, Beatty JH. Fractures and dislocations in children, elbow dislocation. In: Canale ST, Beatty JH, editors. *Campbell's operative orthopaedics*. 12th ed. Philadelphia: Elsevier; 2013., ISBN 978-0-8089-2430-2 p. 1390–9.
4. Cheung EV, O'Driscoll SW. Spontaneous regression of postoperative ossification about the elbow: a case report. *J Shoulder Elbow Surg* 2007;**16**(6):e15–6, <http://dx.doi.org/10.1016/j.jse.2006.10.005>.
5. Fowles JV, Kassab MT, Moula T. Untreated intra-articular entrapment of the medial humeral epicondyle. *J Bone Joint Surg Br* 1984;**66**(4):562–5.
6. Hanlon CR, Estes Jr WL. Fractures in childhood, a statistical analysis. *Am J Surg* 1954;**87**(3):312–23, [http://dx.doi.org/10.1016/S0002-9610\(54\)90128-2](http://dx.doi.org/10.1016/S0002-9610(54)90128-2).
7. Inoue G. Neglected intraarticular entrapment of the medial epicondyle after dislocation of the elbow. *J Shoulder Elbow Surg* 1994;**3**(5):320–2, [http://dx.doi.org/10.1016/S1058-2746\(09\)80077-3](http://dx.doi.org/10.1016/S1058-2746(09)80077-3).
8. Isaac SM, Danial I, Modi A. Isolated posterior elbow dislocation in a one-year-old child: a case report. *Acta Orthop Belg* 2009;**75**(1):133–5.
9. Kim SJ, Ji JH. Irreducible posteromedial elbow dislocation: a case report. *J Shoulder Elbow Surg* 2007;**16**(6):e1–5, <http://dx.doi.org/10.1016/j.jse.2006.09.013>.
10. Kuhn MA, Ross G. Acute elbow dislocations. *Orthop Clin North Am* 2008;**39**(2):155–61, <http://dx.doi.org/10.1016/j.jocl.2007.12.004>.
11. Lieber J, Zundel SM, Luithle T, Fuchs J, Kirschner HJ. Acute traumatic posterior elbow dislocation in children. *J Pediatr Orthop B* 2012;**21**(5):474–81.
12. Lima S, Correia JF, Ribeiro RP, Martins RM, Alegrete N. A rare case of elbow dislocation associated with unrecognized fracture of medial epicondyle and delayed ulnar neuropathy in pediatric age. *J Shoulder Elbow Surg* 2013;**22**(3):e9–11, <http://dx.doi.org/10.1016/j.jse.2012.11.009>.
13. Alexander MG, Graham HK. Dislocations of the elbow in children. In: Stanley D, Trail I, editors. *Operative elbow surgery*. Philadelphia: Elsevier; 2012., ISBN 978-0-7020-3099-4 p. 203–22.
14. Reed MW, Reed DN. Acute ulnar nerve entrapment after closed reduction of a posterior fracture dislocation of the elbow: a case report. *Pediatr Emerg Care* 2012;**28**(6):570–2, <http://dx.doi.org/10.1097/PEC.0b013e318258bfba>.
15. Rovinsky D, Ferguson C, Younis A, Otsuka NY. Pediatric elbow dislocation associated with a Milch type I lateral condyle fracture of the humerus. *J Orthop Trauma* 1999;**13**(6):458–60.
16. Saied A, Moussavi AA. Elbow dislocation translocation in a child: a case report. *J Shoulder Elbow Surg* 2007;**16**(6):e17–9, <http://dx.doi.org/10.1016/j.jse.2006.10.008>.
17. Sharma H, Ayer R, Taylor GR. Complex pediatric elbow injury: an uncommon case. *BMC Musculoskelet Disord* 2005;**6**(March):13.
18. Tropet Y, Menez D, Brientini JM, Vichard P. Entrapment of the median nerve after dislocation of the elbow. *Acta Orthop Belg* 1989;**55**(2):217–21.
19. Van Haaren ER, Van Vugt AB, Bode PJ. Posterolateral dislocation of the elbow with concomitant fracture of the lateral humeral condyle: case report. *J Trauma* 1994;**36**(2):288–90.
20. Weise K, Schwab E, Scheufele TM. Elbow injuries in childhood. *Unfallchirurg* 1997;**100**(4):255–69.

#### Open Access

This article is published Open Access at [sciendo.com](http://sciendo.com). It is distributed under the [IJSCR Supplemental terms and conditions](#), which permits unrestricted non commercial use, distribution, and reproduction in any medium, provided the original authors and source are credited.