



## De novo Vogt-Koyanagi-Harada disease after vaccination for COVID-19, successfully treated with systemic steroid therapy and monitored with laser speckle flowgraphy

Chiaki Yamaguchi<sup>a</sup>, Hiroshi Kunikata<sup>a,b,\*</sup>, Kazuki Hashimoto<sup>a</sup>, Masaaki Yoshida<sup>a</sup>, Takahiro Ninomiya<sup>a</sup>, Takehiro Hariya<sup>a</sup>, Toshiaki Abe<sup>c</sup>, Toru Nakazawa<sup>a,b,d,e</sup>

<sup>a</sup> Department of Ophthalmology, Tohoku University Graduate School of Medicine, Sendai, Japan

<sup>b</sup> Department of Retinal Disease Control, Tohoku University Graduate School of Medicine, Sendai, Japan

<sup>c</sup> Division of Clinical Cell Therapy, United Centers for Advanced Research and Translational Medicine, Tohoku University Graduate School of Medicine, Sendai, Japan

<sup>d</sup> Department of Advanced Ophthalmic Medicine, Tohoku University Graduate School of Medicine, Sendai, Japan

<sup>e</sup> Department of Ophthalmic Imaging and Information Analytics, Tohoku University Graduate School of Medicine, Sendai, Japan

### ARTICLE INFO

#### Keywords:

Vogt-Koyanagi-Harada disease  
COVID-19  
Vaccination  
mRNA vaccine  
Laser speckle flowgraphy  
Mean blur rate

### ABSTRACT

**Purpose:** Vogt-Koyanagi-Harada (VKH) disease after vaccination for coronavirus disease 2019 (COVID-19) is rare, and the prognosis for this condition and its effect on ocular blood flow remains unclear. The purpose of this paper is to present the first case of de novo VKH disease after the second vaccination for COVID-19 with an mRNA vaccine that was successfully treated with systemic steroid therapy and monitored with laser speckle flowgraphy (LSFG).

**Observations:** A 30s-year-old Japanese woman reported bilateral decreased visual function 2 weeks after receiving a second dose of the BNT162b2 mRNA vaccine. Best-corrected visual acuity was 20/50 OD and 20/70 OS. Optical coherence tomography revealed bilateral serous retinal detachment over the swollen choroidal layer. LFSG showed decreased blood flow in the peripapillary region of both eyes. This case was diagnosed as complete VKH syndrome, and the patient underwent systemic steroid therapy. After treatment, the retinal detachment disappeared, choroidal thickness decreased, and ocular blood flow increased. Three months later, visual acuity recovered to 20/20 in both eyes.

**Conclusions:** Caution should be exercised in cases with visual symptoms after COVID-19 vaccination, even after more than one dose and more than one week after vaccination. LFSG may be a useful way to measure the ocular blood flow response to treatment and determine the prognosis for VKH disease after COVID-19 vaccination.

### 1. Introduction

Coronavirus disease 2019 (COVID-19) is an infectious disease accompanied by severe, acute respiratory syndrome associated with coronavirus 2 (SARS-CoV-2). Severe cases of COVID-19 are considered to be associated with the excessive cytokine release and immune hyperactivation, leading to multiple organ failure. Thus, the pandemic has led to an unprecedented pace of development of new vaccines for COVID-19 worldwide within the last two years. Although vaccination may control the pandemic, unfortunately, malaise, fever, uveitis, and other ocular complications have been reported after the administration of COVID-19 vaccines.<sup>1,2</sup> Vogt-Koyanagi-Harada (VKH) disease after

vaccination is rare, and its prognosis remains unclear.<sup>3-7</sup> VKH disease is known as a type of bilateral uveitis associated with alopecia, metamorphopsia (a disorder in which the shape of objects appears distorted), vitiligo, poliosis, dysacusia, meningeal irritation abnormalities of the cerebrospinal fluid,<sup>8</sup> and ocular circulation impairment.<sup>9,10</sup> The current report describes the first reported Japanese case of VKH disease two weeks after administration of the second dose of a COVID-19 mRNA vaccine. VKH disease causes inflammation of the choroid, so we evaluated choroidal blood flow over time using laser speckle flowgraphy (LSFG). LSFG can measure ocular blood flow noninvasively. This technique, based on the laser speckle phenomenon, has been reported to be useful for clinical diagnosis or monitoring of glaucoma and retinal

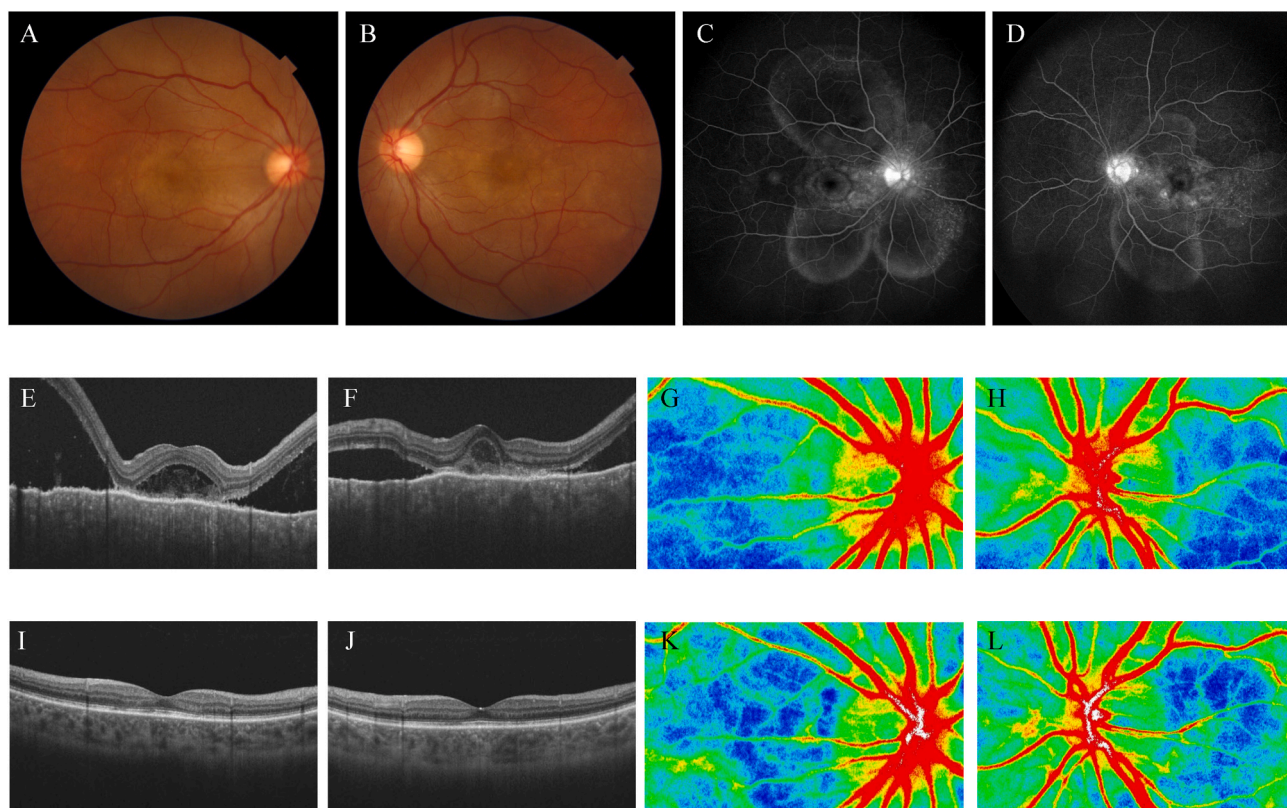
\* Corresponding author. Department of Ophthalmology, Tohoku University Graduate School of Medicine, 1-1 Seiryomachi, Aoba-ku, Sendai, 980-8574, Japan.  
E-mail address: [kunikata@oph.med.tohoku.ac.jp](mailto:kunikata@oph.med.tohoku.ac.jp) (H. Kunikata).

<https://doi.org/10.1016/j.ajoc.2022.101616>

Received 18 March 2022; Received in revised form 6 June 2022; Accepted 9 June 2022

Available online 11 June 2022

2451-9936/© 2022 The Authors. Published by Elsevier Inc. This is an open access article under the CC BY-NC-ND license (<http://creativecommons.org/licenses/by-nc-nd/4.0/>).



**Fig. 1.** A, B: Pretreatment fundus photographs. A slightly reddish disc with SRD around the optic disc and over the macula is present bilaterally (A: right eye; B: left eye).

C, D: Fluorescein angiography images in the late phase before treatment. Optic disc hyperfluorescence, hyperfluorescence points over the posterior pole, and pooling of the fluorescent dye at the SRD are present bilaterally (C: right eye; D: left eye).

E, F: Pretreatment OCT images. SRD is present over the swollen choroidal layer in both eyes (E: right eye; F: left eye).

G, H: Pretreatment LSF color maps. Blue and cooler colors are dominant in the peripapillary region of both eyes (G: right eye; H: left eye). The colors in this map represent time averages of mean blur rate over one heartbeat; warmer colors represent higher blood flow.

I, J: Posttreatment OCT images. The SRD has disappeared completely and choroidal thickness has decreased in both eyes (I: right eye; J: left eye).

K, L: Posttreatment LSF color maps. Green and warmer colors are dominant in the peripapillary region in both eyes (K: right eye; L: left eye), indicating that the pretreatment decrease in choroidal circulation has returned to normal levels after systemic steroid therapy. (For interpretation of the references to color in this figure legend, the reader is referred to the Web version of this article.)

diseases.<sup>11,12</sup> VKH disease is an autoimmune disease caused by auto-antibodies against melanocytes and is initially treated with systemic steroids. This case was successfully treated with systemic steroid therapy and monitored with LSF.

## 2. Case report

A 30s-year-old woman visited Tohoku University Hospital, located in Sendai, Japan, with ocular symptoms after receiving the SARS-CoV-2 mRNA vaccine (BNT162b2). One week after the second dose, she noticed metamorphopsia in her right eye and headache. Two weeks after the vaccination, she noticed bilateral decreased visual function. Best-corrected visual acuity (BCVA) was 20/50 OD and 20/70 OS. Intraocular pressure was 16 mmHg in both eyes. Anterior chamber inflammation was noted with 1+ cells in both eyes, and laser flare photometry (LFP) values were 10.5 ph/ms OD and 14.3 ph/ms OS (normal values are 4–6 ph/ms). LFP provides an automated technique to objectively quantify cells and protein levels (termed “flare”) in the aqueous humor.<sup>13</sup> Fundus examination showed serous retinal detachment (SRD) over the posterior pole, retinal venous dilation, and optic disc hyperemia in both eyes (Fig. 1 A and B). Fluorescein angiography revealed multiple hyperfluorescence points over the posterior pole bilaterally in the early phase. Optic disc leakage and pooling of the fluorescent dye in the area of the SRD were confirmed in the late phase (Fig. 1 C and D). Optical coherence tomography (OCT) revealed a bilateral SRD over the swollen

choroidal layer, such that no measurement was possible (Fig. 1 E and F). LSF showed decreased blood flow in the peripapillary region (i.e., decreased choroidal blood flow) in both eyes (Fig. 1 G and H). Systemic evaluation was nonspecific, with mononuclear cells (70 cells/ $\mu$ L) in the cerebrospinal fluid. An infectious work-up was negative. This patient had no history of penetrating ocular trauma or surgery preceding the initial onset of uveitis. She had bilateral diffuse choroiditis and serous retinal detachments, neurological findings of mononuclear cells in the cerebrospinal fluid, and integumentary findings of alopecia, prompting us to diagnose the case as complete VKH syndrome according to the revised diagnostic criteria.<sup>14</sup>

We decided to apply vigorous and sustained treatment to suppress the inflammation, starting with intravenous methylprednisolone (1000 mg/day) for 3 days followed by oral prednisolone (60 mg/day) without the use of topical steroid. Upon tapering the oral prednisone, ocular findings in the anterior chamber returned to normal, LFP values improved to 5.7 ph/ms OD and 10.4 ph/ms OS, the SRD disappeared completely, and choroidal thickness decreased (Fig. 1 I and J). LSF showed that the pretreatment decrease in choroidal circulation returned to near normal in parallel with the decrease in the SRD 3 months after starting the systemic steroid therapy (Fig. 1 K and L). Finally, BCVA recovered to 20/20 in both eyes.

**Table 1**  
Comparison with previous case reports of VKH disease after vaccination for COVID-19.

Study	Age/ sex	Type of vaccine	Dose	Time to onset of visual symptoms	Type of VKH disease	Pretreatment BCVA (OD, OS)	Final BCVA (OD, OS)	Route of administration of systemic corticosteroid therapy
Reddy Y et al.	30/F	AZD1222	1st	7 days	SRD	CF, CF	6/9, 6/9	Oral
Kim SY et al.	72/F	AZD1222	1st	3 days	ODS	20/40, 20/40	20/20, 20/ 20	Intravenous for 3 days followed by oral
Brunet de Courssou JB et al.	57/F	BNT162b2	1st	5 weeks	SRD	20/60, 20/80	20/20, 20/ 20	Intravenous for 3 days followed by oral
Saraceno JJF et al.	62/F	AZD1222	1st	4 days	SRD	20/600, 20/200	20/20, 20/ 20	Oral
Koong LR et al.	54/M	BNT162b2	1st	4 days	SRD	6/24, 6/45	6/12, 6/12	Intravenous for 3 days followed by oral
Current	30s/F	BNT162b2	2nd	2 weeks	SRD	20/50, 20/70	20/20, 20/ 20	Intravenous for 3 days followed by oral

VKH = Vogt-Koyanagi-Harada, BCVA = best-corrected visual acuity, SRD = serous retinal detachment, ODS = optic disc swelling, CF = counting fingers, HM = hand motion.

### 3. Discussion

Although the exact pathogenesis of VKH disease remains unclear, it is generally considered to be caused by CD4<sup>+</sup> T cells that target melanocytes. CD4<sup>+</sup> T cells are activated by IL-6 and TGF- $\beta$ , differentiate into Th17 cells, and proliferate after cytokine activation due to IL-23, resulting in uveitis.<sup>15</sup> The actual onset of VKH disease may be associated with genetic factors and viral infections. Cold symptoms are well known as an antecedent sign of VKH, and VKH after COVID-19 infection has also been reported.<sup>6,16,17</sup> The causal relationship between COVID-19 vaccines and ocular inflammation, including uveitis, is unclear. Commonly proposed mechanisms of vaccine-associated uveitis include molecular mimicry and antigen-specific cells, as well as antibody-mediated hypersensitivity reactions.<sup>18</sup> Since inert spike antigen proteins are produced by mRNA vaccines for COVID-19, which affect coded protein production, SARS-CoV-2 mRNA vaccine administration could trigger antibody-mediated acquired immunity. Thus, COVID-19 vaccines might accelerate an abnormal immunological response, leading to the acute onset of VKH disease. It has been reported that systemic reactions, such as fever due to the immune response, occur more frequently and more severely after the second dose of COVID-19 vaccine than after the first dose.<sup>19</sup> In this case, although the patient had a mild reaction after the first dose, we consider that the second dose triggered an immune mechanism. We speculate that proteins generated by the second mRNA vaccine that mimicked melanocyte-specific proteins might have caused VKH disease.

It is also possible that the COVID-19 vaccine caused the reactivation of a long-term controlled case of VKH disease. A case has been reported in which inflammation caused by severe VKH disease was brought under control over several months by treatment with combined steroidal and non-steroidal immunosuppression; following this, a maintenance treatment was administered that consisted of infliximab every 10 weeks for 6 years.<sup>20</sup> The patient remained inflammation-free, but presented with a severe reactivation of the disease six weeks after the second dose of the BNT162b2 vaccine against SARS-CoV-2. This suggests the possibility that vaccination-associated molecular mimicry of certain proteins could reactivate VKH disease. Thus, ophthalmologists should be aware that a COVID-19 vaccine might cause reactivation of controlled VKH disease, or even the onset of de novo VKH disease, after vaccination.

Although some cases of VKH disease cases have a poor visual prognosis, the six post-COVID19 vaccination de novo VKH cases summarized in Table 1, including the current case, showed a relatively good short-term visual prognosis after systemic corticosteroid therapy.<sup>3-7</sup> Furthermore, VKH cases after COVID-19 vaccination are more likely to be female (5 cases, 83%), develop after the first dose (5 cases, 83%), have visual symptoms within one week after vaccination (4 cases, 67%), and have SRD-type VKH (5 cases, 83%). The preponderance of SRD-type VKH disease is similar to general VKH disease,<sup>21</sup> and since patients

with optic disc swelling-type VKH disease have been reported to be more likely to develop chronic disease than patients with SRD-type VKH disease,<sup>21</sup> the risk of developing chronic disease might also be lower in post-COVID-19 vaccination cases of VKH.

The response to treatment of LSFG-measured mean blur rate (MBR), a measure of the relative velocity of ocular blood flow that is expressed in arbitrary units, may be helpful in determining the prognosis for VKH disease after vaccination. It has been confirmed that impaired choroidal circulation occurs during the anterior recurrence of VKH disease, and that this impairment recovers after corticosteroid therapy.<sup>9</sup> A weaker response to treatment has also been reported to be associated with recurrent VKH disease.<sup>10</sup> In the current case, choroidal circulation was also low before treatment, and increased in response to systemic steroid therapy (i.e., MBR strongly responded to treatment) in parallel with the decrease in the SRD and the improvement in BCVA. Thus, we anticipate a favorable long-term outcome in the current case.

This is the first report of VKH disease after the second dose of a COVID-19 vaccine that underwent ocular blood flow monitoring with LSFG. Our patient responded well to systemic steroid therapy. Although most VKH cases after COVID-19 vaccination occur after the first dose and within one week, caution should be exercised when visual symptoms arise, even when a patient has received more than one COVID-19 vaccine dose, or received it more than one week previously. Further investigation is needed to confirm the ocular blood flow status and its response to therapy, as well as the long-term visual prognosis, in cases with VKH disease after COVID-19 vaccination.

#### Patient consent

Consent to publish the case report was not obtained. This report does not contain any personal information that could lead to the identification of the patient.

#### Funding

This paper was supported in part by a grant from JSPS KAKENHI Grants-in-Aid for Scientific Research (C) (H.K. 26462629). The funders had no role in the design or conduct of the study; collection, management, analysis, or interpretation of the data; preparation, review, or approval of the manuscript; or the decision to submit the manuscript for publication.

#### Author contributions

Involved in the design and conduct of the study were (H.K. and T.N.); collection, management, analysis, and interpretation of the data (C.Y., H.K., K.H., M.Y., T.N., T.H. and T.A.); drafting of the manuscript (C.Y. and H.K.); and review and approval of the manuscript (T.N.). C.Y. and H.

K. prepared all figures.

### Authorship

All authors attest that they meet the current ICMJE criteria.

### Declaration of competing interest

The authors declare that there are no conflicts of interest related to this manuscript.

### Acknowledgement

The principal investigator, Dr. Chiaki Yamaguchi, had full access to all the data in the study and takes responsibility for the integrity of the data and the accuracy of the analysis. All procedures conformed to the tenets of the Declaration of Helsinki. This retrospective study was approved by the Review Board of the School of Medicine, Tohoku University.

### References

- Bolletta E, Iannetta D, Mastrofilippo V, et al. Uveitis and other ocular complications following COVID-19 vaccination. *J Clin Med*. 2021;10.
- Ng XL, Betzler BK, Testi I, et al. Ocular adverse events after COVID-19 vaccination. *Ocul Immunol Inflamm*. 2021;29:1216–1224.
- Reddy Y, Pandey A, Ojha A, Ramchandani S. Harada-like syndrome post-Covishield vaccination: a rare adverse effect. *Indian J Ophthalmol*. 2022;70:321–323.
- Kim SY, Kang MS, Kwon HJ. Bilateral panuveitis mimicking vogt-koyanagi-harada disease following the first dose of ChAdOx1 nCoV-19 vaccine. *Ocul Immunol Inflamm*. 2022;1–4.
- Brunet de Coursou JB, Tisseyre M, Hadjadj J, et al. De novo vogt-koyanagi-harada disease following covid-19 vaccine: a case report and literature overview. *Ocul Immunol Inflamm*. 2022;1–4.
- Jjf Saraceno, Souza GM, Dos Santos Finamor LP, Nascimento HM, Belfort Jr R. Vogt-Koyanagi-Harada Syndrome following COVID-19 and ChAdOx1 nCoV-19 (AZD1222) vaccine. *Int J Retina Vitreous*. 2021;7:49.
- Koong LR, Chee WK, Toh ZH, Ng XL, Agrawal R, Ho SL. Vogt-koyanagi-harada disease associated with COVID-19 mRNA vaccine. *Ocul Immunol Inflamm*. 2021;29:1212–1215.
- Perry HD, Font RL. Clinical and histopathologic observations in severe Vogt-Koyanagi-Harada syndrome. *Am J Ophthalmol*. 1977;83:242–254.
- Takemoto Y, Namba K, Mizuuchi K, et al. Choroidal circulation impairment during the anterior recurrence of Vogt-Koyanagi-Harada disease confirmed with indocyanine green angiography and laser speckle flowgraphy. *Acta Ophthalmol*. 2016;94:e629–e636.
- Maruyama K, Noguchi A, Shimizu A, Shiga Y, Kunikata H, Nakazawa T. Predictors of recurrence in vogt-koyanagi-harada disease. *Ophthalmol Retina*. 2018;2:343–350.
- Takahashi N, Kunikata H, Yasuda M, Hariya T, Nishiguchi KM, Nakazawa T. Polypoidal choroidal vasculopathy in a case of retinitis pigmentosa, successfully treated with intravitreal aflibercept. *Am J Ophthalmol Case Rep*. 2021;23, 101123.
- Aizawa N, Kunikata H, Nakazawa T. Diagnostic power of laser speckle flowgraphy-measured optic disc microcirculation for open-angle glaucoma: analysis of 314 eyes. *Clin Exp Ophthalmol*. 2019;47:680–683.
- Ladas JG, Wheeler NC, Morhun PJ, Rimmer SO, Holland GN. Laser flare-cell photometry: methodology and clinical applications. *Surv Ophthalmol*. 2005;50:27–47.
- Read RW, Holland GN, Rao NA, et al. Revised diagnostic criteria for Vogt-Koyanagi-Harada disease: report of an international committee on nomenclature. *Am J Ophthalmol*. 2001;131:647–652.
- Chi W, Yang P, Li B, et al. IL-23 promotes CD4+ T cells to produce IL-17 in Vogt-Koyanagi-Harada disease. *J Allergy Clin Immunol*. 2007;119:1218–1224.
- Anthony E, Rajamani A, Baskaran P, Rajendran A. Vogt Koyanagi Harada disease following a recent COVID-19 infection. *Indian J Ophthalmol*. 2022;70:670–672.
- Yepez JB, Murati FA, Petitto M, et al. Vogt-koyanagi-harada disease following COVID-19 infection. *Case Rep Ophthalmol*. 2021;12:804–808.
- Cunningham Jr ET, Moorthy RS, Fraunfelder FW, Zierhut M. Vaccine-associated uveitis. *Ocul Immunol Inflamm*. 2019;27:517–520.
- Polack FP, Thomas SJ, Kitchin N, et al. Safety and efficacy of the BNT162b2 mRNA covid-19 vaccine. *N Engl J Med*. 2020;383:2603–2615.
- Papasavvas I, Herbert Jr CP. Reactivation of Vogt-Koyanagi-Harada disease under control for more than 6 years, following anti-SARS-CoV-2 vaccination. *J Ophthalmic Inflamm Infect*. 2021;11:21.
- Okunuki Y, Tsubota K, Kezuka T, Goto H. Differences in the clinical features of two types of Vogt-Koyanagi-Harada disease: serous retinal detachment and optic disc swelling. *Jpn J Ophthalmol*. 2015;59:103–108.