

CLINICAL IMAGE

A challenging case of undifferentiated shock

 Iris Kats^{1,*}, Pieter J. Schraverus¹, Marieke J. Hazewinkel² and Alexander D. Cornet¹
¹Department of Intensive Care, Medisch Spectrum Twente, Enschede, Netherlands, ²Department of Radiology, Medisch Spectrum Twente, Enschede, Netherlands.

*Correspondence address. Department of Intensive Care, Medisch Spectrum Twente, 7512KZ Enschede, Netherlands. Fax: +31534873039; Tel: +31534873383; E-mail: i.kats@mst.nl

A CHALLENGING CASE OF UNDIFFERENTIATED SHOCK

A 68-year old woman was admitted to our hospital with severe bilateral shoulder pain, which had developed over the previous days, without a history of trauma. An underlying cardiac cause, for example myocardial infarction, had already been ruled out by a cardiologist. Upon admission the patient was stable with no fever present, but her laboratory results showed high inflammatory markers (i.e. C-reactive protein 321 mg/l). Computed tomography (CT) of head, chest and abdomen showed no local shoulder pathology or other clear focus of infection, therefore she was empirically treated with broad spectrum antibiotics. The following day she developed symptoms of shock (heart rate 67/min,

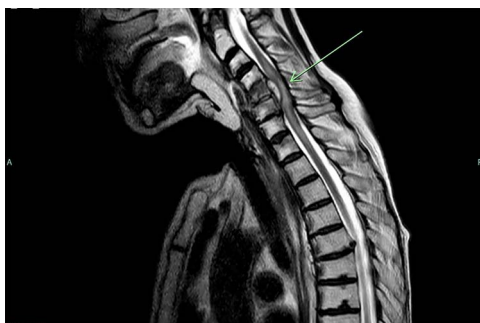

Figure 1. Sagittal T2 image showing spondylodiscitis C4-C5-C6, vertebral compression fracture and epidural abscess (arrow), compressing the spinal cord. Also posttherapeutic changes following laryngopharyngectomy, flap reconstruction and radiotherapy are seen.

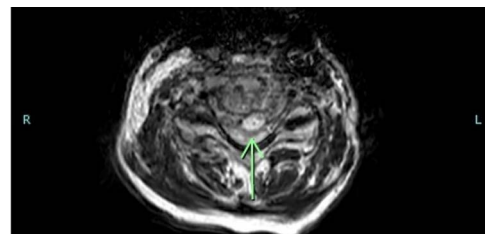


Figure 2. Transverse T2 image showing the vertebral compression fracture and epidural abscess (arrow), compressing the spinal cord.

RR 66/38 mmHg, mottling of the skin, hypothermia(34.7°C)), for which she was admitted to our intensive care unit (ICU).

Initially we hypothesized this to be a septic shock. Upon admission to the ICU however, her body temperature had spontaneously normalized and follow-up inflammatory markers were found to be decreasing, bringing into question whether the sepsis-hypothesis should be further pursued. Nevertheless, CT-angiography of the chest and abdomen also showed no signs of aortic dissection, hemorrhage or pulmonary embolism. Cardiac re-evaluation was unremarkable. Therefore hemorrhagic, cardiogenic and obstructive shock were also deemed unlikely.

During the first 12h our patient developed progressive motor- and sensory function loss of all extremities. MRI of the spine revealed a spondylodiscitis level C4 through C6 with an epidural abscess compressing the spinal cord, accompanied by a new vertebral compression fracture of C5 (Fig. 1 and 2). We believe the

†Iris Kats, <http://orcid.org/0000-0002-8793-0053>

Received: April 30, 2021. Revised: July 22, 2021. Accepted: September 12, 2021

© The Author(s) 2021. Published by Oxford University Press.

This is an Open Access article distributed under the terms of the Creative Commons Attribution Non-Commercial License (<https://creativecommons.org/licenses/by-nc/4.0/>), which permits non-commercial re-use, distribution, and reproduction in any medium, provided the original work is properly cited. For commercial re-use, please contact journals.permissions@oup.com

latter to have led to spinal cord injury and consequently spinal shock.

The antibiotic regimen was acuminated to spondylodiscitis and oral midodrine (vasopressive agent) was started to treat her hypotension. Due to extensive comorbidity neurosurgical decompression was not an option. Our patient was discharged to the general ward for further treatment the following day.

FUNDING STATEMENT

No sources of funding.

CONFLICTS OF INTEREST

The authors declare no conflicts of interest.

CONSENT

Informed consent was obtained verbally from patient and with her consent the consent form was signed by her husband (since the patient was not physically able to sign herself).

GUARANTOR

Iris Kats.