

Autologous Fat Grafting in the Upper Extremity: Defining New Indications

Peter Deptula, MD*†
Tennyson Block, MD*
Kylie Tanabe, MS-PAC*
David Kulber, MD*

Background: Autologous fat grafting is a commonly used technique in plastic surgery that can also be applied broadly in hand surgery. We present a case series to demonstrate the diverse indications for fat grafting in hand surgery.

Methods: We retrospectively reviewed cases of fat grafting in the upper extremity in 2020. Cases representing a unique application of fat grafting were identified. Patient data, including demographics, diagnoses, preoperative and postoperative assessments, complications, patient satisfaction, and surgical operative reports, were recorded.

Results: Five patients representing distinct indications for autologous fat grafting in the upper extremity were identified. Indications included hand rejuvenation (20.0%), burn/scar management (20.0%), tenolysis (20.0%), revision nerve decompression (20.0%), and carpometacarpal joint arthritis (20.0%). Average patient age was 60.4 years (range, 42–71). Average volume of fat injected was 15.2 ml (range, 1–37 ml). No major complications were noted (0.0%). All patients expressed satisfaction with their overall result with good functional outcomes (100%).

Conclusions: Autologous fat grafting can be applied broadly in hand surgery. Indications for fat grafting in hand surgery include hand rejuvenation, burn/scar management, tenolysis, revision nerve decompression, and thumb carpometacarpal arthritis. Hand surgeons can easily incorporate fat grafting into their daily practice. Current literature supports fat grafting as a viable technique in hand surgery with lower-level studies. (*Plast Reconstr Surg Glob Open* 2022;10:e4469; doi: 10.1097/GOX.0000000000004469; Published online 19 August 2022.)

INTRODUCTION

Autologous fat transfer has various applications for upper extremity surgery. It offers long-term improvements in soft tissue contour and functional motion.^{1,2} Harvested fat contains adipose-derived stem cells (ASCs), containing proliferative and multilineage differentiation potential, directly supporting nerve regeneration, angiogenesis, and chondroprotection.^{3–6}

We have found fat useful in hand rejuvenation, burn/scar management, tenolysis/contracture, peripheral nerve decompression, and basilar thumb arthritis.⁷ We aim to share our clinical experience in unique applications of autologous fat grafting in hand surgery to introduce an effective and easy technique to the larger community of hand surgeons.

METHODS

Cases of autologous fat grafting in the upper extremity by the senior author from 2019 to 2020 were retrospectively reviewed. Cases representing unique indications for the use of fat grafting were selected. We reviewed patient demographics, diagnoses, preoperative and postoperative assessments, complications, patient satisfaction, and operative reports.

RESULTS

Five patients representing five indications for autologous fat grafting in the upper extremity were identified (Table 1). Patient age ranged from 42 to 71 years. Volume of fat injected ranged from 1 to 37 ml. Donor sites included the abdomen, flank, hips, and thighs. No major complications were noted (0.0%). All patients expressed satisfaction and good functional outcomes (100%). Follow-up period after fat grafting ranged from 2 to 36 months.

From *Cedars-Sinai Medical Center, Department of Hand Surgery, Los Angeles, Ca.; and †Stanford Plastic Surgery, Stanford, Ca. Received for publication August 25, 2021; accepted June 3, 2022.

Copyright © 2022 The Authors. Published by Wolters Kluwer Health, Inc. on behalf of The American Society of Plastic Surgeons. This is an open-access article distributed under the terms of the Creative Commons Attribution-Non Commercial-No Derivatives License 4.0 (CCBY-NC-ND), where it is permissible to download and share the work provided it is properly cited. The work cannot be changed in any way or used commercially without permission from the journal.

DOI: 10.1097/GOX.0000000000004469

Disclosure: The authors have no financial interest to declare in relation to the content of this article.

Related Digital Media are available in the full-text version of the article on www.PRSGlobalOpen.com.

Example 1: Rejuvenation

A 70-year-old woman with thumb basilar joint osteoarthritis presented with severe soft tissue atrophy following corticosteroid injection. She underwent 10 ml of fat grafting from her thighs into a 12 cm × 6 cm defect. Her preoperative and postoperative results are shown in [Figure 1](#).

Example 2: Scar Management

A 42-year-old man with diffuse full-thickness burn to his right hand and a localized full-thickness burn to his left hand from a bonfire underwent full-thickness skin grafting. After 4 months, he underwent contracture release and fat grafting to the dorsum of his right hand and palmar fingers. His hands are shown before fat grafting and at 3 years postoperatively ([Figs. 2–7](#)).

Example 3: Tenolysis

A 60-year-old man presenting with a fixed proximal interphalangeal (PIP) joint flexion contracture of 110 degrees was treated with tenolysis through a lateral incision. Eight ml of fat was harvested from the abdomen

Takeaways

Question: What are the indications for fat grafting in the upper extremity?

Findings: We present five cases of fat grafting hand surgery with unique surgical indications.

Meaning: Autologous fat grafting had broad applications in the upper extremity, including hand rejuvenation, burn/scar revision, tenolysis, Dupuytren contracture, peripheral nerve injury, and arthritis.

and injected overlying the tendons. At 5-month follow-up, he achieved full passive range of motion.

Example 4: Nerve Decompression

A 71-year-old woman with recurring right ulnar nerve neuropathy at the elbow presented following two decompressions. She reported constant pain and progressive tingling. She underwent revision neurolysis at the cubital tunnel with adipofascial transposition. Thirty-seven ml

Table 1. Patient Demographics and Clinical Characteristics

Case	Age	Indication	Volume of Fat (ml)	Donor Site	Other Treatment	Time to Follow-up (Months)	Satisfaction and Function (1, Worst and 5, Best)	Complication
1	70	Soft tissue atrophy	10	Thighs	None	2	5	No
2	42	Full-thickness burn	20	Abdomen	Full-thickness skin graft, contracture release	36	5	No
3	60	Contracture	8	Abdomen	Tenolysis, central slip reconstruction	3	5	No
4	71	Ulnar neuropathy	37	Abdomen and flank	Decompression and transposition	6	5	No
5	59	Basilar joint arthritis	1	Flank	Synovectomy	2	5	No

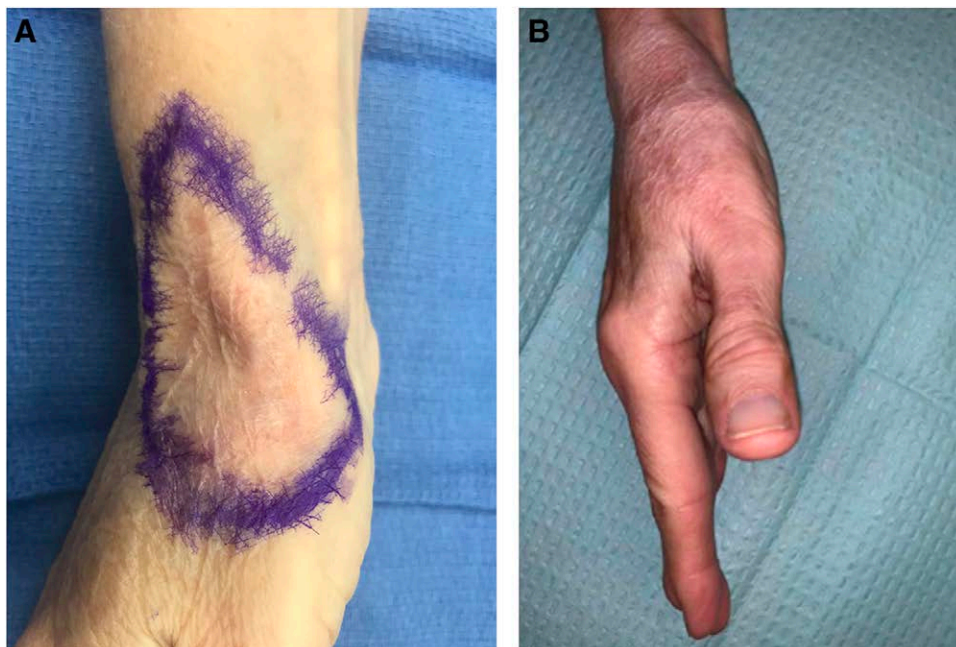


Fig. 1. Case example 1. A, Preoperative wrist soft tissue atrophy. B, Wrist image 2 months after fat grafting.

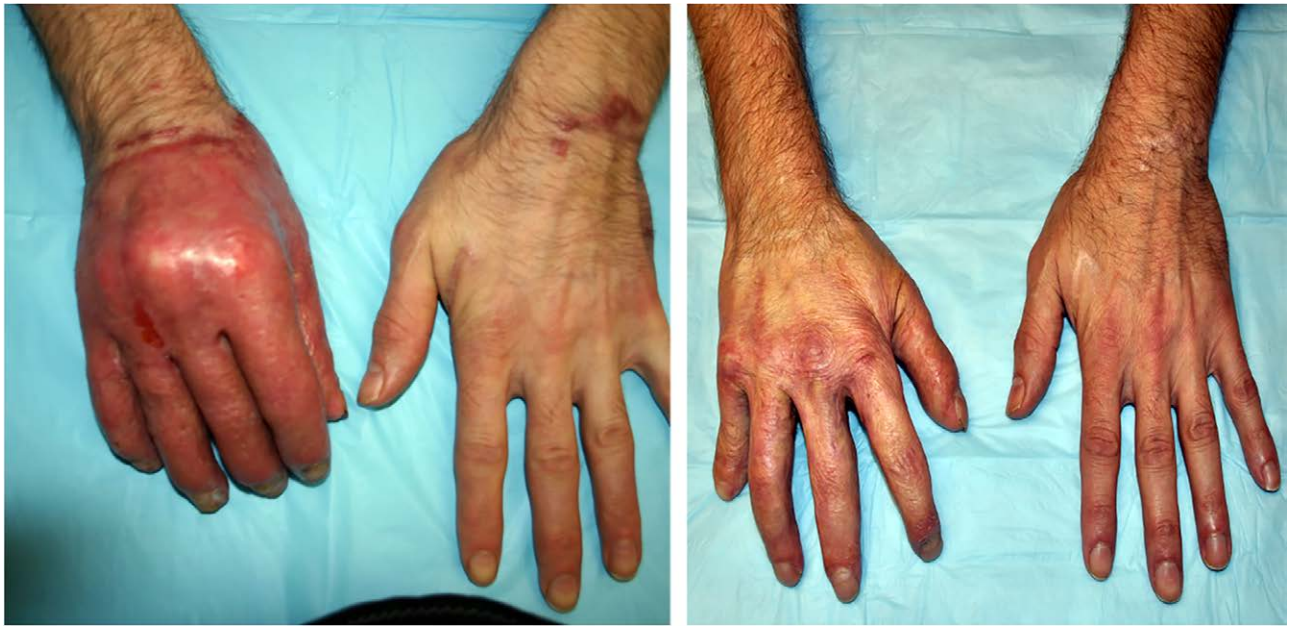

Fig. 2. Case example 2. A, Preoperative scarring. B, Results 3 years after fat grafting.

of fat was harvested from her abdomen and flank and injected overlying the ulnar nerve. She reported relief of her pain at 6 weeks postoperatively, which continued through her 6-month follow-up.

Example 5: Basilar Joint Arthritis

A 59-year-old woman with symptomatic thumb CMC joint arthritis presented with minimal radiographic changes. Arthroscopy of the scaphotrapezial joint showed mild synovitis without cartilage degeneration. The CMC

joint had extensive synovitis and chondral degeneration. Arthroscopic CMC synovectomy was performed, and 1 ml of fat harvested from the flanks was injected into the joint. At 2 months postoperatively, she had full thumb range of motion and minimal pain. [See figure, **Supplemental Digital Content 1**, which displays intraoperative case example 5. The images show carpometacarpal (CMC) joint before (a), during (b), and after synovectomy (c), and during insertion of fat (d), <http://links.lww.com/PRSGO/C129>.]

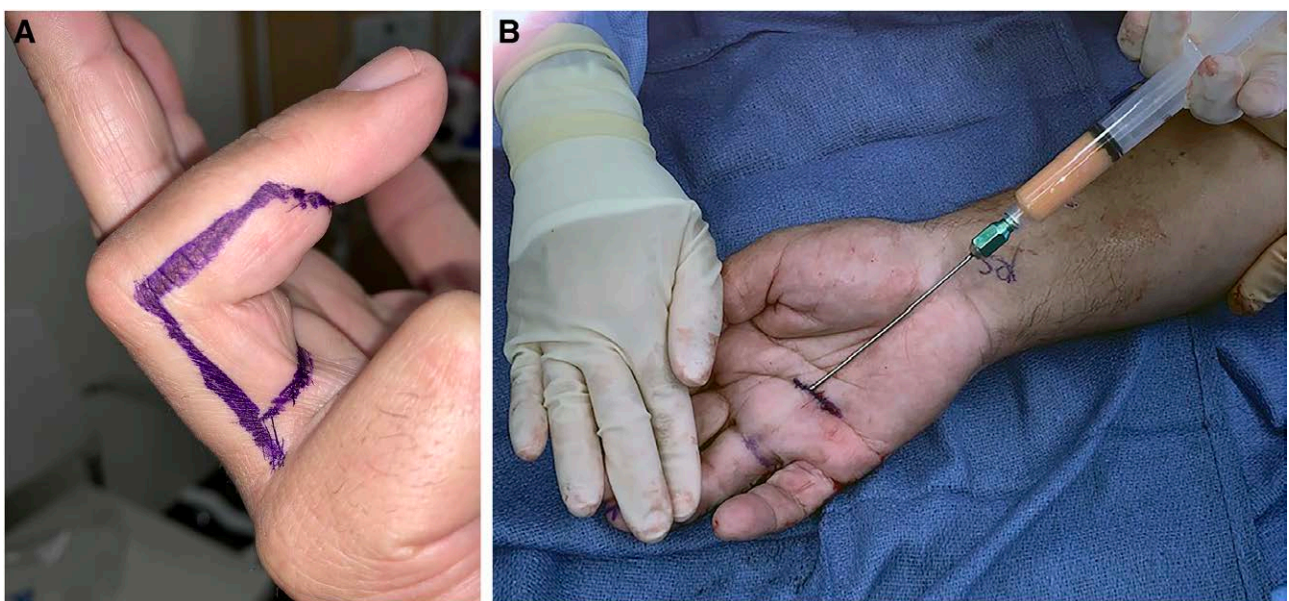


Fig. 3. Case example 3. A, Preoperative fixed contracture of the ring finger and planned incisions. B, Injection of autologous fat following contracture release.

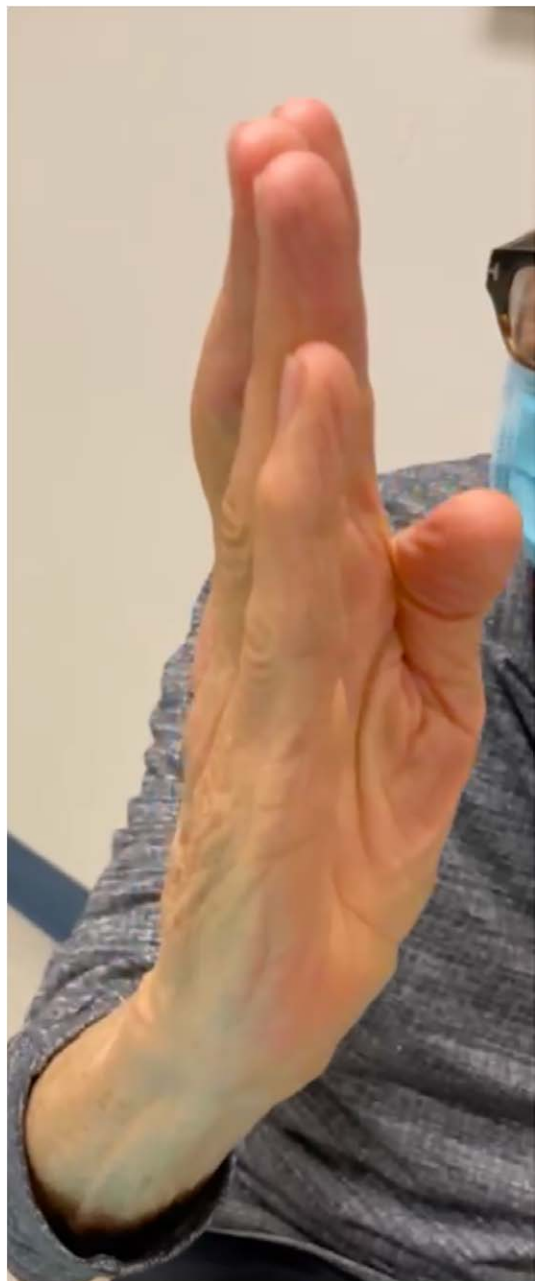

Fig. 4. Postoperative photographs of case example 3. Active extension at 5 months postoperative demonstrates sustained improvement compared with initial presentation.

DISCUSSION

We have found fat grafting to be safe based on our lack of major complications and universally high patient satisfaction; however, this small case series lacks a control group. Each case represents a unique application of fat grafting, and, in most cases, fat grafting was utilized in addition to standard treatments such as tenolysis or nerve decompression. Although we showcase the many uses of fat grafting, recent literature provides specifics of fat grafting for each unique application.

Zhou et al⁸ demonstrated a high patient satisfaction rate of 94.1% in their targeted approach to restore volume and improve pigmentation to the dorsum of the hand. Fat grafting of the superficial compartments allowed for the decreased visibility of tendons and veins. In the deep lamella, fat grafting addresses interosseous atrophy. The middle lamella, containing nerves and veins, should be avoided to prevent injury.⁸⁻¹⁰

Burn and injury to the hand can result in scar contracture, adhesions, and unstable skin, leading to reduced range of motion and function.¹¹⁻¹³ Fat grafting aids in regeneration of injured tissues through ASCs and facilitates gliding planes. Byrne et al¹³ describe fat grafting in 13 patients who gained statistically significant improvements in total active movement, Michigan Hand Outcome Questionnaire, and Patient Observer Scar Assessment Scale.

Autologous fat has been described to reduce recurrence of tendon adhesions from trauma of immobilization.¹⁴⁻¹⁵ This is presented in the lower extremity by Colonna et al¹² as two cases of dorsal foot and tendon adhesions treated with tenolysis and fat grafting. They found a reduction in activity-related pain and improved range of motion with recovery of normal ambulation without recurrence at 2 years.¹²

Autologous fat grafting may inhibit scar formation over peripheral nerves through anti-inflammatory and angiogenic properties.¹⁶⁻¹⁹ In cases of nerve compression, the grafted fat prevents reformation of entrapping scar tissue.¹⁶ Krzesniak et al¹⁶ reported 10 patients who underwent autologous fat transfer in secondary carpal tunnel release. Patients universally reported resolution of night pain. By the Boston carpal tunnel questionnaire, they demonstrated significant improvements in the functional and sensory severity scores.¹⁶

Osteoarthritic change at the thumb CMC joint may be treated with autologous fat grafting, offering a less invasive treatment than trapeziectomy.²⁰⁻²¹ The therapeutic relief may result from the regenerative effect of transplanted ASCs or a volume effect to cushion the diseased joint.^{22,23} Herold et al²⁰ published their series of 50 patients undergoing fat grafting for stage II–IV osteoarthritis. At 1 year, they found patients with stage II and III disease to have significant improvement in pain, DASH, grip, and pinch strength, but not for stage IV disease.²⁰

CONCLUSIONS

Autologous fat grafting is used in the treatment of hand rejuvenation, burn/scar contracture, peripheral nerve pathology, tendon adhesion and contracture, and thumb CMC arthritis. The literature and our case series demonstrate fat grafting's versatility, efficacy, and safety. Further research is needed to better understand the therapeutic mechanisms and improve the collective level of evidence represented in the literature.

Temyson Block, MD
Cedars-Sinai Medical Center
Hand Surgery Department

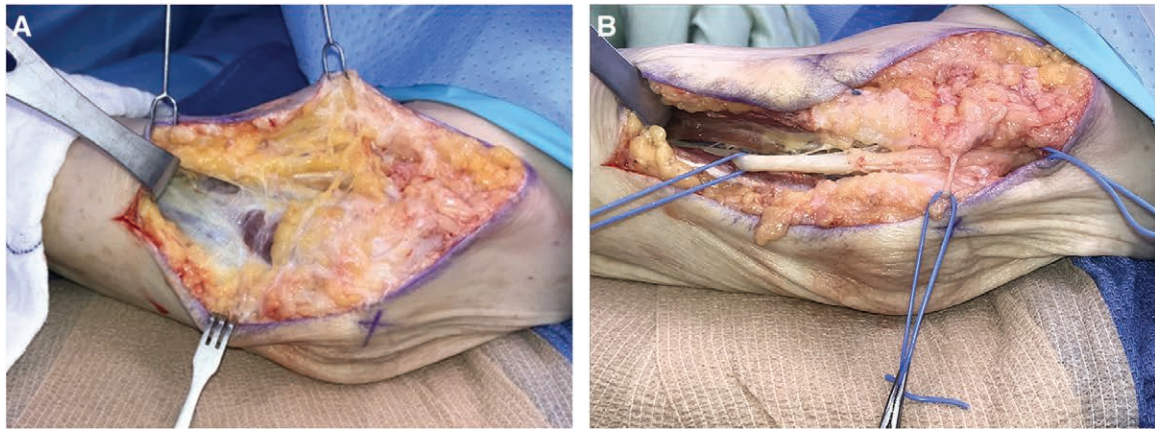


Fig. 5. Intraoperative photograph of case example 4. A, Intraoperative findings of severe neuritis of the ulnar nerve at the cubital tunnel. B, Neurolysis of the ulnar nerve is complete.

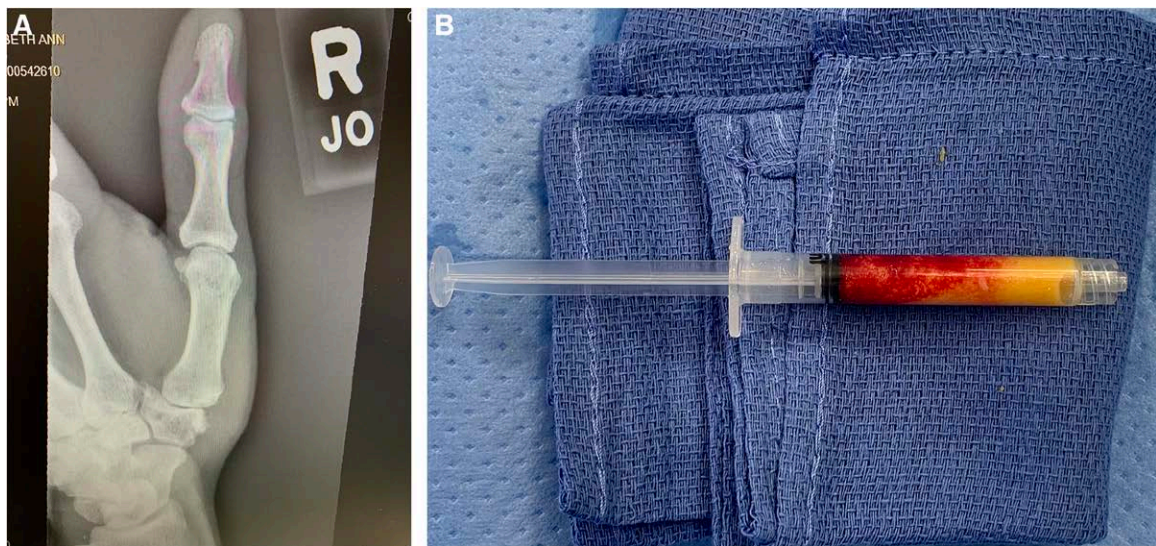


Fig. 6. Preoperative photographs of case example 5. A, Preoperative radiograph demonstrating moderate osteoarthritis of the thumb CMC joint. B, Autologous fat is mixed with PRP in preparation for injection into the CMC joint.

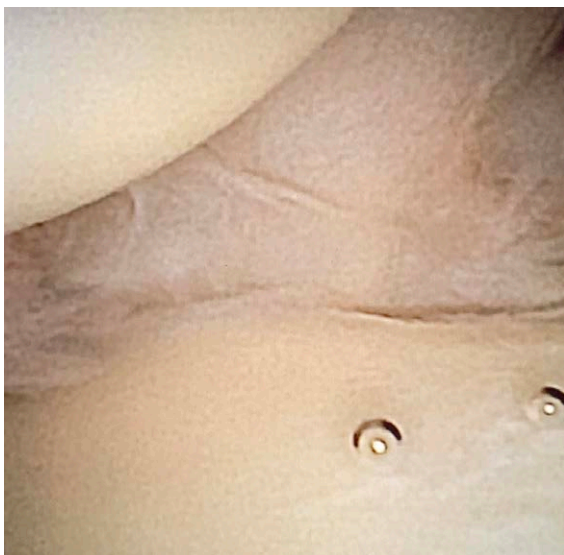


Fig. 7. Intraoperative photograph of case example 5. STT joint visualized by nanoscope after synovectomy.

8635 W 3rd Street, Suite 990W
 Los Angeles, CA 90048
 E-mail: tennysonblock@gmail.com

REFERENCES

1. Chajchir A, Benzaquen I. Fat-grafting injection for soft-tissue augmentation. *Plast Reconstr Surg.* 1989;84:921–934.
2. Coleman SR. Structural fat grafting: more than a permanent filler. *Plast Reconstr Surg.* 2006;118(3 suppl):108S–120S.
3. Zuk PA, Zhu M, Ashjian P, et al. Human adipose tissue is a source of multipotent stem cells. *Mol Biol Cell.* 2002;13:4279–4295.
4. Kondo K, Shintani S, Shibata R, et al. Implantation of adipose-derived regenerative cells enhances ischemia-induced angiogenesis. *Arterioscler Thromb Vasc Biol.* 2009;29:61–66.
5. ter Huurne M, Schelbergen R, Blattes R, et al. Antiinflammatory and chondroprotective effects of intraarticular injection of adipose-derived stem cells in experimental osteoarthritis. *Arthritis Rheum.* 2012;64:3604–3613.
6. Tuncel U, Kostakoglu N, Turan A, et al. The effect of autologous fat graft with different surgical repair methods on nerve regeneration in a rat sciatic nerve defect model. *Plast Reconstr Surg.* 2015;136:1181–1191.

7. Hoang D, Orgel MI, Kulber DA. Hand rejuvenation: a comprehensive review of fat grafting. *J Hand Surg Am.* 2016;41:639–644.
8. Zhou J, Xie Y, Wang WJ, et al. Hand rejuvenation by targeted volume restoration of the dorsal fat compartments. *Aesthet Surg J.* 2018;38:92–100.
9. Yun-Nan L, Shu-Hung H, Tsung-Ying L, et al. Micro-autologous fat transplantation for rejuvenation of the dorsal surface of the aging hand. *J Plast Reconstr Aesthet Surg.* 2018;71:573–584.
10. Fantozzi F. Hand rejuvenation with fat grafting: a 12-year single-surgeon experience. *Eur J Plast Surg.* 2017;40:457–464.
11. Al-Hayder S, Gramkow C, Trojahn Kølbe SF. Use of autologous fat grafting for the correction of burn scar contracture in the hand: a case report. *Case Reports Plast Surg Hand Surg.* 2017;4:81–83.
12. Colonna MR, Scarcella MC, Stagno d'Alcontres Fd, et al. Should fat graft be recommended in tendon scar treatment? Considerations on three cases (two feet and a severe burned hand). *Eur Rev Med Pharmacol Sci.* 2014;18:753–759.
13. Byrne M, O'Donnell M, Fitzgerald L, et al. Early experience with fat grafting as an adjunct for secondary burn reconstruction in the hand: Technique, hand function assessment and aesthetic outcomes. *Burns.* 2016;42:356–365.
14. Damgaard OE, Siemssen PA. Lipografted tenolysis. *J Plast Reconstr Aesthet Surg.* 2010;63:e637–e638.
15. Ueda K, Harashina T, Harada T, et al. Omentum as gliding material after extensive forearm tenolysis. *Br J Plast Surg.* 1993;46:590–593.
16. Krzeńskiak NE, Noszczyk BH. Autologous fat transfer in secondary carpal tunnel release. *Plast Reconstr Surg Glob Open.* 2015;3:e401.
17. Zimmermann S, Fakin RM, Giesen T, et al. Stromal vascular fraction-enriched fat grafting for the treatment of symptomatic end-neuromata. *J Vis Exp.* 2017;129:55962.
18. Beugels J, Hommes JE, Balthasar AJR, et al. Autologous fat transfer as a treatment for peripheral neuropathic pain without apparent cause. *Plast Reconstr Surg Glob Open.* 2018;6:e1905.
19. Vaienti L, Gazzola R, Villani F, et al. Perineural fat grafting in the treatment of painful neuromas. *Tech Hand Up Extrem Surg.* 2012;16:52–55.
20. Herold C, Rennekampff HO, Grodeck R, et al. Autologous fat transfer for thumb carpometacarpal joint osteoarthritis: a prospective study. *Plast Reconstr Surg.* 2017;140:327–335.
21. Kemper R, Wirth J, Baur EM. Arthroscopic synovectomy combined with autologous fat grafting in early stages of CMC osteoarthritis of the thumb. *J Wrist Surg.* 2018;7:165–171.
22. Erne HC, Cerny MK, Ehrl D, et al. Autologous fat injection versus Lundborg resection arthroplasty for the treatment of trapeziometacarpal joint osteoarthritis. *Plast Reconstr Surg.* 2018;141:119–124.
23. Haas EM, Eisele A, Arnoldi A, et al. One-year outcomes of intraarticular fat transplantation for thumb carpometacarpal joint osteoarthritis: case review of 99 joints. *Plast Reconstr Surg.* 2020;145:151–159.