

# Spatiotemporal characterization of the transition from sinus rhythm to ventricular fibrillation during an acute ischemic event in the intact human heart by whole-heart sock-mapping



Michele Orini, PhD,<sup>\*†</sup> Peter Taggart, MD, DSc, FRCP,<sup>\*†</sup> Martin Hayward, MS, FRCS,<sup>‡</sup>  
Pier D. Lambiase, PhD, FRCP, FHRS<sup>\*†</sup>

From the <sup>\*</sup>Institute of Cardiovascular Science, University College London, London, United Kingdom, <sup>†</sup>Barts Heart Centre, St Bartholomew's Hospital, London, United Kingdom, and <sup>‡</sup>The Heart Hospital, London, United Kingdom.

## Introduction

The accurate characterization of the spatiotemporal pattern of electrical activation and repolarization during ischemia is relevant for diagnosis and sudden cardiac death prediction. Although several animal studies have comprehensively described changes in acute ischemic models in the dog,<sup>1,2</sup> cat,<sup>3</sup> and pig,<sup>4</sup> data from whole-heart mapping of acute ischemia in the in vivo human heart are scant and are needed to complement animal models.

## Case report

A 55-year-old man with chronic total occlusion of the right coronary artery with retrograde filling, 50% left anterior descending artery disease, mild left anterior descending diagonal re-stenosis of stents (inserted 10 years previously), and occlusion of distal circumflex artery was referred for coronary artery bypass grafting at the Heart Hospital, London, UK.

Echocardiographic analysis reported normal left ventricle (LV) and right ventricle size and systolic function and mild mitral and tricuspid regurgitation.

The patient gave informed consent for a research study that involved whole-heart epicardial mapping using a multielectrode sock.<sup>5</sup> The study protocol conforms to the ethical guidelines of the Declaration of Helsinki as reflected in the approval by the local institution's human research committee.

---

**KEYWORDS** Arrhythmia mechanisms; Acute ischemia; Cardiac mapping; Human electrophysiology; Alternans; Ventricular tachycardia/fibrillation (Heart Rhythm Case Reports 2017;3:259–263)

---

M.O. is supported by Marie Curie Intra-European Fellowship for Career Development (IEF) FP7-PEOPLE-2013-IEF. P.L. is supported in part by a grant from University College London Hospital Biomedicine NIHR. **Address reprint requests and correspondence:** Dr Michele Orini UCL Institute of Cardiovascular Science Gower St, London WC1E 6BT, UK. E-mail address: [m.orini@ucl.ac.uk](mailto:m.orini@ucl.ac.uk).

Cardiopulmonary bypass was temporarily commenced to allow the surgeon to fit the multielectrode sock over the epicardium of both ventricles as in previous studies.<sup>6</sup> The heart was then refilled and the bypass discontinued in order to allow the study to proceed with a normally beating heart.

A total of 240 unipolar electrograms sampled at 2 kHz were recorded during spontaneous sinus rhythm for about 30 seconds. Then, steady-state ventricular pacing was delivered at a cycle length of 650 ms from the mid LV wall. Ventricular pacing was maintained for 160 beats (104 seconds) and discontinued afterwards because of hemodynamic instability and ST changes appearing on electrocardiogram. After 3 spontaneous sinus beats the rhythm became unstable with short runs of ventricular tachycardia (VT) that quickly degenerated into fibrillation. The study was stopped and the normal surgical intervention continued successfully after cardioversion.

Data were exported and analyzed off-line with bespoke software.<sup>6–8</sup> Local activation time (AT) was measured as the interval between the time of the pacing stimulus and the instant corresponding to the minimum derivative during the local QRS.<sup>5</sup> T-wave alternans (TWA) and QRS alternans (QRSA) in the epicardial unipolar electrograms were measured with the time-varying Laplacian likelihood ratio method in sliding windows of 32 beats.<sup>7</sup> Surrogate data analysis was used to establish the statistical significance of alternans.<sup>7</sup> Conduction block was defined as the absence of a local QRS complex in the unipolar electrogram.

During sinus rhythm prior to ventricular pacing, no conduction delay, QRSA, or TWA were observed. However, ST-segment elevation was registered in the mid and apical inferior region of the heart (Figures 1 and 2B).

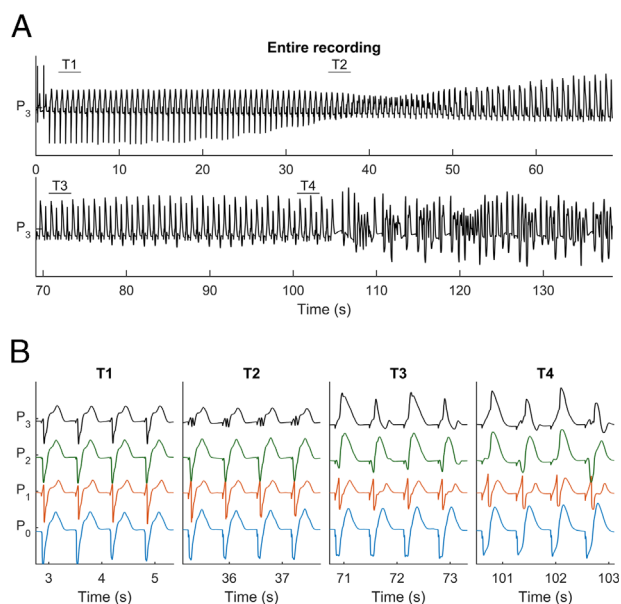
At the beginning of ventricular pacing, total AT was normal (126 ms). After a few seconds, substantial changes occurred in the morphology of epicardial signals. Representative examples of unipolar electrograms during the

## KEY TEACHING POINTS

- The spatiotemporal characterization of electrophysiological changes during acute ischemia leading to ventricular tachycardia / ventricular fibrillation is poorly characterized in the in vivo human heart.
- Electrophysiological changes can be very rapid, with a transition from normal to severely abnormal electrical activation and repolarization occurring in less than 1 minute at a time before significant postrepolarization refractoriness is expected to occur.
- Electrocardiographic signs of acute ischemia on the epicardium appeared in this sequence: ST-segment elevation, activation delay, QRS fractionation, T-wave and QRS alternans, conduction block.
- The severity of the electrocardiographic abnormalities increases with activation time delay.

transition from mild to severe electrical instability leading to VT are shown in [Figure 1](#). Sites outside the ischemic region ( $P_0$ ) showed a progressive broadening of the QRS complex and a subtle change in the T wave, probably due to remote activity, but no significant ischemia-related abnormalities. Sites at the border of the ischemic region ( $P_1$ ) showed a moderate-to-high AT delay (represented by a progressive shift of the QS downslope) and large TWA, mainly apparent during the T wave upslope,<sup>2</sup> but no QRSA or conduction block. Sites within the ischemic region ( $P_2$ – $P_3$ ) showed early ST-segment elevation, severe AT delay, QRS fractionation, QRSA, TWA, and signs of conduction block. Additionally, in site  $P_3$  TWA was preceded by QRS fractionation. Of note, the transition from a normal to severely abnormal activation and repolarization occurred in only 20–30 seconds.

[Figure 2](#) shows that abnormal electrophysiological indices related to ischemia were mainly distributed in the mid and apical inferior region of the heart. During sinus rhythm prior to the onset of ventricular pacing, normal peak-to-peak amplitude of QRS complexes demonstrates absence of electrical scar, while ST-segment elevation was observed and therefore considered the first sign of regional ischemia ([Figure 2B](#)). Successively, after about 30 seconds of ventricular pacing, this same region was characterized by the following, in this temporal order: intermittent QRS fractionation and progressive conduction delay ([Figure 2C](#)), T-wave alternans ([Figure 2D](#)), QRS-alternans ([Figure 2E](#)), and conduction block ([Figure 2F](#)). The pattern of activation and repolarization at the onset of ventricular pacing (normal conditions) and after 100 seconds of pacing (severely abnormal conditions including conduction block and repolarization alternans) can be seen in [supplementary videos S1 and S2](#), respectively (available online). The spatial distribution of abnormal electrophysiological indices is

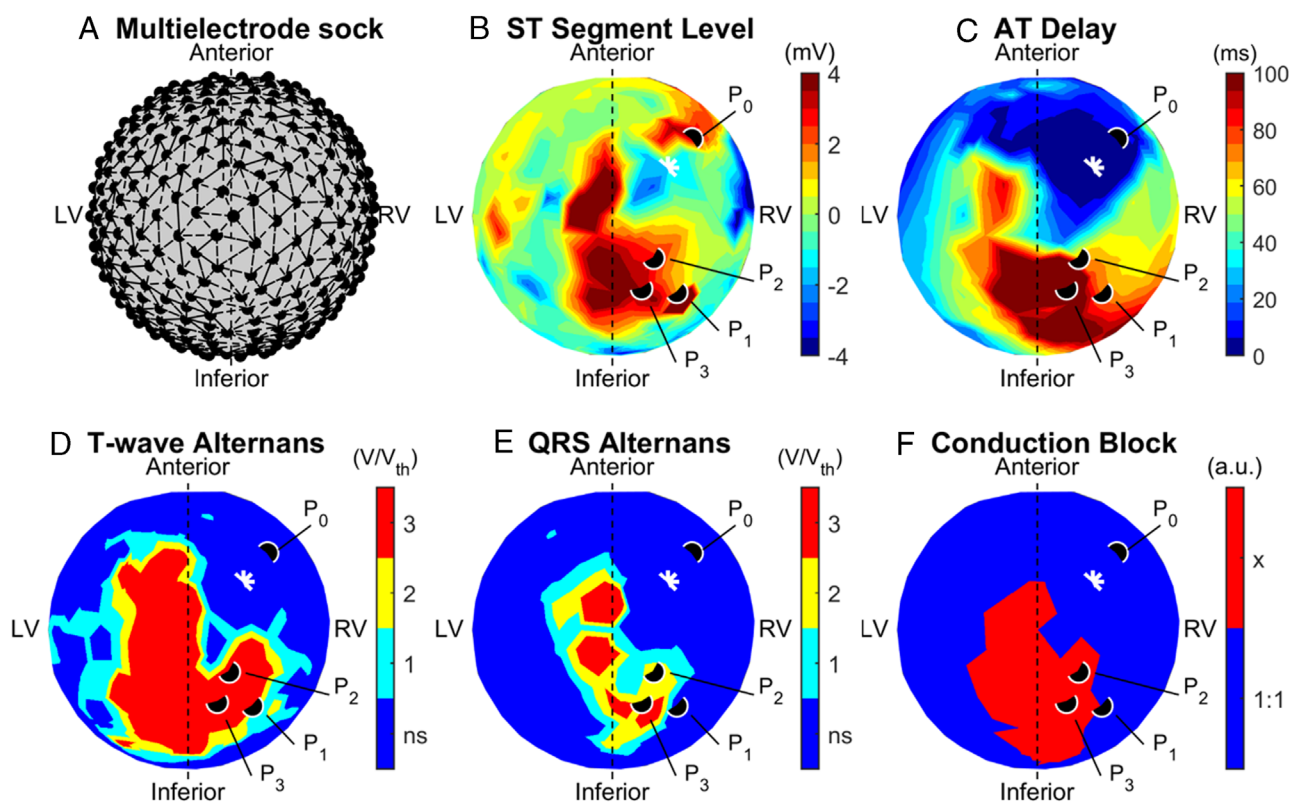


**Figure 1** A: Evolution of a unipolar electrogram from inside the ischemic region including early sinus rhythm, ventricular pacing, late sinus rhythm, and ventricular tachycardia / ventricular fibrillation. B: Detailed representation of morphologic changes in unipolar electrograms from sites  $P_0$  to  $P_3$  (see [Figure 2](#)) during the progression of ischemia. From interval T1 to T4, site  $P_0$  (outside the ischemic region) shows broadening QRS and mild changes in the T wave;  $P_1$  (border-zone region) shows progressive activation time (AT) delay (shift in the S wave) and T-wave alternans (TWA);  $P_2$ – $P_3$  (inside the ischemic region) show ST-segment elevation, AT delay, TWA, QRS alternans, and conduction block. Site  $P_3$  also shows QRS fractionation during T2.

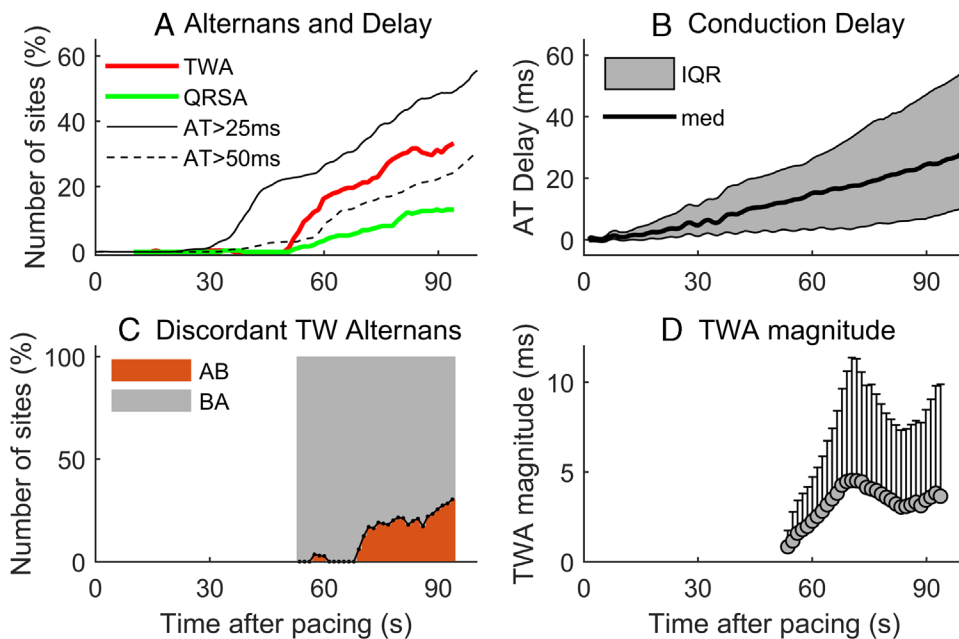
consistent with ongoing myocardial ischemia owing to very small and severely diseased right coronary artery, posterior descending artery, and obtuse marginal artery, as found during surgery.

[Figure 3](#) shows the precise temporal evolution of events. Conduction delay was the first sign of ischemia, followed by TWA and QRSA. By the time TWA and QRSA became significant, approximately 25% of the epicardium already showed AT delay > 25 ms. TWA and QRSA appeared simultaneously, but TWA quickly propagated in a larger region than QRSA, with about 40% of cardiac sites showing TWA after 90 seconds from the onset of ventricular pacing, as opposed to 20% of sites showing QRSA. AT delay increased almost linearly from the onset to the end of ventricular pacing, showing a median deceleration of about 0.28 ms per second. Regions of greater delay showed a deceleration 3 times faster. TWA was mainly concordant, with a low (<30%) but increasing number of sites showing discordant alternans during the progression of ischemia ([Figure 3C](#)). TWA magnitude increased for approximately 20 seconds, after which it reached a plateau ([Figure 3D](#)).

The analysis of the activation sequence during VT/ventricular fibrillation (VF) (see [supplementary videos S3–S6](#), available online) shows that VT was intermittent and interrupted by few sinus beats and pauses. The morphology of the unipolar electrograms progressively changed, reflecting a substrate and a circuit that evolved over time.



**Figure 2** A: Diagram of the multielectrode sock with circles representing electrodes; B: ST-segment elevation/depression during sinus rhythm prior to ventricular pacing; C: Maximum activation time (AT) delay; D: T-wave alternans (TWA); E: QRS alternans (QRSA); F: conduction block. Parameters in C–F are derived from recordings during pacing. The average magnitudes of QRSA and TWA are measured as multiples of the level of statistical significance ( $V/V_{th}$ ). The white star represents the pacing site. Points P0–P3 mark cardiac sites outside, at the border zone of, and inside the ischemic region, respectively. Unipolar electrograms from these sites are reported in Figure 1. LV = left ventricle; RV = right ventricle.



**Figure 3** Temporal evolution of electrophysiological abnormalities. A: Propagation of alternans throughout the epicardium, described as the number of sites with significant QRS alternans (QRSA) and T-wave alternans (TWA). B: Distribution of activation time (AT) delay throughout the epicardium. IQR = interquartile range; med = median. C: Temporal evolution of proportion of sites showing concordant alternans (gray region indicating the same BA patterns, where the T-wave amplitude of the odd beat is larger than that of the even beat) and discordant alternans (red region indicating opposite AB pattern). D: TWA magnitude over time.

Conduction was severely delayed or blocked in the mid and apical inferior region of the heart previously characterized by abnormal electrophysiological parameters (Figure 2).

## Discussion

This is the first whole-heart high-density mapping demonstration of acute ischemia leading to VT/VF reported in the in vivo human heart. Previous studies have used animal models to characterize the spatiotemporal evolution of acute ischemia,<sup>1–4</sup> while human studies have been limited to the analysis of few intracardiac recordings during coronary occlusion during angioplasty.<sup>9</sup>

In the epicardial electrograms, the first sign of ischemia was ST-segment elevation, followed by AT delay progressively increasing in magnitude, affecting a steadily increasing proportion of the epicardium. QRS fractionation preceded TWA and QRSA, which propagated quickly, paralleling the increase in AT delay and eventually evolving into conduction block. All sites showing conduction block previously showed TWA as well as QRSA, confirming that TWA is a hallmark of cardiac instability in ischemia<sup>1–4</sup> as well as in other conditions.<sup>10</sup> The magnitude of TWA as well as the proportion of sites showing discordant alternans increased with time, paralleling the increasing complexity in the substrate as a result of ongoing ischemia. During VT/VF, conduction was delayed and often blocked in the same region, showing block during pacing, with the wavefront traveling around the line of block. Although it was not possible to identify a clear epicardial reentrant circuit, it cannot be excluded that VT was sustained by a reentrant transmural mechanism. Another possibility is that VT was due to triggered activity with a basal LV focus (white circle in the videos). Both reentrant and nonreentrant mechanisms have been observed during ischemia-induced VT in previous studies<sup>3</sup> and they may coexist.

Of note, the sequence of events from sinus rhythm to VT/VF was more rapid than what was reported in most animal studies. VT developed after about 100 seconds from the onset of ventricular pacing and within 50 seconds from the establishment of alternans, and may reflect critical coronary artery disease combined with diminished collateral circulation in this patient.

ST-segment elevation, QRS fractionation, TWA, QRSA, and conduction block are known consequences of acute ischemia,<sup>11</sup> but their interplay is not completely understood. For example, alternans may be both cause and effect of conduction block,<sup>11,12</sup> while conduction delay can contribute to TWA.<sup>13</sup> This report suggests that fractionation, alternans, and conduction block primarily stem from a progressively increasing AT delay.

Importantly, this study demonstrates that large changes in membrane potential may occur extremely early, becoming profound at a time before significant postrepolarization refractoriness<sup>14,15</sup> develops and reaches a level when

repolarization gradients become less relevant to reentrant activity. This case report therefore supports the notion that in the in vivo human heart, repolarization changes contribute to the vulnerability to arrhythmia during the very early phase of ischemia.

## Conclusion

This report presents the first whole-heart high-density mapping study of acute ischemia in the in vivo human heart, and it provides an accurate description of the sequence of events leading to VT and VF, with initial signs of AT delay and ST-segment elevation evolving into QRS fractionation, alternans, and conduction block in less than 1 minute. Repolarization changes relevant to arrhythmogenesis may develop very early, at a time before significant postrepolarization refractoriness is expected to occur.

## Appendix

### Supplementary data

Supplementary data associated with this article can be found in the online version at <http://dx.doi.org/10.1016/j.hrcr.2017.01.002>.

## References

- Gordon D, Kadish AH, Koolish D, Taneja T, Ulphani J, Goldberger JJ, Ng J. High-resolution electrical mapping of depolarization and repolarization alternans in an ischemic dog model. *Am J Physiol Heart Circ Physiol* 2010;298:H352–H359.
- Nearing BD, Oesterle SN, Verrier RL. Quantification of ischaemia induced vulnerability by precordial T wave alternans analysis in dog and human. *Cardiovasc Res* 1994;28:1440–1449.
- Pogwizd SM, Corr PB. Reentrant and nonreentrant mechanisms contribute to arrhythmogenesis during early myocardial ischemia: results using three-dimensional mapping. *Circ Res* 1987;61:352–371.
- Nash MP, Bradley CP, Paterson DJ. Imaging electrocardiographic dispersion of depolarization and repolarization during ischemia: simultaneous body surface and epicardial mapping. *Circulation* 2003;107:2257–2263.
- Taggart P, Orini M, Hanson B, Hayward M, Clayton R, Dobrzynski H, Yanni J, Boyett M, Lambiase PD. Developing a novel comprehensive framework for the investigation of cellular and whole heart electrophysiology in the in situ human heart: historical perspectives, current progress and future prospects. *Prog Biophys Mol Biol* 2014;115:252–260.
- Orini M, Taggart P, Srinivasan N, Hayward M, Lambiase PD. Interactions between activation and repolarization restitution properties in the intact human heart: in-vivo whole-heart data and mathematical description. *PLoS One* 2016;11:e0161765.
- Orini M, Hanson B, Monasterio V, Martínez JP, Hayward M, Taggart P, Lambiase P. Comparative evaluation of methodologies for T-wave alternans mapping in electrograms. *IEEE Trans Biomed Eng* 2014;61:308–316.
- Orini M, Citi L, Hanson BM, Taggart P, Lambiase PD. Characterization of the causal interactions between depolarization and repolarization temporal changes in unipolar electrograms. *Comput Cardiol* 2013;719–722.
- Taggart P, Runnalls M, Donaldson R, Swanton H, Sutton P, O'Brien W, Hayward R, Emanuel R. Use of monophasic action potential recordings during routine coronary-artery bypass surgery as an index of localised myocardial ischaemia. *Lancet* 1986;1:1462–1465.
- Bayer JD, Lalani GG, Vigmond EJ, Narayan SM, Trayanova NA. Mechanisms linking electrical alternans and clinical ventricular arrhythmia in human heart failure. *Heart Rhythm* 2016;13:1922–1931.
- Qu Z, Xie Y, Garfinkel A, Weiss JN. T-wave alternans and arrhythmogenesis in cardiac diseases. *Front Physiol* 2010;1:154.
- Orini M, Taggart P, Hayward M, Lambiase P. On how 2/1 conduction block can induce T-wave alternans in the unipolar intracavitary electrogram: Modelling in-

vivo human recordings from an ischemic heart. *Conf Proc IEEE Eng Med Biol Soc* 2015;5676–5679.

13. Watanabe MA, Fenton FH, Evans SJ, Hastings HM, Karma A. Mechanisms for discordant alternans. *J Cardiovasc Electrophysiol* 2001;12:196–206.
14. Coronel R, Janse MJ, Opthof T, Wilde AA, Taggart P. Postrepolarization refractoriness in acute ischemia and after antiarrhythmic drug administration: Action potential duration is not always an index of the refractory period. *Heart Rhythm* 2012;9:977–982.
15. Taggart P, Sutton PM, Opthof T, et al. Inhomogeneous transmural conduction during early ischaemia in patients with coronary artery disease. *J Mol Cell Cardiol* 2000;32:621–630.