

Received: 2016.10.04
Accepted: 2016.11.04
Published: 2017.02.28

Metronomic Capecitabine Effectively Blocks Leptomeningeal Carcinomatosis From Breast Cancer: A Case Report and Literature Review

Authors' Contribution:
Study Design A
Data Collection B
Statistical Analysis C
Data Interpretation D
Manuscript Preparation E
Literature Search F
Funds Collection G

AE **Michela Maur**
EF **Claudia Omarini**
AE **Federico Piacentini**
F **Annalisa Fontana**
BD **Elisa Pettorelli**
DE **Stefano Cascinu**

Division of Medical Oncology, Department of Medical and Surgical Sciences for Children and Adults, University Hospital of Modena, Modena, Italy

Corresponding Author: Claudia Omarini, e-mail: claudia.omarini@gmail.com
Conflict of interest: None declared

Patient: Female, 57
Final Diagnosis: Meningeal carcinomatosis from breast cancer
Symptoms: Seizures
Medication: —
Clinical Procedure: —
Specialty: Oncology

Objective: Unusual clinical course





Background: Meningeal carcinomatosis is a rare complication in breast cancer patients. At present, there are no defined guidelines for its management. The efficacy of systemic treatment seems to depend on its ability to cross the blood-brain-barrier and its interaction with tumor vasculature. Metronomic chemotherapy is a known modality of drug administration able to inhibit tumor angiogenesis.

Case Report: We present a case of symptomatic leptomeningeal carcinomatosis from breast cancer successfully treated with capecitabine. Based on the hypothesis that angiogenesis contributes to neoplastic meningitis, the patient was treated with a metronomic schedule that provided long-term clinical benefit with a very low toxicity profile.

Conclusions: To assess the real impact of metronomic chemotherapy in patients with meninges involvement, a phase II study will be starting soon in our institution. A review of the literature concerning the management of meningeal carcinomatosis is also presented.

MeSH Keywords: Administration, Metronomic • Breast Neoplasms • Meningeal Carcinomatosis

Full-text PDF: <http://www.amjcaserep.com/abstract/index/idArt/901812>

 1138  —  2  22



Background

Meningeal carcinomatosis (MC) is a rare complication in cancer patients due to brain and/or spinal cord meninges involvement. If left untreated, median survival is 4–6 weeks; if treated, median survival is 2–3 months [1]. About 2–5% of patients with breast cancer (BC) develop MC, usually late in the course of their metastatic disease [2]. Three methods are routinely used to diagnose neoplastic meningitis: clinical signs and symptoms, cerebrospinal fluid cytology, and brain/spine magnetic resonance imaging (MRI). Treatment goals include improvement or stabilization of neurologic symptoms. Intrathecal therapy, radiotherapy, and systemic chemotherapy have been proposed, without clear survival benefit [3].

Capecitabine is a known anticancer drug used in the treatment of advanced BC. Low-dose metronomic capecitabine was shown to induce disease control with a lower incidence of adverse events compared with conventional maximum-tolerated-dose chemotherapy. This approach is known to enhance the anti-angiogenic activity of this agent [4].

Case Report

In June 2008, a 57-year-old post-menopausal woman was referred to our hospital because of a pathological fracture of the left arm. She was diagnosed with stage IV BC with multiple bone and lung metastases. The biological characterization

of disease revealed an invasive ductal carcinoma with hormonal receptors positive (estrogen receptor 100%, progesterone receptor 20%), human epidermal growth factor receptor type 2 (HER2) negative, and high proliferative rate (MIB-1 30%). The patient was started on first-line hormonal therapy with letrozole and zoledronic acid associated with palliative radiotherapy on the left arm and the spinal cord (D8–L1). Disease was stable until March 2012, when bone progression occurred, and a second-line hormonal therapy with Fulvestrant was commenced. In March 2014, serum cancer antigen 15-3 (Ca15-3) and carcinoembryonic antigen (CEA) levels increased to 321 U/ml and 150 ng/ml, respectively. A spinal MRI confirmed bone progression, without visceral progression on CT scan. A third-line therapy with exemestane plus everolimus was proposed. In June 2014, the patient referred to our emergency room due to a seizure. After a negative central nervous system (CNS) CT scan, a contrast-enhanced MRI of the brain and spinal cord was performed. It revealed larger contrast-enhancing leptomeningeal lesions (Figure 1). No bone progression or visceral disease were detected by CT scan. A significant increase of Ca15.3 and CEA were also reported (Ca15.3 758 U/ml, CEA 155 ng/ml). Cerebrospinal fluid analysis was not performed because of the poor compliance of the patient. The MC was diagnosed through radiological imaging and neurological symptoms. Based on the diagnosis of MC and considering the poor performance status of the patient, a metronomic schedule of capecitabine (500 mg 3 times a day continuously) was proposed. After the start of metronomic capecitabine, Ca15.3 and CEA levels gradually reduced and MRI performed

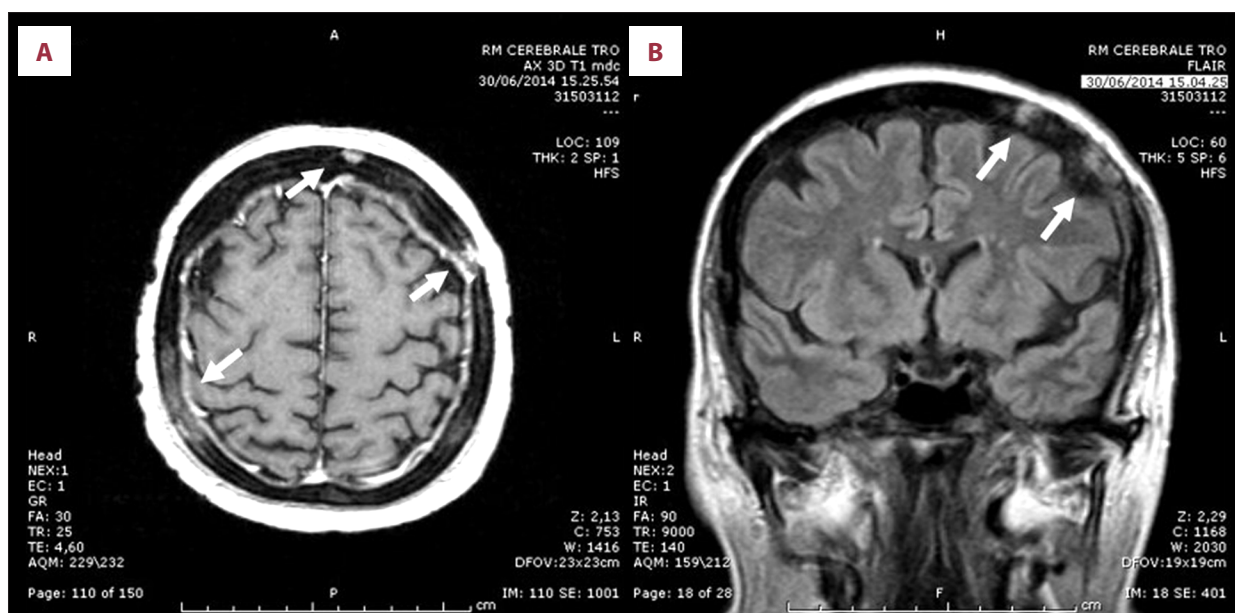


Figure 1. (A) The contrast-enhanced T1-weighted MRI shows multiple and diffuse bone metastatic lesions that infiltrate dural tissue into the subarachnoid space. Thickened and irregular enhancement with surrounding edema is seen along frontal, left, and right parietal lobes. (B) Flair (fluid attenuated inversion-recovery) shows the erosive changes of the cortical margins of the cranial bone with masses involving the subarachnoid space.

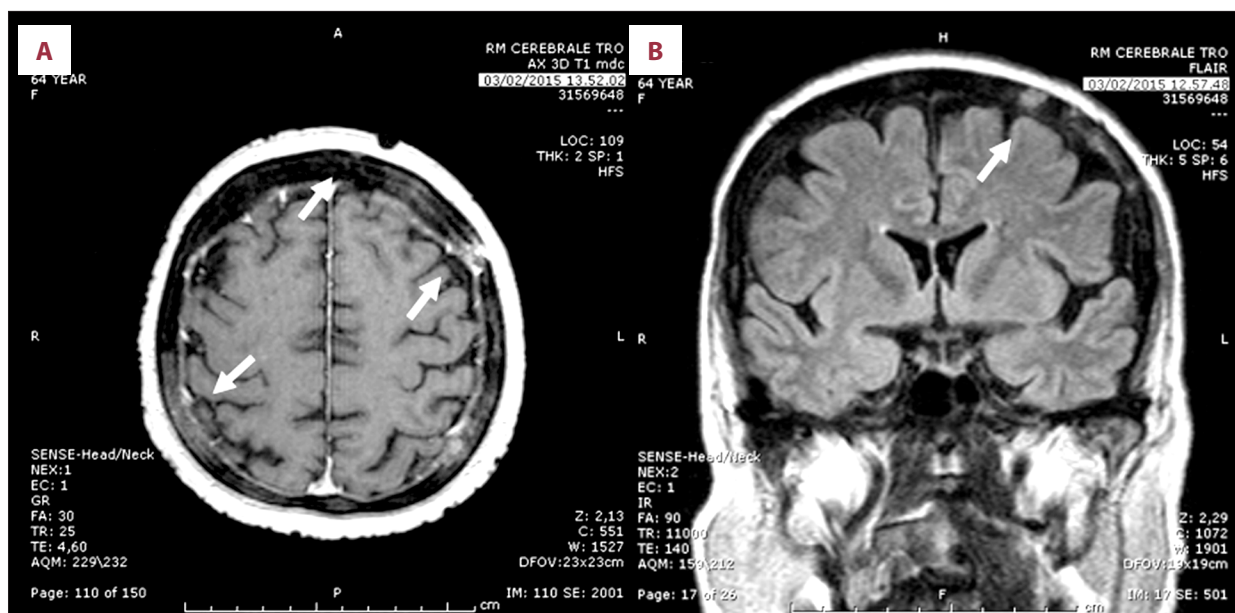


Figure 2. (A, B) The brain MRI performed after 6 months of metronomic capecitabine, confirming the diffuse bone and meningeal disease involvement, and showing initial response to the treatment and reduction in tumor vasculature.

after 6 months of treatment showed reduction of the leptomeningeal lesions and tumor vasculature (Figure 2). Persisting bone and visceral stable disease was also reported on CT scan. The adverse effects of metronomic capecitabine were negligible. Leptomeningeal progression-free survival, at time of case reporting, was 23 months. No more seizures were reported, and the patient is still well and has good performance status.

Discussion

Despite new anticancer strategies developed in recent years, there has been no improvement in the treatment of MC [2]. Intrathecal chemotherapy has been proposed, but it requires invasive procedures and its benefit has never been demonstrated in randomized clinical trials. Three drugs are used for intrathecal application: methotrexate (MTX), AraC (DEPOCYTE®), and thiotepa. In a prospective controlled trial, DEPOCYTE® was compared to MTX in 61 patients with MC, with similar response rates [5]. A similar study [6] reported a significantly improved median time interval to neurological progression for AraC. No prolonged survival or higher response rates have been shown from combination therapies (e.g., MTX + AraC) [7]. Focal radiotherapy to symptomatic sites or bulky disease are usually used, but with controversial results [3]. Concerning systemic treatment, the entire therapeutic success seems to depend on its ability to cross the blood-brain barrier (BBB). Although most of the drugs given systemically have poor cerebrospinal fluid penetration, various studies have shown that in MC the BBB is more permeable. Agents most commonly used are temozolomide, BCNU, CCNU, topotecan, lapatinib, trastuzumab, methotrexate, and capecitabine [3].

Capecitabine is an oral third-generation fluoropyrimidine carbamate. It is a prodrug converted by 3 enzymatic reactions to 5-fluorouracil [8]. Single-agent capecitabine demonstrated activity against BC progression with anthracyclines and taxanes, with a clinical response rate of 15–29%, stable disease in 31–46% of patients, and median overall survival of 10–15 months [9,10]. The standard package insert recommends a starting dose of 2500 mg/m² twice daily for 14 days every 3 weeks. Nevertheless, at the standard dose, capecitabine has a well-established toxicity profile: palmar-plantar erythrodysesthesia (PPE) ranging from 18% to 64%, grade 3 and 4 diarrhea in 5–19%, as well as stomatitis, nausea, and vomiting [8]. To reduce toxicity and improve the compliance to capecitabine, metronomic administration has been proposed, showing a median progression-free survival of 6.9 months and overall survival of 24.8 months in metastatic BC patients previously treated with anthracycline and taxane [11]. Worse outcomes have been reported in heavily pretreated metastatic BC patients [12]. The rationale for the metronomic schedule was the possibility to overcome drug resistance, targeting both tumor cells and tumor vasculature [13,14]. It is well known that continuous low-dose capecitabine has anti-angiogenic action. Preclinical evidence showed that chronic administration of low-dose capecitabine prevented effective recovery of the damaged tumor vasculature [15]. Metronomic chemotherapy also induces the anti-angiogenic glycoprotein Thrombospondin-1 (TSP1), which is endowed with further anti-tumor effects [16].

Preclinical and clinical studies highlighted the role of angiogenesis in the development of neoplastic meningitis. Groves et al. reported that elevated cerebrospinal fluid levels of VEGF are

highly specific for the diagnosis of MC, and that VEGF expression is correlated with survival [17]. A study [18] showed a significant decline in VEGF level after 2 and 6 months from baseline among the patients with disease control, supporting the importance of angiogenesis in the development of MC.

In the literature, there are few reports of the efficacy of capecitabine in the treatment of MC [19–22], and none in patients treated with a metronomic schedule. Our case report is the first showing a long-term response in leptomeningeal metastasis treated with metronomic capecitabine. Considering the reduction in tumor vasculature shown on RMN after 6 months of treatment, we hypothesized that the anti-angiogenic activity of metronomic capecitabine was the main mechanism responsible for long-term disease control.

References:

1. Rudnicka H, Niwińska A, Murawska M: BC leptomeningeal metastasis—the role of multimodality treatment. *J Neurooncol*, 2007; 84(1): 57–62
2. Boogerd W, Dorresteijn LD, van Der Sande JJ et al: Response of leptomeningeal metastases from BC to hormonal therapy. *Neurology*, 2000; 55(1): 117–19
3. Lombardi G, Zustovich F, Farina P et al: Neoplastic meningitis from solid tumors: New diagnostic and therapeutic approaches. *Oncologist*, 2011; 16(8): 1175–88
4. Emmenegger U, Kerbel RS: Five years of clinical experience with metronomic chemotherapy: achievements and perspectives. *Onkologie*, 2007; 30(12): 606–8
5. Glantz MJ, Jaeckle KA, Chamberlain MC et al: A randomized controlled trial comparing intrathecal sustained-release cytarabine (DepoCyt) to intrathecal methotrexate in patients with neoplastic meningitis from solid tumors. *Clin Cancer Res*, 1999; 5(11): 3394–402
6. Mack F, Baumert BG, Schäfer N et al: Therapy of leptomeningeal metastasis in solid tumors. *Cancer Treat Rev*, 2016; 43: 83–91
7. Giannone L, Greco FA, Hainsworth JV: Combination intraventricular chemotherapy for meningeal neoplasia. *J Clin Oncol*, 1986; 4(1): 68–73
8. Walko CM, Lindley C: Capecitabine: A review. *Clin Ther*, 2005; 27(1): 23–44
9. Reichardt P, Von Minckwitz G, Thuss-Patience PC et al: Multicenter phase II study of oral capecitabine (Xeloda) in patients with metastatic BC relapsing after treatment with a taxane-containing therapy. *Ann Oncol*, 2003; 14: 1227–33
10. Fumoleau P, Largillier R, Trillet-Lenoir V et al: Capecitabine (Xeloda) in patients with advanced BC (ABC) previously treated with anthracyclines and taxanes: Results of a large phase II study. *Proc Am Soc Clin Oncol*, 2002; 21: 62a (Abstr 247)
11. Taguchi T, Nakayama T, Masuda N et al., Kinki BC Study Group: Study of low-dose capecitabine monotherapy for metastatic BC. *Chemotherapy*, 2010; 56(2): 166–70
12. Fedele P, Marino A, Orlando L et al: Efficacy and safety of low-dose metronomic chemotherapy with capecitabine in heavily pretreated patients with metastatic BC. *Eur J Cancer*, 2012; 48(1): 24–29
13. Kerbel RS, Kamen BA: The anti-angiogenic basis of metronomic chemotherapy. *Nat Rev Cancer*, 2004; 4(6): 423–36
14. Laquente B, Viñals F, Germà JR: Metronomic chemotherapy: an antiangiogenic scheduling. *Clin Transl Oncol*, 2007; 9(2): 93–98
15. Fox SB, Generali DG, Harris AL: Breast tumour angiogenesis. *Breast Cancer Res*, 2007; 9(6): 216
16. Damber JE, Vallbo C, Albertsson P et al: The anti-tumour effect of low-dose continuous chemotherapy may partly be mediated by thrombospondin. *Cancer Chemother Pharmacol*, 2006; 58(3): 354–60
17. Groves MD, Hess KR, Puduvalli VK et al: Biomarkers of disease: cerebrospinal fluid vascular endothelial growth factor (VEGF) and stromal cell derived factor (SDF)-1 levels in patients with neoplastic meningitis (NM) due to breast cancer, lung cancer and melanoma. *J Neurooncol*, 2009; 94(2): 229–34
18. Herrlinger U, Wiendl H, Renninger M et al: Vascular endothelial growth factor (VEGF) in leptomeningeal metastasis: diagnostic and prognostic value. *Br J Cancer*, 2004; 91(2): 219–24
19. Rogers LR, Remer SE, Tejwani S et al: Durable response of BC leptomeningeal metastasis to capecitabine monotherapy. *Neuro Oncol*, 2004; 6(1): 63–64
20. Tanaka Y, Oura S, Yoshimasu T et al: Response of meningeal carcinomatosis from BC to capecitabine monotherapy: A case report. *Case Rep Oncol*, 2013; 6(1): 1–5
21. Tham YL, Hinckley L, Teh BS et al: Long-term clinical response in leptomeningeal metastases from breast cancer treated with capecitabine monotherapy: A case report. *Clin Breast Cancer*, 2006; 7(2): 164–66
22. Giglio P, Tremont-Lukats IW, Groves MD: Response of neoplastic meningitis from solid tumors to oral capecitabine. *J Neurooncol*, 2003; 65: 167–72

Conclusions

MC presents a poor prognosis. Currently available therapies are toxic and provide limited benefits. Metronomic capecitabine could be the treatment of choice to induce disease control, mainly due to interaction with tumor vasculature and inhibition of tumor angiogenesis. To assess the real impact of this metronomic treatment in patients with MC, a phase II study will be starting soon.

Disclosure

The authors have declared no conflicts of interest.