

Case Report

Management of foot degloving injury with bilateral anterolateral thigh flaps

Pan Zhou, Xiaobin Cong, Zhenbing Chen*

Department of Hand Surgery, Union Hospital, Tongji Medical College, Huazhong University of Science and Technology, Wuhan 430022, China

ARTICLE INFO

Keywords:

Degloving injuries
Foot injuries
Salvage limb
Soft tissue defect
Surgical flaps
Anterolateral thigh flap

ABSTRACT

Foot degloving injuries are frequently encountered by reconstructive surgeons as there are more and more vehicles on the road. The separation between the deep fascia and the superficial skin often damage the blood supply of the cutaneous tissue, resulting skin defect and digit necrosis. In order to manage these challenging situations, reconstructive surgeons have explored various types of techniques. Our team have managed to cure one such patient through bilateral anterolateral thigh flaps, in which the two flaps cover the dorsal and plantar side respectively. The flaps survived uneventfully and second stage operation of defatting was consequently arranged. The patient obtained protective sensation and felt satisfied with the cosmetic outcome. With the development of microsurgery, bilateral anterolateral thigh flaps could be effectively adopted to manage foot degloving injuries.

Introduction

Foot degloving injuries used to be rare. Yet, with the development of modern society, we have seen persistent increase in the number of this challenging situation, mainly caused by traffic accident. Forces between a fixed surface and a moving object can easily avulse the skin and separate the superficial tissue from the deep fascia, damaging the blood supply of the degloved skin and soft tissue.

Feet comprise a special anatomy and are of great importance to everyday life. To simply employ amputation will no doubt bring both physical and emotional damage to the patient. So how to handle the degloved skin and soft tissue and help the patient salvage the limb is the concern of reconstructive surgeons.

Our patient presented with extensive degloving injury of the left foot, involving both the dorsal and plantar side. He underwent serial debridements, negative-pressure wound therapy, and bilateral anterolateral thigh flaps. Rehabilitation and second stage de-fatting operation were carried out consequently, achieving good functional and cosmetic results.

Case report

A 45-year-old man presented to the emergency department with his left foot degloved in a car accident. His vital signs were normal, and he reported no special previous history. On physical examination, we found that both the dorsal and plantar skin of the foot were degloved, with fracture of the calcaneus and dislocation of the tarsometatarsal joint. Despite these, the tendons and the five toes were relatively intact.

The fracture and dislocation were fixed with k-wires and external fixation, with the degloved skin defatted and grafted upon the

* Corresponding author.

E-mail address: 2990430205@qq.com (Z. Chen).

<https://doi.org/10.1016/j.tcr.2020.100337>

Accepted 27 July 2020

Available online 31 July 2020

2352-6440/ © 2020 The Authors. Published by Elsevier Ltd. This is an open access article under the CC BY-NC-ND license (<http://creativecommons.org/licenses/by-nc-nd/4.0/>).

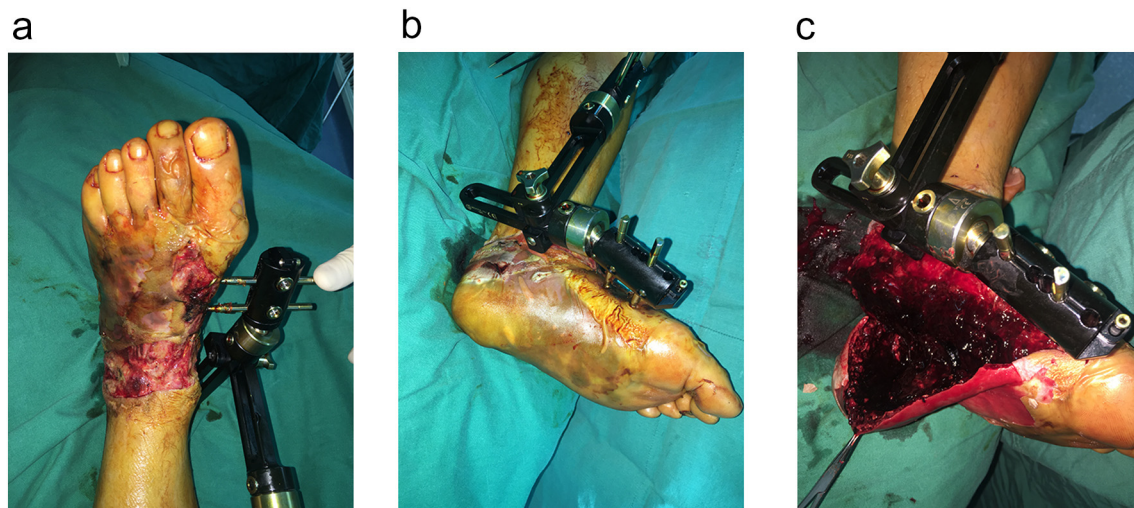


Fig. 1. The dorsal (a) and plantar (b) side of the degloved foot after defatted skin graft. Hematoma was found under the plantar skin (c).

primary site. Vacuum assisted therapy was applied for one week. However, most of the grafted skin were lost [Fig. 1]. Following two times of debridement, there left a large area of skin defect involving both the dorsal and the plantar side [Fig. 2], which posed a challenge to us.

After a thorough communication, the patient was determined to receive bilateral anterolateral thigh (ALT) flaps to salvage the foot, rather than amputation. Based upon the precise defect of the foot, we designed on the left a 20 cm*16 cm ALT flap for the dorsal side, and on the right a 19.5 cm*15 cm ALT flap for the plantar. The artery of the dorsal flap was anastomosed to the pedis dorsalis artery, with its vein to the great saphenous vein , both using an end-to-end technique. The plantar flap was nourished by two separate perforator vessels, and fabrication was performed so as to secure flap blood supply. In order to protect the forefoot, the artery of the plantar flap was anastomosed, employing the end-to-side technique, to the posterior tibial artery, with its accompanying vein providing drainage [Fig. 3].

Flap donor sites were covered by split thickness skin grafts, and postoperative procedure went uneventfully.

Two months later, the patient went back and the k-wires as well as external fixation was removed. He was encouraged to carry out some rehabilitation exercise. Six months later, a defatting operation was performed to make it convenient for him to wear shoes. At the last follow up, twelve months after the injury, the patient could walk independently and was satisfied with both functional and aesthetic outcome (Fig. 4).

Discussion

Reconstructive surgeons have been struggling with foot degloving injuries for a long time, especially those with large area of soft tissue defects. They have explored several techniques in order to salvage the limb, avoiding physical and psychological hurt that

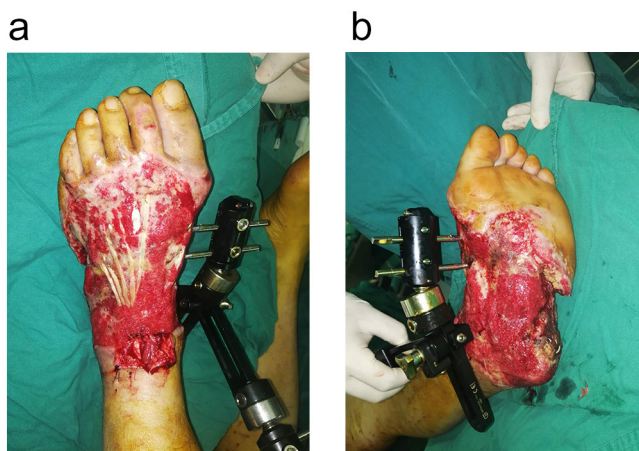


Fig. 2. The dorsal (a) and plantar (b) side of the degloved foot after thorough debridement.

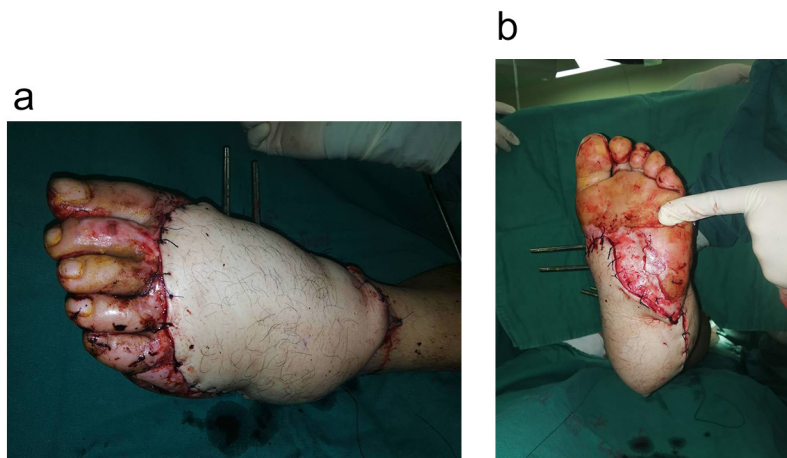


Fig. 3. The dorsal side of foot was covered by an ALT flap from the left (a) and the plantar side received an ALT flap from the right (b).

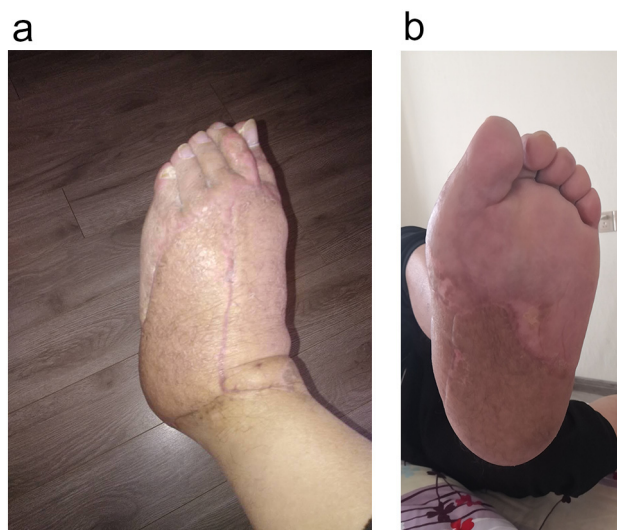

Fig. 4. The dorsal (a) and plantar (b) side of the left foot at the latest follow up, twelve months after the injury.

amputation may bring to the patient.

Defatting and replacement of the degloved skin as a full-thickness graft have been widely accepted as effective means to manage the degloving injury. Josty I.C. et al. introduced their experience of vacuum assisted closure, which could provide constant conforming pressure to the replaced skin and increase the take of the graft [2].

For those patients involved with worse wound bed as well as unstable condition, immediate defatting and graft may sound unacceptable. In this situation, Tian L. et al. adopted the technique of hypothermic preservation [4]. Full thickness-skin slices were harvested and stored in liquid nitrogen until the wound granulation tissue was satisfactory. Hypothermic preservation was an effective and economical way in managing degloving injuries for not introducing additional trauma. However, lack of liquid nitrogen in ordinary hospitals may limit its application.

With the development of microsurgery, various types of flaps have been introduced to solve degloving injuries of the foot. Zhou L.R. et al. used free latissimus dorsi musculocutaneous flap, distal-based lateral skin flap of the leg and free tensor fasciae latae muscle flap successfully in their clinical practice [7]. They defined thorough debridement of the recipient area, appropriate selection of the donor site, precise vascular anastomosis and active postoperative rehabilitation as four vital factors in achieving favourable results. Furthermore, Zhang W.K. et al. creatively used a technique of free coupling chain-link flap, which combined a posterior tibial artery flap and a medial plantar flap together [6].

Zgonis T. et al. reported a case of a crossover reverse sural artery flap for soft tissue coverage of the plantar aspect of a degloving forefoot [5]. It provided valuable solution when neither a suitable recipient vessel for anastomosis nor a sufficient local flap was available. Special attention should be paid to old patients with co-morbidities and children, for whom relatively conservative therapy should be recommended. Damkat-Thomas L. et al. applied a novel synthetic biodegradable temporising matrix to cure an obese, 72-

year-old diabetic man and Kaufman R. et al. employed an extracellular matrix for a 16-year-old girl [1,3]. These newly developed bio-materials were proven to be useful, although they required a relatively long closure time.

Our team shared similar strategy with Zhang W.K. et al. [6]. In order to solve large area defect involving both the dorsal side and the plantar side, we harvest bilateral anterolateral thigh flap simultaneously. The two flaps received independent blood supply, and end-to-side anastomosis was carried out so as to protect the blood supply of the foot. We may also adopt the technique of chain link flap, when blood vessels of one flap can be conveniently fabricated to those of the other. These should be determined according to associated anatomical variations.

Considering the obstacles often faced during the microsurgery process, it did bring us great challenge to harvest two free flaps during one operation. Sufficient preparation should be fixed, so alternative measures could be obtained when needed.

Conclusion

Foot degloving injuries comprise a group of challenging situations. Reconstructive surgeons may choose a therapy from their toolbox according to the special condition of the patient. Bilateral anterolateral thigh flaps could be of great help in repairing large area of skin defect involving both the dorsal and the plantar side.

Acknowledgement

We thank Qingshan-Wang, who was studying in our department at that time, for his help in the flap operation.

References

- [1] L. Damkat-Thomas, J.E. Greenwood, M. Wagstaff, A synthetic biodegradable temporising matrix in degloving lower extremity trauma reconstruction: a case report, *Plast. Reconstr. Surg. Glob. Open* 7 (2019) e2110.
- [2] I.C. Josty, R. Ramaswamy, J.H. Laing, Vacuum assisted closure: an alternative strategy in the management of degloving injuries of the foot, *Br. J. Plast. Surg.* 54 (2001) 363–365.
- [3] R. Kaufman, J. Nguyen, B. Williams, et al., Treatment of traumatic degloving injury of the foot using a biologic dressing in a pediatric patient, *Wounds* 31 (2019) E77–E81.
- [4] L. Tian, X. Ji, T. Chen, et al., Deep hypothermic preservation of autologous skin in the treatment of large-area circumferential multi-plane degloving trauma: a pilot study of 2 cases, *Cell Tissue Bank.* 20 (2019) 109–115.
- [5] T. Zgonis, D.T. Cromack, J.J. Stapleton, Utilizing a crossover reverse sural artery flap for soft tissue reconstruction of the plantar forefoot after a severe degloving injury, *Int. J. Low. Extrem. Wounds* 6 (2007) 114–119.
- [6] W.K. Zhang, W.K. Zhang, H.B. Wang, et al., Vacuum sealing drainage and free coupling chain-link posterior tibial artery flap in the reconstruction of degloving injury of propodium, *Zhonghua Zheng Xing Wai Ke Za Zhi* 29 (2013) 258–260.
- [7] L.R. Zhou, J. Li, W. Wang, Microsurgical repair of skin-degloving injury of whole hand or foot, *Zhongguo Xiu Fu Chong Jian Wai Ke Za Zhi* 17 (2003) 321–323.