Case Report

Regional interdependence between senile kyphosis and cervical postural syndrome: a case report

Eric Chun-Pu Chu^

New York Chiropractic and Physiotherapy Center, Hong Kong, China

Correspondence to: Eric Chun-Pu Chu, DC, FRCC, PhD. New York Chiropractic and Physiotherapy Centre, 41/F Langham Place Office Tower, 8 Argyle Street, Hong Kong, China. Email: eric@nymg.com.hk.

Background: Although senile kyphosis may not be the primary reason older people seek medical attention, it can cause functional difficulties and associated health risks. Kyphotic curvature can be alleviated through conservative measures, which are also a viable option to relieve the discomfort caused by the abnormalities. This case study describes successful multimodal chiropractic treatment for senile kyphosis and cervical postural syndrome. The purpose of this manuscript is to provide evidence for the concept of regional interdependence between senile kyphosis and cervical postural syndrome. This is achieved by demonstrating the positive outcome of a multimodal chiropractic intervention performed over 24 months.

Case Description: This case study involves a 60-year-old female office manager who had been suffering from neck and right shoulder pain for five years. Her family doctor diagnosed her with cervical spondylosis with cervical syndrome based on radiographic findings. She took pain medication for a year, underwent ten physiotherapy sessions and monthly massage therapy. This did not alleviate her problems, but caused her head slowly droop forward. EOS® radiography at the first chiropractic consultation showed reverse lordosis of the cervical spine, degeneration of the C4/5, C5/6, L3/4, L4/5, and L5/S1 intervertebral discs, and marginal osteophytes. A working diagnosis of age-related hyperkyphosis and cervical postural syndrome was made based on the main symptoms and clinical findings. After a 24-month multimodal chiropractic treatment program, the corrected thoracic curvature resulted in the simultaneous remission of cervical symptoms.

Conclusions: Given the high prevalence of age-related kyphosis among non-care seeking individuals and its rehabilitation potential, early intervention in senile kyphosis may help reduce the functional burdens and associated health problems.

Keywords: Cervical postural syndrome; chiropractic; regional interdependence; thoracic postural kyphosis; case report

Received: 28 February 2024; Accepted: 13 December 2024; Published online: 07 March 2025.

doi: 10.21037/acr-24-41

View this article at: https://dx.doi.org/10.21037/acr-24-41

Introduction

The aging process is associated with a decline in skeletal muscle mass, strength and function, a condition called sarcopenia. This disorder leads to physical weakness and increases the risk of morbidity (1). Common postural abnormalities include forward protrusion of the head (forward head posture or anterior head translation) and gradual humping of the thoracic spine (age-related hyperkyphosis or senile kyphosis). Based on a descriptive cross-sectional study (2), it was found that the prevalence of senile kyphosis in the elderly in the community could be as high as 62.50%.

^ ORCID: 0000-0002-0893-556X.

© AME Publishing Company.

Poor posture can affect various postural mechanisms, including postural/phasic muscle activation, muscle strength and length, and sensory integration. If left uncorrected, poor posture can lead to continue stress and symptoms such as nerve irritation and muscle strain, known as postural syndrome (3). Cervical postural syndrome includes a range of adverse effects resulting from changes in the cervical spine and its surrounding soft tissues, with pain being the main symptom (4). Degenerative changes in the cervical spine are the main contributing factor to neck pain, accounting for up to 90% of instances (4).

Studies have shown a strong association between thoracic hyperkyphosis and cervical postural syndrome, suggesting that forward head posture is a potential contributing factor (5,6). This issue supports the concept of 'regional interdependence', suggesting that the patient's main musculoskeletal symptom(s) may be directly or indirectly related to or influenced by dysfunctions of various body parts and systems, regardless of their proximity to the main symptoms (7). This concept was inspired by the favorable results achieved in the rehabilitation of patients with cervical syndromes in senile kyphosis (5). Understanding the relationship between senile kyphosis and cervical dysfunction is crucial to tailor more specific and effective treatment programs for patients with neck dysfunction (5). The findings of this case report have important implications for the clinical setting. It is noteworthy that senile kyphosis may not be emphasized by the patients themselves or by medical professionals, but may be reversible with the help of various physical therapies (8-12). Early recognition and intervention can reduce suffering and significantly improve the patients' quality of life. I present this case in accordance with the CARE reporting checklist (available at https://acr.amegroups.com/article/view/10.21037/acr-24-41/rc).

Highlight box

Key findings

- The goal of this case study is to give evidence supporting the concept of regional interdependence between senile kyphosis and cervical postural syndrome. It accomplishes this by demonstrating the positive outcomes of a multimodal chiropractic intervention carried out over the course of 24 months.

What is known and what is new?

- Senile kyphosis may not be a primary complaint for aged individuals seeking professional healthcare, yet it can lead to functional challenges and related health risks.
- Conservative interventions have the potential to address kyphotic curvature and offer a promising solution for alleviating the discomfort associated with the deformities.

What is the implication, and what should change now?

- Early correction of senile kyphosis can reduce functional limitations and associated health risks. Interventions and treatment plans should be expanded to include overlooked causes or areas that may be contributing to the patient's complaints.

Case presentation

The patient, a 60-year-old female office manager, had been suffering from chronic pain at the base of the neck and across the top of her right shoulder for five years, with intermittent tingling in her right second and third fingers. The patient had a significant medical history of essential hypertension and was undergoing treatment for it. She denied previous history of any trauma. There was no known history of serious illness in her family. Her family doctor diagnosed her with cervical syndrome related to cervical spondylosis based on the findings from radiographs. Over the past year, she had been taking pain medication and undergoing ten sessions of physiotherapy and monthly massage therapy. Unfortunately, these treatments did not alleviate her symptoms and instead resulted in a steady forward leaning of her head, which was attributed to bad posture caused by prolonged sedentary periods at a desk.

On physical assessment, it was observed that she had a hunchbacked appearance and a posture of protruding chin. She weighed 65 kg and was 158 cm tall, giving her a body mass index (BMI) of 26 kg/m^2 (overweight). The pain in her neck and shoulder was described as deep and achy. She rated her pain as a "5" on a numerical rating scale (NRS 0–10; 0, no pain; 10, worst pain imaginable) (13), indicating moderate intensity and interference with function. Her overall quality of life (WHOQOL-BREF questionnaire) (14) was scored at 75 (Higher scores reflect a better quality of life). Cervical extension was limited to 10° (normal ~70°) (15), while bilateral rotation was restricted to 20° (normal ~90°) (15) and painful on the right side. Side flexion was also limited and painful on the right side. Motion palpation revealed tenderness and limited movement at the levels of C4-5 and C5-6. Palpation of the right deep upper cervical extensors, levator scapulae, upper trapezius, and sternocleidomastoid muscles identified myofascial trigger points and tight muscles. The Spurling's neck compression test resulted in tingling beginning in the right medial scapula region and extending to the 7th dermatome. Manual muscle testing (16),

© AME Publishing Company.

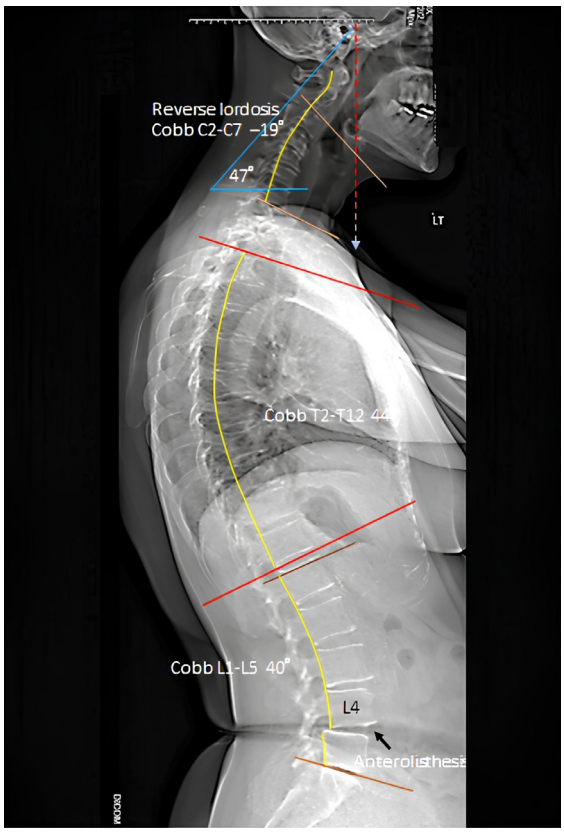

Figure 1 Initial sagittal EOS® radiograph of the spine demonstrating a loss of cervical lordosis and narrowing at the intervertebral disc spaces of C4/5, C5/6, T6/7, T7/8, L3/4, L4/5, and L5/S1, with grade I anterolisthesis of L4 on L5. Marginal osteophyte formation is observed in the cervical and lumbar spine. The center of gravity plumb line (dashed line) represents the virtual gravity line of the entire body, and it should pass through the midline of the body.

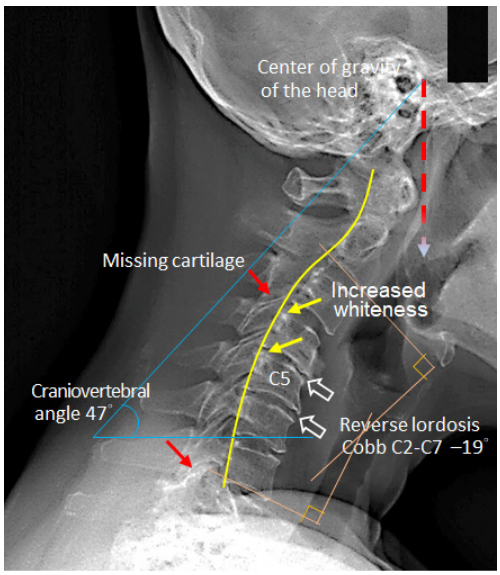

Figure 2 Sagittal close-up view of patient's cervical spine showing endplate sclerosis, disc space narrowing (hollow white arrows), anterior and posterior marginal lipping of vertebrae, and degenerative hypertrophy of the facets (red arrows) and uncovertebral joints (yellow arrows), compatible with cervical degenerative spondylosis. The craniovertebral angle is 47°. An angle less than 50° will be defined as forward head posture. Reverse cervical lordosis is highlighted by the posterior vertebral line (yellow line). The center of gravity plumb line (dashed line) is considered the virtual gravity line of the entire body and should pass though the midline of the body.

deep tendon reflexes, and sensory testing were normal. EOS® radiographs (*Figures 1,2*) revealed reverse lordosis of the cervical spine from C3 to C7, with accelerated degeneration of the C4/5, C5/6, L3/4, L4/5, and L5/S1 intervertebral discs, as well as a grade I anterolisthesis of L4 on L5. The Cobb angle of kyphosis was measured 44°. Based on the primary complaint of neck and shoulder pain and the assessment findings, the differential diagnosis included thoracic kyphosis (ICD-10-CM Code M40.204) and cervical postural syndrome (ICD-10-CM Code M99.01).

After ruling out all risk factors for major adverse events, a series of chiropractic treatments was initiated. The objective of the chiropractic rehabilitation program spanning 24 months was to improve posture, alleviate pain, and enhance the functional capacity of the neck. Initially, the patient attended 8 sessions per month for the first 3 months. The multimodal chiropractic treatment plan included using high-velocity low-amplitude manipulation to elicit the release of joint restriction (17), applying axial cervical extension traction to alleviate pain and to restore the natural curve of the neck (18), using therapeutic ultrasound to reduce inflammation, and doing daily neck stretches (forward and backward tilt, side tilt, and side rotation) and isometric chin tucks (tucking the chin in against an isometric pushing onto the forehead) at home. Afterward, the frequency of treatment was reduced to once a week for the next 9 months, while continuing manipulative techniques and cervical extension traction to maintain the corrected alignment. Moreover, a home program focused on improving posture and core stability was implemented. The glute bridge, planks, and opposing arm and leg raises were prescribed as core stability exercises. During the second year of the chiropractic program, monthly sessions were scheduled for maintenance, focusing

© AME Publishing Company.

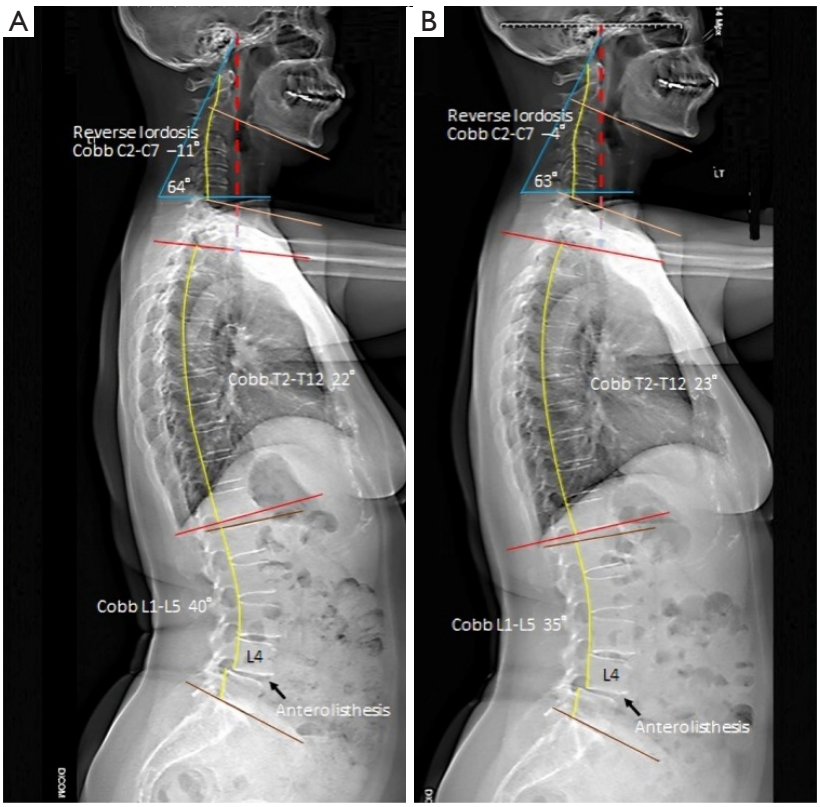

Figure 3 Comparison of spinal alignment over time in the same patient shown in *Figure 1*. (A) In the 12th month evaluation, the lordosis $Cobb_{C2\text{-}C7}$ angle is measured at –11°, the kyphosis $Cobb_{T2\text{-}T12}$ angle at 22°, and the lordosis $Cobb_{L1\text{-}L5}$ angle at 40°. (B) A repeat EOS® radiograph at the 24th month evaluation reveals a correction of the craniovertebral angle and cervical curvature. The spinal curvature is highlighted by the posterior vertebral line (yellow line).

on core-muscle training. Additionally, a home program was suggested, which included seated thoracic extensions (crossing the arms over the chest and leaning backward in the chair to arch the upper back), scapular retractions (drawing the shoulder blades together towards the spine to strengthen the muscles around them) and chest stretches (placing the forearm and elbow on one side of the doorway and gradually turning the body away to feel a stretch in the chest and front of the shoulder, repeating on the other side). Also, recommendations regarding ergonomics were provided, such as suggestion for ergonomic workstations, posture and positioning.

The patient exhibited a gradual response to the prescribed treatment. After undergoing treatment for a period of 6 months, the patient's pain rating decreased from 5 to 2 on a numeric pain rating scale. The patient's cervical range of motion improved, with an extension of 50° and rotation of 75°. Furthermore, the size of the thoracic hump was reduced. Patient adherence to the home-based program was assessed using a self-reported exercise diary, revealing an adherence rate of 63% to the exercises. Subsequent evaluations conducted after one year demonstrated significant improvement in all radiographic parameters, as depicted in *Figure 3A*, as well as enhanced spinal function. At the 24-month assessment (*Figures 3B*,*4*), all complaints had completely resolved, allowing the patient to fully engage in daily and recreational activities. Moreover, the score of follow-up WHOQOL-BREF increased to 95, suggesting a substantial improvement in the patient's perceived quality of life across all evaluated domains. Radiographs were repeated after treatment completion, parameters of spinal morphology, including sagittal curvature, craniovertebral angle (CVA), Cobb angle, and center of gravity plumb line were all improved (*Figure 3B* and *Table 1*). Importantly, no adverse effects related to the treatment were observed in the patient.

All procedures performed in this study were in accordance

© AME Publishing Company.



Figure 4 sEMG comparison pre- and post-treatment. (Left) During the initial evaluation, high readings indicate muscle spasms in both the trapezius and erector spinae muscle groups, suggesting the considerable strain in these muscles as a result of thoracic hyperkyphosis. (Right) Following a 24-month chiropractic therapy, the sEMG signal of most muscle groups is mitigated, and the decreased EP stress score correlates positively with the relief of the patient's symptoms. The EP stress score represents the cumulative muscle activity along the spine, measured in microvolts. EP, electrophysiological; sEMG, surface electromyography.

Table 1 Data of patient's radiographic parameters evaluated over the period of treatment

Evaluation	CVA	$Cobb_{C2-C7}$	$Cobb_{T2-T12}$	$Cobb_{L1-L5}$
Initial	47°	19° reverse	44°	40°
12th month	64°	11° reverse	22°	40°
24th month	63°	4° reverse	23°	35°

CVA, craniovertebral angle.

with the ethical standards of the institutional and national research committee(s) and with the Helsinki Declaration (as revised in 2013). Written informed consent was obtained from the patient for publication of this case report and accompanying images. A copy of the written consent is available for review by the editorial office of this journal.

Discussion

Thoracic kyphosis tends to worsen with age due to wear and tear on the spine over time (9,11). There is currently no consensus on the threshold values to define hyperkyphosis or "normal" aging-related changes in the spine (19). In older people, the kyphosis angle is on average 48° to 50° in women and 44° in men. Some publications recommend a hyperkyphosis threshold above 50° (19). There are different methods to assess kyphosis, but Cobb maneuvers are most commonly used in radiology (19). To increase generalizability and obtain comparative data, the Cobb method was used to assess thoracic kyphosis in this study. Due to shoulders obscuring the view of the cervicothoracic junction, measuring thoracic kyphosis was assessed on a sagittal EOS® radiograph with T2 and T12 contours. Patients who have an excessive curvature display a hunchbacked appearance and a typical posture of protruding chin. This posture places additional strain on the extensor muscles and bones in the neck, leading to cervical postural syndrome. It is important to underline that around 90% of cervical pain cases can be ascribed to degenerative changes within the cervical spine (4).

Progressive kyphosis develops from a variety of factors, the most common of which is an age-related loss in back

© AME Publishing Company.

muscular strength (20). Sarcopenia is the gradual decline in muscle fiber size and the potential substitution of these fibers with fat and connective tissue that occurs with age. These alterations eventually weaken the muscles. As the strength of the back muscle weakens, the back muscles gradually provide less support to the spine. As a result, this degeneration contributes to the abnormal curvature of the spine (20). Underlying osteoporosis is an excellent predictor of long-term progression of kyphosis (21,22). Aging degrades bone composition, structure, and function, which contributes to osteoporosis (23). Aging also causes a drop in vitality and functional loss of intervertebral disc cells, leading to intervertebral disc degeneration (24). These pathological conditions render the bones and discs more fragile, delicate, and deformable. In turn, the thoracic spine gradually bends forward. Unhealthy habits, such as repetitive physical activity like typing on a computer, maintaining a slouched posture while watching television, and prolonged use of mobile phones, have been identified as risk factors for developing a hunchback (25). Physical inactivity and low protein intake are the leading causes of age-related sarcopenia and obesity. Thoracic kyphosis and lumbar lordosis are frequent complications of age-related sarcopenia (26).

As thoracic kyphosis progresses, upper cervical spine undergoes compensatory extension to hold the head's position at a horizontal sight level, known as 'forward head posture'. Forward head posture is diagnosed when the CVA is less than 50° or when the horizontal distance from the vertical line of gravity to the tragus is 5 cm or more (27). Studies have shown a significant correlation between thoracic kyphosis and forward head posture (6), as well as an association between the CVA and senile kyphosis (5). Traditionally, CVA is assessed externally on the person using lateral photographs. For this patient, CVA values were obtained internally using cervical sagittal radiographs to allow retrospective comparison of the change in head posture after chiropractic treatment. Forward protrusion of the head impairs the ability to maintain balance in the sagittal plane and increases risk of falls and related morbidity and mortality (28).

From a biomechanical perspective, forward head posture places stress and tension on the suboccipital, neck, and shoulder muscles, making them overstretched and fatigued (29). A phenomenon known as creep results in the constant increase in the resting length of the tissue, mimicking constant stretching (30). The cervical spine exhibits viscoelastic creep behavior, meaning that it undergoes time-dependent inelastic deformation under prolonged or excessive loading (31). Cervical instability occurs when there is a combination of gradual viscoelastic creep in the soft tissues and a decrease in reflexive muscular activation. This reduces protection against spinal instability (31). The facet joints of the cervical spine are primarily stabilized by the capsular ligaments (32). It has been suggested that chronic neck pain is largely caused by underlying joint instability due to capsular ligament laxity and creep (32). As shown in this case report, the presence of arthritic facets (shown in *Figure 2*) indicated that the cervical spine was mobile.

The treatments to correct the curvature of the spine are very diverse (33). Physical therapy is recommended as the initial approach, especially since many cases of hyperkyphosis stem from musculoskeletal problems (9,26). A recent clinical study (34) found that higher muscle tension, as indicated by surface electromyography (sEMG) amplitude recording, was associated with greater deviation in spinal curvature. Therefore, the goal of chiropractic treatment should be to reinstate the proper tension of the spinal muscles. Strengthening and stretching exercises are often used in physical interventions to correct hyperkyphosis. A study of fifty-one older adults with cervical dysfunction found that correcting forward head posture can alleviate cervical dysfunctions, and treating thoracic kyphosis impairments can promote overall physical well-being (5). Daily activities with poor posture often contribute to a worsening thoracic kyphosis. This emphasizes the importance of maintaining proper posture and engaging core strengthening exercises to prevent the progressive development of a hunched posture as we age.

The findings of this case provide evidence support several issues. First, the clinical practices observed in this case support the concept of regional interdependence, which refers to the interaction of different regions of the body (7). There is growing evidence to suggest that interventions targeting the thoracic spine may be able to alleviate cervical dysfunction (35). Therefore, interventions and treatment strategies should be expanded to include other causes or domains that may contribute to the patient's complaints. Early correction of hyperkyphosis may reduce the incidence of falls, fractures, and functional impairments (9).

The study's limitations stem from the use of a multimodal protocol and reliance on patient-reported data. As a result, it was impossible to determine the precise efficacy of various treatment strategies. Radiography has inherent limitations. There was a 20° difference in arm elevation between the first radiograph and the two follow-ups, potentially impacting the assessment of kyphosis angle for comparison analysis. Furthermore, the study lacked long-term follow-up imaging

© AME Publishing Company.

to establish a link between long-term improvements and structural alterations, which would provide a more complete picture of the treatment's effectiveness. As the clinical report is not research, sample bias exists, and the study's conclusions may be prejudiced, less generalizable, or even deceptive. Despite these limitations, the findings gave useful insights into using a multimodal regimen to treat a complex diagnostic and therapeutic illness. To expand our understanding of therapy benefits and the mechanisms behind symptom reduction, objective outcome measurements and long-term follow-up are necessary.

Conclusions

Senile kyphosis is a prevalent condition that is often underestimated by healthcare professionals who are more focused on relieving patients' symptoms than on the patients' hunchback. Given the concept of regional interdependence and the potential for improving senile kyphosis, research suggests that early interventions targeting hyperkyphosis can effectively reduce spinal deformity, cervical postural syndrome, and associated problems.

Acknowledgments

None.

Footnote

Reporting Checklist: The author has completed the CARE reporting checklist. Available at https://acr.amegroups.com/article/view/10.21037/acr-24-41/rc

Peer Review File: Available at https://acr.amegroups.com/article/view/10.21037/acr-24-41/prf

Funding: None.

Conflicts of Interest: The author has completed the ICMJE uniform disclosure form (available at https://acr.amegroups.com/article/view/10.21037/acr-24-41/coif). The author has no conflicts of interest to declare.

Ethical Statement: The author is accountable for all aspects of the work in ensuring that questions related to the accuracy or integrity of any part of the work are appropriately investigated and resolved. All procedures performed in studies involving human participants were in accordance with the ethical standards of the institutional and/or national research committee(s) and with the Helsinki Declaration (as revised in 2013). Written informed consent was obtained from the patient for publication of this case report and accompanying images. A copy of the written consent is available for review by the editorial office of this journal.

Open Access Statement: This is an Open Access article distributed in accordance with the Creative Commons Attribution-NonCommercial-NoDerivs 4.0 International License (CC BY-NC-ND 4.0), which permits the non-commercial replication and distribution of the article with the strict proviso that no changes or edits are made and the original work is properly cited (including links to both the formal publication through the relevant DOI and the license). See: https://creativecommons.org/licenses/by-nc-nd/4.0/.

References

1. Xu J, Wan CS, Ktoris K, et al. Sarcopenia Is Associated with Mortality in Adults: A Systematic Review and Meta-Analysis. Gerontology 2022;68:361-76.
2. Bimali I, Pudasaini S. Hyperkyphosis among the Elderly in a Community: A Descriptive Cross-sectional Study. JNMA J Nepal Med Assoc 2022;60:710-3.
3. Mann SJ, Lam JC, Singh P. McKenzie back exercises. 2023 Jul 3. In: StatPearls [Internet]. Treasure Island (FL): StatPearls Publishing; 2024.
4. Kasumovic M, Gorcevic E, Gorcevic S, et al. Cervical syndrome - the effectiveness of physical therapy interventions. Med Arch 2013;67:414-7.
5. Quek J, Pua YH, Clark RA, et al. Effects of thoracic kyphosis and forward head posture on cervical range of motion in older adults. Man Ther 2013;18:65-71.
6. Torres-Cusihuaman L, Bravo-Cucci S. Association between thoracic kyphosis and forward head posture in teenagers: An analytical cross-sectional study. Middle East J Rehabil Health Stud 2023;10:e134579.
7. Sueki DG, Cleland JA, Wainner RS. A regional interdependence model of musculoskeletal dysfunction: research, mechanisms, and clinical implications. J Man Manip Ther 2013;21:90-102.
8. Jabbar KM, Gandomi F. The comparison of two corrective exercise approaches for hyperkyphosis and forward head posture: A quasi-experimental study. J Back Musculoskelet Rehabil 2021;34:677-87.
9. Katzman WB, Wanek L, Shepherd JA, et al. Age-related hyperkyphosis: its causes, consequences, and management.

J Orthop Sports Phys Ther 2010;40:352-60.
10. Fortner MO, Oakley PA, Harrison DE. Alleviation of chronic spine pain and headaches by reducing forward head posture and thoracic hyperkyphosis: a CBP(®) case report. J Phys Ther Sci 2018;30:1117-23.
11. Chau C, Chu EC, Huang KH, et al. Remission of Dowager's hump by manipulative correction of spinal alignment: a case report. J Med Life 2023;16:957-62.
12. Pawlowsky SB, Hamel KA, Katzman WB. Stability of kyphosis, strength, and physical performance gains 1 year after a group exercise program in community dwelling hyperkyphotic older women. Arch Phys Med Rehabil 2009;90:358-61.
13. Jensen MP, Karoly P, O'Riordan EF, et al. The subjective experience of acute pain. An assessment of the utility of 10 indices. Clin J Pain 1989;5:153-9.
14. World Health Organisation. WHOQOL: Measuring Quality of Life. Available online: https://www.int/tools/whoqol. Accessed 16 February 2024.
15. Swartz EE, Floyd RT, Cendoma M. Cervical spine functional anatomy and the biomechanics of injury due to compressive loading. J Athl Train 2005;40:155-61.
16. Ciesla N, Dinglas V, Fan E, et al. Manual muscle testing: a method of measuring extremity muscle strength applied to critically ill patients. J Vis Exp 2011;2632.
17. LaPelusa A, Bordoni B. High-velocity low-amplitude manipulation techniques. [Updated 2023 Jun 4]. In: StatPearls [Internet]. Treasure Island (FL): StatPearls Publishing; 2024.
18. Oakley PA, Ehsani NN, Moustafa IM, et al. Restoring cervical lordosis by cervical extension traction methods in the treatment of cervical spine disorders: a systematic review of controlled trials. J Phys Ther Sci 2021;33:784-94.
19. Kado DM, Prenovost K, Crandall C. Narrative review: hyperkyphosis in older persons. Ann Intern Med 2007;147:330-8.
20. Liu J, Liu P, Ma Z, et al. The effects of aging on the profile of the cervical spine. Medicine (Baltimore) 2019;98:e14425.
21. Kado DM, Miller-Martinez D, Lui LY, et al. Hyperkyphosis, kyphosis progression, and risk of non-spine fractures in older community dwelling women: the study of osteoporotic fractures (SOF). J Bone Miner Res 2014;29:2210-6.
22. Woods GN, Huang MH, Lee JH, et al. Factors Associated With Kyphosis and Kyphosis Progression in Older Men: The MrOS Study. J Bone Miner Res 2020;35:2193-8.
23. Demontiero O, Vidal C, Duque G. Aging and bone loss: new insights for the clinician. Ther Adv Musculoskelet Dis 2012;4:61-76.
24. Wen P, Zheng B, Zhang B, et al. The role of ageing and oxidative stress in intervertebral disc degeneration. Front Mol Biosci 2022;9:1052878.
25. Lam JC, Mukhdomi T. Kyphosis. [Updated 2023 Aug 8]. In: StatPearls [Internet]. Treasure Island (FL): StatPearls Publishing; 2024.
26. Zaborova V, Zolnikova O, Dzhakhaya N, et al. Associations between Physical Activity and Kyphosis and Lumbar Lordosis Abnormalities, Pain, and Quality of Life in Healthy Older Adults: A Cross-Sectional Study. Healthcare (Basel) 2023;11:2651.
27. Sim G, Kim D, Jeon H. Comparing the effects on manual and self-exercise therapy for improving forward head posture. Phy Ther Korea 2023;30:184-93.
28. Kado DM, Huang MH, Nguyen CB, et al. Hyperkyphotic posture and risk of injurious falls in older persons: the Rancho Bernardo Study. J Gerontol A Biol Sci Med Sci 2007;62:652-7.
29. Lee JH. Effects of forward head posture on static and dynamic balance control. J Phys Ther Sci 2016;28:274-7.
30. Blum W, Eisenlohr P, Breutinger F. Understanding creep - a review. Metall Materials Trans Metall Mater Sci 2002;33:291-303.
31. Abboud J, Nougarou F, Descarreaux M. Muscle Activity Adaptations to Spinal Tissue Creep in the Presence of Muscle Fatigue. PLoS One 2016;11:e0149076.
32. Steilen D, Hauser R, Woldin B, et al. Chronic neck pain: making the connection between capsular ligament laxity and cervical instability. Open Orthop J 2014;8:326-45.
33. Suwaidi ASA, Moustafa IM, Kim M, et al. A Comparison of Two Forward Head Posture Corrective Approaches in Elderly with Chronic Non-Specific Neck Pain: A Randomized Controlled Study. J Clin Med 2023;12:542.
34. Wilczyński J, Karolak P, Janecka S, et al. The relationship between the angle of curvature of the spine and sEMG amplitude of the erector spinae in young school-children. Appl Sci 2019;9:3115.
35. Cleland JA, Childs JD, McRae M, et al. Immediate effects of thoracic manipulation in patients with neck pain: a randomized clinical trial. Man Ther 2005;10:127-35.

doi: 10.21037/acr-24-41
Cite this article as: Chu ECP. Regional interdependence between senile kyphosis and cervical postural syndrome: a case report. AME Case Rep 2025;9:52.

© AME Publishing Company.