

## Kikuchi-Fujimoto disease: unusual presentation of rare disease

Duy Vu,<sup>1</sup> Srinu Reddy,<sup>2</sup> Lynn Day,<sup>1</sup> Nail Aydin,<sup>1</sup> Subhasis Misra<sup>1</sup>

<sup>1</sup>Texas Tech University Health Sciences Center School of Medicine, Amarillo, TX;

<sup>2</sup>Texas Oncology, Amarillo, TX, USA

### Abstract

Kikuchi-Fujimoto disease (KFD) is a rare, benign disorder that typically follows a self-limiting natural course and was initially described in young females of Asian descent. Its clinical presentation may mimic lymphoproliferative disorders, connective tissue disorders, and chronic infections. This often leads to misdiagnosis and inappropriate treatment. The exact cause of this condition remains unknown although autoimmune processes and certain infectious agents have been associated with the disease. The diagnosis of KFD is made histopathologically. Treatment is supportive and long-term follow-up is recommended due to increased risk of future development of systemic lupus erythematosus. Here we are presenting a case of a patient with an unusual presentation of KFD.

### Case Report

Patient is a 48-year-old male who was in his usual state of health when he started having intermittent fever, chills, drenching night sweats, gradual decrease in appetite, and weight loss of 15 pounds over five weeks. He also complained of back pain and diarrhea for a few days. He noticed a rash at the onset of symptoms that subsided after a week. He denies any travel outside United States or exposure to tuberculosis. He denied cough, shortness of breath, or sore throat. He has no family history of lymphoma or other blood dyscrasias.

Due to the persistence of his symptoms, patient was admitted to the hospital. He underwent computed tomography (CT) scan of the abdomen and pelvis without contrast, which showed enlarged portacaval and retroperitoneal lymph nodes ranging up to 1.5 cm. No kidney stones or other abnormalities were noted to explain his back pain. He also had CT of the neck and chest without contrast, which did not show any abnormal adenopathy in those areas.

Extensive laboratory workup was done, including hepatitis serology, which was nega-

tive. HIV was negative. Alpha-fetoprotein was normal. Rheumatoid factor was not elevated. ANA and anti-dsDNA antibodies were negative. However, C-reactive protein (CRP) was high at 2.04 (less than 0.7 mg/dL). Serum electrophoresis was done which showed no abnormal paraprotein. Blood culture and urine culture did not grow any organisms. Stool was negative for *Clostridium difficile* toxin and negative for ova and parasites. Citomegalovirus immunoglobulin (Ig) M was negative, but IgG was elevated. IgG of Epstein-Barr virus was elevated, but IgM was not. Coxsackievirus panel was negative except for coxsackievirus B4 and B6, which was 1H28; normal range is less than 1H28. The only obvious abnormalities were elevation in  $\beta$ -2 microglobulin of 4.53, elevation in lactate dehydrogenase up to 450, and elevation in CRP.

Patient was empirically placed on IV antibiotics with no improvement in symptoms, ruling out bacterial infection as a possible cause. Patient was noted to have leukopenia with absolute neutropenia while no malignant cells were identified on peripheral smear. Because of persistence of symptoms and no obvious infectious or inflammatory etiology obtained, bone marrow aspiration and biopsy was recommended. Bone marrow biopsy showed normal hematopoiesis and no evidence of lymphoproliferative disorders. Cytogenetics was normal. AFB cultures showed no growth, ruling out tuberculosis.

He underwent positron-emission tomography/CT scan to assess lymphadenopathy, which showed mild to moderate hypermetabolism involving several enlarged lymph nodes in the upper abdomen and upper retroperitoneum. The largest conglomerates of lymph nodes are present in the right periceliac and peripancreatic area, measuring up to 4.2x2.5 cm with uptake of 2.8. Portacaval lymph nodes measured 2.7x1.7 with uptake of 3.5.

He underwent excision biopsy of the periportal and retroperitoneal lymph nodes (Figures 1 and 2). Pathology reported as atypical lymphoid proliferation with foci of necrosis representing necrotizing lymphadenitis or lupus lymphadenitis. It was noted that the differential diagnosis included lymphoid neoplasm with focal necrosis such as Hodgkin lymphoma or non-Hodgkin lymphoma. However, flow cytometry revealed no evidence of B cell non-Hodgkin's lymphoma. The case was reviewed intradepartmentally without consensus, and was therefore sent for outside consultation for expert hematopathologist's review. Histologic sections revealed slightly thickened lymph node capsules with no significant capsular infiltration or extracapsular extension of lymphoid tissue. The normal nodal architecture was distorted. There were many residual germinal centers present with typical benign features. Focally throughout the node were atypical large pale areas, which

Correspondence: Subhasis Misra, Texas Tech University Health Sciences Center, 1400 South Coulter Street 3550, Amarillo, TX 79106, USA. Tel.: +1.806.354.5696 - Fax: 1.806.354.5693. E-mail: subhasis.misra@ttuhsc.edu

Key words: Kikuchi-Fujimoto disease; lymphadenitis; lymphoma.

Contributions: SR, LD, SM, decision to write case report; DV, manuscript writing and references search; LD, collection of materials; SR, LD, NA, SM, manuscript reviewing and revising.

Conflict of interest: the authors declare no potential conflict of interest.

Received for publication: 27 November 2015.

Revision received: 3 March 2016.

Accepted for publication: 13 March 2016.

This work is licensed under a Creative Commons Attribution NonCommercial 4.0 License (CC BY-NC 4.0).

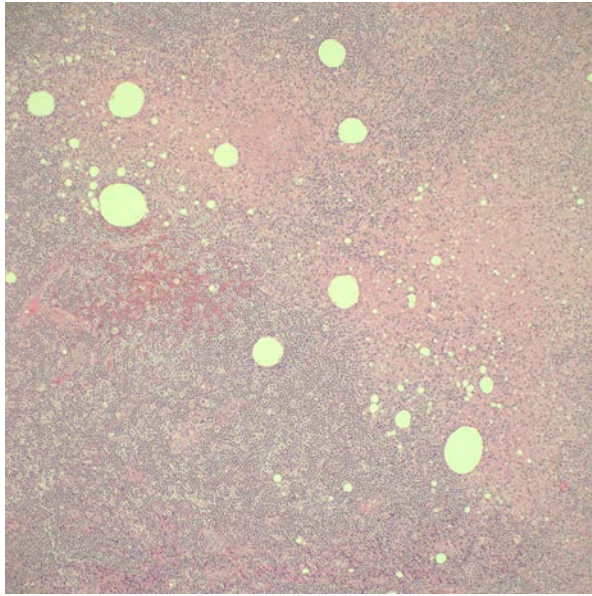
©Copyright D. Vu et al., 2016  
Licensee PAGEPress, Italy  
Clinics and Practice 2016; 6:828  
doi:10.4081/cp.2016.828

were composed of small lymphocytes, increased numbers of histiocytes and some small fragments of scattered apoptotic debris. No viral inclusions, atypical lymphocytes, Hodgkin cells or diffuse areas of large cells were identified. Final pathology from outside consultation confirmed as necrotizing histiocytic lymphadenitis. It was recommended we rule out acute lupus lymphadenitis, which has similar morphological findings as KFD. ANA, anti-dsDNA antibodies, and antiphospholipid antibodies were rechecked and came back negative.

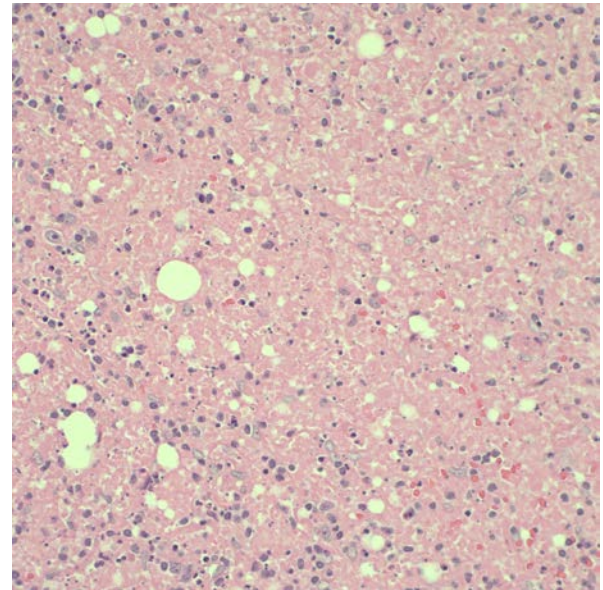
The treatment for this patient was supportive which included non-steroidal anti-inflammatory agents for symptomatic relief. Patient was advised to take naproxen and acetaminophen as needed for his fever and to reduce inflammation. Patient recovered slowly from surgery. Four months after the onset of symptoms, the patient's fatigue and appetite improved. He began to gain weight but still had occasional night sweats. He denied fever, chills, or rigors. At his six-month follow-up, the patient's symptoms completely resolved. Repeat CT of the abdomen and pelvis showed improvement and decrease in size of the retroperitoneal and peritoneal lymph nodes.

### Discussion

Kikuchi-Fujimoto disease or histiocytic necrotizing lymphadenitis is a benign, self-



**Figure 1.** Low power view of hematoxylin and eosin stained lymph node biopsy showing areas of necrosis surrounded by numerous histiocytes.



**Figure 2.** High power view of disrupted architecture of necrotic area with apoptotic bodies and karyorrhectic debris.

limiting disease. It was initially described by Japanese pathologists in 1972 and was classically seen in Asian females younger than 35 years of age.<sup>1</sup> However, recent studies have shown a worldwide distribution and affects males and females almost equally.<sup>2,3</sup> The exact etiology of KFD remains unknown. However, many infectious agents such as Epstein-Barr virus and human herpes virus are associated with the disease.<sup>4</sup>

Patients commonly present with painful cervical lymphadenopathy and fever. Affected lymph nodes usually range from 0.5 to 4.0 cm.<sup>2</sup> Less common symptoms include chills, night sweats, weight loss, arthralgia, and cutaneous manifestations.<sup>2,5</sup> Although the amount of weight loss is not mentioned in the literature, our patient had lost a significant amount of weight. This may be explained by lack of appetite due to an inflammatory response and release of cytokines. These presenting features mimic other common conditions, which may lead to misdiagnosis and inappropriate treatment. Differential diagnosis includes lymphoproliferative disorders, systemic lupus erythematosus (SLE), and infection.<sup>5</sup> Excision biopsy of affected lymph nodes is essential for diagnosis. Histopathological findings include paracortical expansion with foci of coagulative necrosis and extensive karyorrhectic debris.<sup>6</sup> Several studies have shown CD8+ T lymphocytes and plasmacytoid dendritic cells as the predominant proliferating cells with a relative absence of neutrophils.<sup>3,6,7</sup>

There are currently no treatment guidelines for KFD although spontaneous resolution typically occurs in one to six months with a low recurrence rate of 3-4%.<sup>1,3,7</sup> Due to its underly-

ing inflammatory response, non-steroidal anti-inflammatory drugs and antipyretics are important for symptomatic relief. In severe cases, high-dose corticosteroids or hydroxychloroquine have been shown to be effective in rapid resolution of symptoms.<sup>1,2,3,7</sup> Due to its association with connective tissue disorders, patients should be evaluated for simultaneous or subsequent development of SLE.<sup>8</sup>

## Conclusions

Kikuchi-Fujimoto disease is a rare, self-resolving disorder that primarily affects younger adults (under the age of 35) worldwide. Patients typically present with painful cervical lymphadenopathy and intermittent fever. However, our patient, who is older than the typical patient with KFD, presented instead with periportal and retroperitoneal lymphadenopathy. Clinically, Kikuchi-Fujimoto disease cannot be differentiated from lymphoproliferative disorders, connective tissue disorders, or an infectious process. It is important to make an accurate diagnosis with biopsy for histology in order to prevent any unnecessary treatment that may be harmful to the patient. Through excision biopsy of affected lymph nodes and extensive investigations, we were able to narrow our diagnosis and to rule out lymphoma. Although pathology report could not rule out lupus adenitis, we were able to exclude this diagnosis with the patient's clinical presentation and serum studies. Long-term follow-up is recommended due to the increased risk of future development of SLE.

## References

1. Yalcin S, Toprak SK, Erismis B, et al. Management of Kikuchi-Fujimoto disease using glucocorticoid: a case report. *Case Rep Med* 2011;2011:230840.
2. Deaver D, Horna P, Cualing H, Sokol L. Pathogenesis, diagnosis, and management of Kikuchi-Fujimoto disease. *Cancer Control* 2014;21:313-21.
3. Bosch X, Guilabert A. Kikuchi-Fujimoto disease. *Orphanet J Rare Dis* 2006;1:18.
4. Hudnall D, Chen T, Amr S, et al. Detection of human herpesvirus DNA in Kikuchi-Fujimoto disease and reactive lymphoid hyperplasia. *Int J Clin Exp Pathol* 2008;1:362-8.
5. Deaver D, Naghashpour M, Sokol L. Kikuchi-Fujimoto disease in the United States: three case reports and review of the literature. *Mediterr J Hematol Infect Dis* 2014;6:e2014001.
6. Rakesh P, Alex RG, Varghese GM, et al. Kikuchi-Fujimoto disease: clinical and laboratory characteristics and outcome. *J Glob Infect Dis* 2014;6:147-50.
7. Rezayat T, Carroll MB, Ramsey BC, Smith A. A case of relapsing Kikuchi-Fujimoto disease. *Case Rep Otolaryngol* 2013;2013:364795.
8. Patra A, Bhattacharya SK. SLE developing in a follow-up patient of Kikuchi's disease: a rare disorder. *J Clin Diagn Res* 2013;7:752-3.