

# Etiology and management of nasopharyngeal hemorrhage after radiotherapy for nasopharyngeal carcinoma

Jiabin Zhan<sup>1,\*</sup>

Shuai Zhang<sup>2,\*</sup>

Xin Wei<sup>1</sup>

Yihui Fu<sup>3</sup>

Jing Zheng<sup>1</sup>

<sup>1</sup>Department of Otolaryngology, Hainan General Hospital, Haikou 570311, Hainan, China; <sup>2</sup>Department of Radiation Oncology, Hainan General Hospital, Haikou 570311, Hainan Province, China; <sup>3</sup>Department of Respiratory Medicine, Hainan General Hospital, Haikou 570311, Hainan Province, China

\*These authors contributed equally to this work

**Objective:** To analyze the etiology of nasopharyngeal hemorrhage after radiotherapy for nasopharyngeal carcinoma (NPC) and evaluate the relevant management and rescue approaches.

**Methods:** Seventeen cases of nasopharyngeal hemorrhage caused by radiotherapy of NPC, treated between January 2015 and March 2018, were retrospectively analyzed to study the etiology of nasopharyngeal hemorrhage. The management and rescue strategies, including anterior and posterior nostril packing, endoscopic nasopharynx electrocoagulation, and digital subtraction angiography embolization, were assessed for their effectiveness.

**Results:** Nasopharynx hemorrhage after radiotherapy of NPC was mainly associated with erosion of the internal carotid artery or maxillary artery by the tumor. Among the 17 cases, 11 patients were treated by digital subtraction arterial angiography embolization, and 3 were treated by endoscopic nasopharynx electrocoagulation. Overall, 13 patients survived, while 4 died.

**Conclusion:** Anterior and posterior nostril packing, endoscopic nasopharynx electrocoagulation, and digital subtraction angiography embolization are suitable for treating nasopharyngeal hemorrhage. However, effective hemostasis depends on early identification of the bleeding vessels.

**Keywords:** nasopharyngeal carcinoma (NPC), nasopharyngeal hemorrhage, radiotherapy, prognosis

## Introduction

Nasopharyngeal carcinoma (NPC) is the most common head and neck cancer in southern China, affecting 30 out of 100,000 people. It is usually diagnosed with a high degree of malignancy and consequently leads to >34,000 deaths annually.<sup>1</sup> Currently, the primary treatment modality for NPC is radical radiation therapy, with chemotherapy as an auxiliary option. Although radiotherapy has evolved from two-dimensional radiotherapy to intensity-modulated radiation therapy (IMRT), which has improved local control rates and minimized adverse effects on surrounding healthy tissue, radiation complications are frequently observed. These include xerostomia, sinusitis, temporal lobe necrosis, cranial nerve palsy, and brainstem damage.<sup>2</sup> In addition, radiation arteritis with carotid stenosis, especially nasopharyngeal hemorrhage, also occurs often.<sup>3</sup>

The vascular injury resulting from radiation is believed to be a significant cause of bleeding after radiation treatment for NPC.<sup>4</sup> Multiple factors may be involved, including local hypoxia, vascular remodeling, inflammatory infection, nasopharyngeal and nasal dysfunction, dry mucous membranes, tumor recurrence, and malnutrition.<sup>5</sup> Nasopharyngeal hemorrhage represents a particular subtype of epistaxis after radiotherapy for NPC, described as a sudden hemorrhage of >100 mL or continuous bleeding of more than 300 mL in the nasopharyngeal area within a short period.<sup>6</sup> The condition is usu-

Correspondence: Shuai Zhang  
Department of Radiation Oncology,  
Hainan General Hospital, No. 19 Xiuhua  
Road, Xiuying District, Haikou 570311,  
Hainan Province, China  
Tel +86 138 7642 8968  
Email 46370976@qq.com

Xin Wei  
Department of Otolaryngology, Hainan  
General Hospital, No. 19 Xiuhua Road,  
Xiuying District, Haikou 570311, Hainan,  
China  
Tel +86 130 1629 6267  
Email hnweking@sina.com

ally dangerous and critical, with many complications, and the reported mortality rate has varied from 35.7% to 100%.<sup>7</sup>

There are no standard treatment methods for significant bleeding after radiotherapy, and bleeding-related factors should be avoided. Various hemostasis strategies are available, including packing of the anterior and posterior nostrils, applying the nasal cavity balloon, carotid artery ligation, and vascular interventional embolization. In the past five years, >800 new cases of NPC have been treated in our clinic every year. In the present study, we retrospectively analyzed the etiological factors of nasopharyngeal hemorrhage after radiotherapy for NPC and evaluated the management protocols to provide insight into improving the effectiveness of the treatments.

## Materials and methods

### Ethical statement and patient selection

This study was approved by the Ethics Committee of Hainan General Hospital, Haikou, China, and conducted in accordance with the Declaration of Helsinki. Written informed consent was obtained from each patient. The 17 patients included in this study were treated for nasopharyngeal hemorrhage after radiation treatment for NPC in Hainan General Hospital, China, from January 2015 to March 2018.

### Management of nasopharyngeal hemorrhage

Upon the emergence of nasopharyngeal hemorrhage, the upper airway patency was ensured. The blood and blood clots in the throat were timely removed with a bedside mucus suction device to prevent tracheal obstruction. Meanwhile, single- or dual-chamber balloons, which were inflated with 10–15 mL of air or water, were used to fill the nasopharynx to control the bleeding. If the bleeding continued, nasal packing with Vaseline gauze was performed to fill the anterior nares. In cases with a large amount of blood loss, intravenous access was established to meet the potential needs for intravenous fluids and blood transfusion.

Rescue and management approaches were chosen appropriately to the clinical conditions and the bleeding rate. Patients with a small amount or continuous bleeding and bleeding point identified by nasal endoscopy were treated in the emergency with endoscopic nasopharynx electrocoagulation under general anesthesia. Patients with an unidentifiable bleeding point, due to an urgent medical condition or limited diagnostic options, underwent selective digital subtraction angiography (DSA) to identify the bleeding vessel. Hemorrhage in the external carotid artery was controlled by selective vascular embolization using a stainless steel coil, while bleeding from the internal carotid artery was managed using a stent.

Endotracheal intubation was performed in an emergency that the patients presented respiratory abnormality, which might be caused by insufficient blood clot removal under conditions of restricted jaw opening and poor throat emission. A tracheotomy was performed when endotracheal intubation was infeasible. After the airway patency was ensured and bleeding controlled by using a single or double-lumen balloon tamponade, the patients were sent to the interventional room for DSA to further clarify the bleeding site and bleeding artery, which were eventually treated with selective vascular embolization. Endoscopic nasopharynx electrocoagulation hemostasis was generally not recommended for patients with nasopharyngeal hemorrhage after radiotherapy for NPC.

The treatment was considered effective if the active bleeding decreased or stopped, and hemorrhage symptoms disappeared within 72 hours.

## Results

### Physical and clinical characteristics of the patients

A total of 17 patients with nasopharyngeal hemorrhage after radiation treatment of NPC were included in this study, and their clinical characteristics are summarized in Table 1. The majority of these patients had stage III or IV NPC, which was classified according to the seventh edition of American Joint Committee on Cancer TNM classification. In the 17 patients, 10 cases received 1 course of radiotherapy, 7 cases received two courses of radiotherapy, and all patients had not undergone surgical

**Table 1** Physico-pathological characteristics of NPC patients

Characteristic	Category	Patients (n)
Age (years)	Median	62
	Range	46–75
Bleeding time (months)	Median	31
	Range	6–96
Bleeding time (hours)	Median	1.5
	Range	1–3
Sex, n (%)	Male	12 (70.6)
	Female	5 (29.4)
Radiotherapy courses, n (%)	I	10 (58.8)
	2	7 (41.2)
Clinical stage, n (%)	II	2 (11.8)
	III	5 (29.4)
	IV	10 (58.8)
Anemia, n (%)	<120 g/l	12 (70.6)
	<60 g/L	3 (17.6)
Mouth opening, n (%)	Limited	14 (82.4)
	Normal	3 (17.6)
Distant metastases, n (%)	Yes	3 (17.6)
	No	14 (82.4)

**Abbreviation:** NPC, nasopharyngeal carcinoma.

resection. Among them, 3 cases were treated by two-dimensional radiotherapy and 14 cases were treated by IMRT. The nasopharynx dose was 68–72 Gy, the cervical metastatic lymph node was 64–70 Gy, the high-risk area was 60–62 Gy, and the low-risk area was 54–56 Gy. 13 (76.5%) presented with extensive erosion and necrosis in the nasopharyngeal tissue, with necrotic tissue located mostly adjacent to the posterior wall. These patients also exhibited extensive skull base destruction and sinusitis according to computed tomography (CT) scan performed at admission (Table 2). Fourteen patients had varying degrees

of difficulty in opening their mouths, with an average gap of 2.35 cm and a minimum gap of 0.5 cm. Nasal discharge accompanied with oral or nasal odor was noted in 14 cases about two weeks before the occurrence of nasopharyngeal hemorrhage. Ten patients (58.8%) complained of recurrent headaches, including six cases with occipital pain, 2 cases with frontal pain, and two cases with palatal pain. Also, 6 patients (35.3%) suffered repeated nasal bleeding before nasopharyngeal hemorrhage. Of the 17 patients, 15 (88.2%) had unilateral illness, whereas the other 2 had bilateral hemorrhage (Table 3). The cumulative total blood

**Table 2** Imaging of skull base bone destruction

Number	Bone destruction in the sphenoid bone slope area	Bone destruction in the basal part of sphenoid bone	Bone destruction in the petrous part of temporal bone	Bone destruction of occipital bone
1	Yes	No	No	No
2	Yes	No	No	No
3	Yes	Yes	No	No
4	No	No	Yes	Yes
5	Yes	No	No	No
6	No	No	No	Yes
7	No	Yes	No	No
8	No	No	Yes	Yes
9	No	No	No	No
10	No	Yes	No	No
11	Yes	No	No	No
12	No	No	Yes	No
13	Yes	No	No	No
14	No	Yes	No	No
15	No	No	Yes	No
16	Yes	No	No	No
17	No	No	Yes	No

**Table 3** The features of 17 NPC patients with nasopharyngeal hemorrhage

Number	Difficulty in opening mouth	Pre-bleeding symptoms			Hemoglobin level on hospitalization (g/L)	Nasal hemorrhage	
		Stench from mouth and nose	Recurrent headache	A few nosebleeds one week before		Unilateral	Bilateral
1	No	Yes	Yes	Yes	83	Yes	No
2	No	Yes	No	No	125	Yes	No
3	Yes	Yes	No	No	105	Yes	No
4	Yes	Yes	Yes	Yes	74	No	Yes
5	Yes	No	Yes	No	112	Yes	No
6	Yes	No	Yes	No	43	Yes	No
7	Yes	Yes	Yes	No	133	Yes	No
8	Yes	Yes	No	Yes	89	Yes	No
9	Yes	No	Yes	No	97	Yes	No
10	Yes	Yes	No	No	101	Yes	No
11	Yes	Yes	Yes	Yes	79	Yes	No
12	Yes	No	No	Yes	56	No	Yes
13	Yes	Yes	Yes	No	67	Yes	No
14	Yes	Yes	No	No	110	Yes	No
15	No	Yes	Yes	No	104	Yes	No
16	Yes	No	No	No	112	Yes	No
17	Yes	Yes	Yes	Yes	51	Yes	No

**Abbreviation:** NPC, nasopharyngeal carcinoma.

loss ranged between 300 and 4,000 mL. All the clinical data and results are summarized in Tables 4 and 5.

## Origin and treatment of the nasopharyngeal hemorrhage

Among the 17 cases, sphenopalatine artery bleeding was found in two patients, and posterior nasal septal artery bleeding was identified in one patient. These three patients were

treated by endoscopic nasopharyngeal electrocoagulation and hemostasis.

Eleven patients were treated by digital subtraction arterial angiography embolization. These included seven patients with bleeding sites on the external carotid artery branches, such as intra-maxillary arteries, facial arteries, and ascending pharyngeal artery (Figures 1–4), 2 patients with vascular hemorrhage caused by internal carotid artery stenosis, and

**Table 4** Demographics and outcomes of 17 NPC patients with nasopharyngeal hemorrhage

Number	Sex	Age (years)	Nasopharyngeal features under endoscope	The time of massive hemorrhage after radiotherapy (years)	Clinical stage	RNPC for two-stage radiotherapy	Therapy	Affected artery	Survival
1	F	46	OR	0.5	IVa	Yes	NP + EE	SA	Alive
2	M	49	OR	2	III	Yes	NP	BOECA	Alive
3	M	63	OR	3	II	No	NP	ROICA	Alive
4	M	75	OR	0.75	IVa	Yes	NP	undefined	DLBS
5	F	58	MN	3	IVa	Yes	NP	BOECA	Alive
6	M	59	OR	1	IVa	Yes	NP + TR	undefined	DLB
7	F	66	No	8	III	No	NP	POICA	Alive
8	M	57	OR	4	III	No	NP + TR	undefined	DLB
9	M	64	No	3	III	No	NP	BOECA	Alive
10	M	52	OR	6	IVa	No	NP + EE	PNSA	Alive
11	M	65	MN	2	III	No	NP	BOECA	Alive
12	M	69	OR	4	Iva	No	NP	POICA	MODS
13	F	62	No	2	IVa	No	NP	BOECA	Alive
14	M	73	OR	2	IVa	No	NP + EE	SA	Alive
15	M	56	MN	3	II	No	NP	BOECA	Alive
16	M	74	No	0.5	IVa	Yes	NP	ROICA	Alive
17	F	61	OR	1	IVa	Yes	NP	BOECA	Alive

**Abbreviations:** DLB, died of loss of blood; DLBS, died of loss of blood and suffocation; IMA, internal maxillary artery; NP, nasal packing; NPC, nasopharyngeal carcinoma; TR, tracheostomy; APS, the arteriae pharyngea ascendens of the external carotid artery; EE, endoscopic electrocoagulation; POICA, pseudoaneurysm of internal carotid artery; OR, osteoradionecrosis; MN, member necrosis; RNPC, recurrent nasopharyngeal carcinoma; SA, sphenopalatine artery; DSA, digital subtraction angiography; PNSA, posterior nasal septum artery; BOECA, branch of external carotid artery; ROICA, rupture of internal carotid artery; MODS, multiple organ dysfunction.

**Table 5** Clinical characteristics of 10 NPC patients with just 1 course of RT

Number	Sex	Age (years)	Stage	Skull base erosion at diagnosis	GTV volume of the primary cancer (cm <sup>3</sup> )	RT dose	GTV Vol >105% (cm <sup>3</sup> )	Chemotherapy manner
1	M	63	II	No	50.6	70 Gy/30F	20.1	None
2	F	66	III	Yes	88.9	70 Gy/32F	29.8	C+A
3	M	57	III	Yes	135.6	70 Gy/32F	91.5	C+A
4	M	64	III	No	87.4	70 Gy/31F	72.5	Cc
5	M	52	IVa	Yes	107.9	70 Gy/32F	67.2	C+A
6	M	65	III	Yes	62.7	70 Gy/31F	28.1	C+A
7	M	69	IVa	Yes	165.8	70 Gy/35F	94.2	C+A
8	F	62	IVa	Yes	145.6	70 Gy/32F	99.2	C+A
9	M	73	IVa	Yes	107.2	70 Gy/32F	71.1	C+A
10	M	56	II	No	49.2	69 Gy/30F	39.6	None

**Notes:** Concurrent chemotherapy program consisted of cisplatin; the adjuvant chemotherapy program consisted of cisplatin and 5-fluorouracil.

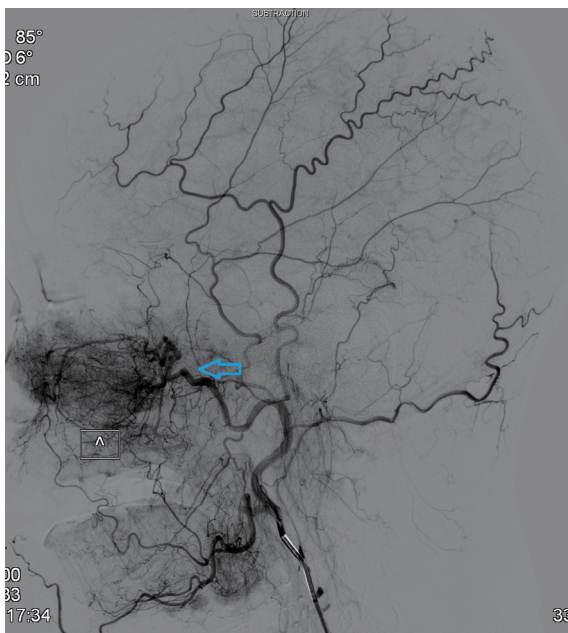
**Abbreviations:** GTV, gross tumor volume; KDI, keep doing irrigation; NPC, nasopharyngeal carcinoma; ODI, occasionally doing irrigation; RT, radiotherapy; TCM, traditional Chinese medicine; C+A, concurrent + adjuvant; Cc, concurrent chemotherapy.

two patients with hemorrhage resulting from the rupture of a pseudoaneurysm in the internal carotid artery (Figures 5 and 6). The bleeding sites were identified by the bilateral external carotid artery and internal carotid artery angiography in which the contrast-enhanced Seldinger technique was used to percutaneously puncture the right femoral artery with a 4F or 5F Cobra catheter or a multipurpose catheter. Embolization approaches were chosen based on the results of angiography. External carotid artery branches were embolized with a steel coil alone, a steel coil plus gelatin sponge, or a steel coil together with polyvinyl alcohol particles. Internal carotid artery embolization was achieved using a removable balloon

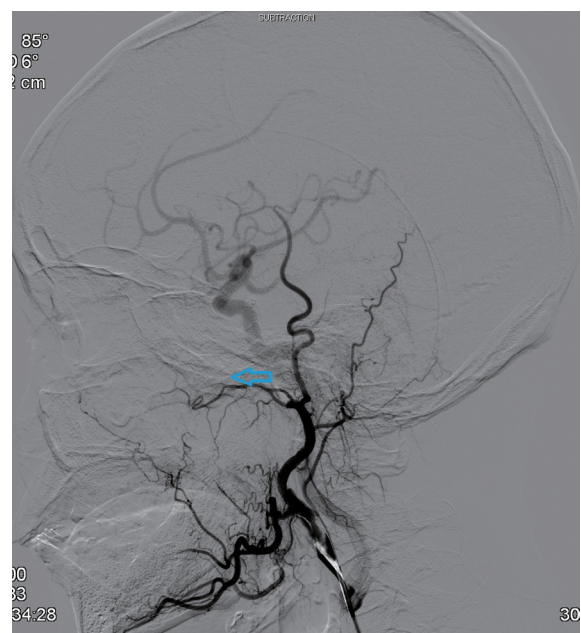
with a closed-cell stent. Eight (72.7%) of these 11 patients underwent single intervention, 2 patients received a double intervention and one required triple intervention. After interventional treatment, 81.8% (9/11) of patients had bilateral maxillofacial pain, pharyngeal numbness, and difficulties in opening the mouth. The symptoms improved significantly after hormone-assisted treatment for half a month and had entirely resolved after one month.

### Patient outcomes

Thirteen of the 17 patients were successfully rescued, whereas four died. Six months of follow-up in the 13 surviving



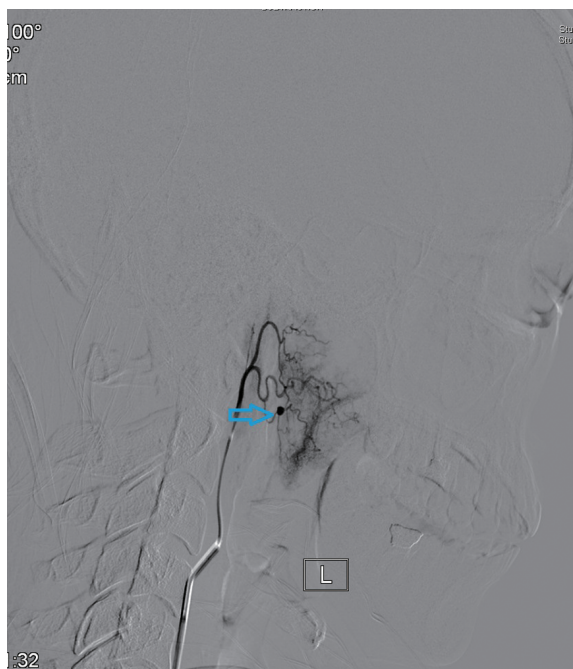
**Figure 1** External carotid artery angiogram showing the bleeding sites on the internal maxillary artery (indicated by the arrow).



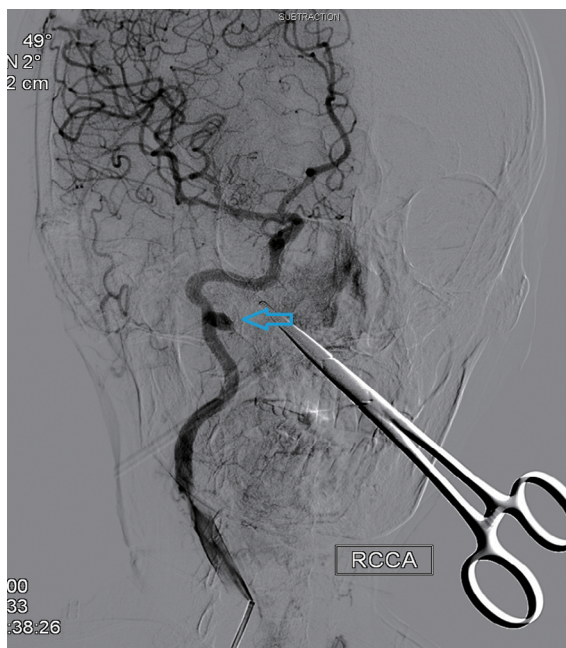
**Figure 2** Post-embolization internal maxillary artery angiograms revealing total occlusion of the artery (indicated by the arrow).

Cycles of chemotherapy	Trismus before the incidence of bleeding	Hypertension	Diabetic	Use of TCM	Nasopharynx irrigation	Use of brachytherapy	Surgical intervention
None	Yes	Yes	No	No	None	No	No
4	Yes	No	Yes	No	KDI	No	No
4	Yes	No	No	No	None	No	No
2	Yes	No	Yes	No	KDI	No	No
5	Yes	Yes	No	No	ODI	No	No
4	Yes	Yes	No	No	ODI	No	No
6	Yes	No	Yes	No	None	No	No
6	Yes	No	No	No	ODI	No	No
6	Yes	Yes	Yes	No	None	No	No
None	No	No	No	No	None	No	No

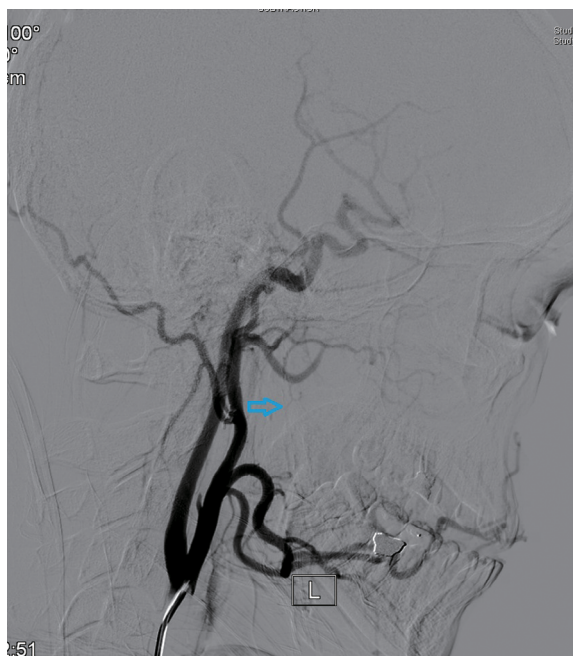




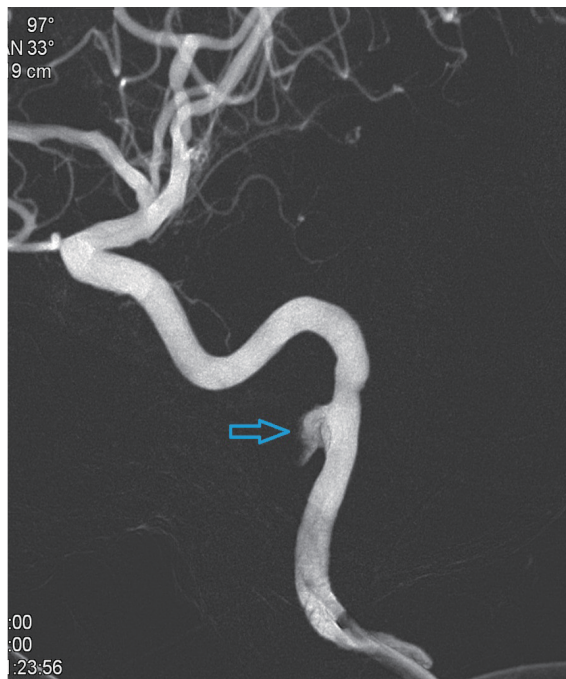**Figure 3** External carotid artery branch angiogram showing the bleeding sites on ascending pharyngeal artery (indicated by the arrow).  
**Note:** L= blood vessel on the left.



**Figure 5** Right lateral internal carotid artery angiogram showing radiation arteritis with pseudoaneurysm (indicated by the arrow).  
**Note:** RCCA=right common carotid artery.



**Figure 4** Post-embolization ascending pharyngeal artery angiogram revealing total occlusion of the artery (indicated by the arrow).  
**Note:** L= blood vessel on the left.



**Figure 6** Vascular imaging of the pseudoaneurysm after 3D reconstruction (indicated by the arrow).

patients showed no recurrence of hemorrhage. Of the four patients who died, 2 patients died of hemorrhagic shock, and 1 died of suffocation resulting from the blocking of the airway by blood clots. The fourth patient had blood clots blocking the airway after the hemorrhage but was saved by an emergency

tracheotomy. The patient was then sent to the interventional theater for emergency digital subtraction angiography embolization and transferred to the intensive care unit for postoperative treatment. The patient subsequently died due to systemic multiple organ failure. The clinical stages of all

four deaths were relatively late, with one in stage III and the other three in stage IV.

## Discussion

While radical radiotherapy represents the primary and most effective approach to treat NPC, the adverse effect of radiation on the adjacent healthy tissues remains to be resolved. Nasopharyngeal bleeding can be caused by tumor ulceration, necrosis, shedding, or mucosal hyperemia during radiotherapy.<sup>8</sup> In the present study, 17 cases of nasopharyngeal hemorrhage after radiation treatment for NPC were collectively reviewed, and the rescue and management strategies were discussed.

Multiple physico-pathological factors contribute to nasopharyngeal hemorrhage. Patients of older age, with advanced disease, or who receive higher irradiation doses are more likely to develop nasopharyngeal bleeding after radiotherapy.<sup>9</sup> Among the 17 patients recruited in this study, only two had stage II NPC, whereas 5 and 10 patients had stage III and IV disease, respectively. Nasopharyngeal hemorrhage is also associated with repeated radiotherapy, which is the major treatment for recurrent NPC.<sup>10</sup> Among the complications of radiotherapy for NPC, nasopharyngeal hemorrhage was reported to account for 77.8%.<sup>11</sup> Spreading more extensively in the skull base than the primary tumor, recurrent NPC requires an increased irradiation area and dose, which cause more damage to the surrounding tissues and increase the chance of nasopharyngeal hemorrhage. Consistently, in this study, seven patients suffered from recurrent NPC and underwent a second course of radiotherapy. In addition, fibrosis of the nasopharyngeal-cranial base tissue after radiotherapy increases the brittleness of blood vessels and hampers tissue repair, triggering long-term ulceration and necrosis.<sup>12</sup> Patients with NPC may have nasal and nasopharyngeal mucosal atrophy after radiotherapy, resulting in reduced mucus production and dryness of the mucous membranes. Furthermore, radiotherapy destroys the motor function of the nasal and nasopharyngeal cilia and weakens the self-cleaning of the nasal cavity and nasopharynx. This increases the occurrence of radiotherapy-induced rhinosinusitis and retention of the nasopharyngeal secretions, leading to infections and inflammation, which are associated with damage to the nasopharynx.<sup>13</sup> Extensive tissue necrosis and erosion of the skull base bone result in the exposure and loss of major blood vessels in the nasopharynx, thereby causing potentially fatal hemorrhage. Moreover, the blood vessels may not be effectively repaired and occluded after the

removal, by radiotherapy, of NPC cells that invade the blood vessels, causing spontaneous rupture and heavy bleeding.<sup>14</sup>

A shorter incubation period has been reported previously in patients of older age, with advanced disease, or repetitive irradiation.<sup>15</sup> Among the 17 patients included in this study, nasopharyngeal hemorrhage occurred between 6 months and 8 years after radiotherapy, suggesting that NPC patients treated by radiotherapy need to remain alert to nasal bleeding over a long period. This is of importance despite advances in radiotherapy technologies that have reduced the local residual rate of NPC and the complications of radiotherapy and improved the efficacy of radiotherapy.<sup>16</sup> Stereotactic radiosurgery and adaptive IMRT have been reported to increase the chance of nasopharyngeal hemorrhage, while both reduce the local residual rate of NPC and the occurrence of complications.<sup>17</sup>

The amount of hemorrhage after nasopharyngeal radiotherapy ranges from dozens to thousands of milliliters, and massive hemorrhage can be lethal within a short period. The likelihood of post-radiotherapy nasopharyngeal hemorrhage in patients with NPC can be assessed by the rate and frequency of symptomatic bleeding and the CT imaging results, which indicate the extent of damage to the nasopharynx and skull base. Patients with frequent or increased symptomatic nasal or oral bleeding, or CT images showing nasopharynx–skull base damage involving the adjacent blood vessels, require close observation and easy accessibility to rescue equipment. In the management of nasopharyngeal hemorrhage, maintaining upper airway patency is critical. Mucus suction, endotracheal intubation, and tracheotomy are approaches of choice depending on the upper airway patency. Once the bleeding sites are identified, anterior and posterior nostril packing, endoscopic nasopharynx electrocoagulation, and digital subtraction angiography embolization can be performed to stop the nasopharyngeal bleeding.

In summary, post-radiotherapy nasopharyngeal hemorrhage is often caused by erosion of the internal carotid artery and maxillary artery. Anterior and posterior nostril packing, endoscopic nasopharynx electrocoagulation, and digital subtraction angiography embolization are effective approaches for managing nasopharyngeal hemorrhage.

## Acknowledgment

This study was supported by the Natural Science Foundation of Hainan Province, China (No. 818MS130). The authors thank all the patients and the research staff for their contributions to this project.

## Disclosure

The authors report no conflicts of interest in this work.

## References

- Zhang S, Zhou L, Huang X, Lin S. A retrospective study of concurrent chemoradiotherapy plus S-1 adjuvant chemotherapy on curative effect for treatment of patients with N3 stage nasopharyngeal carcinoma. *Cancer Manag Res*. 2018;10:1705–1711.
- Zhang S, Lin S, Hu L. Lobaplatin combined with docetaxel neo-adjuvant chemotherapy followed by concurrent lobaplatin with intensity-modulated radiotherapy increases the survival of patients with high-risk lymph node positive nasopharyngeal carcinoma. *J BUON*. 2016;21(1):161–167.
- Kane MF, Loda M, Gaida GM, et al. Methylation of the hMLH1 promoter correlates with lack of expression of hMLH1 in sporadic colon tumors and mismatch repair-defective human tumor cell lines. *Cancer Res*. 1997;57(5):808.
- Cheng KM, Chan CM, Cheung YL, et al. Endovascular treatment of radiation-induced petrous internal carotid artery aneurysm presenting with acute haemorrhage. A report of two cases. *Acta Neurochir*. 2001;143(4):351–356.
- Cheng K-Y, Lee K-W, Chiang F-Y, Ho K-Y, Kuo W-R. Rupture of radiation-induced internal carotid artery pseudoaneurysm in a patient with nasopharyngeal carcinoma—spontaneous occlusion of carotid artery due to long-term embolizing performance. *Head Neck*. 2008;30(8):1132–1135.
- Chen H-Y, Ma X-M, Bai Y-R. Repeated massive epistaxis after re-irradiation in recurrent nasopharyngeal carcinoma. *Contemp Oncol*. 2014;18(5):371–376.
- Agulnik M, Epstein JB. Nasopharyngeal carcinoma: current management, future directions and dental implications. *Oral Oncol*. 2008;44(7):617–627.
- Mok JS, Marshall JN, Chan M, van Hasselt CA. Percutaneous embolization to control intractable epistaxis in nasopharyngeal carcinoma. *Head Neck*. 21(3):211–216.
- Wang CC. Re-irradiation of recurrent nasopharyngeal carcinoma—treatment techniques and results. *Int J Radiat Oncol Biol Phys*. 1987;13(7):953–956.
- Han F, Zhao C, Huang S-M, et al. Long-term outcomes and prognostic factors of re-irradiation for locally recurrent nasopharyngeal carcinoma using intensity-modulated radiotherapy. *Clin Oncol*. 2012;24(8):569–576.
- Tokuuye K, Akine Y, Sumi M, et al. Reirradiation of brain and skull base tumors with fractionated stereotactic radiotherapy. *Int J Radiat Oncol Biol Phys*. 1998;40(5):1151–1155.
- Kodani N, Yamazaki H, Tsubokura T, et al. Stereotactic body radiation therapy for head and neck tumor: disease control and morbidity outcomes. *J Radiat Res*. 2011;52(1):24–31.
- Qiu S, Lu J, Zheng W, et al. Advantages of intensity modulated radiotherapy in recurrent T1-2 nasopharyngeal carcinoma: a retrospective study. *BMC Cancer*. 2014;14(1):797.
- Wong GKC, Chan KK, Yu SCH, Tsang RKY, Poon WS. Treatment of profuse epistaxis in patients irradiated for nasopharyngeal carcinoma. *ANZ J Surg*. 2007;77(4):270–274.
- Elden L, Montanera W, Terbrugge K, Willinsky R, Lasjaunias P, Charles D. Angiographic embolization for the treatment of epistaxis: a review of 108 cases. *Otolaryngol Head Neck Surg*. 1994;111(1):44–50.
- Low YM, Goh YH. Endovascular treatment of epistaxis in patients irradiated for nasopharyngeal carcinoma. *Clin Otolaryngol Allied Sci*. 2003;28(3):244–247.
- Dhanachai M, Kraiphikul P, Dangprasert S, et al. Fractionated stereotactic radiotherapy in residual or recurrent nasopharyngeal carcinoma. *Acta Oncol*. 2007;46(6):828–833.

### Cancer Management and Research

### Publish your work in this journal

Cancer Management and Research is an international, peer-reviewed open access journal focusing on cancer research and the optimal use of preventative and integrated treatment interventions to achieve improved outcomes, enhanced survival and quality of life for the cancer patient. The manuscript management system is completely online and includes

a very quick and fair peer-review system, which is all easy to use. Visit <http://www.dovepress.com/testimonials.php> to read real quotes from published authors.

Submit your manuscript here: <https://www.dovepress.com/cancer-management-and-research-journal>

Dovepress