

Autologous tenon plug and patch in phacoburn

Hana A Mansour,¹ Ahmad M Mansour^{1,2}

¹Ophthalmology, American University of Beirut Faculty of Medicine, Beirut, Lebanon
²Ophthalmology, Rafic Hariri University Hospital, Lebanon

Correspondence to
 Professor Ahmad M Mansour;
 ammansourmd@gmail.com

Accepted 30 December 2020

SUMMARY

This 75-year-old woman had phacomorphic angle closure, dense nuclear sclerosis, deep set eye, miotic pupil and tight corneal wound during phacoemulsification. Phacoemulsification wound burn was noted at the end of surgery. Tenon was harvested from the inferior conjunctiva, placed over the gape and anchored by two radial corneoscleral 10–0 nylon. Ten days later, anterior optical coherence tomography showed good wound apposition and sutures were removed with visual recovery to 20/25 (6/7.5) without astigmatism.

BACKGROUND

Corneal burn during phacoemulsification results from inadequate fluid flow and tight wound. This is a cataract surgeon nightmare because of wound gape. Most surgeons perform primary suturing of the wound resulting in extreme astigmatism and much delayed visual rehabilitation. Other modalities add expenses such as donor cornea and are not available on the spot in most centres. We present a simple inexpensive readily available surgical solution with fast postoperative recovery of vision.

CASE PRESENTATION

This 75-year-old Caucasian woman had phacomorphic angle closure and moderate severe nuclear sclerosis with best spectacle corrected visual acuity of 6/30 (20/100) in the left eye. Besides a shallow anterior chamber, the patient had very deep-set eye, small palpebral fissure and miotic pupil (maximal dilation to 3.5 mm from intake of alpha 1 blocker). Because of shallow anterior chamber, it was not possible to use pupillary tools (iris hooks would hit the lid margin while pupillary dilation devices would damage the corneal endothelium). Under topical anaesthesia, a limbal 2 mm long and 2.6 mm wide corneal tunnel was done with a crescent knife. Hyaluronic acid 2.5% (Microvisc phaco, Bohus BioTech AB, Strömstad, Sweden) was injected to deepen the shallow anterior chamber as well stretch the miotic pupil. Circular anterior capsulorrhexis was performed with a cystotome and phacoemulsification was initiated in order to create a space for subsequent hydrodissection of the lens nucleus. With the phacoemulsification probe placed over the middle nucleus surface and after allowing aspiration around that area, 1 s of phacoemulsification sculpt mode at low settings was done and was immediately stopped after the appearance of lens milk. After aspiration of viscoelastic material, phacoemulsification was slow using low settings to avoid pupillary touch. Following insertion of the intraocular lens implant, there was a gaping limbal wound with leakage of aqueous.

TREATMENT

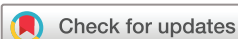Subconjunctival lidocaine was injected at 6 o'clock and after one conjunctival snip 1 cm from the limbus, 3 mm of Tenon was harvested and placed over the gape and anchored by two radial corneoscleral 10–0 nylon. A 14 mm soft contact lens (Oasys, Acuvue, Johnson and Johnson, New Brunswick, New Jersey, USA) was placed with great difficulty due to the small space (short palpebral fissure).

OUTCOME AND FOLLOW-UP

Eight hours later, objective refraction revealed 5 diopters of astigmatism and 6/30 (20/100) uncorrected vision. Anterior optical coherence tomography (OCT) revealed good apposition of the graft (figure 1). Forty-eight hour postoperatively, uncorrected vision was 6/9 (20/30). Ten days later, one of the two nylon sutures was removed along with the contact lens. Anterior OCT scan along the removed suture plane complete apposition of the graft (figure 1), and hence the second suture was also removed. Since uncorrected visual acuity stabilised at the 6/7.5 (20/25) level till the 6-month follow-up.

DISCUSSION

Common approaches for thermal phacoemulsification injuries^{1–10} have included tight suturing of the corneoscleral,⁴ a fornix-based conjunctival flap,¹ amniotic membrane transplantation, scleral patch graft, lamellar corneal graft² or contact lens application. Special suturing techniques are needed to appose the anterior lips to the posterior lips of the wound such as the use of temporary 8–0 nylon traction sutures followed by multiple 10–0 nylon sutures. This latter technique seems to be the most common approach and the sutures are gradually cut over a period of 1 month. With this approach, Sugar and Schertzer⁴ encountered very high astigmatism reaching 15 diopters. Even astigmatism not attributable to the tight sutures, but instead to tissue shrinkage, tends to wane with time needing more than 6 months to dissipate (Mattress sutures in phacoburn, Ahmad M Mansour, unpublished data). Other approaches require the presence of donor tissue adding expenses and time lost in the operating room. Haldar and Saraff¹ used a fornix-based conjunctival flap to adequately cover the wound, followed by a single horizontal mattress suture with 10–0 monofilament nylon to appose the wound. This technique appears fit for small to moderate gape. A rectangular fornix based conjunctival flap would not plug a large gape perfectly with one suture like with a Tenon patch, and there is the possibility of a filtering bleb formation with the conjunctival flap. By anterior OCT, internal architecture of the wound is well noted and shows a



© BMJ Publishing Group Limited 2021. No commercial re-use. See rights and permissions. Published by BMJ.

To cite: Mansour HA, Mansour AM. *BMJ Case Rep* 2021;**14**:e238970. doi:10.1136/bcr-2020-238970

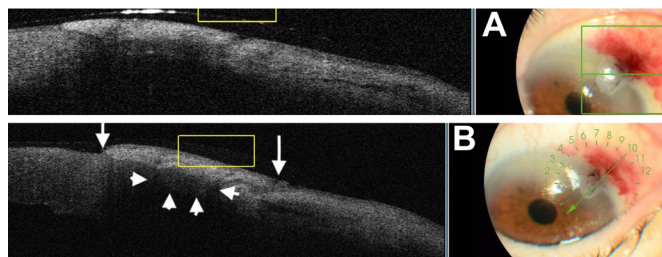


Figure 1 Anterior OCT scan through the phacoemulsification incision. (A) Ten hours after surgery, the wound gape is well sealed by the Tenon graft and 2 radial 10-0 nylon sutures. (B) Ten days postoperatively, one suture is removed and the scan through the removed suture shows no wound gape. Then the second suture is removed and repeat OCT scan through the second removed suture showed a similar finding. Arrows delineate the extent of the Tenon graft. Arrowheads point to the perfect plugging of the wound gape by the Tenon graft.

good seal of the gape by the Tenon ‘plug’ (figure 2). Also, under OCT guidance, the two sutures were removed one at a time with resolution of the astigmatism.

The known risk factors^{3–10} for a phacoburn include shallow anterior chamber, tight wound with wound compression of the irrigating sleeve, sleeve kinking by handpiece movements (with deep set eye), kinked tubing, low irrigation setting, use of thicker viscoelastic material, dense nuclear sclerosis and high ultrasound power. In our case, the eye was small with deep set orbit and we

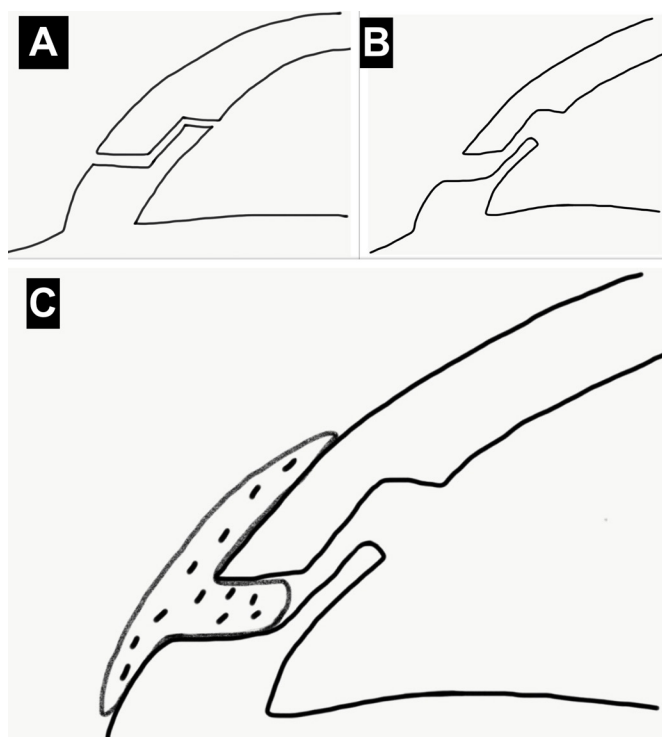


Figure 2 Schematic diagram depicting the role of tenon patch in phacoburn (art work by HAM). (A) Normal architecture of a three-plane phacoemulsification incision. (B) Gaping wound from phacoburn. (C) Ten days postoperatively, the wound appears self-sealed from good apposition of the Tenon plug after suture removal and resolution of induced astigmatism.

used 2.5% hyaluronic acid to deepen a shallow anterior chamber as well as widen a miotic pupil. In our case not only the initial emulsification was the trigger, the continuous use of ultrasound in this dense cataract in a tight wound added insult to injury and we were a little surprised to find a wound gape at the end of the case. The appearance of lens milk is a warning sign to immediately stop use of ultrasound power. Checking the tubing for clogging by nucleus piece, increase irrigating and aspiration flow, widening the corneal incision, decreasing the ultrasound power and continuous rinsing of the corneal wound by BSS can lessen the chance for a phacoburn.

Treatment of phacoburn with a tenon plug¹¹ allows good sealing with minimal astigmatism and with quick removal of the nylon sutures. Tenon’s capsule is easily available and is composed of fibroblasts that accelerate wound healing yielding a robust scar without extra cost and is not limited by the availability of graft tissue.

Learning points

- ▶ Phacoburns occur in the setting of shallow anterior chamber, tight cataract wound, kinked tubing, low irrigation, thicker viscoelastic material, dense nuclear sclerosis and high ultrasound power.
- ▶ Treatment of phacoburn with a tenon plug allows good sealing with minimal astigmatism and with quick removal of the nylon sutures.
- ▶ Tenon’s capsule is easily available and is composed of fibroblasts that accelerate wound healing yielding a robust scar without extra cost.

Contributors Conception and design, acquisition of data or analysis and interpretation of data; drafting the article or revising it critically for important intellectual content: HAM, AMM. Final approval of the version published; agreement to be accountable for the article and to ensure that all questions regarding the accuracy or integrity of the article are investigated and resolved: HAM, AMM.

Funding The authors have not declared a specific grant for this research from any funding agency in the public, commercial or not-for-profit sectors.

Competing interests None declared.

Patient consent for publication Obtained.

Provenance and peer review Not commissioned; externally peer reviewed.

REFERENCES

- 1 Haldar K, Saraff R. Closure technique for leaking wound resulting from thermal injury during phacoemulsification. *J Cataract Refract Surg* 2014;40:1412–4.
- 2 Khodabakhsh AJ, Zaidman G, Tabin G. Corneal surgery for severe phacoemulsification burns. *Ophthalmology* 2004;111:332–4.
- 3 Majid MA, Sharma MK, Harding SP. Corneoscleral burn during phacoemulsification surgery. *J Cataract Refract Surg* 1998;24:1413–5.
- 4 Sugar A, Schertzer RM. Clinical course of phacoemulsification wound burns. *J Cataract Refract Surg* 1999;25:688–92.
- 5 Ernest P, Rhem M, McDermott M, et al. Phacoemulsification conditions resulting in thermal wound injury. *J Cataract Refract Surg* 2001;27:1829–39.
- 6 Sippel KC, Pineda R. Phacoemulsification and thermal wound injury. *Semin Ophthalmol* 2002;17:102–9.
- 7 Roncin S. [Case report of a severe corneoscleral burn caused by the phacoemulsification probe]. *J Fr Ophthalmol* 2002;25:627–31.
- 8 Sorensen T, Chan CC, Bradley M, et al. Ultrasound-induced corneal incision contracture survey in the United States and Canada. *J Cataract Refract Surg* 2012;38:227–33.
- 9 Davis PL. Phaco transducers: basic principles and corneal thermal injury. *Eur J Implant Refract Surg* 1993;5:109–12.
- 10 Bissen-Miyajima H, Shimamura S, Tsubota K. Thermal effect on corneal incisions with different phacoemulsification ultrasonic tips. *J Cataract Refract Surg* 1999;25:60–4.
- 11 Korah S, Selvin SST, Pradhan ZS, et al. Tenons patch graft in the management of large corneal perforations. *Cornea* 2016;35:696–9.

Copyright 2021 BMJ Publishing Group. All rights reserved. For permission to reuse any of this content visit <https://www.bmj.com/company/products-services/rights-and-licensing/permissions/>
BMJ Case Report Fellows may re-use this article for personal use and teaching without any further permission.

Become a Fellow of BMJ Case Reports today and you can:

- ▶ Submit as many cases as you like
- ▶ Enjoy fast sympathetic peer review and rapid publication of accepted articles
- ▶ Access all the published articles
- ▶ Re-use any of the published material for personal use and teaching without further permission

Customer Service

If you have any further queries about your subscription, please contact our customer services team on +44 (0) 207111 1105 or via email at support@bmj.com.

Visit casereports.bmj.com for more articles like this and to become a Fellow