

Comprehensive analysis of clinical utility of three-dimensional ultrasound for benign and malignant breast masses

Jun Fu¹
Yanyan Li²
Na Li¹
Zhanzhan Li¹

¹Department of Oncology,
²Department of Nursing, Xiangya
Hospital, Central South University,
Changsha, Hunan Province 410008,
China

Background: Three-dimensional (3-D) ultrasound is commonly used for screening breast cancer; however, the diagnostic accuracy of this method is unknown. Here, we performed a systematic search on the literature to assess the clinical utility of 3-D ultrasound in benign and malignant breast masses.

Materials and methods: We conducted searches in several online databases covering all publications prior to August 15, 2017. The bivariate random effects model was used to assess the overall sensitivity, specificity, positive likelihood ratio (PLR), negative likelihood ratio (NLR), diagnostic odds ratio (DOR), and summary area under receiver operating curve (AUC) with their corresponding 95% CI.

Results: The overall sensitivity of 3-D ultrasound for diagnosing benign and malignant breast masses was 89% (95% CI, 83%–93%) and the specificity was 88% (95% CI, 83%–92%) with high heterogeneity ($I^2=81.9$; 95% CI, 74.4–89.3, $P<0.001$). Other parameters used to assess efficacy included PLR (5.57; 95% CI, 3.73–8.31), NLR (0.18; 95% CI, 0.11–0.28), and DOR (31.33; 95% CI, 15.19–64.61). The use of a Fagan diagram with a pretest probability of 20% yields a post-test probability of 65% with a PLR of 7. True post-test probability was calculated at 3%, with an NLR of 0.13. The summary receiver operating characteristic curve was 0.94 (95% CI, 0.92–0.96), with no evidence of publication bias.

Conclusion: Three-dimensional ultrasound offers high sensitivity and specificity, with a high AUC, indicating a strong diagnostic value for detecting benign and malignant breast masses. Three-dimensional ultrasound may therefore represent an excellent option for secondary analysis of unclear breast lesions.

Keywords: breast cancer, diagnostic, meta-analysis, three-dimensional ultrasound

Introduction

Cancer has long been an important public health issue, resulting in significant physical and emotional damage to those affected. Since the early 1970s, breast cancer has been the most frequently diagnosed form of cancer in women, with incidence gradually increasing by 0.2%–0.8% each year, and the onset age tends to be more younger.¹ Similar trends in breast cancer incidence are also seen in China, highlighting the importance of this issue in public health and the need for greater public attention.²

Preliminary screening for breast cancer typically involves imaging of susceptible breast tissue by methods such as computed tomography (CT), mammography X-ray examination, MRI, electrical capacitance tomography, and Doppler ultrasound with mammography X-ray examination. Despite the widespread use of Doppler ultrasound

Correspondence: Zhanzhan Li
Department of Oncology, Xiangya
Hospital, Central South University,
No. 87, Xiangya Road, Kaifu District,
Changsha, Hunan Province 410008, China
Tel/fax +86 731 8975 3332
Email liche4006@126.com

methods, in recent years, MRI, CT, and other imaging technologies have grown increasingly common; these methods offer significant advantages over traditional methods, although widespread adoption remains limited due to their higher cost.³

With the continued development and greater availability of color Doppler and contrast-enhanced ultrasound technologies, ultrasound has become the preferred method for breast tissue examination, suitable for differential diagnosis of physical properties of standard and cystic mass lesions. Three-dimensional (3-D) ultrasound works by reconstructing images from standard two-dimensional ultrasound. Besides providing an ultrasonic profile and cross-sectional information, the acquired coronal and stereoscopic images allow for detection and diagnosis of mammary lesions.^{4,5} The widespread adoption of these tools, combined with a greater understanding of enhancement patterns typical of breast lesions, has led to significant improvements in overall detection rates, including that of smaller breast lesions.⁶ A small number of studies have sought to assess the diagnostic abilities of 3-D ultrasound, as the overall sensitivity and specificity of this method remain unclear.^{7,8} Here, we conducted a comprehensive analysis of the public literature to evaluate the clinical utility of 3-D ultrasound for the diagnosis of benign and malignant breast masses among Chinese women.

Materials and methods

Search strategy

All relevant publications deposited in PubMed, Web of Science, Wanfang, and China National Knowledge Infrastructure prior to August 15, 2017, were included in this study. Relevant studies were identified using the following search terms: (breast cancer OR breast neoplasms OR breast carcinoma OR breast tumor OR breast) AND (ultrasound OR three-dimensional ultrasound OR three dimensions hypersound OR 3-D sonography) AND (sensitivity OR specificity OR diagnostic OR receiver operating curve OR ROC) in the title, abstract, or MeSH. Additional studies were identified by manually screening the reference lists of relevant reviews. Although we placed no restriction on language when performing the search, literature screening and full-text scanning were limited to English or Chinese. Two investigators independently performed the search; disagreements over inclusion were resolved by a third investigator.

Criteria for inclusion and exclusion

For a study to be included in this analysis, each of the following criteria had to be met: 1) the study evaluated

the diagnostic accuracy of 3-D ultrasound for benign and malignant breast masses; 2) all patients were confirmed by a gold standard (pathological biopsy); 3) the study provided sufficient data for calculating the sensitivity and specificity including true positive (TP), false positive (FP), false negative (FN), and true negative (TN); and finally 4) the study was conducted on human subjects. Exclusion criteria included 1) experimentation studies, comments, reviews, letters, and conferences abstracts; and 2) studies with very small sample sizes ($N < 30$). In cases of continuing or duplicate studies, only the most recent data were used.

Data extraction and quality assessment

Data extraction was performed by two independent investigators using a standard Excel sheet. For each study, the following information was extracted: the first author of the study, year of publication, type of examination equipment, frequency, number of lesions, mean age, sample size, four-folds (TP, FP, FN, TN), sensitivity, and specificity. A third investigator cross-referenced extraction information and revised the errors.

We used the quality assessment of diagnostic accuracy studies 2 (QUADAS-2) to assess the quality of included studies, based on four basic criteria: patient selection, index test, reference standard, and flow and timing.⁹ Each domain item is further broken down into several subitems designated as low risk, high risk, or unclear risk according to the study.

Statistical analyses

The threshold effect is one of the primary causes of heterogeneity within studies.¹⁰ For the current study, we evaluated the threshold effect using Spearman's coefficient. In this study, the threshold effect does not exist ($r = -0.358$, $P = 0.059$). Heterogeneity was assessed using chi-squared and I^2 statistical analyses. Outcomes significant at a level of $P < 0.05$ or $I^2 > 50\%$ were regarded as indicative of heterogeneity.¹¹ The bivariate random effects model was used to assess the overall sensitivity, specificity, positive likelihood ratio (PLR), negative likelihood ratio (NLR), diagnostic odds ratio (DOR), and summary area under receiver operating curve (AUC) with their respective 95% CI.^{12,13} Diagnostic ability was assessed via AUC. Here, an AUC=1 is indicative of a perfect distinguishing ability, while an AUC<0.5 signifies a poor diagnostic test. We used a Fagan diagram to evaluate pre- and post-test probabilities and Deek's test for publication bias.¹⁴ Sensitivity analyses were also conducted using a standard leave-one-out method. All analyses were calculated using Stata 14.0 version

(StataCorp LP, College Station, TX, USA), with P -values <0.05 considered statistically significant.

Results

Study selection

Our initial screening revealed 365 potential studies, from which 78 records were removed due to duplicated information. An additional 212 were excluded based on a manual screening of titles and abstracts, with most exclusions due to irrelevant topics and review articles. The remaining 75 articles were further screened through a reading of the full text. Twelve articles with unrelated diagnostic values, eight articles with insufficient data, eight studies with duplicates data, 17 case reports, and 11 reviews, comments, and letters were excluded. After all exclusions had been made, we were left with 19 studies that met all of our quantitative and qualitative inclusion criteria.^{7,8,15–31} A flowchart outlining this screening process is shown in Figure 1.

General characteristics of studies and quality assessment

All included studies were published between 2007 and 2014. The mean age ranged from 30 to 56 years. There was a total of 2,165 patients; sample sizes ranged from 51 to 242 patients. Most studies used a GE Voluson ultrasound for examination, run at 5–12 MHz. The total number of lesions detected across all studies was 2,214. Sensitivity scores ranged from 62% to 99%, with a specificity of 71% to 99%. A summary of the patient cohorts included in this study is shown in Table 1.

Pooled results

Nineteen studies reported sensitivity and specificity data. The heterogeneity within studies was high ($I^2=85.0$; 95% CI, 79.2–90.8, $P<0.001$). The overall sensitivity and diagnostic accuracy of 3-D ultrasound for breast cancer was 89% (95% CI, 83%–93%; Figure 2). Overall specificity was 88% (95% CI, 83%–92%; Figure 3) with high heterogeneity ($I^2=81.9$;

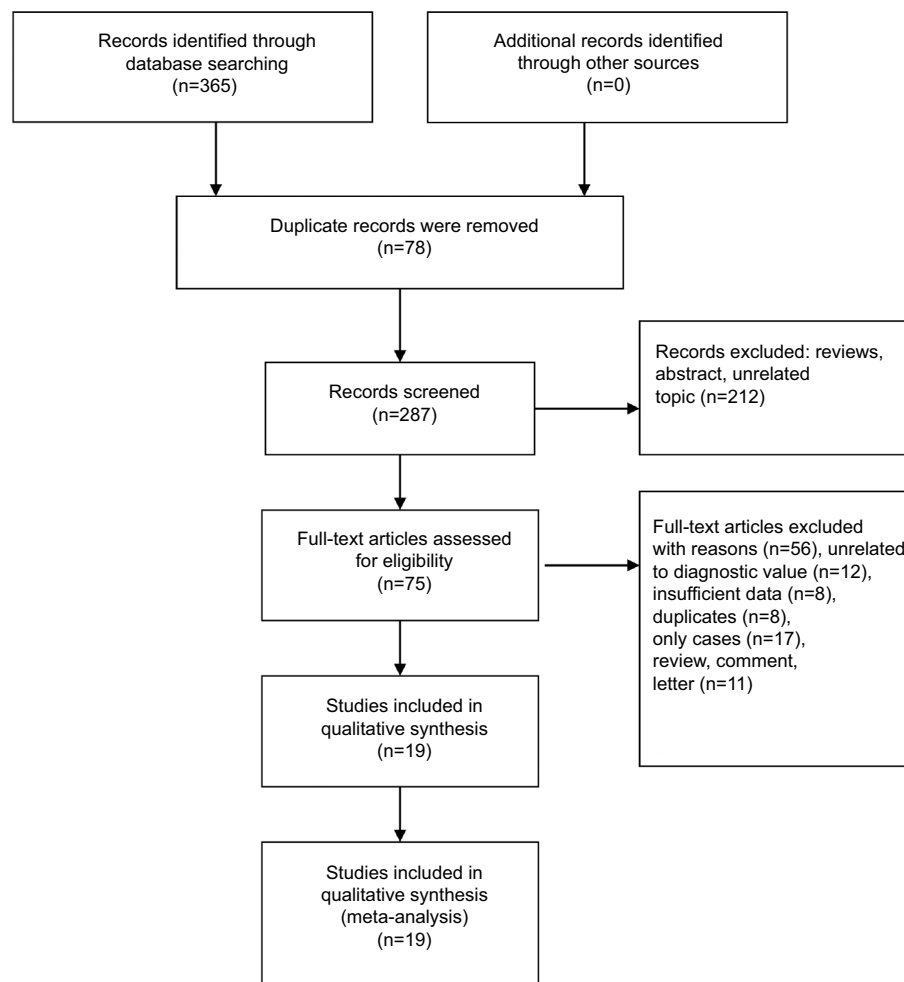
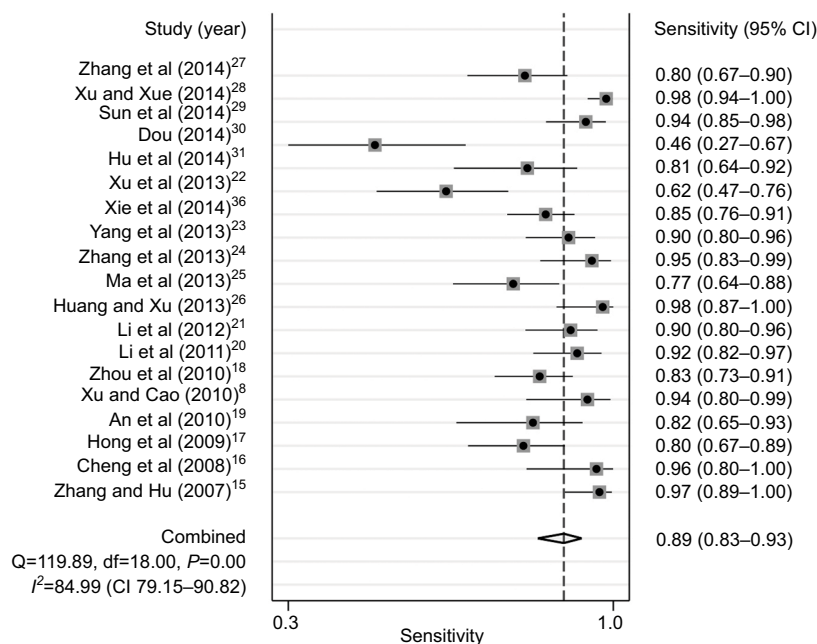


Figure 1 Flow diagram of studies selection.

Table 1 General characteristics of studies included in the meta-analysis

Author	Year	Machine	MHz	Lesions (n)	Mean age	Sample size (case/control)	TP	FP	FN	TN	Sensitivity (%)	Specificity (%)
Zhang and Hu ¹⁵	2007	GE Voluson E8	6–16	130	40	107	61	1	2	66	97	99
Cheng et al ¹⁶	2008	Accuvix XQ	10	51	46	51	25	1	1	24	96	96
Hong et al ¹⁷	2009	GE Voluson	8–12	129	49	129	47	6	12	64	80	91
An et al ¹⁹	2010	Accuvix	8–15	83	45	83	27	12	6	38	82	76
Xu and Cao ⁸	2010	LOGIQ9	5–12	60	–	60	32	4	2	22	94	85
Zhou et al ¹⁸	2010	GE Voluson	5–12	160	48	160	65	15	13	78	83	84
Li et al ²⁰	2011	Philips	5–13	142	46	142	56	10	5	71	92	88
Li et al ²¹	2012	LOGIQ9	–	152	49	126	56	17	6	73	90	81
Huang and Xu ²⁶	2013	GE Voluson	5–12	60	44	60	40	2	1	28	98	93
Ma et al ²⁵	2013	LOGIQ9	5–12	85	–	85	41	11	12	36	77	77
Zhang et al ²⁴	2013	GE Voluson	5–12	79	55	79	39	6	2	34	95	85
Yang et al ²³	2013	GE Voluson	5–12	112	56	112	62	16	7	40	90	71
Xie et al ³⁶	2014	GE Voluson	5–12	201	54	201	83	13	15	137	85	91
Xu et al ²²	2013	GE Voluson	5–12	66	56	66	28	3	17	21	62	88
Hu et al ³¹	2014	GE Voluson	5–12	107	40	107	29	18	7	73	81	80
Dou ³⁰	2014	Accuvix XQ	10	150	45	150	12	6	14	118	46	95
Sun et al ²⁹	2014	GE Voluson	5–12	115	39/46	115	60	5	4	46	94	90
Xu and Xue ²⁸	2014	GE Voluson	5–12	242	44	242	119	5	2	174	98	97
Zhang et al ²⁷	2014	GE Voluson	5–12	90	56	90	44	14	11	21	80	60

Abbreviations: FN, false negative; FP, false positive; TN, true negative; TP, true positive; –, not applicable.

**Figure 2** Forest plot of pooled sensitivity of three-dimensional ultrasound for breast cancer.

95% CI, 74.4–89.3, $P < 0.001$). Other parameters used to assess efficacy included PLR (5.57; 95% CI, 3.73–8.31), NLR (0.18; 95% CI, 0.11–0.28), and DOR (31.33; 95% CI, 15.19–64.61). The use of a Fagan diagram with a pretest probability of 20% yields a post-test probability of 65% with a PLR of 7 (Figure 5). True post-test probability was calculated at 3%, with an NLR of 0.13. The summary receiver operating characteristic

curve was 0.94 (95% CI, 0.92–0.96; Figure 4), indicative of the high diagnostic accuracy of 3-D ultrasound for breast cancer.

Sensitivity analyses and publication bias

To examine the stability of our pooled results, we also conducted sensitivity analyses using a standard leave-one-out method. As shown in Figure 6, the sensitivity ranged from

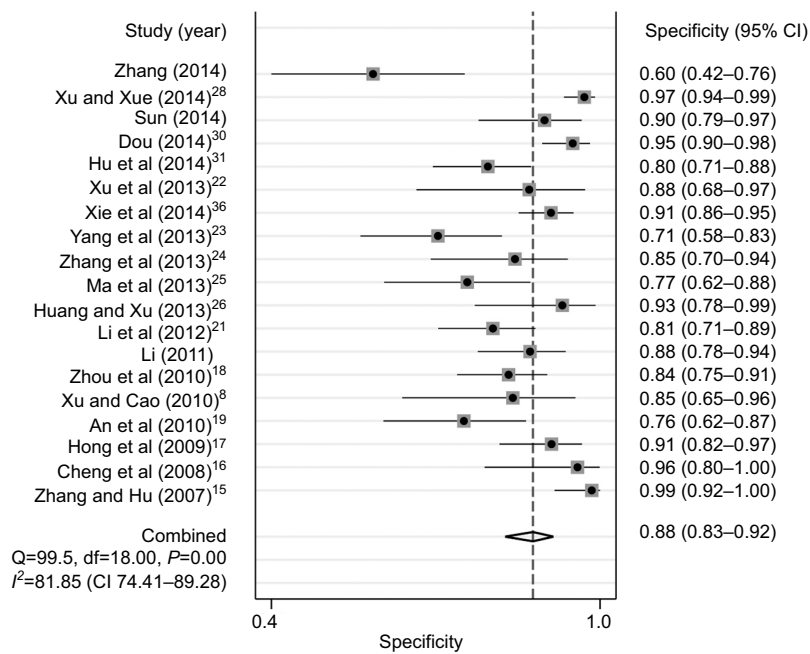


Figure 3 Forest plot of pooled specificity of three-dimensional ultrasound for breast cancer.

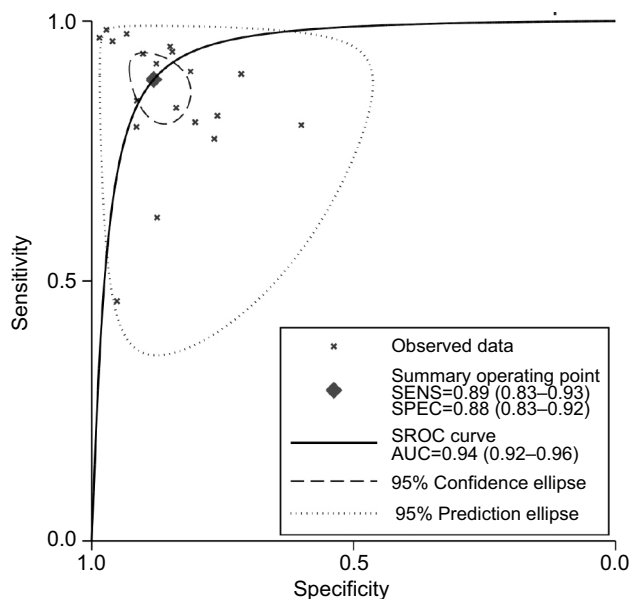


Figure 4 The symmetric receiver operating characteristic curve of three-dimensional ultrasound for breast cancer.

Note: Data and parentheses presented as (CI 95%).

~88% to 96%, with a specificity of 86% to 98%, indicative of high stability. Assessment of publication bias was performed using Deek's test, with no evidence of bias between studies ($t=0.290$; $P=0.781$; Figure 7).

Discussion

Our analyses revealed an overall sensitivity of 3-D ultrasound of 89%, specificity of 88%, and an AUC of 0.94. These

observations are indicative of the high diagnostic ability of 3-D ultrasound for both benign and malignant breast masses. Our pooled PLR was 31.33; thus, patients with malignant breast masses have a nearly 4.5-fold higher chance of a positive 3-D ultrasound compared with those without a benign breast mass. The NLR was 0.13, meaning the probability of a missed diagnosis was 13% if the 3-D ultrasound was negative. Current guidelines suggest a PLR > 10 and NLR < 0.1 as a baseline for high diagnostic ability.³² Our results were outside the threshold for NLR score; however, our results indicated that the predictive power of this method is quite stable, with a narrow CI.

Two-dimensional ultrasound remains the most common method for routine breast examination. Unlike 3-D approaches, two-dimensional ultrasound only produces slice images, meaning clinicians must on their own construct a series of 3-D images to fully visualize the area.³³ Such a limitation greatly increases the likelihood that some lesions will be missed, particularly in cases where highly skilled technicians are not available. Moreover, it is extremely difficult for clinicians to locate lesions observed in a previous examination, which serves as a significant disadvantage for long-term follow-up. In moving to 3-D ultrasound, doctors can pinpoint the exact location, size, and boundaries of a mass.³⁴ In addition, other images of the interface, such as breast coronal images, can be obtained by 3-D ultrasound, thereby improving the accuracy of the diagnosis.³⁵

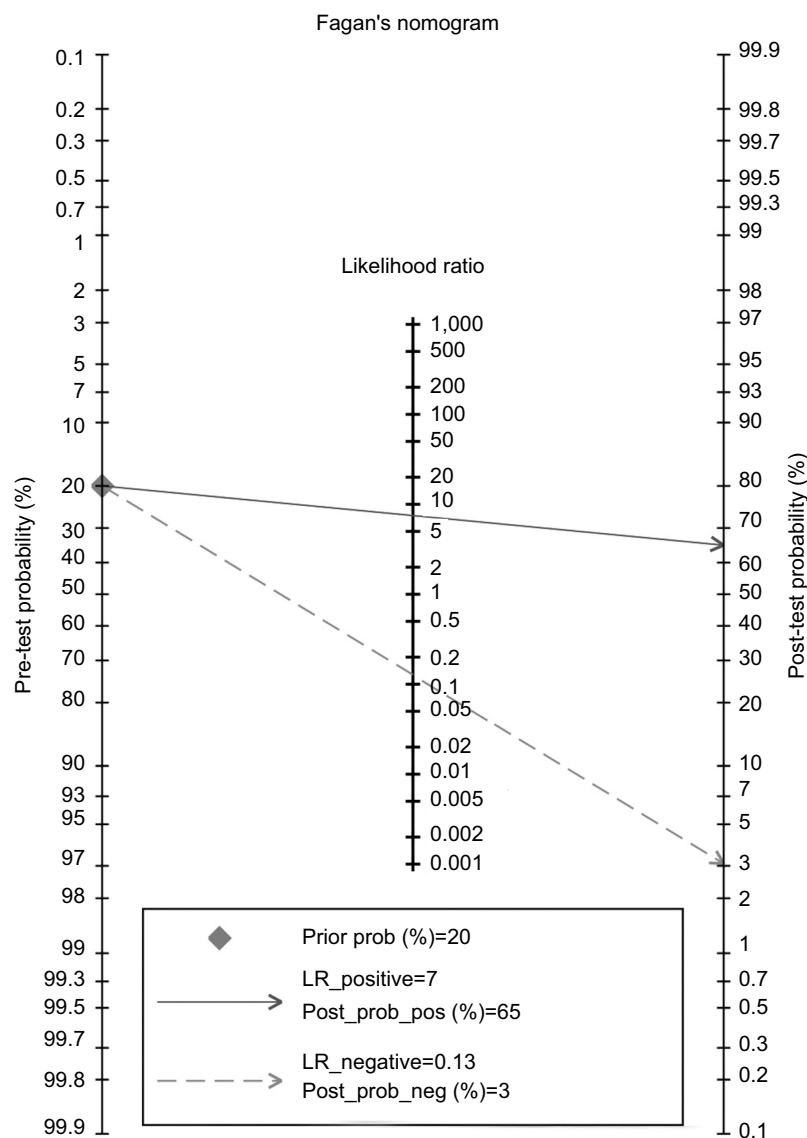


Figure 5 Fagan diagram evaluating the overall diagnostic value of three-dimensional ultrasound for breast cancer.
Abbreviations: pos, positive; neg, negative; prob, probability; LR, likelihood ratio.

The ability to evaluate the size, range, form, and malignancy of a breast lump is an important application of ultrasound.³⁶ Zhang et al found the sensitivity of 3-D ultrasound to be 95.8%, a significant improvement over traditional two-dimensional scan (89.6).²⁴ These 3-D scans also offer significantly better accuracy in terms of lesion locations, especially for the lesions found in the cavity of breast ducts.²¹ The molybdenum target remains the “gold standard” for lesional imaging, although the accuracy of this method is limited in dense breasts, giving ultrasound a clear advantage in these cases.³⁷ Such a consideration may be of particular importance in China, as the breasts of Chinese women are

typically smaller and denser than those of American and European women. Used together, the combination of 3-D ultrasound and a molybdenum target can be used to significantly improve patient diagnosis in the clinical setting. Previous studies reported that the 3-D images of breast cancer are characterized by unclear boundary, convergent feature, and abundant blood flow. The benign lesions in three-dimensional imaging were presented in the form of clear boundaries, regular morphology and the echogenicity was homogeneous and blood flow signal was not rich, and there was no clear boundary between lesions and adjacent tissues. No mass was found for this kind of lesions under the radiographs with

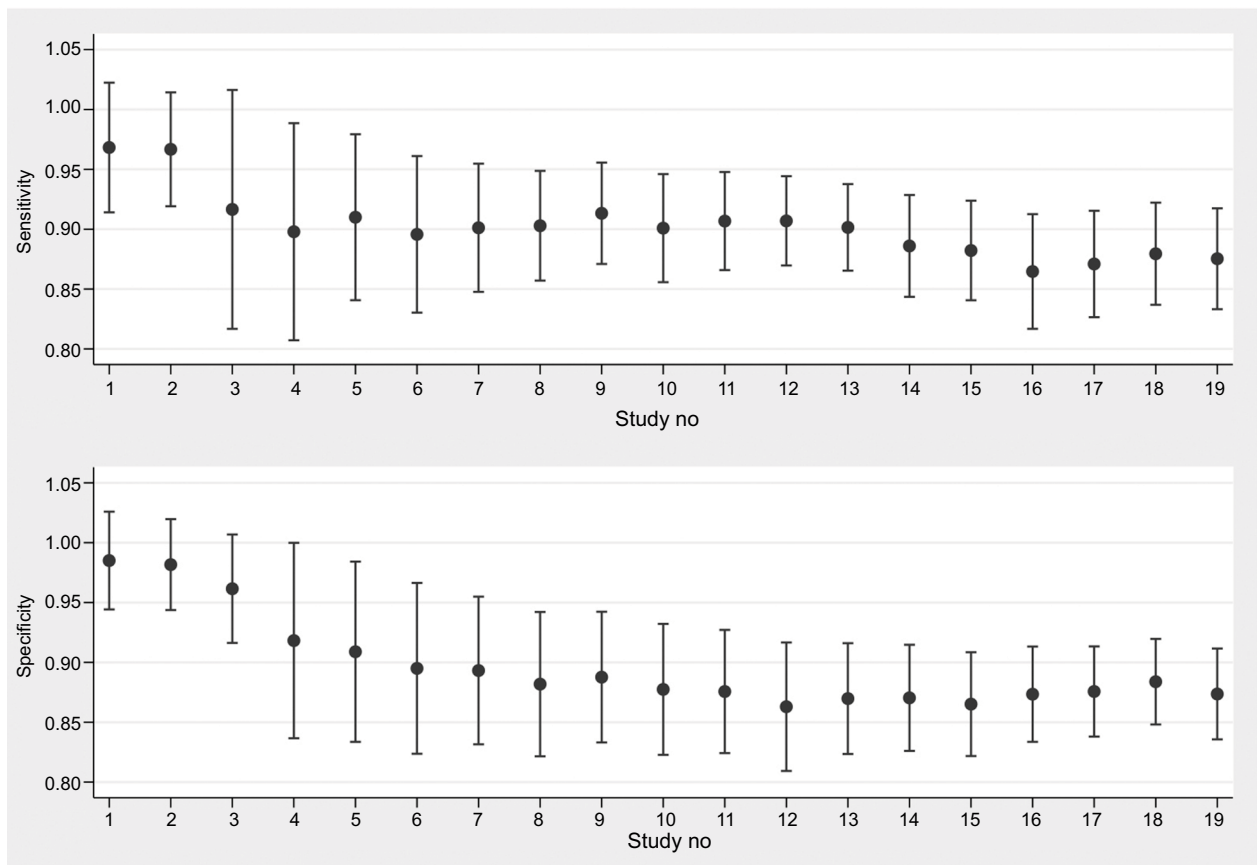


Figure 6 Sensitivity and pooled sensitivity and specificity.

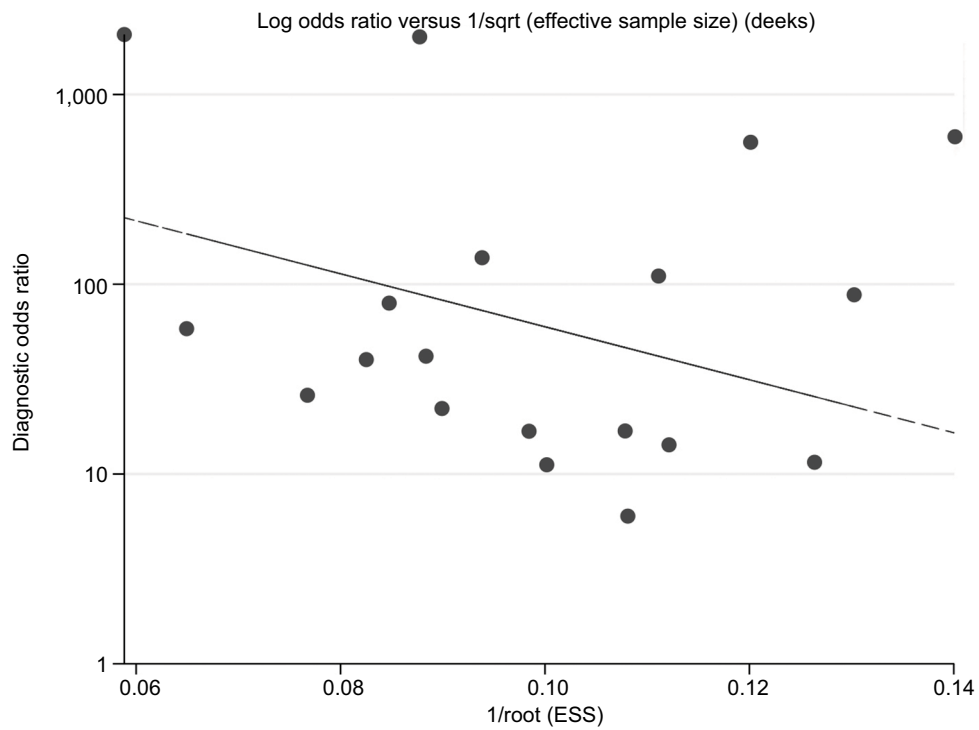


Figure 7 Deek's plot of publication bias.

Abbreviations: sqrt, square root; ESS, effective sample sizes.

molybdenum target. These characteristics can be helpful in differentiating malignant and benign lesions.

Our study had several limitations. First, all of the included studies consisted of patients with benign and malignant tumors, with some studies not providing clear descriptions regarding blinding methods, which may lower the study quality. Second, the diagnostic criteria for benign or malignant tumors differed between studies, with some studies treating specific signs as a benign diagnosis, thereby lowering the reported diagnostic efficiency of 3-D ultrasound. Third, studies were conducted using different examination machines with different frequency, which may underestimate or overestimate the diagnostic accuracy for breast cancer. Finally, patient cohorts differed across studies, which may confound study outcome. More studies will be necessary to fully evaluate the diagnostic value of 3-D ultrasound for benign and malignant breast masses.

Conclusion

Taken together, our results indicated that 3-D ultrasound has a high clinical value for diagnosing benign and malignant breast masses. The use of 3-D ultrasound therefore offers a simple and inexpensive method for diagnosing uncertain breast lesions. Early diagnosis and early treatment of secondary prevention of tumor are the key to improve the prognosis of breast cancer patients. The application value of 3-D ultrasound examination in mammary gland disease is certain, has simple, noninvasive, good repeatability, and is not affected by the density degree of mammary gland and examination position. The confirmation of benign or malignant breast masses assists the clinical decision.

Disclosure

The authors report no conflicts of interest in this work.

References

- National Cancer Institute [webpage on the Internet]. Breast cancer prevention (PDQ®)—patient version [updated August 16, 2018]. Available from: <https://www.cancer.gov/types/breast/patient/breast-prevention-pdq>. Accessed September 4, 2018.
- Fan L, Strasser-Weippl K, Jj L, et al. Breast cancer in China. *Lancet Oncol*. 2014;15(7):e279–e289.
- Wang L. Early diagnosis of breast cancer. *Sensors*. 2017;17(7):1572.
- Health Quality Ontario. Ultrasound as an adjunct to mammography for breast cancer screening: a health technology assessment. *Ont Health Technol Assess Ser*. 2016;16(15):1–71.
- Carlsen J, Ewertsen C, Sletting S, et al. Ultrasound elastography in breast cancer diagnosis. *Ultraschall Med*. 2015;36(6):550–565.
- Fischer T, Filimonow S, Hamm B, Slowinski T, Thomas A. Characterization of sonographically detected breast lesions using three-dimensional data sets. *Rofo*. 2006;178(12):1224–1234.
- Zhang GP, Yao LJ, Zhao Q, Gao JX, Re SL. Three-dimensional volume ultrasound in the diagnosis of breast masses. *J Med Postgraduates*. 2010;23(07):733–737.
- Xu YJ, Cao X. Comparison of two and three-dimensional ultrasound with X-ray mammography in diagnosis of breast masses. *Heilongjiang Med Pharm*. 2010;33(5):47–48.
- Whiting PF, Rutjes AW, Westwood ME, et al. QUADAS-2: a revised tool for the quality assessment of diagnostic accuracy studies. *Ann Intern Med*. 2011;155(8):529–536.
- Li Z, Zhou Q, Li Y, Fu J, Huang X, Shen L. Growth hormone replacement therapy reduces risk of cancer in adult with growth hormone deficiency: A meta-analysis. *Oncotarget*. 2016;7(49):81862–81869.
- Higgins JP, Thompson SG. Quantifying heterogeneity in a meta-analysis. *Stat Med*. 2002;21(11):1539–1558.
- Reitsma JB, Glas AS, Rutjes AW, Scholten RJ, Bossuyt PM, Zwinderman AH. Bivariate analysis of sensitivity and specificity produces informative summary measures in diagnostic reviews. *J Clin Epidemiol*. 2005;58(10):982–990.
- Li Z, Zhou Q, Li Y, et al. Mean cerebral blood volume is an effective diagnostic index of recurrent and radiation injury in glioma patients: A meta-analysis of diagnostic test. *Oncotarget*. 2017;8(9):15642–15650.
- Song F, Khan KS, Dinnes J, Sutton AJ. Asymmetric funnel plots and publication bias in meta-analyses of diagnostic accuracy. *Int J Epidemiol*. 2002;31(1):88–95.
- Zhang TY, Hu P. Three-dimensional ultrasonography in the diagnosis of breast masses. *Shanghai Med Imaging*. 2007;16(02):123–124.
- Cheng YR, Dai ZY, Jj L, Li C, Zhang JQ, Yang L. Differential diagnosis between breast cancer and benign tumors using three-dimensional ultrasonography. *Chinese J Ultrasound Med*. 2008;24(S1):32–34.
- Hong XP, Sun ZX, Chen FH, Huang YH. Clinical value of “sun sign” in three-dimensional imaging of breast masses. *Mod Practical Med*. 2009;21(09):967–968.
- Zhou SC, Zeng Y, Fan YW, Chang X, Chen M. The phenomenon and the value of three-dimensional ultrasound in the diagnosis of breast tumors. *Shanghai Med Imaging*. 2010;19(01):28–29.
- An XH, Liang GX, Cheng YJ, et al. Application value of three-dimensional ultrasound in the differentiation of breast masses. *China Med Engineering*. 2010;18(02):104–144.
- Li CY, Wang Y, Che YP, Zhao W, Song WQ. The application value of 3D-US in the diagnosis of breast tumor. *China Med Herald*. 2011;8(20):150–151.
- Li D, Zhou XL, Wang W. Comparison of three-dimensional ultrasound imaging and X-ray mammography in the diagnosis of breast masses. *Heilongjiang Med Pharm*. 2012;35(05):108–109.
- Xu G, Rr W, Yao MH, Hx X, Ma F, Xie J. Combination of acoustic radiation force impulse technology and three-dimensional ultrasound in differential diagnosis of breast lesions. *Chin J Med Ultrasound*. 2013;10(12):984–988.
- Yang Y, Wu R, Ma F, Xu G, Yao MH, Xie J. Differential diagnostic value of three-dimensional ultrasound and magnetic resonance imaging in breast lesions. *J Tongji University*. 2013;34(06):78–82.
- Zhang W, Wu R, Yao M. Value of variety of non-invasive imaging technique in the differential diagnosis of breast carcinoma. *Chin J Clinicians*. 2013;7(14):6313–6316.
- Ma XM, Huang XL, Li D, Zou XP. Comparison of three-dimensional ultrasound imaging and X-ray mammography in the diagnosis of breast masses. *Heilongjiang Med Pharm*. 2013;36(02):55–56.
- Huang DQ, Xu W. The effect of 3-dimensional ultrasound imaging in the diagnosis of breast lumps. *Mod Instrument Med Treat*. 2013;19(05):24–26.
- Zhang X, Tang G, Ye W, Ma F, Liu Y, Hua T. Comparative imaging in the diagnosis of breast cancer. *J Pract Radiol*. 2014;30(3):434–438.
- Xu ZY, Xue GQ. Comparison between two and three-dimensional ultrasound in the differential diagnosis of benign and malignant breast tumors. *Chin Remedies Clin*. 2014;14(2):204–206.

29. Sun H, Zhang B, Ba S. Diagnostic value of three-dimensional ultrasound and molybdenum target X-ray for benign and malignant breast masses. *J Clin Ultrasound in Med*. 2014;16(11):782–783.
30. Dou FJ. Application of three-dimensional ultrasound in differential diagnosis of benign and malignant breast masses. *Chin J Clin Rational Drug Use*. 2014;7(19):151–152.
31. Hu YS, Hu YP, Wang Q, Xu RY. Diagnostic value of ultrasonic elastography strain rate ratio method combined with three-dimensional ultrasound imaging for breast solid lesions. *Practical Clin Med*. 2014;15(05):105–107.
32. Li ZZ, Shen LF, Li YY, Chen P, Chen LZ, Zz L, Yy L. Clinical utility of microRNA-378 as early diagnostic biomarker of human cancers: a meta-analysis of diagnostic test. *Oncotarget*. 2016;7(36):58569–58578.
33. Europe PMC [webpage on the Internet]. EMS, ultrasound use [updated October 6, 2017. Available from: <http://europepmc.org/books/NBK442034>. Accessed September 4, 2018.
34. Gebhard RE, Eubanks TN, Meeks R. Three-dimensional ultrasound imaging. *Curr Opin Anaesthesiol*. 2015;28(5):583–587.
35. Wu F, Ter Haar G, Chen WR. High-intensity focused ultrasound ablation of breast cancer. *Expert Rev Anticancer Ther*. 2007;7(6):823–831.
36. Xie X, Ouyang S, Wang H, et al. Dosimetric comparison of left-sided whole breast irradiation with 3D-CRT, IP-IMRT and hybrid IMRT. *Oncol Rep*. 2014;31(5):2195–2205.
37. Pan Y, Zhang J, Fu H, Shen L. miR-144 functions as a tumor suppressor in breast cancer through inhibiting ZEB1/2-mediated epithelial mesenchymal transition process. *Onco Targets Ther*. 2016;9:6247–6255.

Cancer Management and Research

Publish your work in this journal

Cancer Management and Research is an international, peer-reviewed open access journal focusing on cancer research and the optimal use of preventative and integrated treatment interventions to achieve improved outcomes, enhanced survival and quality of life for the cancer patient. The manuscript management system is completely online and includes

Submit your manuscript here: <https://www.dovepress.com/cancer-management-and-research-journal>

a very quick and fair peer-review system, which is all easy to use. Visit <http://www.dovepress.com/testimonials.php> to read real quotes from published authors.

Dovepress