

## Oncology

# Mesothelial Inclusions in Pelvic Lymph Nodes Initially Diagnosed as Metastatic Prostate Cancer; the Utility of Second Opinions and Genomic Testing in the Setting of Unexpected Results



Fadi Joudi <sup>a</sup>, Bela S. Denes <sup>b</sup>, Carolyn Mies <sup>b</sup>, Zhiming Yang <sup>c</sup>, Alan W. Shindel <sup>b,\*</sup>

<sup>a</sup> Wichita Urology, 2626 N Webb Rd., Wichita, KS, 67226, USA

<sup>b</sup> Genomic Health Inc, 101 Galveston Dr., Redwood City, CA, 94063, USA

<sup>c</sup> Department of Pathology, Johns Hopkins University, 600 N. Wolfe Street/Carnegie 417, Baltimore, MD, 21287, USA

## ARTICLE INFO

## Article history:

Received 22 August 2016

Received in revised form

18 October 2016

Accepted 28 October 2016

## Keywords:

Prostate cancer

Lymph nodes

Mesothelial inclusions

Genomics

Risk-stratification

Metastasis

## ABSTRACT

Benign mesothelial inclusions in pelvic lymph nodes may be mistaken for metastatic disease in the setting of pelvic malignancy. In this case-report a patient with Low-Risk prostate cancer (confirmed by biopsy and genomic testing) underwent radical prostatectomy with pelvic lymph node dissection. The initial pathological diagnosis was organ-confined Gleason 3 + 3 = 6 cancer with metastasis to a pelvic lymph node. Upon review of the pathological specimen and immunohistochemical staining the lymph node tissue concerning for metastatic disease was recharacterized as mesothelial in origin. This case illustrates the importance of second opinions and immunohistochemistry for unexpected or unusual pathological findings.

© 2016 The Authors. Published by Elsevier Inc. This is an open access article under the CC BY-NC-ND license (<http://creativecommons.org/licenses/by-nc-nd/4.0/>).

## Introduction

Confidence in the accuracy of clinical data is critical to optimize decision making for patients with low-risk prostate cancer. Genomic testing can personalize results and improve confidence in appropriate risk-stratification for these patients.<sup>1</sup>

We report a case of a man with prostate cancer who was reported to have lymph node metastasis after definitive surgery despite clinical, pathological and molecular evidence of low-risk disease. As part of initial risk assessment the patient received genomic testing with the Oncotype DX<sup>®</sup> Genomic Prostate Score (Oncotype DX<sup>®</sup> GPS, Genomic Health Inc, Redwood City, CA) as an adjunct to standard clinical metrics. In conjunction with the patient's National Comprehensive Cancer Center (NCCN<sup>™</sup>) risk-group, the Oncotype DX<sup>®</sup> GPS test confirmed his individual low-risk of adverse pathological findings. The patient initially elected active surveillance (AS) but proceeded to robotic-assisted radical prostatectomy (RALP) based upon a rising PSA. Initial surgical pathology interpretation was positive for metastatic carcinoma in a

pelvic lymph node. Because of this discordant and unexpected finding, secondary review of the pathology was requested. Special stains were negative for metastatic prostate cancer and the final pathology confirmed organ-confined disease, consistent with the patient's individualized pre-surgical risk assessment.

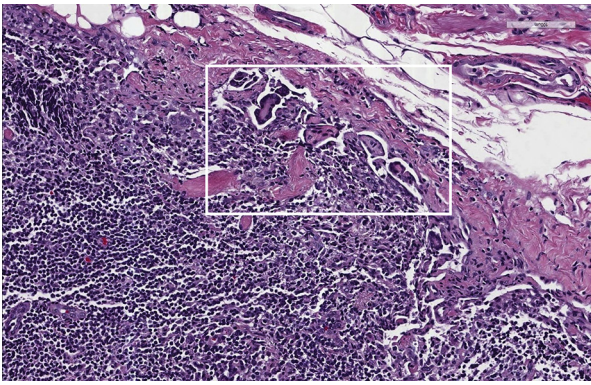
## Case presentation

A 58 year old man with hypertension and hypothyroidism presented to his urologist with an elevated PSA of 6.5 ng/mL. There was no palpable prostate nodule. A Transrectal Ultrasound Guided Biopsy revealed Gleason 3 + 3 = 6 prostate carcinoma involving 2 of 12 cores; maximal core involvement with carcinoma was 30%. PSA density was 0.2 ng/mL/mL. Per NCCN<sup>®</sup> guidelines his cancer was classified as Low-Risk.

As part of his initial evaluation his biopsy was sent for genomic testing with the OncotypeDx<sup>®</sup> GPS test. The Oncotype DX<sup>®</sup> GPS test is a 17-gene rtPCR-based panel that has been validated to improve prediction of organ-confined disease (pT2), low Gleason score (defined as pathological Gleason 3 + 4 or less), and biochemical recurrence after radical prostatectomy. The test reports a Genomic Prostate Score (GPS<sup>™</sup>) result which scales from 0 to 100 with

\* Corresponding author. Fax: +1 650 556 1132.

E-mail address: [ashindel@genomichealth.com](mailto:ashindel@genomichealth.com) (A.W. Shindel).



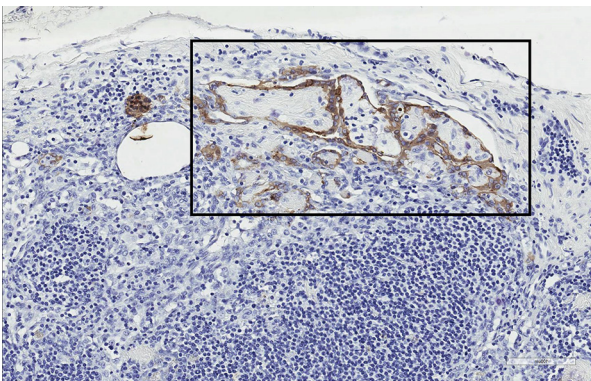
**Figure 1.** 20× magnification hematoxylin and eosin stain of pelvic lymph node; atypical cells initially diagnosed as metastatic cancer are noted in the sub-capsular region (box).

progressively higher scores implying lower odds of favorable pathology.<sup>2</sup>

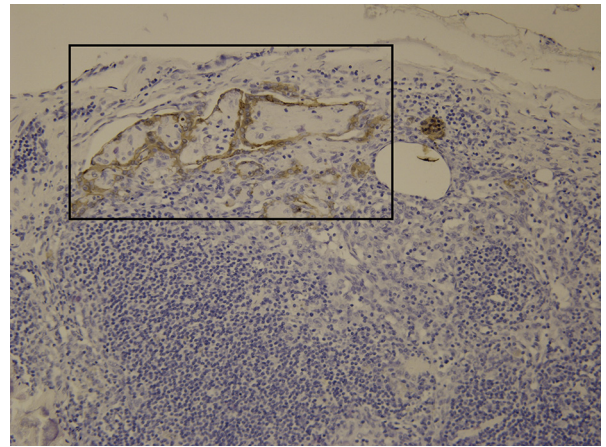
This patient's GPS result was 19, confirming that the patient's risk for adverse pathology was consistent with NCCN Low-Risk Disease. Based on NCCN risk category and the patient's individual GPS result, his estimated likelihood of favorable pathology was 78%; the estimated likelihood of low-grade disease (Gleason 3 + 4 or less) was 89% and the likelihood of organ-confined disease was 84%.

With the incorporation of Oncotype DX<sup>®</sup> GPS testing the urologist and patient elected AS for initial management. Follow up PSA four months after diagnosis had risen to 6.8 ng/mL followed by a further increase to 7.9 ng/mL seven months after diagnosis. Based on rising PSA, the patient and his physician elected to proceed to RALP which was performed without complication nine months after diagnosis.

Surgical pathology revealed a 43 g prostate containing Gleason 3 + 3 = 6 prostate carcinoma with negative surgical margins and no extraprostatic extension of disease. Tumor involved 8% of the gland and was present bilaterally. Perineural invasion was noted but there was no lymphovascular invasion. There was a 3 mm focus of papillary and epithelioid-appearing cells in a single node in the right pelvic lymph node packet (Fig. 1). Immunohistochemical staining (IHC) for pancytokeratin was interpreted as positive (Fig. 2), leading to a diagnosis of metastatic prostate carcinoma.



**Figure 2.** 20× Magnification cytokeratin IHC; the atypical cells are positive for the epithelial and mesothelial marker pancytokeratin (box).



**Figure 3.** 20× Magnification calretinin IHC; the atypical cells are positive for the mesothelial marker calretinin (box).

Pathological stage was reported as pT2cN1Mx (AJCC Staging Manual, 7th edition, 2010).

Given the unexpected finding of metastatic carcinoma in the setting of organ-confined, low-grade disease with low pre-treatment GPS result, the specimens were submitted for secondary pathological review. On review by outside expert review, the papillary tissue in the lymph node was characterized as mesothelial. IHC stains were positive for Calretinin (Fig. 3) Stains for PSA and NKX3.1 were negative. Based on this information the pathologic stage was revised to pT2N0Mx.

Follow up PSA was <0.1 ng/mL at 6 weeks post-operatively. The patient is currently doing well and recovering from surgery.

## Discussion

This patient's comprehensive pre-treatment assessment (including clinical and pathological features as well as individual biology as assessed by Oncotype DX<sup>®</sup> GPS test) suggested a high likelihood of favorable risk, organ-confined prostate cancer. At surgery these results were confirmed in terms of the prostate. However, the unexpected initial finding of metastatic carcinoma called into question the utility and accuracy of the pre-treatment assessment. This discordant result prompted a pathology second opinion which provided a revised diagnosis and cancer stage.

Benign glandular lymph node inclusions are a rare but recognized diagnostic entity in pelvic and abdominal lymph nodes resected in gynecologic cancers.<sup>3,4</sup> To our knowledge, they have been described only once previously in a man, who had small bowel (terminal ileum) carcinoma.<sup>5</sup> Because mesothelial cells – benign and malignant – stain with cytokeratins, it is essential for the pathologist to examine a panel of IHC stains that includes markers for mesothelial differentiation – calretinin and/or WT1 – to accurately distinguish between metastatic carcinoma and benign mesothelial lymph node inclusions. Negative staining for PSA further excluded metastatic prostate carcinoma in this case.

## Conclusion

This case illustrates the benefits of comprehensive assessment, including genomic testing, for personalizing decision making in men with low-risk prostate cancer. Accuracy of the initial

diagnostic procedures (i.e. clinical and genomic features) was confirmed with a pathology second opinion and special IHC stains. The confirmation of low-risk organ confined disease spared this patient from consideration of adjuvant treatments such as long term androgen deprivation therapy.

#### Conflict of interest

BSD, CM, and AWS are full time employees of Genomic Health, United States and have investment interests in this company. FJ has received research support from Genomic Health, United States.

#### Funding Sources

This research did not received any specific grant from funding agencies in the public or not-for-profit sectors. The patient described in this case report is part of an ongoing registry study supported by Genomic Health, United States.

#### Acknowledgment

The authors wish to thank Michael Bonham for assistance in manuscript preparation and Jonathan Epstein for pathology review.

#### References

1. Bostrom PJ, Biartell AS, Catto JW, et al. Genomic predictors of outcome in prostate Cancer. *Eur Urol*. 2015 Dec;68(6):1033–1044.
2. Brand TC, Zhang N, Crager MR, et al. Patient-specific meta-analysis of 2 clinical validation studies to predict pathologic outcomes in prostate cancer using the 17-gene genomic prostate score. *Urology*. 2016 Mar;89:69–75.
3. Acikalin MF, Ozalp S, Turan D. Mesothelial pelvic lymph node inclusion in a patient with ovarian microinvasive borderline mucinous tumor: Case report with review of the literature. *Int J Gynecol Cancer*. 2007 Jul-Aug;17(4):917–921.
4. Colebatch A, Clarkson A, Gill AJ. Benign mesothelial cells as confounders when cytokeratin immunohistochemistry is used in sentinel lymph nodes. *Hum Pathol*. 2011 Aug;42(8):1209–1211.
5. Huntrakoon M. Benign glandular inclusions in the abdominal lymph nodes of a man. *Hum Pathol*. 1985 Jun;16(6):644–646.