

Complex redo cervical and vertebral artery reconstruction for Takayasu arteritis

Aleem K. Mirza, MD,^a Nolan C. Cirillo Penn, MD,^b Robert D. Brown Jr, MD,^c and Thomas C. Bower, MD,^b *Minneapolis and Rochester, Minn*

ABSTRACT

A 54-year-old woman presented with an enlarging, pulsatile left neck mass and a history of Takayasu arteritis. She had seven prior cervical vascular reconstructions, including a prosthetic right-to-left carotid crossover, and left vertebral and subclavian bypasses done with saphenous vein. The skin of her neck was scarred and thin. The anastomotic pseudoaneurysms were resected, the left carotid bifurcation was reconstructed with the cryopreserved femoral artery because of the concern about wound healing, and the subclavian and vertebral vein grafts were reimplanted. Intraoperative management, clamp sites and sequence, manner of shunting, choice of conduit, and wound healing were important considerations. (*J Vasc Surg Cases and Innovative Techniques* 2021;7:78-83.)

Keywords: Takayasu arteritis (TA); Cerebrovascular; Redo operation; Cryopreserved arterial allograft; Anastomotic pseudoaneurysm; Carotid artery; Vertebral artery; Subclavian artery

Takayasu arteritis (TA) affects the supra-aortic trunks in as many as 70% of patients. Involvement of the subclavian arteries is most frequent, followed by the common carotid and vertebral arteries in that order.^{1,2} Surgery is reserved for symptomatic cases refractory to medical management or for end-organ dysfunction.³⁻⁵ We present a patient with TA who had enlarging, symptomatic left carotid anastomotic pseudoaneurysms and multiple prior cerebrovascular reconstructions. The patient provided consent for publication of this case.

CASE PRESENTATION

A 54-year-old woman presented with an enlarging, pulsatile left neck mass associated with dizziness, neck fullness with focal tenderness, and mild dysphagia. Her history was significant for cerebrovascular TA and multiple operations dating to 1983. As a consequence, she suffered from baroreceptor dysfunction and episodic hypotension. She has been followed for years by a senior cerebrovascular neurologist (R.D.B.), and vascular surgery. She developed small pseudoaneurysms at the left carotid bifurcation anastomosis, which slowly enlarged and eventually caused symptoms. She also had a stable asymptomatic

pulmonary artery aneurysm (4.6 cm). Her previous surgical interventions are as follows (Fig 1):

- 1983: Ascending aorto-bilateral common carotid artery bypass with a 14 mm × 7 mm bifurcated polyester graft.
- 1984: Right vertebral artery bypass with ipsilateral great saphenous vein, from the hood of the aorto-carotid graft to the V3 segment of the vertebral artery. This was revised twice for early postoperative thrombosis, and the proximal vein graft replaced with polyester.
- 1984: Redo aorto-left carotid artery bypass with an 8 mm polyester graft due to thrombosis of the original left limb.
- 1988: Right to left carotid-carotid bypass with 8 mm polyester, tunneled anteriorly, due to failure of the second aorto-left carotid graft.
- 1992: Left vertebral and subclavian bypasses with ipsilateral great saphenous vein.
- 2012: Ascending aortic replacement due to aneurysmal degeneration, with a polyester interposition graft to the existing aorto-right carotid graft.
- 2012: Revision of the left carotid anastomosis for a pseudoaneurysm, using a polyester interposition graft. A Gore iliac limb was used to exclude a pseudoaneurysm at the distal aorto-right carotid artery anastomosis.

On examination, she had mild chronic hoarseness. The tissues of her neck were thin and multiple prior incisions were well healed. She had an excellent right carotid pulse over the graft, a visible and bounding pulse over the anteriorly-routed carotid-carotid graft, and an irregular, pulsatile, and mildly tender mass in the left neck. There were visible subcutaneous arteries overlying the carotid graft near the midline of the neck. There were palpable bilateral radial artery pulses at the wrist. Computed tomographic angiography of the head, neck, and chest showed widely patent ascending aortic, aorto-right carotid, and right vertebral artery reconstructions. The carotid-carotid bypass and the left-sided grafts were patent. However, there were irregular pseudoaneurysms at the left carotid graft anastomosis and bifurcation (Fig 2). A transfemoral arteriogram of the head and neck was done to further define her complex

From the Minneapolis Heart Institute at Abbott Northwestern Hospital, Minneapolis^a; and the Division of Vascular and Endovascular Surgery,^b and Department of Neurology,^c Mayo Clinic, Rochester.

Author conflict of interest: none.

Presented at the 2019 Vascular Annual Meeting of the Society for Vascular Surgery, National Harbor, Md, June 14, 2019.

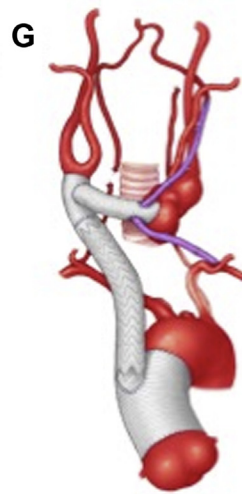
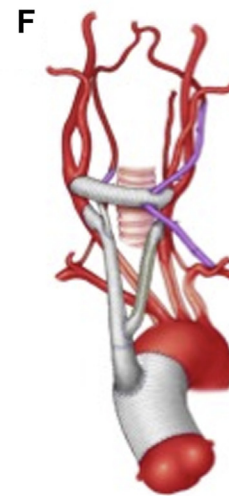
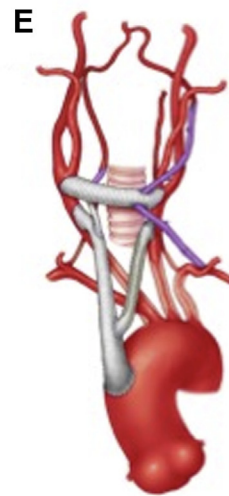
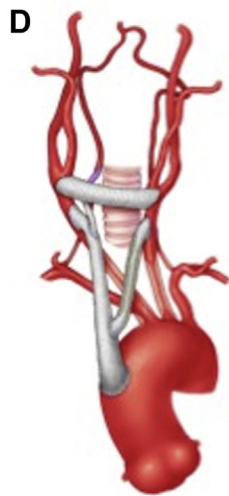
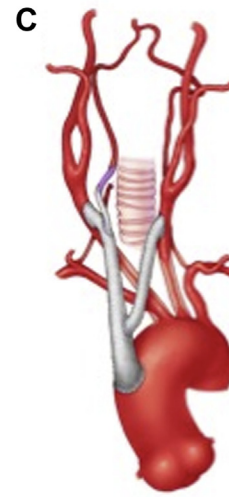
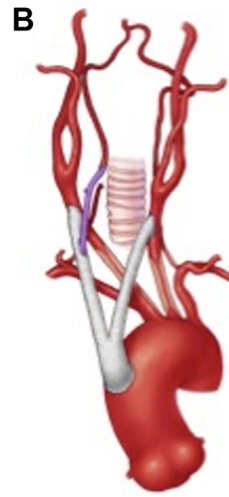
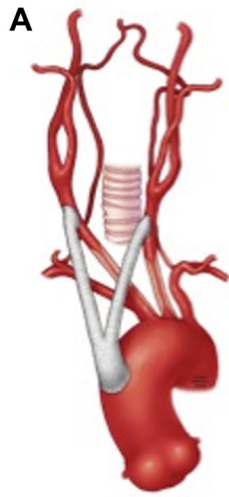
Correspondence: Aleem K. Mirza, MD, Minneapolis Heart Institute at Abbott Northwestern Hospital, 800 East 28th St, Minneapolis, MN 55407 (e-mail: Aleem.mirza@allina.com).

The editors and reviewers of this article have no relevant financial relationships to disclose per the Journal policy that requires reviewers to decline review of any manuscript for which they may have a conflict of interest.

2468-4287

© 2020 The Authors. Published by Elsevier Inc. on behalf of Society for Vascular Surgery. This is an open access article under the CC BY-NC-ND license (<http://creativecommons.org/licenses/by-nc-nd/4.0/>).

<https://doi.org/10.1016/j.jvscit.2020.10.008>



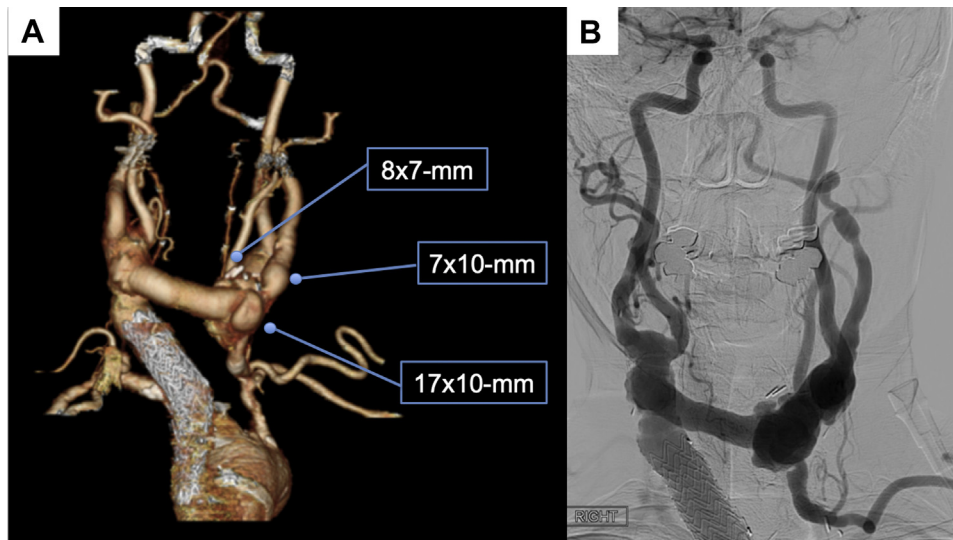


Fig 2. A, Three-dimensional reconstruction of preoperative computed tomography angiography demonstrating the multifocal pseudoaneurysmal degeneration in the left neck, in a 54-year-old woman with a history of cerebrovascular Takayasu arteritis (TA). **B,** Catheter-based angiography demonstrating the multifocal pseudoaneurysmal degeneration in the left neck, in a 54-year-old woman with a history of cerebrovascular TA.

cervical and intracranial cerebrovascular anatomy (Fig 2, B). There was delayed filling of the left cerebral circulation due to turbulence and slow transit through the left carotid pseudoaneurysms. The anterior communicating and bilateral posterior communicating arteries were diminutive. However, the right P1 segment was absent. The arteriogram showed three pseudoaneurysms at the left carotid anastomosis, the largest of which measured 17 mm × 10 mm (Fig 2). The native left subclavian artery was diseased but patent, and the thoracoacromial artery was patent, if a left pectoralis major muscle flap was needed.

Operative repair was recommended because of progressive symptoms and the enlarging pseudoaneurysms. The procedure was performed with general endotracheal anesthesia and electroencephalographic (EEG) monitoring (Supplementary Video, online only). A transverse incision was made at midline in the neck to isolate the carotid-carotid graft away from the pseudoaneurysms, taking care to protect the adjacent subcutaneous arterial collaterals. A 5-cm segment of the graft was dissected free. Two Rummel tourniquets were placed around it to secure shunts into the internal carotid and vertebral artery vein grafts as necessary. The oblique left neck incision along the anterior

border of the sternocleidomastoid muscle was reopened. Control of the left subclavian and vertebral artery saphenous vein grafts was done first. The vertebral vein graft was retracted laterally with a vessel loop to isolate the external and internal carotid arteries. The vagus and hypoglossal nerves were identified and protected, although the vagus later had to be separated from the underside of the old carotid anastomosis using a Freer. Intravenous heparin was administered to achieve a therapeutic activated clotting time (Fig 3).

During the left neck exposure, an 8-mm-diameter cryopreserved femoral artery allograft was thawed and prepared on a back table. The mean arterial blood pressure (MAP) was maintained between 105 mm Hg and 115 mm Hg. The vertebral artery vein graft and the external and internal carotid arteries were clamped for over 2 minutes without EEG changes, so no shunts were used. Clamps were then placed on the carotid-carotid graft in the mid neck and the subclavian graft. The old carotid-graft anastomosis was dissected free and the hood of the old graft was entered sharply. The anastomoses of the vertebral and subclavian saphenous vein grafts were taken down. The native carotid bifurcation had degenerated and was dilated.

Fig 1. Illustration summarizing prior surgical interventions for a 54-year-old woman with a history of cerebrovascular Takayasu arteritis (TA). **A,** Ascending aorto-bilateral common carotid artery bypass with a 14 mm × 7 mm bifurcated polyester graft. **B,** Right vertebral artery bypass with ipsilateral great saphenous vein (GSV), from the hood of the aorto-carotid graft to the V3 segment of the vertebral artery. This was revised twice for early postoperative thrombosis, and the proximal vein graft replaced with polyester. **C,** Redo aorto-left carotid artery bypass with an 8 mm polyester graft due to thrombosis of the original left limb. **D,** 1988: Right to left carotid-carotid bypass with 8 mm polyester, tunneled anteriorly, due to failure of the second aorto-left carotid graft. **E,** 1992: Left vertebral and subclavian bypasses with ipsilateral GSV. **F,** 2012: Ascending aortic replacement due to aneurysmal degeneration, with a polyester interposition graft to the existing aorto-right carotid graft. **G,** 2012: Revision of the left carotid anastomosis for a pseudoaneurysm, using a polyester interposition graft. A Core iliac limb was used to exclude a pseudoaneurysm at the distal aorto-right carotid artery anastomosis.

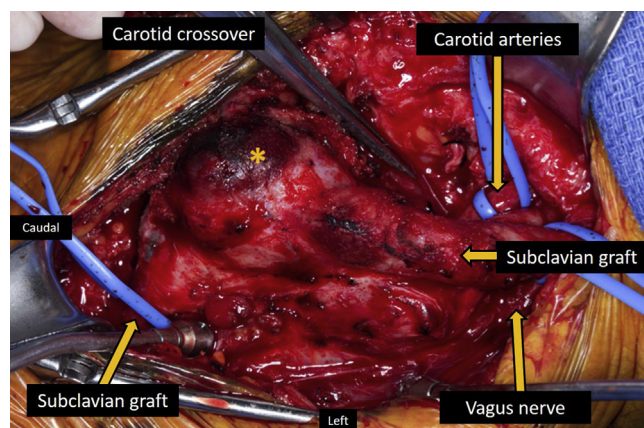


Fig 3. Intraoperative photograph of the pseudoaneurysmal degeneration in the left neck, demonstrating the carotid crossover graft, internal and external carotid arteries, previous saphenous vein vertebral graft, saphenous vein left subclavian graft, vagus nerve, and the largest foci of pseudoaneurysm (*).

There were three pseudoaneurysms along the carotid suture line. The pseudoaneurysms, carotid bifurcation, and a segment of the prosthetic graft were resected en bloc, and the specimen sent to pathology. The frozen section showed no giant cells, bacteria, or other acute inflammatory changes.

The cryopreserved allograft was spatulated and sewn end-to-end to the carotid-carotid graft in the anterior midline of the neck. The internal and external carotid arteries were opened vertically, and the posterior walls sewn together to recreate the carotid artery bifurcation. The allograft was spatulated and sewn end-to-end to the new carotid bifurcation. The vertebral graft was reimplemented end-to-side onto the anterolateral hood of the allograft. Finally, a remaining segment of the allograft was placed as an interposition to the subclavian artery vein graft, with the allograft anastomosis positioned proximal to the vertebral artery vein graft. Blood flow was established into the external carotid, subclavian graft, vertebral graft, and internal carotid artery in that order. The EEG remained at baseline throughout the operation. Intraoperative duplex ultrasound showed the reconstruction to be widely patent with normal flow velocities and no intraluminal defects (Fig 4). The sternocleidomastoid muscle was mobilized medially to cover the grafts. There was good blood supply to the skin to allow primary closure. The patient was awakened in the operating room, moving all four extremities to command.

The patient was monitored for 3 days for strict blood pressure control. She was slowly advanced to a soft diet. She described a "sticking" sensation in her throat with swallowing, and a bedside swallow study proved unremarkable. She was discharged to home the next day, neurologically intact. A subsequent indirect laryngoscopy showed paralysis of the left cord. At 1-year follow-up, she was tolerating a general diet without difficulty, had no recurrent dizziness, and had widely patent reconstructions by computed tomographic angiography. Her voice quality had returned to her preoperative baseline.

DISCUSSION

Surgical intervention for TA is usually reserved for medically refractory disease and/or end-organ dysfunction. Previous analysis by our group showed that the best surgical results occur when the disease is chronic and the patient is on no immunosuppression.^{3,4} Her TA had been quiescent for years, with most of her operations done for early or late graft-related problems and not flares of arteritis. She had been able to discontinue her immunosuppressive therapy in 2017. The pseudoaneurysms were initially observed because they were very small, caused no problems, and a fifth time redo left neck arterial reconstruction would be complex. Indication for operation was clear given the enlargement of the pseudoaneurysms and her new symptoms. There were several important considerations for this operation, including approach and exposure, cerebral protection, the order of the arterial reconstructions, choice of conduit, cranial nerve injuries, and wound healing concerns.

For years, our group has used EEG monitoring for supra-aortic trunk or carotid revascularization to guide the need for shunt placement, and has preferred this adjunct to others. Moreover, MAP is generally maintained between 90 mm Hg and 105 mm Hg during carotid artery clamping to enhance cerebral perfusion. The higher MAP targeted in this patient proved beneficial as routine shunting would have been a challenge. The stability in the EEG tracing after more than a 2-minute test clamp was reassuring. We were prepared to place shunts into both the internal carotid artery and the vertebral artery vein graft given the intracerebral arteriographic findings and concern that the left hemisphere might be isolated. However, placement of the shunts into the carotid-carotid graft was an issue for two reasons. First, there was mild thickening of the graft, which could affect the ability to safely secure the shunts without them becoming dislodged or disrupting the pseudointima. Second, there was a short distance from where the shunts would be inserted into the carotid-carotid graft to the right carotid anastomosis given her asthenic body habitus. Preparation was for two Rummel tourniquets and two other pursestring sutures to be placed on the anterior graft as smaller tourniquets, to secure the shunts. Large Sundt shunts were available and marked for length.

A cryopreserved femoral artery allograft was chosen for the conduit for several reasons. We have found arterial conduit, including the native superficial femoral artery, to be useful in areas where there is a risk of wound breakdown and/or infection.^{6,7} Arterial integrity is better than vein in our opinion and seems to carry less risk of desiccation than vein if exposed, or anastomotic dehiscence if infected. We have used superficial femoral artery or femoral artery allografts successfully for carotid and subclavian artery reconstructions when there is violation of the aerodigestive tract during head and neck cancer

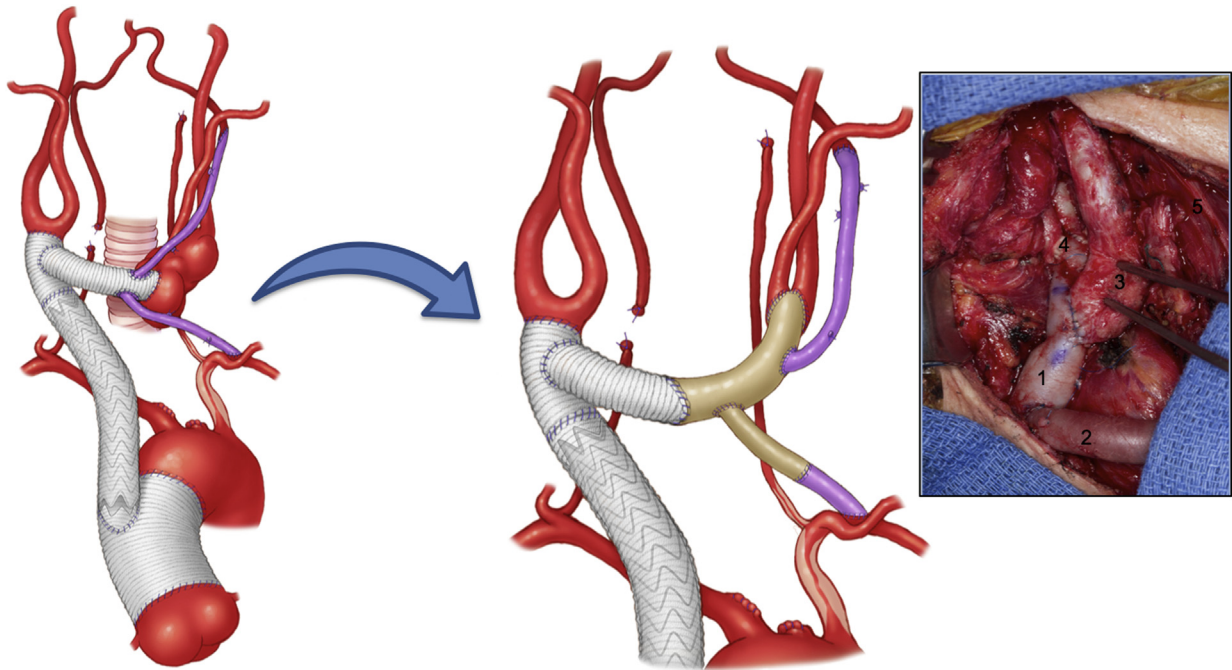


Fig 4. Illustration and photography summarizing the repair of a 54-year-old woman with a history of cerebrovascular Takayasu arteritis (TA) who presented with multifocal pseudoaneurysms in the left neck after multiple prior operations.

resections; and similarly for visceral artery reconstructions in patients who require resection for locally advanced pancreatic cancer.^{6,8} Her superficial femoral arteries and saphenous veins were small, and there would have been clear size mismatch. The cryopreserved allograft is expensive, but we have not yet seen aneurysmal degeneration or spontaneous rupture of these conduits as occurred in the past when the preservation techniques were different.

Routine completion intraoperative duplex ultrasound imaging has been a longstanding mainstay in our practice after carotid, supra-aortic trunk, renal and mesenteric reconstructions. The risk of early postoperative graft failure is negligible when ultrasound imaging shows a widely patent arterial reconstruction.^{9,10} Although she had hoarseness in her voice preoperatively, the left vocal cord was functional. Disappointingly, the cord was paralyzed when examined postoperatively. She was well aware of a high risk of cranial nerve injuries,¹¹⁻¹³ especially because it was a fifth time redo neck exploration. Fortunately, her hoarseness improved, returning to her baseline at 1-year follow-up. The vagus nerve was visualized, but the injury likely occurred when separating the nerve from the back wall of the pseudoaneurysms, as this area was inflamed. Perhaps part of the native arterial or pseudoaneurysm wall could have been left in place and the injury avoided. However, we felt it necessary to remove the old graft and pseudoaneurysms to allow safe closure of the neck incision.

CONCLUSIONS

This case highlights the complexities and challenges of redo cervical arterial revascularization, especially for patients with a history of arteritis. The cerebrovascular arterial anatomy needs to be fully defined to plan the operation and anticipate the need to shunt. Cerebrovascular monitoring is important, and in this case, the EEG helped avoid the need for shunt placement. We favor arterial conduit for reconstruction when the anticipated risk of wound breakdown or local infection is high, or if native vein proves inadequate. Completion intraoperative assessment of the reconstruction is useful and can be done by several techniques. Potential cranial nerve injuries and their sequelae need to be discussed with the patient before surgery.

REFERENCES

1. Grayson PC, Maksimowicz-McKinnon K, Clark TM, Tomasson G, Cuthbertson D, Carette S, et al. Vasculitis Clinical Research Consortium. Distribution of arterial lesions in Takayasu's arteritis and giant cell arteritis. *Ann Rheum Dis* 2012;71:1329-34.
2. Arnaud L, Haroche J, Toledano D, Cacoub P, Mathian A, Costedoat-Chalumeau N, et al. Cluster analysis of arterial involvement in Takayasu arteritis reveals symmetric extension of the lesions in paired arterial beds. *Arthritis Rheum* 2011;63:1136-40.
3. Labarca C, Makol A, Crowson CS, Kermani TA, Matteson EL, Warrington KJ. Retrospective comparison of open versus endovascular procedures for Takayasu arteritis. *J Rheumatol* 2016;43:427-32.

4. Fields CE, Bower TC, Cooper LT, Hoskin T, Noel AA, Panneton JM, et al. Takayasu's arteritis: operative results and influence of disease activity. *J Vasc Surg* 2006;43:64-71.
5. Kermani TA, Crowson CS, Cooper LT, Matteson EL, Warrington KJ. Diagnostic features, treatment, and outcomes of Takayasu arteritis in a US cohort of 126 patients. *Mayo Clin Proc* 2013;88:822-30.
6. Wilson WR, Bower TC, Creager MA, Amin-Hanjani S, O'Gara PT, Lockhart PB, et al; American Heart Association Committee on Rheumatic Fever, Endocarditis, and Kawasaki Disease of the Council on Cardiovascular Disease in the Young; Council on Cardiovascular and Stroke Nursing; Council on Cardiovascular Radiology and Intervention; Council on Cardiovascular Surgery and Anesthesia; Council on Peripheral Vascular Disease; and Stroke Council. Vascular graft infections, mycotic aneurysms, and endovascular infections: a scientific statement from the American Heart Association. *Circulation* 2016;134:e412-60.
7. Truty MJ, Kendrick ML, Nagorney DM, Smoot RL, Cleary SP, Graham RP, et al. Factors predicting response, perioperative outcomes, and survival following total neoadjuvant therapy for borderline/locally advanced pancreatic cancer. *Ann Surg* 2019 Apr 5. [E-pub ahead of print].
8. Truty MJ, Colglazier JJ, Mendes BC, Nagorney DM, Bower TC, Smoot RL, et al. En bloc celiac axis resection for pancreatic cancer: classification of anatomical variants based on tumor extent. *J Am Coll Surg* 2020;231:8-29.
9. Rasmussen TE, Panneton JM, Kalra M, Hofer JM, Lewis BD, Rowland CM, et al. Intraoperative use of new angle-independent Doppler system to measure arterial velocities after carotid endarterectomy. *J Vasc Surg* 2003;37:374-80.
10. Oderich GS, Panneton JM, Macedo TA, Noel AA, Bower TC, Lee RA, et al. Intraoperative duplex ultrasound of visceral revascularizations: optimizing technical success and outcome. *J Vasc Surg* 2003;38:684-91.
11. AbuRahma AF, Abu-Halimah S, Hass SM, Nanjundappa A, Stone PA, Mousa A, et al. Carotid artery stenting outcomes are equivalent to carotid endarterectomy outcomes for patients with post-carotid endarterectomy stenosis. *J Vasc Surg* 2010;52:1180-7.
12. Fokkema M, de Borst GJ, Nolan BW, Indes J, Buck DB, Lo RC, et al. Vascular Study Group of New England. Clinical relevance of cranial nerve injury following carotid endarterectomy. *Eur J Vasc Endovasc Surg* 2014;47:2-7.
13. Kakisis JD, Antonopoulos CN, Mantas G, Moulakakis KG, Sfyroeras G, Geroulakos G. Cranial nerve injury after carotid endarterectomy: incidence, risk factors, and time trends. *Eur J Vasc Endovasc Surg* 2017;53:320-35.

Submitted Aug 13, 2020; accepted Oct 5, 2020.