

Platelet Activation in Cats with Hypertrophic Cardiomyopathy

F. Tablin, T. Schumacher, M. Pombo, C.T. Marion, K. Huang, J.W. Norris, K.E. Jandrey, and M.D. Kittleson

Background: Cats with hypertrophic cardiomyopathy (HCM) are at risk for development of systemic thromboembolic disease. However, the relationship between platelet activation state and cardiovascular parameters associated with HCM is not well described.

Objectives: To characterize platelet activation by flow cytometric evaluation of platelet P-selectin and semiquantitative Western blot analysis of soluble platelet-endothelial cell adhesion molecule-1 (sPECAM-1).

Animals: Eight normal healthy cats (controls) owned by staff and students of the School of Veterinary Medicine and 36 cats from the UC Davis Feline HCM Research Laboratory were studied.

Methods: Platelet-rich plasma (PRP) was used for all flow cytometry studies. Platelet surface CD41 and P-selectin expression were evaluated before and after ADP stimulation. sPECAM-1 expression was evaluated by Western blot analysis of platelet-poor plasma that had been stabilized with aprotinin. Standard echocardiographic studies were performed.

Results: Resting platelets from cats with severe HCM had increased P-selectin expression compared to controls, and expressed higher surface density of P-selectin reflected by their increased mean fluorescence intensities (MFI). Stimulation with ADP also resulted in significantly increased P-selectin MFI of platelets from cats with severe HCM. Increased P-selectin expression and MFI correlated with the presence of a heart murmur and end-systolic cavity obliteration (ESCO). sPECAM-1 expression from cats with moderate and severe HCM was significantly increased above those of control cats.

Conclusions and Clinical Importance: P-selectin and sPECAM expression may be useful biomarkers indicating increased platelet activation in cats with HCM.

Key words: Hypertrophic cardiomyopathy; Platelet activation; Platelets; P-selectin; sPECAM-1.

Hypertrophic cardiomyopathy (HCM) is the most common cardiovascular disease of domestic cats, and is caused by a hereditary mutation in a sarcomeric gene (myosin binding protein C) in Maine Coon and Ragdoll cats.^{1–3} HCM results in left ventricular (LV) hypertrophy and myofibrosis and may lead to left heart failure, systemic arterial thromboembolism (ATE), and sudden death.^{4,5} Most of the thromboemboli are thought initially to form in the left atrium or left auricle, breaking loose to form a thromboembolus. Although the reasons thrombi form in this location have yet to be clearly defined, there is general agreement that the 3 factors of Virchow's triad (ie, endothelial damage, blood flow stasis, and hypercoagulability) likely underlie their formation.⁶ Specifically, endocardial injury has been observed at necropsy of cats with HCM⁷, and Doppler echocardiography has identified slowed blood flow velocity in the left atrium,

Abbreviations:

| | |
|----------|---|
| ADP | adenosine diphosphate |
| ATE | arterial thromboemboli |
| ESCO | end-systolic cavity obliteration |
| HCM | hypertrophic cardiomyopathy |
| LV | left ventricular |
| MFI | mean fluorescence intensity |
| PPP | platelet-poor plasma |
| PRP | platelet-rich plasma |
| RBC | red blood cell |
| sPECAM-1 | soluble platelet-endothelial cell adhesion molecule 1 |

particularly in the left auricle, in cats with left atrial enlargement because of HCM.^{8,9}

Platelet activation associated with HCM may be because of several factors. Studies have demonstrated a correlation between spontaneous platelet activation and LV hypertrophy in humans,^{10,11} and increased P-selectin expression has been documented in association both with congestive heart failure and HCM in humans.^{12–14} When considering the association of heart disease and platelet activation, an enlarged left atrium, endothelial damage, and the presence of mitral regurgitation all have the potential to generate high shear, resulting in platelet up-regulation, release of alpha granule components, and increased sensitivity to agonists.^{15,16} In vitro studies by Holme et al¹⁷ demonstrated shear-induced platelet activation and development of platelet microparticles under flow conditions that may be similar to those associated with diastolic dysfunction in cats with HCM as suggested by Bedard et al.¹⁸

Models of experimental ischemic thrombosis and of clinical studies in cats with HCM have provided evidence that increased platelet activation likely plays a

From the Department of Anatomy, Physiology and Cell Biology (Tablin, Schumacher, Pombo); the Department of Surgery and Radiology (Jandrey); the Department of Medicine and Epidemiology (Kittleson), School of Veterinary Medicine, University of California Davis, Davis, CA; the Berkeley Dog and Cat Hospital, Berkeley, CA (Marion); the Madison Street Animal Hospital, Seattle, WA (Huang); and The Sidney-Kimmel Comprehensive Cancer Center, Johns-Hopkins Medical Institute, Baltimore, MD (Norris).

Corresponding author: Fern Tablin, VMD, PhD, Department of Anatomy, Physiology and Cell Biology, School of Veterinary Medicine, University of California, Davis, Davis, CA 95616; e-mail: ftablin@ucdavis.edu.

Submitted August 22, 2013; Revised November 21, 2013; Accepted January 9, 2014.

Copyright © 2014 by the American College of Veterinary Internal Medicine

DOI: 10.1111/jvim.12325

critical role in HCM-associated thromboembolism. Early aggregometry studies by Helenski and Ross,¹⁹ as well as those of Welles et al,²⁰ demonstrated that platelets from cats with HCM are more sensitive to agonist stimulation. However, a more in-depth study is required to determine the relationship of platelet activation to cardiovascular parameters associated with HCM. We hypothesize that increased platelet reactivity and sensitivity to agonists such as ADP, release of platelet alpha granule contents, and increases in circulating platelet soluble endothelial cell adhesion molecule-1 (sPECAM-1) are indicators of platelet activation which contributes to the development of a hypercoagulable state and eventual development of ATE.

Materials and Methods

Animals

The study was approved by the Institutional Animal Care and Use Committee at the University of California, Davis. Signed owner consent was obtained for all normal cats used in the investigation. Clinically healthy cats were owned and volunteered by the staff and students at the University of California, Davis School of Veterinary Medicine. All cats were >1 year of age, had no known current cardiac disease, and were normal on physical and echocardiographic examinations. This group of cats served as controls.

A second group of animals was selected from a colony of Maine Coon and Maine Coon-cross cats bred and raised at the UC Davis Feline HCM Research Laboratory, School of Veterinary Medicine. Many of these cats have a known genetic predisposition for HCM. There were no healthy Maine Coon cats available for our study. Categorization of cats with HCM was based on physical examination and transthoracic echocardiography. Factors for determining the presence and severity of disease included left ventricular wall thickness, size of papillary muscles, and left atrial size as well as the presence or absence of systolic cranial motion of the mitral valve, end-systolic cavity obliteration (ESCO), a heart murmur, or some combination of these findings. The genotype (+/- A31P myosin binding protein C mutation) of each cat in the HCM colony also was noted. Based on these criteria, cats were identified as severely diseased, moderately diseased, or equivocal, based on the study of Hsu et al.²¹ Cats that were equivocal for HCM had normal left ventricle (LV) wall thickness and enlarged papillary muscles with or without systolic cranial motion of the mitral valve. Cats with moderate HCM had normal to mild left atrial enlargement and left ventricular wall thickness of 6–7 mm. Cats with severe HCM had no to severe left atrial enlargement and left ventricular wall thickness >7 mm. None of the colony cats had a history of or clinical signs consistent with ATE. No cats were receiving any treatment for HCM at the time of this study.

When required, cats were sedated with 0.1 mg/kg acepromazine SC, and blood was collected from either the jugular or medial saphenous veins. Complete blood counts were obtained using an automated blood cell analyzer.^a For sPECAM-1 studies, blood was collected into EDTA tubes, and samples were immediately transferred to 15 mL polypropylene tubes containing 769 μ L of chilled aprotinin and maintained on ice until centrifugation (5 min, 500 \times g, 4°C). The resulting plasma was centrifuged (5 min, 15,800 \times g, 4°C), and platelet-poor plasma (PPP) was collected and immediately

frozen in polypropylene cryotubes at -80°C until further analysis.

Flow Cytometry

For flow cytometry studies, blood was collected into 3.2% trisodium citrate tubes and PRP was prepared by gravity sedimentation after by dilution with Tyrodes Hepes buffer containing 5 mM dextrose to achieve a final platelet concentration 1×10^7 platelets/100 μ L.¹⁸ Samples either were unstimulated (resting) or treated with 20 μ M ADP, and incubated for 15 minutes at room temperature. Samples then were labeled with antibodies to both CD62P (P-selectin)^b and a biotinylated antibody to CD41,^c incubated an additional 45 min followed by the addition of streptavidin conjugated to Alexa 633.^d Samples were incubated for an additional 30 min before to fixation in 1% paraformaldehyde. Isotype and autofluorescent controls were run for all samples. Samples were read on a 5 color flow cytometer^e and data were analyzed using commercially available flow cytometry analysis software.^f

Platelets were defined by forward and side scatter properties as well by the use of 0.9 μ m calibrated beads^g according to the method of Robert et al.²² Platelets were further defined by expression of CD41 (the alpha subunit of the major platelet integrin $\alpha 2\text{b}\beta 3\text{a}$) on their cell surface. Within the CD41-positive platelet population, we evaluated the percentage of platelets that were positive for P-selectin on their surface and the mean fluorescence intensity of P-selectin expression, an indicator of protein density. A microvesicle population was defined as CD41-positive events that had a shift in forward scatter, and which were approximately 0.5 μ m in size, as determined by calibration beads.

Western Blot Analysis

Plasma expression of sPECAM-1 was quantified by Western blot analysis using an affinity purified polyclonal antibody.^h Equal volumes of plasma from normal cats and cats with HCM were evaluated by sodium dodecyl sulfate-polyacrylamide gel electrophoresis (SDS-PAGE), transferred to nitrocellulose membranes, blocked with 5% nonfat milk, and incubated overnight with a polyclonal antibody to the extracellular domain of recombinant human PECAM-1 (diluted 1:1000 in 5% bovine serum albumin, 4°C). Blots were washed 3 times and probed with a rabbit antisheep antibody conjugated to horseradish peroxidase (1:50,000, 1 hour at room temperature). Membranes were imaged with a commercial imaging system,ⁱ using a chemiluminescent substrate.^j Densitometry was quantified using the Image J analysis system.^k

Fibrinogen

Blood samples collected in 3.2% trisodium citrate were submitted for plasma fibrinogen concentration analysis at the Veterinary Medical Teaching Hospital Clinical Pathology laboratory. Fibrinogen assays were performed by the same laboratory using the "Claus method".²³

Statistical Analysis

Normally distributed data were analyzed by one-way ANOVA with Dunnett's multiple comparison tests. Normality was determined by the Shapiro-Wilk normality test. Data that were not normally distributed were evaluated by a Kruskal-Wallis One-way ANOVA on ranks and a Dunn's multiple comparison test.

All calculations were performed using statistical software.¹ All tests used a significance level of $P \leq .05$.

Results

A total of 8 control cats, 5 cats with equivocal echocardiographic findings, 22 cats with moderate HCM, and 9 cats with severe HCM were studied. However, a number of cats with moderate HCM were not available for the flow cytometry studies.

Flow Cytometry

Platelet and platelet microvesicle populations were defined using calibrated beads, according to the method of Robert et al²² and the authors' platelet flow cytometry experience.^{24,25} Resting platelet populations in control cats have a distinctive oval pattern (Fig 1A) whereas resting platelets from cats with severe HCM have an elongated profile typical of activated platelets (Fig 1B).^{24,25} A representative histogram demonstrates the difference in resting platelet P-selectin expression between a control cat and a cat with severe HCM (Fig 1C). Cats with severe HCM had statistically higher numbers of P-selectin-positive platelets when compared with platelets from a resting control population ($n = 20$, Fig 1D). Also, a statistically significant increase in the mean fluorescence intensity (MFI) of P-selectin of platelets from cats with severe HCM was identified as compared to those of resting control platelets ($n = 20$, Fig 1E). However, there was no difference in either the percentage of P-selectin-positive platelets or their MFI between the control group and the equivocal and moderate groups. No significant differences in the number of CD41-positive platelet microvesicles were observed among any of the groups (data not shown).

When platelets were stimulated with 20 μM ADP, no significant differences in the percentage of P-selectin-positive platelets were identified among any of the groups ($n = 20$, Fig 2A). Statistically significant differences in the MFI of P-selectin on the platelet surface between control cats and cats with severe HCM ($n = 20$, Fig 2B), however, were identified. In addition, a significant increase in the CD41-positive platelet microvesicle population in cats with severe HCM was identified when compared to the control group ($n = 20$, Fig 3A). A representative histogram of CD41-positive microvesicles from a control and a cat with severe HCM is shown in Figure 3B.

All cats underwent echocardiographic examinations, allowing us to determine whether either the changes seen in P-selectin expression or MFI correlated with a heart murmur or with ESCO. A significant difference was identified between the percentage of P-selectin-positive platelets from cats with a murmur and those without a murmur ($n = 20$, Fig 4A). Significance differences in resting platelet P-selectin MFI also were observed between cats with and without a murmur ($n = 20$, Fig 4B). Similarly, ESCO had a statistically significant effect, both with regard to the percentage

P-selectin-positive ($n = 20$, Fig 5A) and P-selectin MFI of unstimulated (resting) platelets ($n = 20$, Fig 5B).

Soluble Platelet-Endothelial Cell Adhesion Molecule-1

sPECAM-1 relative concentration in the plasma of our study population were evaluated by Western blot using an affinity purified polyclonal antibody to sPECAM-1. Densitometry was performed to evaluate the relative extent of expression plasma sPECAM-1. Interestingly, there were significant differences in the relative means concentrations of sPECAM-1 between control cats and cats with either moderate or severe HCM ($n = 44$, Fig 6). There was no correlation between the genotype (cats with the A31P mutation in myosin binding protein C) and sPECAM-1 plasma expression, nor was there any correlation between ESCO and sPECAM-1 expressions.

Plasma Fibrinogen Concentrations

We found no significant differences in fibrinogen concentrations between control cats and the cats with equivocal, moderate, and severe HCM. All fibrinogen concentrations were within the normal reference intervals of our clinical laboratory.

Discussion

Our study showed that unstimulated (resting) platelets from cats with severe HCM had significantly increased activation as measured by surface expression of P-selectin. Stimulation of platelets from these cats with the physiological agonist ADP resulted in increased P-selectin expression (MFI) compared to control cats. This increase in MFI likely is the result of increased numbers of secreted alpha granules, and has been suggested to be a more sensitive indicator of activation than the percentage of positive cells.²⁶ Platelets from cats with severe HCM also had increased numbers of CD41-positive microvesicles, another indicator of platelet activation. The presence of a heart murmur as well as ESCO in cats with HCM correlated with increased P-selectin expression on the platelet surface. sPECAM-1 expression also was significantly increased in cats with moderate and severe HCM.

Platelet P-selectin is localized to the membranes of alpha granules and only is expressed on the platelet surface after alpha granule secretion, where it plays a key role in stabilizing platelet-platelet aggregates that are formed initially by the interaction of fibrinogen and $\alpha 2\text{b}\beta 3\text{a}$ integrin.²⁷ Under conditions that activate platelets and promote platelet-endothelial interaction, P-selectin also tethers platelets to leukocytes by platelet P-selectin and leukocyte P-selectin glycoprotein ligand-I.²⁸⁻³⁰ These interactions can result in the development of a more stable platelet-leukocyte complex as well as promoting the adhesion and recruitment of leukocytes to the endothelium. Recruitment of leukocytes to damaged endothelium by P-selectin

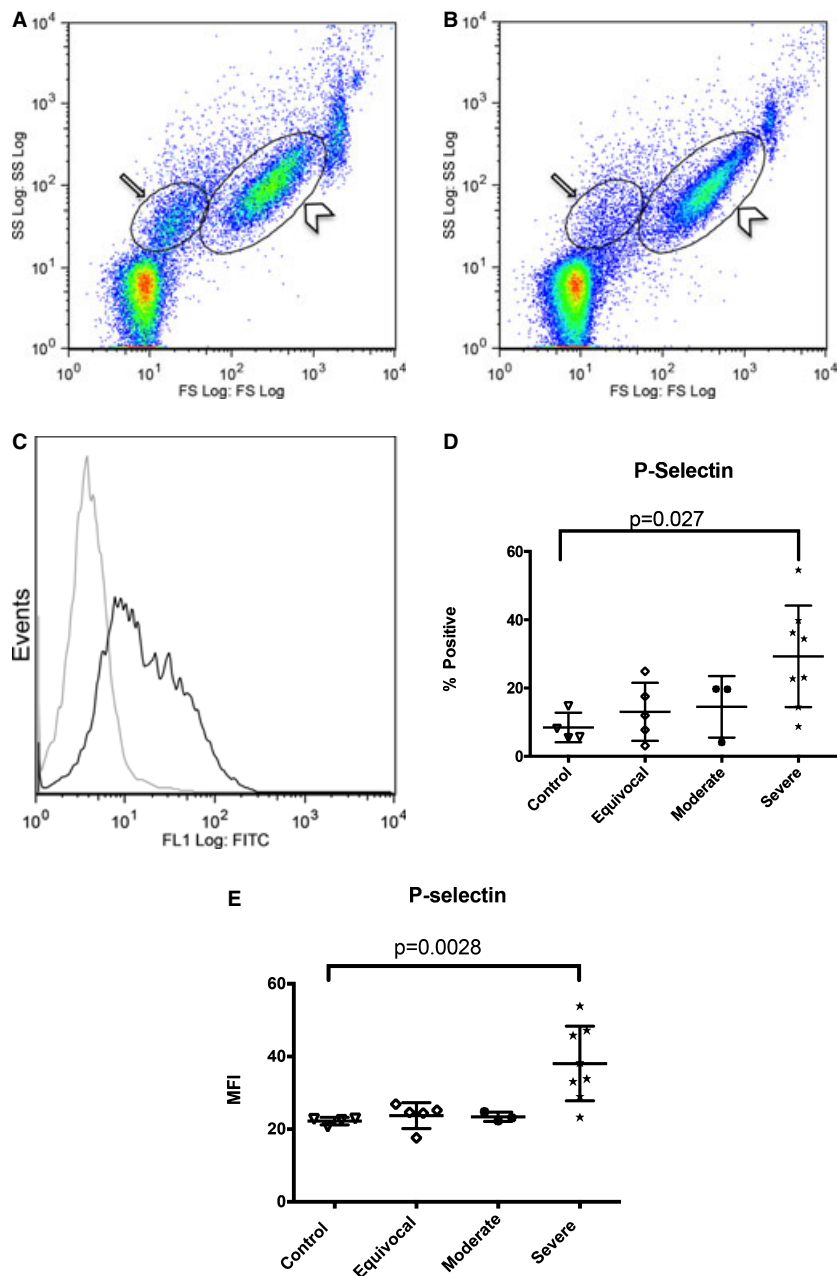


Fig 1. (A, B) Representative forward scatter and side scatter images of resting control platelets (A) and resting platelets from a cat with severe hypertrophic cardiomyopathy (HCM) (B). Black oval (\rightarrow) delineates the microvesicle population as defined by 0.5 μm -standardized beads, while the larger black oval to the right (\rightarrow) represents the platelet population. (C) Representative histograms of resting platelets from a control cat (light gray) and a cat with severe HCM (black) demonstrating the significant increase in platelet P-selectin expression in cats with severe HCM. (D) Flow cytometric analysis of P-selectin-positive platelets demonstrates a significant difference between P-selectin-positive platelets in control cats and cats with severe HCM ($P = .0275$). (E) Platelets from cats with severe HCM have a higher mean fluorescence intensities of P-selectin on their surface than platelets from control cats ($P = .0028$).

and the generation of leukocyte-derived microparticles mediate the generation of fibrin.³¹ Studies in P-selectin knockout mice showed prolonged bleeding times and increased hemorrhage in response to trauma, providing further evidence for the role of this selectin in hemostasis.³² These and other studies suggest that P-selectin serves as a critical regulator of hemostasis by capture of leukocyte-derived microparticles, result-

ing in the recruitment of tissue factor into developing thrombi.³³

Plasma sPECAM-1 may be derived from multiple sources including, but not limited to, platelets and endothelial cells. In platelets, PECAM-1 is present both in alpha granules as well as on the platelet plasma membrane.³⁴ In endothelial cells, the molecule is located on the plasma membrane and is

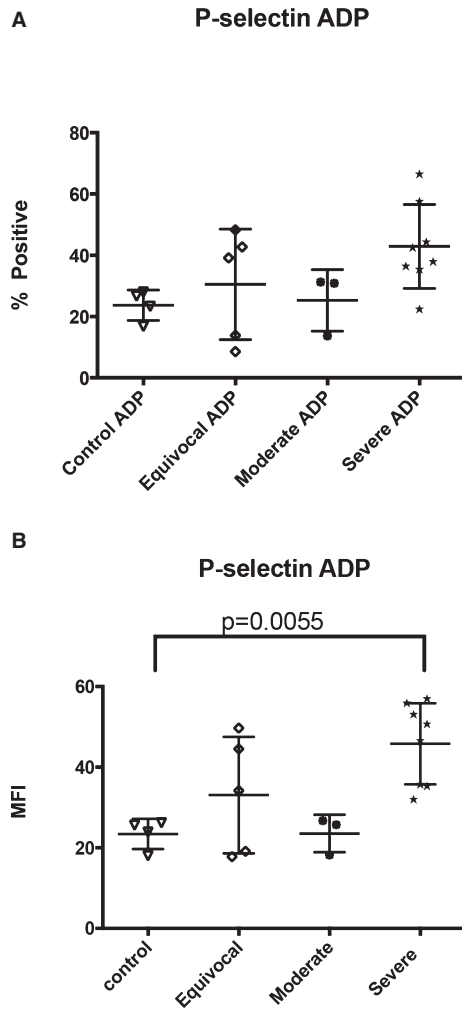


Fig 2. (A) When platelets are stimulated with the physiologic agonist adenosine diphosphate, there were no statistically significant differences in the percentage of P-selectin-positive platelets between any of the groups. (B) There were statistically significant differences in mean fluorescence intensities (MFI), and platelets from cats with severe hypertrophic cardiomyopathy had higher P-selectin MFI on their surface than did control cats ($P = .0055$).

concentrated at endothelial cell-cell junctions. In both platelets and endothelial cells, PECAM-1 is shed into the plasma after proteolytic cleavage of its ectodomain. sPECAM-1 is consistently and significantly increased in humans with acute myocardial infarction, as well as in patients with congestive heart failure independent of disease origin.^{35,36} Similar results have been documented by Soeki et al, who suggested that increased sPECAM-1 concentrations may be a sensitive marker for the early diagnosis of acute cardiac disease in humans.³⁵ PECAM-1 has been shown to have proinflammatory activity through the promotion of leukocyte-endothelial translocation and transmission of systemic signals associated with endothelial stress.³⁷ Unlike platelet P-selectin, which supports neutrophil-platelet and platelet-endothelial interactions, platelet PECAM is an inhibitory molecule that has been

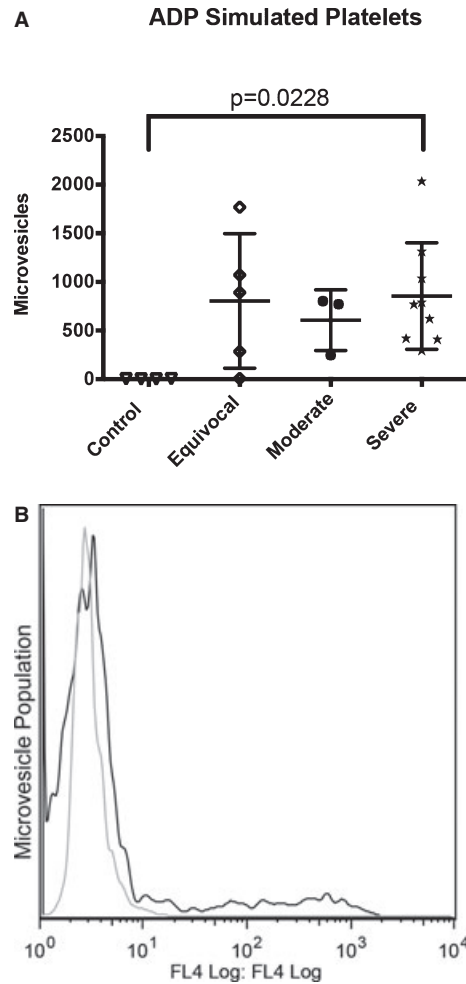


Fig 3. (A) When platelets were stimulated with adenosine diphosphate (ADP), cats with severe hypertrophic cardiomyopathy (HCM) expressed greater numbers of CD41-positive microvesicles than did control cats ($P = .0228$). (B) Representative histograms of ADP-activated platelets from a control cat (light gray) and a cat with severe HCM (black) demonstrating the significant increase in CD41-positive microvesicles in cats with severe HCM.

proposed to limit thrombus formation by limiting platelet-platelet interactions as well as platelet adhesion to collagen.^{34,38,39} These studies have suggested that PECAM-1 serves to regulate thrombus formation and thereby inhibit vessel occlusion. We suggest that the significantly increased concentrations of sPECAM-1 in cats with moderate and severe HCM may serve as early markers of heart disease, similar to what has been observed in humans.⁴⁰ Furthermore, we cannot rule out the possibility that the increases in sPECAM-1 seen in cats with severe HCM are a systemic response to a procoagulant state, as suggested by the significant increases in P-selectin expression and microvesicle production.

This study had some limitations. Increased concentrations of sPECAM-1 in the plasma of cats with HCM may not be related to platelet activation, but

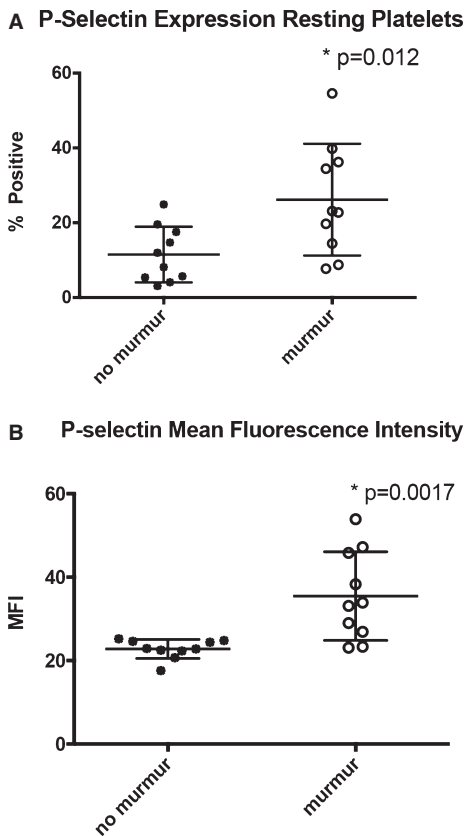


Fig 4. (A) There was a significant increase in P-selectin-positive platelets in cats with murmurs ($P = .011$). (B) Platelets from cats with heart murmurs had significantly increased P-selectin mean fluorescence intensities on their surface ($P = .0017$).

instead could be because of damaged or inflamed endothelium where sPECAM-1 is associated with leukocyte migration. Given that increased inflammatory mediators such as interleukin-6 and tumor necrosis factor- α have been shown to be present in congestive heart failure in humans,⁴¹ increased sPECAM-1 may reflect chronic inflammation and long-term endothelial damage.¹⁰ An additional limitation is the lack of Maine Coon control cats, as well as the small numbers of cats with moderately severe HCM that were available for flow cytometry studies. Also, not all HCM colony cats were purebred Maine Coon cats, and the control group did not contain Maine Coon cats, thus it is not possible to exclude breed specific differences as an alternative explanation for the differences between control and HCM groups. Since P-selectin results were only significantly different between control cats and cats with severe HCM, the data suggest that the difference is likely HCM-related, rather than breed-related. Similarly, sPECAM-1 results only were significantly increased in cats with moderate and severe HCM, also suggesting that differences are not a breed effect.

In conclusion, our study shows that there is an association between biomarkers of platelet activation (P-selectin and sPECAM-1) and HCM. Specifically,

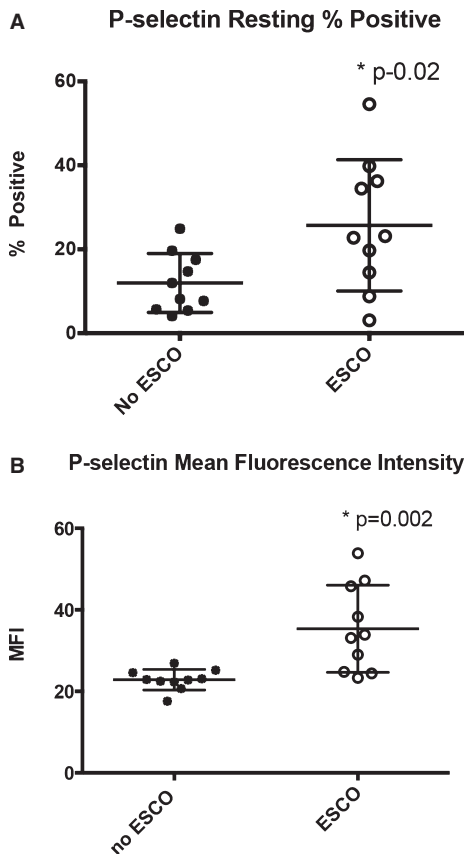


Fig 5. (A) Cats that had end-systolic cavity obliteration (ESCO) on ultrasound examination expressed more P-selectin-positive cells ($P = .02$). (B) Cats that had ESCO on ultrasound examination also had a higher mean fluorescence intensities of P-selectin on the cell surface ($P = .002$).

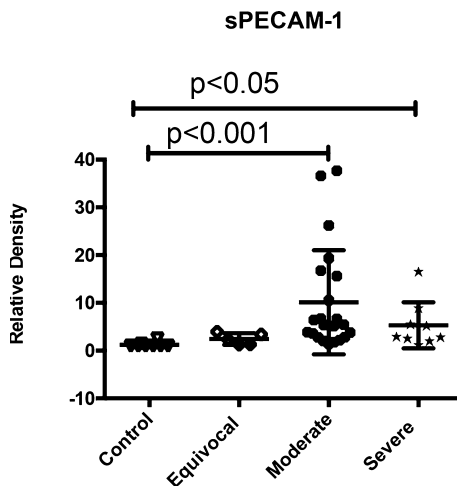


Fig 6. Mean relative densities of soluble platelet-endothelial cell adhesion molecule-1 from cats with moderate and severe hypertrophic cardiomyopathy were significantly higher than those of controls ($P \leq .001$ and $P \leq .05$, respectively).

P-selectin expression is increased in cats with severe HCM as well as in those with a heart murmur and in those with ESCO, suggesting that platelets from cats

with HCM are procoagulant and that those cats maybe at higher risk for ATE.

Footnotes

- ^a Coulter ACT Diff, Beckman-Coulter Inc, Miami, FL
^b BD Pharmingen, BD Biosciences, San Jose, CA
^c eBioscience, San Diego, CA
^d Invitrogen, Carlsbad, CA
^e Beckman-Coulter FC500 Flow Cytometer, Beckman-Coulter Inc
^f FlowJo, Tree Star Inc, Ashland, OR
^g Megamix, BioCytex, France
^h R&D Systems, Minneapolis, MN
ⁱ Biospectrum Imaging System, UVB Corp, Upland, CA
^j Lumi-light plus chemiluminescent substrate, Roche Applied Sciences, Switzerland
^k Image J, National Institutes of Health, Bethesda, MD
^l GraphPad Prism, GraphPad Software Inc, San Diego, CA
-

Acknowledgments

The work was supported by a grant #D08FE-056 from the Morris Animal Foundation to Dr Fern Tablin.

Portions of this work were presented by Katharine Huang at a UC Davis School of Veterinary Medicine STARS in Science meeting 2007; and by Karl Jandrey at the 2009 American College of Veterinary Internal Medicine Forum & Canadian Veterinary Medical Association Convention, Montreal, Quebec, Canada; and the Pacific Veterinary Conference 2013.

Conflict of Interest: The authors disclose no conflict of interest.

References

- Longeri M, Ferrari P, Knafelz P, et al. Myosin-binding protein C DNA variants in domestic cats (A31P, A74T, R820W) and their association with hypertrophic cardiomyopathy. *J Vet Intern Med* 2013;27:275–285.
- Meurs KM, Norgard MM, Kuan M, et al. Analysis of 8 sarcomeric candidate genes for feline hypertrophic cardiomyopathy mutations in cats with hypertrophic cardiomyopathy. *J Vet Intern Med* 2009;23:840–843.
- Meurs KM, Norgard MM, Ederer MM, et al. A substitution mutation in the myosin binding protein C gene in Ragdoll hypertrophic cardiomyopathy. *Genomics* 2007;90:261–264.
- Abbott JA. Feline hypertrophic cardiomyopathy: An update. *Vet Clin Small Anim* 2010;40:687–700.
- Kittleson MD, Meurs KM, Munro MJ, et al. Familial hypertrophic cardiomyopathy in Maine Coon cats: An animal model of human disease. *Circulation* 1999;99:3172–3180.
- Virchow R. Neuer Fall von toedlicher Embolie der Lungenarterien. *Arch Pathol Anat* 1856;10:225–229.
- Liu SK. Acquired cardiac lesions leading to congestive heart failure in the cat. *Am J Vet Res* 1971;31:2071–2088.
- Schober KE, Maerz M. Assessment of left atrial appendage flow velocity and its relationship to spontaneous echocardiographic contrast in 89 cats with myocardial disease. *J Vet Intern Med* 2006;20:120–130.
- MacDonald KA, Kittleson MD, Garcia-Nolan T, et al. Tissue Doppler imaging and graduate echo cardiac magnetic resonance imaging in normal cats and cats with hypertrophic cardiomyopathy. *J Vet Intern Med* 2006;20:627–634.
- Cambronero F, Marin F, Roldan V, et al. Biomarkers of pathophysiology in hypertrophic cardiomyopathy: Implications for clinical management and prognosis. *Eur Heart J* 2009;30:139–151.
- Riazanov AS, Gabbasov ZA, Iurenev AP. Platelet aggregation in patients with hypertrophic cardiomyopathy. *Ter Arkh* 2000;72:36–38.
- Icli A, Aksoy F, Dogan A, et al. Increased mean platelet volume in hypertrophic cardiomyopathy. *Angiology* 2013 Apr 5 (Epub ahead of print)
- Yarom R, Lewis BS, Lijovetsky G, et al. Platelet studies in patients with hypertrophic cardiomyopathy. *Cardiovasc Res* 1982;16:324–330.
- Weikert U, Kuhl U, Schultheiss HP, Tauch U. Platelet activation is increased in patients with cardiomyopathy: Myocardial inflammation and platelet reactivity. *Platelets* 2002;13:487–491.
- Tse H-F, Lau C-P, Cheng G. Relation between mitral regurgitation and platelet activation. *J Am Coll Cardiol* 1997;30:1813–1818.
- Nesbitt WS, Weinstein E, Tovar-Lopez FJ, et al. A shear gradient-dependent platelet aggregation mechanism drives thrombus formation. *Nat Med* 2009;15:665–673.
- Holme PA, Orvim U, Hamers MJ, et al. Shear-induced platelet activation and platelet microparticle formation at blood flow conditions as in arteries with a severe stenosis. *Arterioscler Thromb Vasc Biol* 1997;17:646–653.
- Bedard C, Lanevski-Pietersma A, Dunn M. Evaluation of coagulation markers in the plasma of healthy cats and cats with asymptomatic hypertrophic cardiomyopathy. *Vet Clin Pathol* 2007;36:79–84.
- Helenski CA, Ross JN. Platelet aggregation in feline cardiomyopathy. *J Vet Internal Med* 1987;1:24–28.
- Welles EG, Boudreau MK, Crager CS, et al. Platelet function and anti-thrombin, plasminogen and fibrinolytic activities in cats with heart disease. *Am J Vet Res* 1994;55:619–627.
- Hsu A, Kittleson MD, Paling A. Investigation into the use of plasma NT-proBNP concentration to screen for feline hypertrophic cardiomyopathy. *J Vet Cardiol* 2009;S1:S63–S70.
- Robert S, Poncelet P, Lacroix R, et al. Standardization of platelet-derived microparticle counting using calibrated beads and a Cytomics FC500 routine flow cytometer: A first step towards multicenter studies? *J Thromb Haemostasis* 2008;7:190–197.
- Clauss A. Gerinnungsphysiologische schnellmethode zur bestimmung des fibrinogens. *Acta Haematol* 1957;17:237–246.
- Norris JW, Pratt SM, Hunter JF, et al. Prevalence of reduced fibrinogen binding to platelets in a population of Thoroughbreds. *Am J Vet Res* 2007;68:716–721.
- Norris JW, Pratt SM, Auh JH, et al. Investigation of a novel, heritable bleeding diathesis of Thoroughbred horses and development of a screening assay. *J Vet Intern Med* 2006;20:1450–1456.
- Ramstrom AS, Fagerberg I, Lindahl T. A flow cytometric assay for the study of dense granule storage and release in human platelets. *Platelets* 1999;2:153–158.
- Merten M, Thiagarajan P. P-selectin expression on platelets determines size and stability of platelet aggregates. *Circulation* 2000;102:1931–1936.
- Lehr HA, Olofsson AM, Carew TE, et al. P-selectin mediates the interaction of circulating leukocytes with platelets and microvascular endothelium in response to oxidized lipoprotein in vivo. *Lab Invest* 1994;71:380–386.

29. Kirton CM, Nash GB. Activated platelets adherent to an intact endothelial cell monolayer bind flowing neutrophils and enable them to transfer to the endothelial surface. *J Lab Clin Med* 2000;136:303–313.
30. Isenberg WM, McEver RP, Shuman MA, Bainton DF. Topographic distribution of a granule membrane protein (GMP-140) that is expressed on the platelet surface after activation: An immunogold-surface replica study. *Blood Cells* 1994;12:191–204.
31. Palabrica T, Lobb R, Furie BC, et al. Leukocyte accumulation promoting fibrin deposition is mediated in vivo by P-selectin on adherent platelets. *Nature* 1992;359:848–851.
32. Mayadas TN, Johnson RC, Rayburn H, et al. Leukocyte rolling and extravasation are severely compromised in P-selectin deficient mice. *Cell* 1993;13:541–554.
33. Cambien B, Wagner DD. A new role in hemostasis for the adhesion receptor P-selectin. *Trends Mol Med* 2004;10:179–186.
34. Patil S, Newman DK, Newman PJ. Platelet endothelial cell adhesion molecule-1 serves as an inhibitory receptor that modulates platelet responses to collagen. *Blood* 2001;97:1727–1732.
35. Serebruany VL, Murugesan SR, Pothula A, et al. Increased soluble platelet-endothelial cell adhesion molecule -1 and osteonectin levels in patients with severe congestive heart failure. Independence of disease etiology, and antecedent aspirin therapy. *Eur J Heart Failure* 1999;1:243–249.
36. Serebruany VL, Murugesan SR, Pothula A, et al. Soluble PECAM-1, but not P-selectin nor osteonectin identify acute myocardial infarction in patients presenting with chest pain. *Cardiology* 1999;91:50–55.
37. Privratsky JR, Newman DK, Newman PJ. PECAM-1: Conflicts of interest in inflammation. *Life Sci* 2010;87:69–82.
38. Zhang JJ, Kelm RJ, Biswas P, et al. PECAM-1 modulates thrombin-induced tissue factor expression on endothelial cells. *J Cell Physiol* 2007;210:527–537.
39. Ming Z, Hu Y, Xiang J, et al. Lyn and PECAM-1 function as interdependent inhibitors of platelet aggregation. *Blood* 2011;117:3903–3906.
40. Soeki T, Yamura Y, Shinohara H, et al. Increased soluble platelet/endothelial cell adhesion molecule-1 in the early stages of acute coronary syndromes. *Int J Cardiol* 2003;90:261–268.
41. Hogue M, Mandi Y, Csanady M, et al. Comparison of circulating levels of interleukin-6 and tumor necrosis factor-alpha in hypertrophic cardiomyopathy and in idiopathic dilated cardiomyopathy. *Am J Cardiol* 2004;94:249–251.