

# Step-by-step full mouth rehabilitation of a nasopharyngeal carcinoma patient with tooth and implant-supported prostheses: A clinical report

MARZIEH ALIKHASI, MAHMOOD KAZEMI,<sup>1</sup> SAEED NOKAR,<sup>1</sup> ARASH KHOJASTEH,<sup>2</sup> SEDIGHEH SHEIKHZADEH<sup>3</sup>

## Abstract

This clinical report presents a 46-year-old man diagnosed with nasopharyngeal carcinoma with the chief complaint of masticatory and speech deficiency because of radiation therapy. After a period of controlling post radiation caries, the patient was rehabilitated with tooth and implant supported metal ceramic restorations following surgical and endodontic intervention.

**Keywords:** Case report, implant-supported prostheses, nasopharyngeal carcinoma, oral rehabilitation

## Introduction

Nasopharyngeal carcinoma (NPC) refers to a group of tumors originating from lymphoid tissues. NPC shows three categories based on histological examination. The first symptom in half of the patients is cervical lymphadenopathy which represents a metastatic tumor. Although rare in most parts of the world, NPC is very common in southern China and Southeast Asia. NPC is associated with Epstein-Barr virus infection, and other probable etiological factors are smoking and occupational exposure to wood, intake of some kinds of food specially the ones containing nitrosamines such as salted fish.<sup>[1,2]</sup>

Treatment plan for NPC patients varies from radiotherapy alone in primary lesions to adjuvant chemotherapy in advanced ones. Radiotherapy is one of the most common treatments for head and neck malignancies. Exposure period and total treatment dose are both important factors in treating early stage NPC. Decreasing the total radiation time to less than 12 weeks and not exceeding a radiation

dose of 75 Gy has proved to show the best results.<sup>[3]</sup> In such cases, results are comparable to those obtained with surgery because NPC early lesions are very sensitive to radiation.<sup>[4]</sup> Although radiotherapy is preferred to surgery in early stages of treatment of NPCs as it renders more chances of tissue preservation, it exerts complications in sensitive structures such as the oral mucosa, salivary glands, dentition and jaws.

Trismus is one of the common side effects after radiotherapy and chances for it are 8% to 38%.<sup>[5,6]</sup> It can be the result of scar formation or tissue fibrosis and muscle spasm.<sup>[7,8]</sup> Limited mouth opening can interfere with patient's daily activities and compromise the quality of life. Dental malpractice is also a sequel of this limitation because the practitioner would not have enough accessibility during dental treatments.

Irradiation can also damage the salivary glands and consequently xerostomia occurs. Xerostomia starts as soon as patients receive the first fractions of radiotherapy and can last up to 2 years.<sup>[9]</sup> Xerostomia can also cause discomfort especially in denture wearers.<sup>[10]</sup> Reduced salivary flow rate can develop an increased incident of radiation caries affecting incisal and cervical parts of teeth.<sup>[11]</sup>

Dentists being part of the management team for NPC patients can play a significant role. The dental treatments to these patients have to be done both before and after the radiation. Pretreatment dental evaluation is consisted of full clinical and radiographical evaluation. Dental practitioners must omit infection sources since the risk of new infection is high due to the compromised host defense after cancer therapy.<sup>[12]</sup> There is also an increased risk of radio necrosis in the first few months after radiotherapy. Therefore, unrestorable teeth must be extracted before the radiation. The dentists should describe the condition and explain the post radiation complications to the patients to provide more compliance.

During the time patients are undergoing radiotherapy, dentists must control acute infections and avoid invasive dental procedures as possible.<sup>[12]</sup> At the time irradiation

*Departments of Dental Research and Prosthodontics,  
1Prosthodontics, and 3Dental Research, School of Dentistry,  
Tehran University of Medical Sciences, 2Department of Oral and  
Maxillofacial Surgery, Taleghani Hospital, Beheshti University of  
Medical Sciences, Tehran, Iran*

**Correspondence:** Ms. Sedigheh Sheikhzadeh, Department of Dental Research, School of Dentistry, Tehran University of Medical Sciences, North Amirabad St., Tehran, Iran.  
E-mail: elfsh@yahoo.com

Access this article online	
Quick Response Code: 	Website: <a href="http://www.contempclindent.org">www.contempclindent.org</a>
	DOI: 10.4103/0976-237X.86489

therapy for NPC comes to end, patients need different sorts of dental treatments due to extensive caries caused by decreased salivary flow and poor oral hygiene as a sequence of compromised medical status. Some dental materials including resin-modified glass-ionomer, compomers, and fluoride-releasing resin composites could be effective in preventing secondary caries.<sup>[13-15]</sup> However, it should be emphasized that maintaining oral hygiene and patient's diet surveying are important aspects of treatment. Fluoride supplements are effective in reducing secondary caries and the patient should be asked to use it regularly.

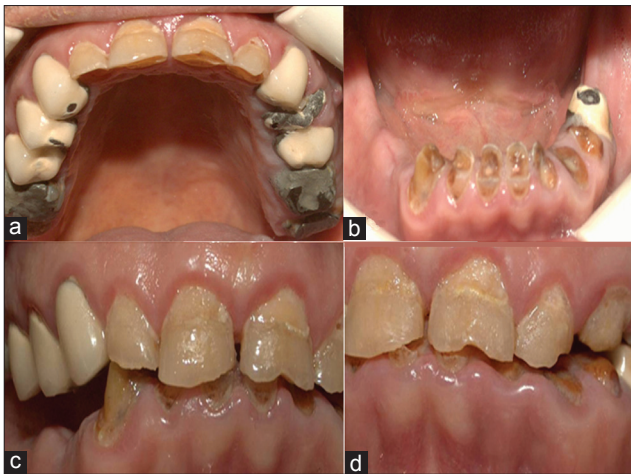The patients who have received radiotherapy usually need full mouth rehabilitations since most of them have had their unrestorable teeth extracted before and after the radiotherapy to prevent various side effects. The limited mouth opening in these patients also causes challenges in choosing the type of the prosthetic treatment plan.

This article describes a sequential approach to the interdisciplinary treatment of a partially edentulous patient with excessive tooth tissue loss in a 46-year-old man with a history of radiotherapy and chemotherapy. Excessive tooth loss was attributed to post radiation xerostomia and iatrogenic imperfect treatments.

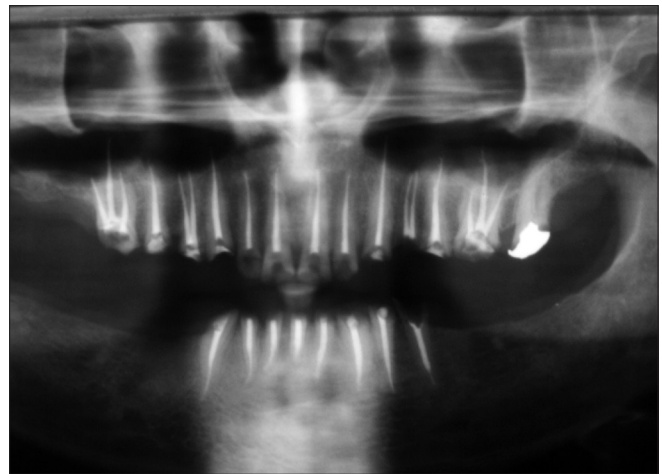
## Case Report

A 46-year-old man presented to the Department of Prosthodontics at Tehran University, School of Dentistry. His chief complaint was deficiency in speech and mastication. His past medical history revealed that he has been under treatment for undifferentiated nasopharyngeal carcinoma of neck (NPC). Surgery included a local tumor resection and lymph node dissection. Radiotherapy was accomplished within 100 days postoperatively. He was irradiated with 60 Gray (Gy), at single doses of 2 Gy. Radiotherapy parameters, such as radiation dose and technique used, were recorded. The patient had no muscle tenderness or facial asymmetry and denied any symptoms of temporomandibular joint disorder or myofascial pain dysfunction. Functional manipulation did not show any sign of parafunction, but mandibular range of motion was not within normal limits and there was obvious limitation in mouth opening (30 mm). Intraoral palpation showed submucosal fibrosis like condition of oral mucosa. The saliva was thick and mucous and there was generalized caries and recurrent caries throughout dentition. Clinical examination revealed missing of mandibular posterior teeth except left first and second premolars. All the teeth except maxillary incisors and first right premolar had received endodontic treatment, though all were faulty treatments and needed retreatment. The maxillary left and right canines, first and second premolars and mandibular left second premolar had complete coverage crowns [Figure 1]. Marginal opening of all complete crowns and breakdown and leakage of these restorations were noted.

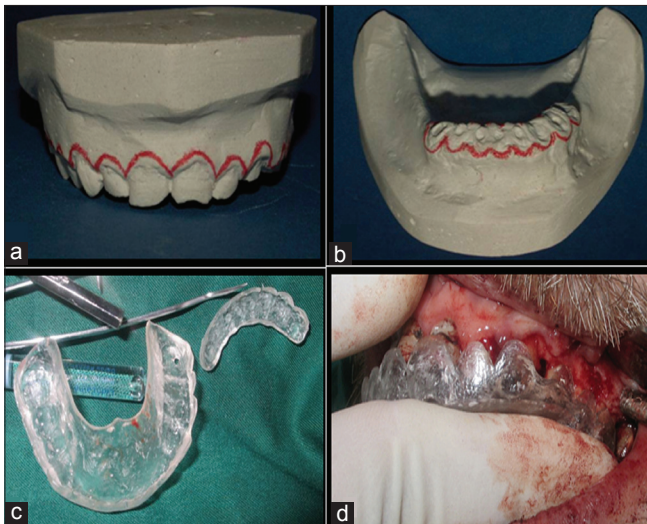
Defective amalgam restorations with marginal breakdown and recurrent caries were present in teeth # 3, 14, and 15, and defective composite restorations with marginal leakage were present in teeth # 8, 9, and 10. The patient exhibited generalized mild gingivitis and minimal bleeding on probing. The patient was referred to the ENT department for evaluation. However, his medical consultation reported that he did not have any current signs or symptoms of NPC. Treatment plan options (fixed versus removable) were presented to the patient. However, considering the patient's desires, complete mouth rehabilitation with tooth and implant supported metal ceramic restorations was suggested. However, the first step was controlling caries. Therefore, diet evaluation was performed and he received daily fluoride treatment with a custom-made carrier and 0.4% stannous fluoride gel. Besides diet survey and diet modification, oral health instruction including informing the patient about disease etiology and oral hygiene instruction, evaluation of salivary flow, and prescribing xylitol products were carried out for the patient. Endodontic treatment and retreatment were done for all the remaining teeth except maxillary second left molar. This tooth was extracted because of limited mouth opening and therefore limited access to it [Figure 2]. The treatment plan included initial preparation and caries removal and complete mouth clinical crown lengthening surgical procedures to expose 1.5 to 2 mm of tooth structure circumferentially for adequate ferrule for resistance and retention forms and to facilitate esthetic gingival levels. Since there was no acceptable posterior support, the diagnostic phase involved a removable diagnostic overdenture. This phase also helped determining the length of teeth and evaluating phonetics and esthetics. After the removal of failing restorations and caries removal, primary impressions were made and esthetic clinical crown lengthening was designed on the diagnostic casts. Then a diagnostic wax up was done and a vacuum formed surgical template was fabricated as a reference for the prospective desired gingival levels during the crown lengthening surgical procedures. Full-thickness flaps with scalloped incisions were elevated to preserve interdental papillae [Figure 3]. Osteotomy was performed according to surgical templates to develop 2.0 mm of biological width and 1.0 mm of sulcular depth. Tooth #12 was extracted during crown lengthening procedure because of vertical root fracture. A centric relation record was obtained with record bases and occlusion rims using an interocclusal registration material (Virtual; Ivoclar Vivadent, Schaan, Liechtenstein). The casts were transferred into a semi-adjustable articulator (Dentatus ARH, Stockholm, Sweden) by the centric relation record. Prosthetic teeth (Major; Major Prodotti Dentari, Torino, Italy) were arranged for trial insertion. The overlay denture was processed and was adjusted on the remaining teeth [Figure 4]. A radiographic stent for implants was fabricated (lucitone clear resin) by duplicating the overlay denture and coating its teeth surface with barium sulfate. Then, tomographic radiographs were taken to check bone height and width and proper implant



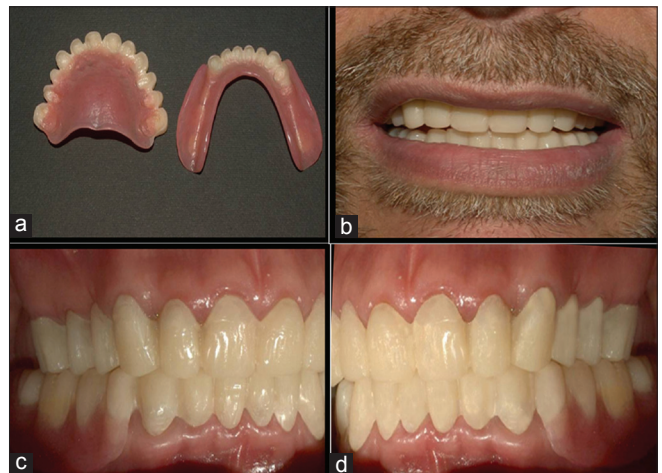
**Figure 1:** Intraoral view of pretreatment dental situation: (a, b) occlusal views. (c, d) Left and right lateral views



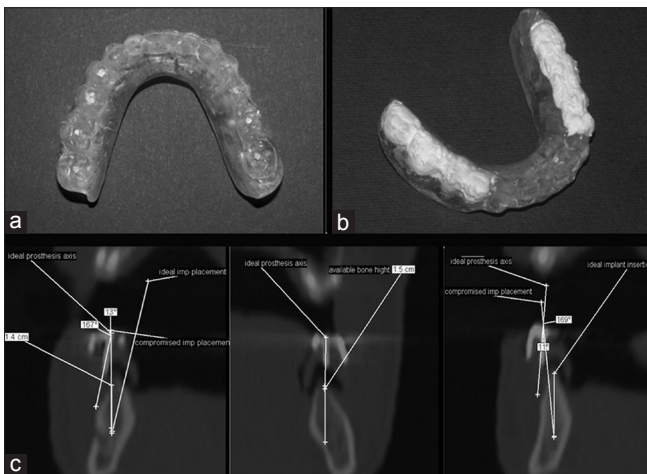
**Figure 2:** Panoramic radiograph after endodontic treatments



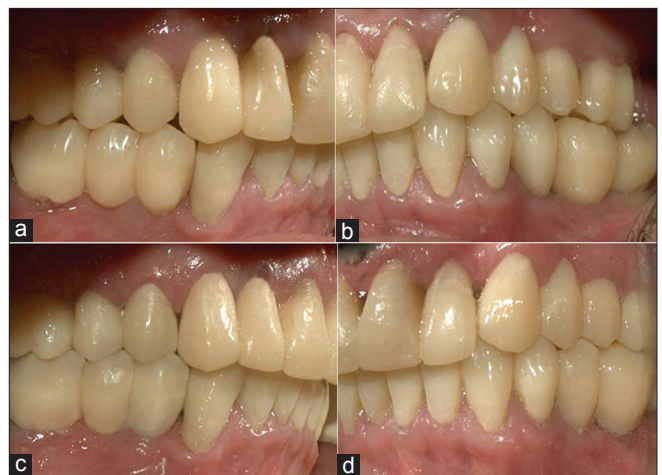**Figure 3:** Crown lengthening procedure. (a, b): Maxillary and mandibular diagnostic casts; (c) Surgical templates; (d) Elevation of full thickness flap with scalloped incisions



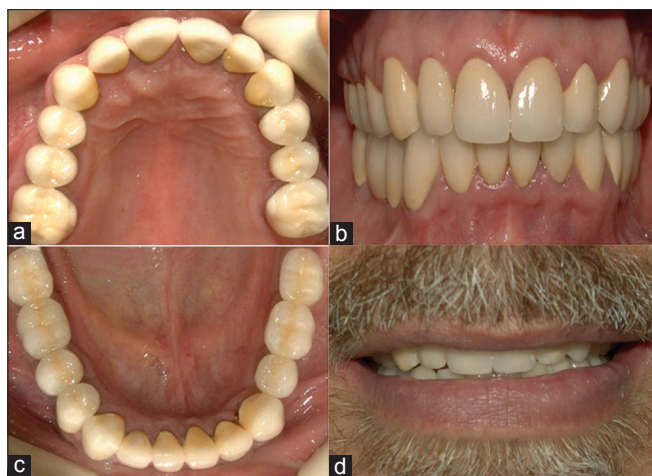**Figure 4:** (a) The overlay denture; (b, c, d): Adjustment of the overlay denture on the remaining teeth



**Figure 5:** (a, b): Radiographic templates; (c) Evaluation of available bone in tomographic radiographs



**Figure 6:** Progressive bone loading. (a) Right posterior temporary restorations out of occlusion; (b) Left posterior temporary restorations out of occlusion; (c) Three weeks later, temporary restorations in occlusion except pontic; (d) Three weeks later, full occlusal contact



**Figure 7:** Clinical view of post-treatment dentition. (a, b) occlusal views of maxilla and mandible; (c) Frontal view; (d) Smile view

position [Figure 5]. Two 4.1 × 10 mm endosteal dental implants (Institut Straumann AG, Waldenburg, Switzerland) were placed in each posterior mandibular quadrant using the surgical guide. All implants were inserted under local anesthesia and were inserted primarily stable. Bulky flaps were thinned in the same session. The following 5 days, 250 mg of cefuroxim (Elobacts, Bad Oldeslohe, Cascan, Germany) was given twice orally and patients rinsed their mouth twice daily with 3% hydrogen peroxide; no specific diet was followed. After 5 weeks, the stability was tested with Osstell (Integration Diagnostics, Gothenburg, Sweden). The teeth were prepared and custom post patterns were fabricated according to a vacuum silicon guide made over overlay dentures. After finalizing cast post in the all remaining teeth, impressions were made of maxillary and mandibular arches. This impression in mandible not only record prepared teeth, but also was an implant level impression. For transferring the exact maxillo mandibular relationship established with overlay dentures to the final fixed restoration, the anterior section of the overlays were removed so that Lucia jig could be made between incisors at the existing vertical dimension of occlusion (VDO). Then, the centric relation was made between posterior maxillary prepared teeth and mandibular record base along with cross mounting with cast made of over impressions of overlay dentures. A custom incisal guide table was made from GC pattern resin (GC America) while overlay dentures were on the articulator. Waxing was done according to the customized guide table on die casts and converted to heat-processed acrylic temporary restorations. The diagnostic interim restorations were modified until the patient was satisfied with phonetics, esthetics, and function. During the evaluation period, the patient's anterior and posterior speaking space and function was assessed. Furthermore, these restorations were used for progressive loading of implants. Acrylic restorations on the implants first were made without occlusal contact, with occlusal contact

on the abutments 4 weeks later, and full occlusal contact on the abutments and pontic after 8 weeks. The interim restorations were functioned for about 4 months to assess the patient's adaptation to the proposed new vertical dimension of occlusion and the new clinical crown lengths [Figure 6]. Subsequently, the gingival tissue around the tooth preparations had matured and definitive impressions were made with vinyl polysiloxane impression material (Affinis; Coltène/Whaledent, Inc, Cuyahoga Falls, Ohio). The maxillary and mandibular anterior teeth were restored with definitive restorations. Centric occlusion, even protrusive contacts, and canine guidance were established in the definitive anterior restoration. The complete crowns and fixed partial dentures (FPD) were prepared and completed. Crowns were cast with a gold alloy. After the fit of the cast crowns was verified intraorally, metal-ceramic restorations were completed (Omega 900; VITA Zahnfabrik, Bad Sackingen, Germany). All crowns were cemented with temporary cement. A heat processed hard occlusal guard (Lucitone Clear, Dentsply, York, PA, USA) was delivered to evaluate the patient's tolerance of new VDO and providing the patient with a mutually protected occlusion [Figure 7]. Following the definitive cementation of all restorations, neutral pH sodium fluoride (Previ Dent 1.1% Brush-On Gel; Colgate Oral Pharmaceuticals, New York, NY) was prescribed to prevent secondary decay under the restorations. The patient was advised to return every 6 months for a recall evaluation. The patient was satisfied with the improved esthetics and function of his teeth. The patient has been followed for 8 months since the completion of his treatment and remains free of any complications. Additional instruction was given on the use of floss threaders and superfloss under the FPD.

## Discussion

Radiotherapy in NPC patients has dramatic effects on their quality of life. Rehabilitation of NPC patients involves several steps among which preventive measures such as oral hygiene instruction and diet survey are very important. As a sequel of xerostomia, not only there is an increased risk of caries, but also treatment plan is also affected. In these patients, the routine prosthetic treatments are not often successful because of reduced surface tension between mucosa and prosthesis.<sup>[15]</sup> Therefore, implant-supported prosthesis would be of choice and has demonstrated its efficacy and seems to be reliable.<sup>[16-18]</sup> However, dosage and healing time after radiotherapy are significant factors to indicate implant in these patients.<sup>[19,20]</sup> Treatment of this case involved successful restorative treatment after a 3-month period of preventive evaluation phase.

## References

1. Chapman KE, Patton LL. Nasopharyngeal carcinoma: A 15-year retrospective study. *Spec Care Dentist* 1993;13:163-70.
2. Hildesheim A, Dosemeci M, Chan CC, Chen CJ, Cheng YJ, Hsu

- MM, *et al.* Occupational exposure to wood, formaldehyde, and solvents and risk of nasopharyngeal carcinoma. *Cancer Epidemiol Biomarkers Prev* 2001;10:1145-53.
3. Chang JT, See LC, Liao CT, Chen LH, Leung WM, Chen SW, *et al.* Early stage nasopharyngeal carcinoma: Radiotherapy dose and time factors in tumor control. *Jpn J Clin Oncol* 1998;28:207-13.
  4. Caponigro F, Longo F, Ionna F, Perri F. Treatment approaches to nasopharyngeal carcinoma: A review. *Anticancer Drugs* 2010;21:471-7.
  5. Steelman R, Sokol J. Quantification of trismus following irradiation of the temporomandibular joint. *Mo Dent J* 1986;66:21-3.
  6. Thomas F, Ozanne F, Mamelie G, Wibault P, Eschwege F. Radiotherapy alone for oropharyngeal carcinomas: the role of fraction size (2 Gy. vs 2.5 Gy.) on local control and early and late complications. *Int J Radiat Oncol Biol Phys* 1988;15:1097-102.
  7. Goldstein M, Maxymiw WG, Cum-mings BJ, Wood RE. The effects of antitumor irradiation on mandibular opening and mobility: A prospective study of 58 patients. *Oral Surg Oral Med Oral Pathol Oral Radiol Endod* 1999;88:365-73.
  8. Daly TE. Head and neck: dental care in the irradiated patient. In: Fletcher GH, editor. *Textbook of radiotherapy*. Philadelphia: Lea and Febiger; 1973. p. 229-37.
  9. Jen YM, Lin YC, Wang YB, Wu DM. Dramatic and prolonged decrease of whole salivary secretion in nasopharyngeal carcinoma patients treated with radiotherapy. *Oral Surg Oral Med Oral Pathol Oral Radiol Endod* 2006;101:322-7.
  10. Cassolato SF, Turnbull RS. Xerostomia: Clinical aspects and treatment. *Gerodontology* 2003;20:64-77.
  11. Lăcătușu S, Frâncu L, Frâncu D. Clinical and therapeutical aspects of rampant caries in cervico-facial irradiated patients. *Rev Med Chir Soc Med Nat Iasi* 1996;100:198-202.
  12. Brennan MT, Woo SB, Lockhart PB. Dental treatment planning and management in the patient who has cancer. *Dent Clin North Am* 2008;52:19-37, 7.
  13. Dikman GE, Arends J. Secondary caries *in situ* around fluoride-releasing light-curing composites: A quantitative model investigation on four materials with a fluoride content between 0 and 26 vol%. *Caries Res* 1992;26:351-7.
  14. Nagmine M, Itota T, Torii Y, Irie M, Staninec M, Inoue K. Effect of resin-modified glass-ionomer cements on secondary caries. *Am J Dent* 1997;10:173-8.
  15. Tam LE, Chan GP, Yim D. *In vitro* caries inhibition effects by conventional and resin-modified glass-ionomer restorations. *Oper Dent* 1997;22:4-14.
  16. Roumanas ED, Markowitz BL, Lorant JA, Calcaterra TC, Jones NF, Beumer J 3rd. Reconstructed mandibular defects: Fibula free flaps and osseointegrated implants. *Plast Reconstr Surg* 1997;99:356-65.
  17. Schultes G, Gaggl A, Kärcher H. Stability of dental implants in microvascular osseous transplants. *Plast Reconstr Surg* 2002;109:916-24.
  18. McGhee MA, Stern SJ, Callan D, Shewmake K, Smith T. Osseointegrated implants in the head and neck cancer patient. *Head Neck* 1997;19:659-65.
  19. Nishimura RD, Roumanas E, Moy PK, Sugai T, Freymiller EG. Osseointegrated implants and orbital defects: UCLA experience. *J Prosthet Dent* 1998;79:304-9.
  20. Esposito M, Hirsch JM, Lekholm U, Thomsen P. Biological factors contributing to failures of osseointegrated oral implants (II). Etiopathogenesis. *Eur J Oral Sci* 1998;106:721-64.

**How to cite this article:** Alikhasi M, Kazemi M, Nokar S, Khojasteh A, Sheikhzadeh S. Step-by-step full mouth rehabilitation of a nasopharyngeal carcinoma patient with tooth and implant-supported prostheses: A clinical report. *Contemp Clin Dent* 2011;2:256-60.

**Source of Support:** Nil. **Conflict of Interest:** None declared.