



Vessel healings after stenting with different polymers in STEMI patients

Qin-Hua JIN, Yun-Dai CHEN, Feng TIAN, Jun GUO, Jing JING, Zhi-Jun SUN

Department of Cardiology, Chinese PLA General Hospital, Beijing, China

Abstract

Background Different stents implantation in ST-segment elevation myocardial infarction (STEMI) patients may influence the long term prognosis by affecting vessel healings after stenting. The aim of this study was to evaluate the vessel healings after implantation of drug eluting stents (DES) with biodegradable or durable polymer or of bare-metal stents (BMS) in patients with acute STEMI. **Methods** This study included 50 patients, who underwent follow up angiogram and optical coherence tomography (OCT) assessment about one year after percutaneous coronary intervention (PCI) for STEMI. According to the initial stents types, these patients were classified to durable ($n = 19$) or biodegradable polymer sirolimus-eluting stents ($n = 15$), or BMS ($n = 16$) groups. The conditions of stent struts coverage and malapposition were analyzed with OCT technique. **Results** A total of 9003 struts were analyzed: 3299, 3202 and 2502 from durable or biodegradable polymer DES, or BMS, respectively. Strut coverage rate (89.0%, 94.9% and 99.3%, respectively), malapposition presence (1.7%, 0.03% and 0 of struts, respectively) and average intimal thickness over struts ($76 \pm 12 \mu\text{m}$, $161 \pm 30 \mu\text{m}$ and $292 \pm 29 \mu\text{m}$, respectively) were significantly different among different stent groups (all $P < 0.001$). **Conclusions** Vessel healing status in STEMI patients is superior after implantation of biodegradable polymer DES than durable polymer DES, while both are inferior to BMS.

J Geriatr Cardiol 2016; 13: 306–311. doi:10.11909/j.issn.1671-5411.2016.04.004

Keywords: Acute myocardial infarction; Biodegradable polymer; Optical coherence tomography; Uncovered struts

1 Introduction

In a meta-analysis of 14 randomized controlled trials involving 7,654 patients with ST-segment elevation myocardial infarction (STEMI), the use of drug eluting stents (DES) significantly reduced revascularization compared with that of bare metal stents (BMS) without increasing mortality or stent thrombosis (ST).^[1] However, some studies showed that acute myocardial infarction (MI) was a predictor of thrombotic stent complications occurring late after DES implantation, particularly in the presence of a high thrombus burden.^[2,3] Two meta-analyses in patients with acute MI confirmed a lower risk of repeat revascularization with early generation DES compared with BMS, however, at the expense of a 2-fold increased risk of very late stent thrombosis.^[4,5] The risk of ST was related to incomplete stent strut coverage.^[6] Vessel healing is delayed with evidence of chronic inflammation related at least in part to the persistence of durable polymer components.^[7] DES with biodegradable polymers provides controlled drug release with subsequent degradation of the polymer rendering the metal stent surface more closely than that of a BMS after the period of biodegradation. Clinical outcomes appear better after biodegradable than durable polymer DES for acute STEMI.^[8] While, there were no data on vessel healing status after biodegradable polymer DES in acute STEMI patients.

2 Methods

2.1 Study population

From our optical coherence tomography (OCT) image database, 50 patients met all the following criteria for inclusion in this study: (1) had undergone percutaneous coronary intervention (PCI) for acute MI (AMI); (2) had been implanted with BMS, degradable or durable polymer DES; (3) had undergone one year follow-up coronary angiography (CAG) and OCT simultaneously to evaluate the stents; and (4) follow up CAG showed no restenosis.

In this study, the diagnoses of acute STEMI were based on a clinical diagnosis (overall clinical evidence including symptoms, electrocardiographic evidence, and cardiac troponin levels).^[9] All patients received oral loading dose aspirin (300 mg) and clopidogrel (600 mg) before initial coronary angiogram. Before stent implantation, intravenous

Correspondence to: Yun-Dai CHEN MD, PhD, Department of Cardiology, Chinese PLA General Hospital, No.28, Fuxing Road, HaiDian District, Beijing, China 100853. E-mail: cyundai@vip.163.com

Received: October 7, 2015 **Revised:** November 29, 2015

Accepted: December 10, 2015 **Published online:** April 14, 2016

(100 U/kg) heparin was administered, and thrombus aspiration was performed in all patients. Predilation of the culprit lesion, post dilation after stenting and use of glycoprotein IIb/IIIa inhibitors were all at the discretion of the operator. All patients received dual antiplatelet therapy (aspirin 100 mg + clopidogrel 75 mg) and statins (atorvastatin 20 mg or rosuvastatin 10 mg) for at least one year. They all underwent follow-up CAG and OCT examination about one year later. Patients were divided into three groups according to stents implanted at culprit lesions. Group 1 included 19 patients who had durable polymer DES implanted, among them, eight patients were implanted with FIREBIRD 2 stents [durable ethylene vinylacetate (EVAC) polymer sirolimus coated stents, Microport Medical System, Shanghai, China]; another eight patients were implanted with PARTNER stent [durable ethylene & polyvinyl acetate (PEVA) and poly n-butyl methacrylate (PBMA) polymer sirolimus coated stent, LEPU Medical System, China] and another three patients were implanted with CYPHER SELECT stent (durable PEVA and PBMA polymer sirolimus coated stents, Cordis Corporation, Johnson & Johnson Company, USA). Group 2 included 15 patients who were implanted with biodegradable polymer stents, EXCEL stent (biodegradable polylactic acid polymer-coated sirolimus-eluting stent, JW Medical System, Weihai, China). Group 3 included 16 patients who were implanted with BMS [six VISION stents (Abbott Vascular Corporation, USA), six TITAN stents (HEXACATH Corporation, France) and four PENTA stents (Guidant Corporation, USA)]. Clinical, procedural, and imaging data were obtained from an interventional database of the Chinese PLA General Hospital cardiovascular catheterization laboratories. Image analysis was performed at the Chinese PLA General Hospital cardiovascular interventional Center. The hospital review board approved the study.

2.2 OCT procedure

OCT examinations were performed after intracoronary administration of 200 µg nitroglycerin. There were 21 patients underwent OCT examination with the M2 OCT image machine. An over-the-wire occlusion balloon catheter (OBC) (Helios; LightLab Imaging Inc., Westford, MA, USA) was advanced over a 0.014-inch angioplasty guidewire to the distal end of the target stent. The guidewire was then removed from the OBC inner lumen and a 0.016-inch imaging wire (ImagingWire; LightLab Imaging Inc., Westford, MA, USA) was inserted through the OBC. With the ImagingWire held in place across the target stent, the OBC was withdrawn until the balloon was positioned proximal to the stent. Then, the occlusion balloon was inflated to between

0.4 and 0.6 atm while lactated Ringer's solution was infused from the distal tip of the OBC at 0.5 mL/s to flush blood from the imaging field. An imaging run was performed from the distal segment through the stent to the proximal segment of the target stent using automated transducer pullback at 1.0 mm/s, followed by occlusion balloon deflation. OCT images of another 29 patients were obtained using the LightLab C7-XR frequency domain OCT system (LightLab Imaging, Inc., Westford, MA, USA) with the non-occlusive technique. The imaging catheter was inserted through a 0.014 inch angioplasty wire to the distal end of the target stent. Contrast then was infused (at a flow rate of 3.0 to 4.0 mL/s) from the tip of the guiding catheter to flush blood from the imaging field. At the same time, a motorized pullback system was used at 20 mm/s and OCT images were acquired at 100 frames per second. During this procedure, ST-segment elevation, patient symptoms, and hemodynamic conditions were observed carefully.

2.3 OCT Analysis

OCT images were analyzed using software from LightLab Imaging, Inc. (Westford, MA, USA) by two independent observers who were blinded to the clinical situation. Stent strut coverage, stent malapposition, neointimal hyperplasia was evaluated at 1 mm intervals in cross-sectional images. When there was any discordance between the observers, a consensus reading was obtained.

Visible stent struts were classified into six groups: (a) apposed to the vessel wall and covered with neointima; (b) apposed to the vessel wall and uncovered; (c) malapposed and covered; (d) malapposed and uncovered; (e) stent struts over a side branch and covered; and (f) stent struts over a side branch and uncovered (Figure 1). Stent strut coverage was reported as percentage of covered struts [(a) and (c)] of all analyzed struts in categories (a)–(d). Struts overlaying a side branch [(e) and (f)] could not be classified in terms of apposition and were excluded from calculations. A stent strut was defined as covered if there was a visible layer of tissue over it. The thickness of the neointimal layer over each covered strut was measured. The thickness of the neointimal layer was defined as perpendicular distance from the endoluminal surface of the strut reflection to the border of the vessel lumen. A stent strut was classified as malapposed if the distance of the endoluminal surface of the strut reflection to the border of the vessel lumen is greater than the sum of stent thickness and polymer thickness and axial resolution (10–20 µm) of OCT, which was rounded up to full ten microns: CYPHER, ≥ 160 µm; FIREBIRD, LEPU, EXCEL, VISION or TITAN, ≥ 110 µm; and PENTA, ≥ 130 µm. If the image quality of a cross section was inadequate to

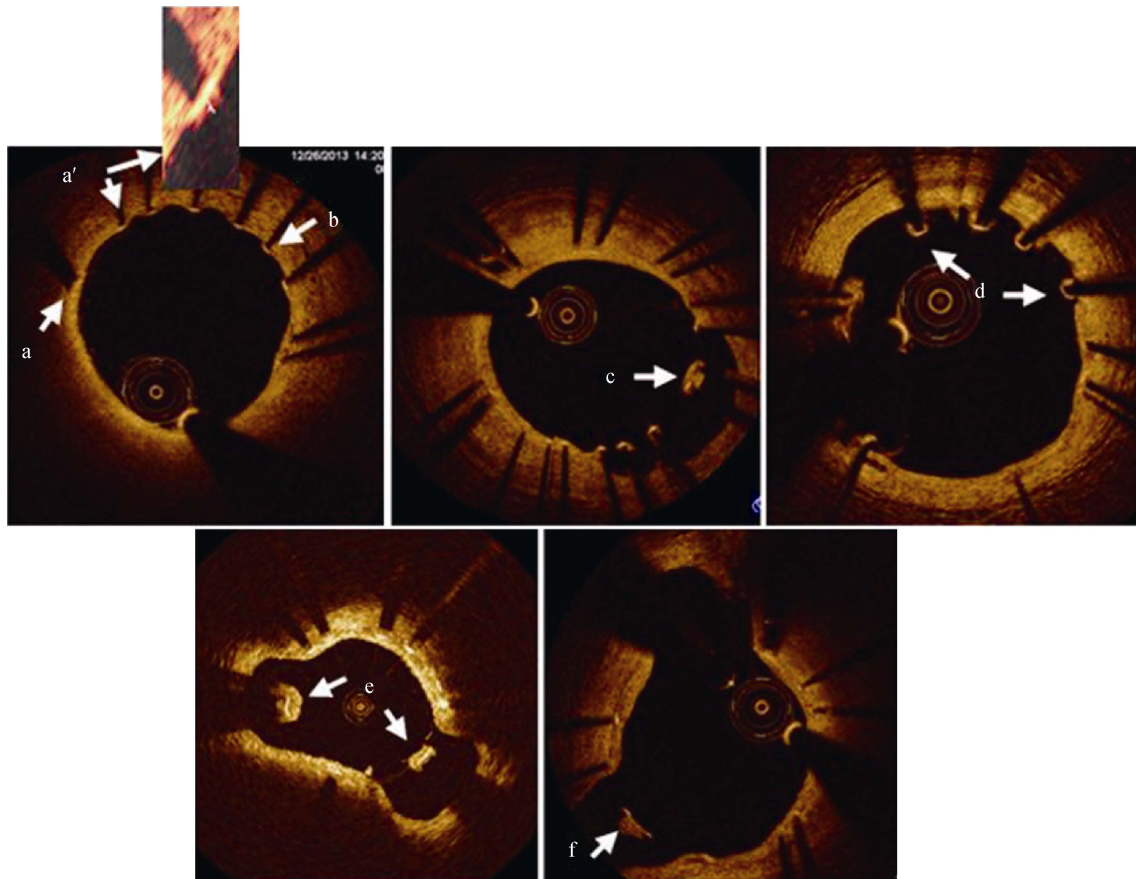


Figure 1. Stent struts intimal coverage conditions. (a) Stent strut apposed well and covered well; (a') strut apposed well but without apparent intimal coverage, however after zooming in the strut, is appeared covered by a thin tissue; (b) strut apposed well while uncovered; (c) strut malapposed while covered well; (d) struts malapposed and uncovered; (e) struts over side branch covered well; and (f) strut over side branch uncovered.

allow reliable measurements, previous or subsequent cross section with adequate quality was used for measurements.

2.4 Angiographic analysis

Quantitative coronary angiographic analysis (QCA) was performed using a computer-assisted, automated edge-detection algorithm by two independent observers who were blinded to clinical and OCT information. Intracoronary thrombus was defined as a filling defect seen in multiple projections. The reference diameter, minimum lumen (stent) diameter, diameter stenosis (DS), thrombolysis in myocardial infarction (TIMI) flow, and lesion length were measured.

2.5 Statistics

All statistical analyses were performed by an independent statistician at the Core Laboratory. Continuous variables were expressed as mean \pm SD and compared with *t* test. Categorical variables were expressed as frequencies and compared using chi-square statistics or Fisher exact test (if

the expected cell value was < 5). All statistical analyses were performed with Stata 10. A *P* value of < 0.05 was considered statistically significant.

3 Results

3.1 Baseline demographics and angiographic characteristics

Main baseline clinical data are shown in Table 1. Clinical characteristics including age, gender, smoking, diabetes, hypertension, hypercholesterolemia, and left ventricular ejection fraction, were all similar among the three groups. While if compared each two groups, the patients in BMS were older than those in other two groups; the left ventricular ejection fraction in hospital was a little bit better in durable polymer stent group.

Angiographic characteristics are shown in Table 2. There were no significant differences among the three groups in terms of the following variables: lesion location, mean diameter stenosis degree and minimal lumen diameter of the

Table 1. Baseline clinical characteristics.

Variables	Durable polymer <i>n</i> = 19	Biodegradable polymer <i>n</i> = 15	BMS <i>n</i> = 16	<i>P</i> value
Male	18 (94.7%)	15 (100.0%)	16 (100.0%)	0.435
*Age, yrs	52.1 ± 11.7	50.1 ± 8.9	65.3 ± 11.4	0.074
Body mass index, kg/m ²	25.2 ± 3.2	24.7 ± 2.7	25.0 ± 2.6	0.632
Hypertension	10 (52.6%)	10 (66.7%)	11 (68.8%)	0.561
HC	2 (10.5%)	1 (6.7%)	1 (6.3%)	0.875
Diabetes mellitus	7 (36.8%)	5 (33.3%)	3 (18.8%)	0.480
Smoker	9 (47.4%)	6 (40.0%)	4 (25.2%)	0.390
Family history	0 (0)	2 (13.4%)	1 (6.3%)	0.187
Anterior MI	7 (36.8%)	8 (53.3%)	7 (43.8%)	0.629
Inferior MI	12 (63.2%)	7 (46.7%)	9 (56.2%)	0.629
#LVEF, %	50.3 ± 4.7	46.2 ± 4.2	47.8 ± 6.6	0.164
Multi-vessel disease	14 (73.7%)	10 (66.7%)	10 (62.5%)	0.806
Follow up interval, months	11.9 ± 2.6	13.3 ± 2.1	11.5 ± 4.1	0.905

Data are presented as mean ± SD, or *n*(%). **P* value < 0.01 between BMS and durable or biodegradable polymer stents; #*P* value < 0.05 between durable and biodegradable polymer stents. BMS: bare-metal stents; HC: hypercholesterolemia; MI: myocardial infarction; LVEF: left ventricular ejection fraction.

target vessel before PCI, mean target lesion lengths, mean stent length, number of stents implanted, residual diameter stenosis of the target vessels after PCI. TIMI flow before and post stenting and follow-up diameter stenosis of target stents. If compared between each two groups, stent length in durable polymer stent group was longer than that in BMS group; the ratio of post-dilation balloon size and stent size in biodegradable stent was larger than that in durable polymer stent group; the residual diameter stenosis post procedure was larger in BMS than that in biodegradable polymer stent group.

3.2 Vessel healing conditions

Follow-up CAG and OCT imagine had been performed 11.9 ± 4.2 months after primary stenting. Table 3 summarizes the vessel healing status at follow-up evaluation by OCT. Among 9111 struts, 108 struts were excluded because of location over side branches. In the remaining 9003 struts rates of struts coverage and of malapposed struts of DES with biodegradable polymer was between those of BMS and DES with durable polymer (*P* < 0.001). While malapposed struts rate of biodegradable polymer stents was similar to that of BMS (*P* > 0.05). Tissue coverage thickness over stent struts was least in durable polymer DES, followed by biodegradable polymer DES, and greatest in BMS (*P* < 0.001).

Table 2. Lesion and procedural characteristics.

Variables	Durable polymer <i>n</i> = 19	Biodegradable polymer <i>n</i> = 15	BMS <i>n</i> = 16	<i>P</i> value
Lesion location				
LAD	7 (36.8%)	8 (53.3%)	7 (43.8%)	0.629
LCX	3 (15.8%)	1 (6.7%)	0 (0)	0.224
RCA	9 (47.4%)	6 (40.0%)	9 (56.3%)	0.662
Vessel size, mm	3.2 ± 0.5	3.1 ± 0.4	3.3 ± 0.6	0.481
TIMI flow				
0 grade	12 (63.2%)	9 (60.0%)	8 (50.0%)	0.722
1 grade	4 (21.1%)	3 (20.0%)	4 (25.0%)	0.938
2 grade	2 (10.5%)	2 (13.3%)	3 (18.8%)	0.780
3 grade	1 (5.3%)	1 (6.7%)	1 (6.3%)	1.000
Thrombus aspiration	19 (100.0%)	15 (100.0%)	16 (100.0%)	-
Predilation	14 (73.7%)	12 (80.0%)	12 (75.0%)	0.907
Stent diameter, mm	3.4 ± 0.5	3.1 ± 0.4	3.4 ± 0.5	0.451
*Stent length, mm	27.4 ± 7.6	26.0 ± 9.0	22.0 ± 7.5	0.520
Stent inflation pressure, atm	14.9 ± 2.7	14.4 ± 1.3	13.5 ± 3.4	0.589
Postdilation	11 (57.9%)	10 (66.7%)	10 (62.5%)	0.871
#Balloon size/ stent size	1.0 ± 0.1	1.2 ± 0.4	1.0 ± 0.1	0.222
&DS post procedure, %	9.4 ± 3.2	7.0 ± 3.9	9.3 ± 1.5	0.249
Final TIMI flow				
3 grade	18 (94.7%)	15 (100.0%)	15 (93.8%)	0.633
2 grade	1 (5.3%)	0 (0)	1 (6.3%)	0.633
DS at follow up, %	13.1 ± 3.3	11.7 ± 2.5	11.3 ± 2.5	0.408

Data are presented as mean ± SD, or *n* (%). **P* value < 0.05 between durable polymer stent and BMS; #*P* value < 0.05 between durable and biodegradable polymer stents; &*P* value < 0.05 between biodegradable polymer stent and BMS. BMS: bare-metal stents; DS: diameter stenosis; LAD: left anterior descending artery; LCX: left circumflex artery; RCA: right coronary artery; TIMI: thrombolysis in myocardial infarction.

Table 3. OCT image analysis in each subgroup of patients who underwent interventional imaging at follow up.

Variables	Durable polymer	Biodegradable polymer	BMS	<i>P</i> value
Struts over side branches	43	34	31	-
Struts (- side branch)	3,299	3,202	2,502	-
Uncovered struts	363 (11.0)	163 (5.1)	17 (0.7)	< 0.001*
Malapposed struts	56 (1.7)	1 (0.03)	0 (0)	< 0.001#
uncovered	39 (70.9)	1 (100.0)	-	-
Tissue coverage thickness, μm	76 ± 12	161 ± 30	292 ± 29	< 0.001*

Data are presented as mean ± SD, or *n*(%). * There exists significant difference between each two groups; #*P* value < 0.001 between durable polymer stent group and biodegradable polymer stent or BMS group, while there were no significant difference between biodegradable polymer stent and BMS group (*P* > 0.05). BMS: bare-metal stents; OCT: optical coherence tomography.

4 Discussion

The main findings of this study are as follows: (1) biodegradable polymer DES implanted in Chinese STEMI patients has better stent struts coverage than durable polymer DES, while both were inferior to BMS in this regard; (2) biodegradable polymer DES implanted in Chinese STEMI patients has less malapposed struts than durable polymer DES but more than BMS.

Suzuki, *et al.*^[10] studied long-term outcomes of DES vs. BMS in patients with AMI, and showed that in Japanese patients with AMI, there was no significant difference in the incidence of MACE during 5-years follow-up. Although a lower rate of TLR was observed in the DES group within the first year, the difference disappeared after the first year following primary PCI. Moreover, studies showed that acute MI was a predictor of thrombotic stent complications occurring late after DES implantation, particularly in the presence of a high thrombus burden; risk of ST was related to incomplete stent strut coverage; and DES polymer which was associated with chronic inflammation, and may-be related to incomplete strut coverage or strut malapposition.^[2,3,7] Therefore, it was posited that biodegradable polymer DES use might yield better outcome than durable polymer DES in acute MI patients. In our study, each group sample size was too small and follow up period was too short to analyze the clinical outcomes. While Lupi, *et al.*,^[8] in a meta-analysis of bioabsorbable versus durable polymer DES in 20,005 patients with coronary artery disease showed that bioabsorbable DES significantly reduced late lumen loses and late ST rates without improvement in mortality, MI, TLR and TVR rates.

Stent apposition and neointimal coverage might be a useful surrogate parameter for late stent thrombosis and stent safety.^[11,12] OCT allows accurate assessment of neointimal coverage and apposition after DES implantation. Presence of struts with incomplete neointimal coverage or malapposition indicate poor vessel healing after DES implantation and at high risk of stent thrombosis.^[13-15] Our study findings suggest better vessel healings in biodegradable than durable polymer DES implanted in acute STEMI patients. Biodegradable polymer DES will leave a metal stent backbone and therefore would be expected to have similar performance to BMS after the period of biodegradation. However, in our study, biodegradable polymer DES had more incomplete strut coverage and strut malapposition than BMS at about 1-year follow-up. The relatively short follow-up interval in this study might underlie these findings.

Does complete strut coverage assure safety? The fully functional endothelial layer is known to have antithrombotic

and anticoagulant effects via secreting factors inhibiting platelet aggregation, such as nitric oxide or prostacyclins.^[16] However, several questions remain to be answered such as whether coverage seen over the stented segments is truly endothelium, and if it is, whether this endothelium is functional. Some researchers have studied coronary endothelial dysfunction by focusing on vasoconstriction response to Ach, and showed that DES has a potential long-term adverse effect on local coronary endothelial dysfunction.^[17] However, it remains difficult to decide if the tissue covering stent struts is functional endothelium.

Hong, *et al.*^[18] reported that the predictors of late stent malapposition include total stent length, primary stenting in acute MI, and chronic total occlusion lesions. In the current study, different polymers appear to also differentially influence stent malapposition.

Although OCT is the highest resolution technique available at the present time, it cannot detect a very thin intimal coverage (< 10 μm) beyond its resolution. This might increase the frequency of uncovered stent struts during OCT imaging analysis. The single-center retrospective design of this study and the very small sample size undermine evaluation of the relationship between vessel healing status and clinical MACE rate. A study involving larger patient populations from various centers is warranted. Finally, OCT images in this study had been acquired with two OCT machines M2 and C7, which may affect the result.

In conclusion, durable as compared to biodegradable polymer DES showed more delayed healing at 1-year follow-up while both DES showed more delayed healing as compared to BMS.

Acknowledgements

Dr. Jin has received research funding from Chinese PLA General Hospital. All other authors have reported that they have no relationships relevant to the contents of this paper to disclose. Pharmaceutical or medical device companies had no input into the design of the study or in the preparation of the paper.

References

- 1 Suh HS, Song HJ, Choi JE, *et al.* Drug-eluting stents versus bare-metal stents in acute myocardial infarction: a systematic review and meta-analysis. *Int J Technol Assess Health Care* 2011; 27: 11–22.
- 2 Sianos G, Papafaklis MI, Daemen J, *et al.* Angiographic stent thrombosis after routine use of drug-eluting stents in ST-segment elevation myocardial infarction: the importance of thrombus burden. *J Am Coll Cardiol* 2007; 50: 573–583.

- 3 Daemen J, Wenaweser P, Tsuchida K, *et al.* Early and late coronary stent thrombosis of sirolimus-eluting and paclitaxel-eluting stents in routine clinical practice: data from a large two-institutional cohort study. *Lancet* 2007; 369: 667–678.
- 4 De Luca G, Dirksen MT, Spaulding C, *et al.* Drug-eluting vs. bare-metal stents in primary angioplasty: a pooled patient-level meta-analysis of randomized trials. *Arch Intern Med* 2012; 172: 611–621.
- 5 Kalesan B, Pilgrim T, Heinemann K, *et al.* Comparison of drug-eluting stents with bare metal stents in patients with ST-segment elevation myocardial infarction. *Eur Heart J* 2012; 33: 977–987.
- 6 Claessen BE, Henriques JP, Jaffer FA, *et al.* Stent thrombosis: a clinical perspective. *JACC Cardiovasc Interv* 2014; 7: 1081–1092.
- 7 Nakazawa G, Finn AV, Joner M, *et al.* Delayed arterial healing and increased late stent thrombosis at culprit sites after drug-eluting stent placement for acute myocardial infarction patients: an autopsy study. *Circulation* 2008; 118: 1138–1145.
- 8 Lupi A, Secco GG, Rognoni A, *et al.* Meta-analysis of bioabsorbable versus durable polymer drug eluting stents in 2005 patients with coronary artery disease: an update. *Catheter Cardiovasc Interv* 2014; 83: E193–E206.
- 9 O’Gara PT, Kushner FG, Ascheim DD, *et al.* 2013 ACCF/AHA guideline for the management of ST-elevation myocardial infarction: a report of the American College of Cardiology Foundation/American Heart Association Task Force on practice guidelines. *Circulation* 2013; 127: 529–555.
- 10 Suzuki S, Ishii H, Matsudaira K, *et al.* Long-term outcome of drug-eluting vs. bare-metal stents in patients with acute myocardial infarction. Subgroup analysis of the Nagoya acute myocardial infarction study (NAMIS). *Circ J* 2013; 77: 2024–2031.
- 11 Moore P, Barlis P, Spiro J, *et al.* A randomized optical coherence tomography study of coronary stent strut coverage and luminal protrusion with rapamycin-eluting stents. *J Am Coll Cardiol Interv* 2009; 2: 437–444.
- 12 Takano M, Yamamoto M, Inami S, *et al.* Long-term follow-up evaluation after sirolimus-eluting stent implantation by optical coherence tomography: do uncovered struts persist? *J Am Coll Cardiol* 2008; 51: 968–969.
- 13 Cook S, Wenaweser P, Togni M, *et al.* Incomplete stent apposition and very late stent thrombosis after drug-eluting stent implantation. *Circulation* 2007; 115: 2426–2434.
- 14 Gonzalo N, Barlis P, Serruys PW, *et al.* Incomplete stent apposition and delayed tissue coverage are more frequent in drug-eluting stents implanted during primary percutaneous coronary intervention for ST-segment elevation myocardial infarction than in drug-eluting stents implanted for stable/unstable angina: insights from optical coherence tomography. *JACC Cardiovasc Interv* 2009; 2: 445–452.
- 15 Guagliumi G, Costa MA, Sirbu V, *et al.* Strut coverage and late malapposition with paclitaxel-eluting stents compared with bare metal stents in acute myocardial infarction: optical coherence tomography substudy of the harmonizing outcomes with revascularization and stents in acute myocardial infarction (HORIZONS-AMI) trial. *Circulation* 2011; 123: 274–281.
- 16 Yao SK, Ober JC, Krishnaswami A, *et al.* Endogenous nitric oxide protects against platelet aggregation and cyclic flow variations in stenosed and endothelium-injured arteries. *Circulation* 1992; 86: 1302–1309.
- 17 Kim JW, Suh SY, Choi CU, *et al.* Six-month comparison of coronary endothelial dysfunction associated with sirolimus-eluting stent versus Paclitaxel-eluting stent. *JACC Cardiovasc Interv* 2008; 1: 65–71.
- 18 Hong SJ, Kim MH, Ahn TH, *et al.* Multiple predictors of coronary restenosis after drug-eluting stent implantation in patients with diabetes. *Heart* 2006; 92: 1119–1124.