

## CASE REPORT

## Successful treatment of hemochromatosis with renal tubular dysgenesis in a preterm infant

Uta Koura<sup>1</sup>, Shinjiro Horikawa<sup>1</sup>, Mako Okabe<sup>1</sup>, Yukako Kawasaki<sup>1</sup>, Masami Makimoto<sup>1</sup>, Koichi Mizuta<sup>2</sup> & Taketoshi Yoshida<sup>1</sup>

<sup>1</sup>Division of Neonatology, Maternal and Perinatal Center, Toyama University Hospital, 2630 Sugitani, Toyama 930-0194, Japan

<sup>2</sup>Department of Transplant Surgery, Jichi Medical University Hospital, 3311-1 Yakushiji, Shimotsuke-shi, Tochigi-ken 329-0498, Japan

### Correspondence

Taketoshi Yoshida, Division of Neonatology Maternal and Perinatal Center Toyama University Hospital, 2630 Sugitani, Toyama 930-0194, Japan. Tel: 81 (0)76 434 7313; Fax: 81 (0)76 434 5029; E-mail: ytake@med.u-toyama.ac.jp

### Funding Information

No sources of funding were declared for this study.

Received: 8 November 2014; Revised: 27

April 2015; Accepted: 7 May 2015

*Clinical Case Reports* 2015; 3(8): 690–693

doi: 10.1002/ccr3.306

## Introduction

Neonatal hemochromatosis (NH) is defined by liver disease associated with siderosis of the extrahepatic tissues [1]. The most frequent cause of NH is a gestational allo-immune disorder called gestational alloimmune liver disease, which results from the transplacental transfer of maternal immunoglobulin G (IgG) antibodies [2]. Although about 80% of NH patients can survive without liver transplantation because of exchange transfusions and intravenous Ig therapy, some of the patients with more serious disease require transplantation [3]. Occasionally, severely affected NH infants exhibit renal tubular dysgenesis (RTD) [4]. NH with RTD has been reported in only five cases, all of which were stillborn or resulted in early neonatal death [5–8]. We describe a case of surviving patient who had NH with RTD and underwent peritoneal dialysis and liver transplantation from her father.

## Case History

A 29-year-old woman was referred to our hospital at 35 weeks' gestation in her second pregnancy with atypical

### Key Clinical Message

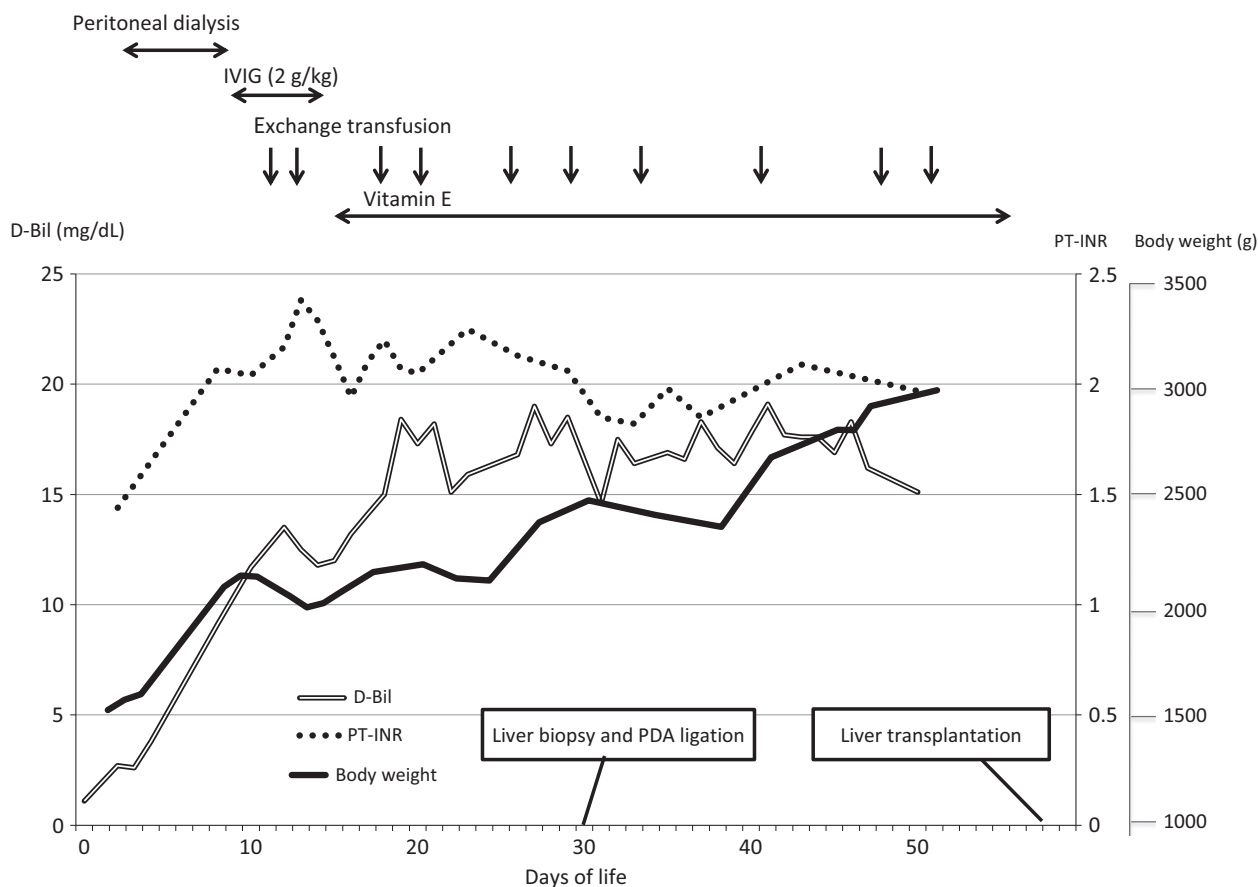
We report the first surviving case of neonatal hemochromatosis with renal tubular dysgenesis. Renal failure was treated with peritoneal dialysis. Although hepatic failure from neonatal hemochromatosis was progressive, repeated exchange transfusions improved jaundice and coagulopathy. The patient gained weight and received a liver transplantation from her father.

### Keywords

Liver transplantation, neonatal hemochromatosis, peritoneal dialysis, renal tubular dysgenesis.

genital bleeding. She had been diagnosed with poor fetal growth and oligohydramnios from 30 weeks of gestation. A female infant was born by spontaneous vaginal delivery at 35 weeks with a birth weight of 1544 g (−2.8 standard deviations, SD), a birth length of 42 cm (−1.6 SD), and a head circumference of 29 cm (−1.8 SD). Apgar scores were 1 (1 min) and 6 (5 min). She was given artificial surfactant and received mechanical ventilation. Physical examination revealed calvarial bone hypoplasia with enlarged fontanelles and hepatosplenomegaly, but with no other abnormalities.

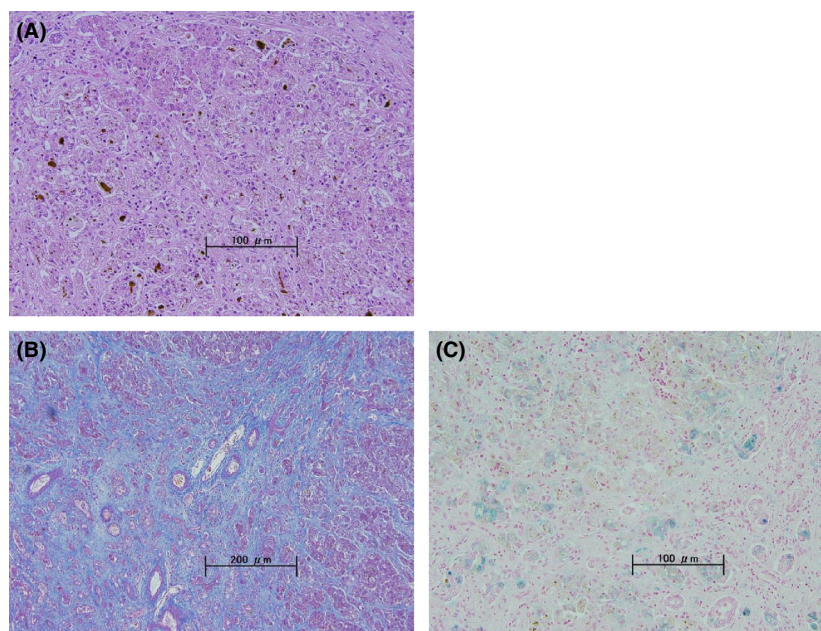
The infant was anuric and hypotensive at birth. Renal ultrasound showed hyperechogenicity of both kidneys, but the size and morphology were normal. Anuria, skull ossification defects, and renal hyperechogenicity suggested renal tubular dysgenesis. Because the anuria persisted longer than 48 h and serum creatinine had increased to 3.0 mg/dL, peritoneal dialysis was performed on day 3 (Fig. 1). Persistent hypotension was treated with fresh frozen plasma (FFP) infusions. Spontaneous urination was first observed on day 6, and it increased gradually; therefore, peritoneal dialysis was discontinued on day 10. Finally, serum creatinine reached normal levels (0.5 mg/dL) on day 30.



**Figure 1.** The clinical course of selected laboratory parameters. PT-INR and D-Bil were improved by repeated exchange transfusion. The patient was able to gain weight because of internal medicines and liver transplantation. IVIG, intravenous immunoglobulin; D-Bil, direct bilirubin; PT-INR, prothrombin time/international normalized ratio.

Hepatic failure was suspected on day 9 because of hepatosplenomegaly, a poor coagulation profile (PT-INR: 2.07), jaundice (Direct-bilirubin: 9.1 mg/dL), thrombocytopenia (platelets:  $7.2 \times 10^4/\text{mm}^3$ ), and hypoglycemia. Congenital infections and metabolic disorders were ruled out by blood examinations. On the basis of the clinical course of acute liver failure and the complication of RTD, NH was suspected. However, she had a normal iron level of 138  $\mu\text{g}/\text{dL}$  and a ferritin level of 280 ng/mL. Moreover, magnetic resonance imaging of the abdomen did not reveal hepatic and extrahepatic siderosis on day 15. To obtain a definitive diagnosis, a liver biopsy was performed on day 30, concomitant with the surgical ligation of the ductus arteriosus. The liver biopsy revealed an increase in stainable iron within the hepatocytes, confirming our diagnosis of NH (Fig. 2). Moreover, a marked loss of hepatocytes and cholestasis was detected and the remaining hepatocytes were multinucleated. Parenchymal fibrosis was extensive in most areas of the liver (Fig. 2).

Intravenous Ig was administered on days 11–16 after the clinical suspicion of NH. Exchange transfusion was performed 10 times to improve jaundice and coagulopathy from day 12. Vitamin E was administered starting at day 16 (25 IU/kg/day), whereas vitamin K was intravenously administered periodically after birth. She received continuous infusions of FFP and repeated transfusions of platelets because of her overwhelming liver dysfunction. Her liver function did not improve; however, she gained weight, reaching 2500 g, which indicated that she was able to accept a liver transplantation from an adult (Fig. 1). She was then transferred to Jichi Medical University for the liver transplant procedure. A living donor liver transplantation with segment 2 monosubsegment graft (130 g) for her was performed on day 59. The liver extracted from patient was replaced by small nodules and overall fibrosis was progressing. Microscopically, the liver showed almost total distortion of the lobular architecture, loss of the hepatocytes, and a diffuse increase in fibrous tissue. A high degree of iron deposition in hepatocytes



**Figure 2.** Liver histopathology. (A) A marked loss of hepatocytes and cholestasis. The remaining hepatocytes were multinucleated (Hematoxylin and eosin, original magnification  $\times 200$ ). (B) Parenchymal fibrosis was extensive in most areas (Azan staining, original magnification  $\times 100$ ). (C) Distribution of siderosis. Iron staining was predominantly both inside and outside the hepatocytes (Berlin Blue staining, original magnification  $\times 200$ ).

was observed, which was definitely findings in neonatal hemochromatosis. Her liver function is normal at present on 9 month after transplantation.

## Discussion

The clinical course of this patient suggested two important clinical issues. First, the infusion of FFP and peritoneal dialysis were effective in treating persistent hypotension and renal failure in RTD with NH. To the best of our knowledge, this is the first surviving case of NH with RTD. Second, repeated exchange transfusions improved the jaundice and coagulopathy, facilitating the patient's growth for subsequent liver transplantation regardless of her status as a preterm infant.

Occasionally, severely affected NH infants exhibit RTD [1]. NH with RTD has only been reported in five cases, all of which were fatal or resulted in early neonatal death because of coagulopathy and liver failure [5–7]. In the case reported here, FFP infusion and peritoneal dialysis were effective in maintaining systemic blood pressure and organ perfusion. RTD with NH may be reversible within a certain range. This is supported by a recent report on a neonatal case of inherited RTD with an angiotensinogen gene mutation; this patient survived for more than 18 months with a treatment regimen that comprised FFP infusion and peritoneal dialysis [9, 10].

Because the diagnosis of RTD was made on the basis of the clinical symptoms and the hyperechogenicity of both kidneys in the present case, a kidney biopsy was required to confirm the diagnosis. However, the kidney biopsy was difficult to perform because of the presence of severe coagulopathy.

Recently, some patients with severe NH have been successfully treated by liver transplantation. Transplantation is not indicated if an acceptable alternative is available. In this case, liver failure did not improve regardless of a plurality of times of exchange transfusion and other medications. Moreover, her liver biopsy showed the remaining hepatocytes were multinucleated. On basis of clinical course and biopsy observation, we determined surgical liver transplantation was essential in this case.

Most liver transplantations for children in Japan are performed using the liver from one of the patient's parents. Our patient was very young, because of which we had to wait until her body weight reached at least 2500 g to accept an adult liver, and we thus treated her jaundice and coagulopathy with exchange transfusions. Fortunately, she developed no serious hemorrhage but instead showed weight gain, indicating growth. Her condition was stable when she had to undergo the transplantation. Our case report indicates that even a premature infant of NH with RTD can survive with peritoneal dialysis and exchange transfusions.

## Conflict of Interest

None declared.

## References

1. Whittington, P. F. 2006. Fetal and infantile hemochromatosis. *Hepatology* 43:654–660.
2. Lopriore, E., M. L. Mearin, D. Oepkes, R. Devlieger, and P. F. Whittington. 2013. Neonatal hemochromatosis: management, outcome, and prevention. *Prenat. Diagn.* 33:1221–1225.
3. Whittington, P. F.. 2012. Gestational alloimmune liver disease and neonatal hemochromatosis. *Semin. Liver Dis.* 32:325–332.
4. Gubler, M. C. 2014. Renal tubular dysgenesis. *Pediatr. Nephrol.* 29:51–59.
5. Bonila, S. F., H. M. Aldana, and P. F. Whittington. 2010. Relationship of proximal renal tubular dysgenesis and fetal liver injury in neonatal hemochromatosis. *Pediatr. Res.* 67:188–193.
6. Bale, P. M., A. E. Kan, and S. F. Dorney. 1994. Renal proximal tubular dysgenesis associated with severe neonatal hemosiderotic liver disease. *Pediatr. Pathol.* 14:479–489.
7. Johal, J. S., J. W. Thorp, and C. E. Oyer. 1998. Neonatal hemochromatosis, renal tubular dysgenesis, and hypocalvaria in a neonate. *Pediatr. Dev. Pathol.* 1:433–437.
8. Morris, S., S. Akima, J. E. Dahlstorm, D. Ellwood, A. Kent, and M. C. Falk. 2004. Renal tubular dysgenesis and neonatal hemochromatosis without pulmonary hypoplasia. *Pediatr. Nephrol.* 19:341–344.
9. Uematsu, M., O. Sakamoto, T. Nishio, T. Ohura, T. Matsuda, T. Inagaki, et al. 2006. A case surviving for over a year of renal tubular dysgenesis with compound heterozygous angiotensinogen gene mutation. *Am. J. Med. Genet. Part A.* 140A:2355–2360.
10. Uematsu, M., O. Sakamoto, T. Ohura, N. Shimizu, K. Satomura, and S. Tsuchiya. 2009. A further case of renal tubular dysgenesis surviving the neonatal period. *Eur. J. Pediatr.* 168:207–209.