

# Totally laparoscopic associating liver tourniquet and portal vein occlusion for staged hepatectomy combined with simultaneous left hemicolectomy for bilateral liver metastases of the primary colon cancer

## A case report

Hong-wei Xu, MD<sup>a</sup>, Hong-yu Li, MD<sup>b</sup>, Fei Liu, MD<sup>a</sup>, Yong-gang Wei, MD<sup>a,\*</sup>, Bo Li, MD<sup>a</sup>

### Abstract

**Background:** Resection of the liver is often limited to the insufficient future liver remnant (FLR). To address this problem, the modification surgical technique “associating liver tourniquet and portal vein occlusion for staged hepatectomy” (ALTPS) was developed and led to quick hypertrophy in a short interval. In some colorectal cancer patients with multiple and bilobar metastases, the resection of the primary is often protracted immensely to the unpredictable postoperative complications for whom is to be treated with a liver-first approach. To overcome this problem, a simultaneous resection of the primary tumor and totally laparoscopic ALTPS for bilateral liver metastases of the primary colon cancer were performed.

**Case summary:** A 63-year-old female patient with left colon cancer and synchronous bilateral colorectal liver metastases underwent a totally laparoscopic ALTPS and simultaneous left hemicolectomy because of the small FLR. The operative times were 460 minutes for the first stage and 240 minutes for the second stage without the need for blood transfusions. The recoveries after the first and the second operations were uneventful, and the patient was discharged on postoperative day 11 of the second stage operation.

**Conclusion:** Our case shows the totally laparoscopic ALTPS and simultaneous left hemicolectomy at step 1 for bilobar liver metastases of the primary colon cancer with no severe postoperative complications. If a resection of the primary tumor does not compromise the split procedure, the combination of pure laparoscopic ALTPS and primary resection is feasible and safe.

**Abbreviations:** ALPPS = associating liver partition and portal vein ligation for staged hepatectomy, ALTPS = associating liver tourniquet and portal vein occlusion for staged hepatectomy, FLR = future liver remnant, FLRV = future liver remnant volume, PVE = portal vein embolization, SLV = standard liver volume, TLV = total liver volume.

**Keywords:** ALTPS, colorectal carcinoma, laparoscopy

## 1. Introduction

Extended hepatectomy is often limited to the insufficient future liver remnant (FLR).<sup>[1]</sup> To address this problem, the modification surgical technique “associating liver tourniquet and portal

vein occlusion for staged hepatectomy” (ALTPS) was developed and led to quick hypertrophy in a short interval.<sup>[2]</sup> Although liver resection has proved the only curative modality of colorectal cancer patients with multiple and bilobar liver metastases, the resection of the primary is often protracted immensely to the unpredictable postoperative complications for whom is to be treated with a liver-first approach.<sup>[3]</sup> This situation can be solved with the combination of the first step of ALTPS and simultaneous removal of the primary tumor.<sup>[4]</sup> Recent advances in laparoscopic techniques have increased the indications for laparoscopic liver resection.<sup>[5]</sup> Therefore, a simultaneous resection of the primary tumor and totally laparoscopic ALTPS for bilateral liver metastases of the primary colon cancer were performed.

## 2. Case report

A 63-year-old female patient with left colon cancer and synchronous bilateral colorectal liver metastases underwent a totally laparoscopic ALTPS and simultaneous left hemicolectomy.

The total liver volume (TLV) was 1188 mL, and the volume of the left lateral section, the future liver remnant volume (FLRV), was 376 mL (Fig. 1). To achieve sufficient hypertrophy of the left lateral section, the first step of ALTPS plus left hemicolectomy was performed. Informed consent was obtained from the patient

Editor: Emmanuel Melloul.

Disclosure: All the authors mentioned above have no benefits in any form have been received or will be received from a commercial party related directly or indirectly to the subject of this article.

The authors have no funding and conflicts of interest to disclose.

<sup>a</sup> Department of Liver Surgery, Center of Liver Transplantation, <sup>b</sup> Department of Pancreatic Surgery, West China Hospital of Sichuan University, Chengdu, Sichuan Province, China.

\* Correspondence: Yong-gang Wei, Department of Liver Surgery, Center of Liver Transplantation, West China Hospital, Sichuan University, Chengdu, Sichuan Province, China (e-mail: dr\_wyg@163.com).

Copyright © 2017 the Author(s). Published by Wolters Kluwer Health, Inc. This is an open access article distributed under the terms of the Creative Commons Attribution-Non Commercial License 4.0 (CCBY-NC), where it is permissible to download, share, remix, transform, and buildup the work provided it is properly cited. The work cannot be used commercially without permission from the journal.

Medicine (2017) 96:11(e6368)

Received: 9 August 2016 / Received in final form: 15 February 2017 / Accepted: 20 February 2017

<http://dx.doi.org/10.1097/MD.0000000000006368>

and her parents. The West China Hospital administration and the ethics committee authorized the surgery.

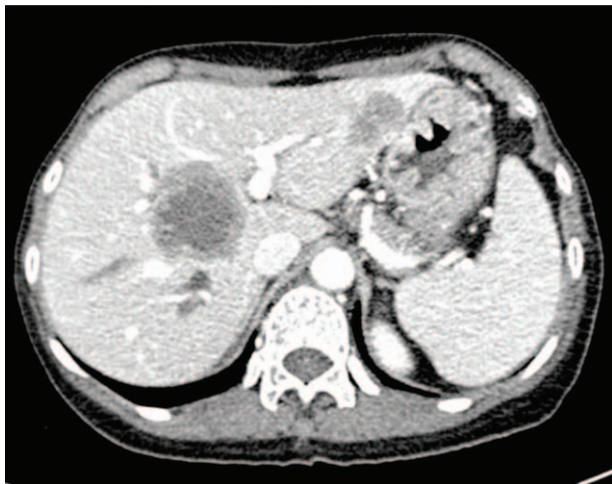The operation was started with laparoscopic left hemicolectomy. After step 1, laparoscopic resection of partial segment III was followed by identification of the portal structures, and the right portal vein was ligated. The hepatic artery and common bile duct were marked with loops. After it was confirmed that the tumor had not spread and that R0 resection could be achieved at the second stage of the ALTPS by laparoscopic ultrasound, the tourniquet was passed between the middle and left hepatic veins and continued around the base of the left lobe to the left portal vein pedicle. The blood loss in stage 1 was 250 mL. Postoperative pathology showed ulcerative adenocarcinoma of the colon and a low-grade adenocarcinoma of the liver.

Reevaluation of the patient after 13 days showed that the left liver had regenerated. Volumetry of the FLRV was 550 mL and the TLV was 1410 mL (Fig. 2). Considering that the weight of the patient is only 44 kg (standard liver volume [SLV]=1029 mL), the second step of the laparoscopic ALTPS was performed the following day. Small adhesions were found at laparoscopy. The right hepatic artery and the right bile duct were sectioned, and the right trisectionectomy was performed at the level of the tourniquet. There were no intraoperative complications, and the blood loss was 300 mL. The postoperative pathology revealed a low-grade adenocarcinoma of the liver which is in compliance with colorectal liver metastasis.

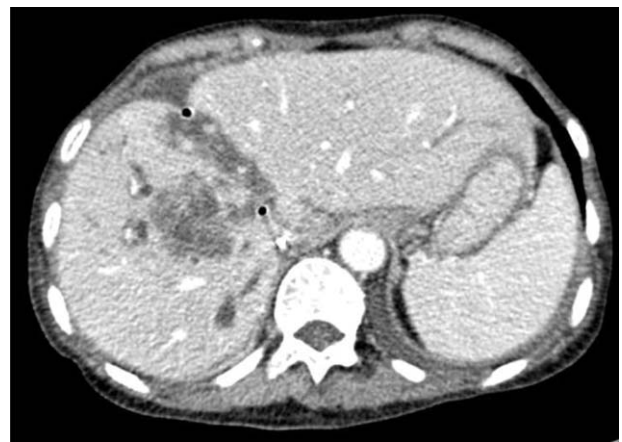
The operative times were 460 minutes for the first stage and 240 minutes for the second stage. The recoveries after the first and the second operations were uneventful, and the patient was discharged on postoperative day 11 of the second stage operation with no 90-day postoperative mortality.

### 3. Discussion

Hepatectomy may prolong the survival time of colorectal cancer patients with liver metastases.<sup>[3]</sup> However, for patients with bilateral liver metastases, a curative resection either cannot be achieved with a single procedure or would result in a too small FLR.<sup>[6]</sup> To address this problem, 2-stage liver resection with portal vein embolization (PVE) or portal vein ligation was



**Figure 1.** Preoperative computed tomography showing the tumor invading the segment VIII, segment IV, and segment III; the FLR is 376 mL. FLR = future liver remnant.



**Figure 2.** Control computed tomography at postoperative day 13 showing the hypertrophy of the left lobe; the FLR rise to 550 mL. FLR = future liver remnant.

developed to achieve sufficient hypertrophy of the FLR.<sup>[7]</sup> These techniques, however, remain controversial due to the problems of delay or absence of hypertrophy and tumor progression related to the formation of intrahepatic vascular collaterals.<sup>[6,8]</sup> In 2007, the first case of “associating liver partition and portal vein ligation for staged hepatectomy” (ALPPS) procedure was performed successfully, and since then, this technique was adopted worldwide with reported rapid growth of the FLR in 7 to 14 days and prevention of tumor progression.<sup>[9]</sup> However, ALPPS was associated with a morbidity rate as high as 68% and a mortality rate as high as 14% regarding biliary fistulas, infected collections, and posthepatectomy liver failure.<sup>[10,11]</sup> Moreover, the first stage of this technique is very aggressive and often associated with prolonged operative duration and high blood loss. Therefore, the modification surgical technique ALTPS was emerged with reduced morbidity and mortality rates. Robles et al<sup>[2]</sup> reported 22 ALTPS procedures with the same regeneration rate and less aggressiveness of both surgical interventions compared to traditional ALPPS. Instead of splitting the liver parenchyma during the first stage of the surgery, ALTPS simply placed a tourniquet in the umbilical fissure or Cantlie line and thereby reduced the aggressiveness of the first intervention. During the second stage of ALTPS, liver parenchyma transection along the tourniquet could be performed quickly with less blood loss and thereby reduced the aggressiveness of the second intervention. In this case of totally laparoscopic ALTPS, few adhesions were encountered and the transection surface shrank induced by the tourniquet which facilitated the parenchyma transection without the use of Pringle maneuver. In the era of laparoscopic surgery, it has been proved that laparoscopic hepatectomy is associated with reduced blood loss, decreased overall and liver-specific complications, shorter postoperative hospital stays, and fewer adhesions which may facilitate second hepatectomy or liver transplantation compared with traditional open liver resection.<sup>[12,13]</sup> Previous series have reported that the safety and feasibility of laparoscopic ALPPS for primary and secondary cancers of the liver for patients who were once deemed unresectable and laparoscopic ALTPS might provide an even less invasive modification of the traditional open ALPPS procedure.<sup>[14,15]</sup>

It is estimated that there are nearly 25% of colorectal cancer patients have liver metastases at presentation.<sup>[16]</sup> If patients with multiple and bilobar metastases are to be treated with a liver-first

approach, the resection of the primary could sometimes be severely protracted due to the unpredictable postoperative complications.<sup>[3]</sup> Although combined resections have been associated with an increase in morbidity and mortality rates compared to the primary-first approach followed by liver resection about 2 months later, recent studies confirmed its feasibility and safety even when major hepatectomies have to be performed.<sup>[17,18]</sup> Moreover, the simultaneous approach can minimize the use of neoadjuvant chemotherapy, which may in turn potentiate the effects of systemic chemotherapy by reducing the total volume of tumor present.

As a result, we combined the 2 less aggressive approaches and presented the totally laparoscopic ALTPS and simultaneous left hemicolectomy at step 1 for bilateral liver metastases of the primary colon cancer with no severe postoperative complications. If a resection of the primary tumor does not compromise the split procedure, the combination of pure laparoscopic ALTPS and primary resection is feasible and safe.

## References

- [1] Capussotti L, Muratore A, Baracchi F, et al. Portal vein ligation as an efficient method of increasing the future liver remnant volume in the surgical treatment of colorectal metastases. *Arch Surg* 2008;143:978–82.
- [2] Robles R, Parrilla P, López-Conesa A, et al. Tourniquet modification of the associating liver partition and portal ligation for staged hepatectomy procedure. *Brit J Surg* 2014;101:1129–34.
- [3] Wicherts DA, Miller R, de Haas RJ, et al. Long-term results of two-stage hepatectomy for irresectable colorectal cancer liver metastases. *Ann Surg* 2008;248:994–1005.
- [4] Viganò L, Karoui M, Ferrero A, et al. Locally advanced mid/low rectal cancer with synchronous liver metastases. *World J Surg* 2011;35:2788–95.
- [5] Koffron AJ, Aufferberg G, Kung R, et al. Evaluation of 300 minimally invasive liver resections at a single institution: less is more. *Ann Surg* 2007;246:385–92.
- [6] Jaeck D, Oussoultzoglou E, Rosso E, et al. A two-stage hepatectomy procedure combined with portal vein embolization to achieve curative resection for initially unresectable multiple and bilobar colorectal liver metastases. *Ann Surg* 2005;240:1049–51.
- [7] Abulkhir A, Limongelli P, Healey AJ, et al. Preoperative portal vein embolization for major liver resection: a meta-analysis. *Ann Surg* 2008;247:49–57.
- [8] Shindoh J, Vauthey JN, Zimmitti G, et al. Analysis of the efficacy of portal vein embolization for patients with extensive liver malignancy and very low future liver remnant volume, including a comparison with the associating liver partition with portal vein ligation for staged hepatectomy approach. *J Am Coll Surg* 2013;217:126–33.
- [9] Cai YL, Song PP, Tang W, et al. An updated systematic review of the evolution of ALPPS and evaluation of its advantages and disadvantages in accordance with current evidence. *Medicine* 2016;95:e3941.
- [10] Schnitzbauer AA, Lang SA, Goessmann H, et al. Right portal vein ligation combined with in situ splitting induces rapid left lateral liver lobe hypertrophy enabling 2-staged extended right hepatic resection in small-for-size settings. *Ann Surg* 2012;255:405–14.
- [11] Alvarez FA, Ardiles V, De SM, et al. Associating liver partition and portal vein ligation for staged hepatectomy offers high oncological feasibility with adequate patient safety: a prospective study at a single center. *Ann Surg* 2015;261:723–32.
- [12] Dagher I, Di GG, Dubrez J, et al. Laparoscopic versus open right hepatectomy: a comparative study. *Am J Surg* 2009;198:173–7.
- [13] Machado MA, Makdissi FF, Galvão FH, et al. Intrahepatic Glissonian approach for laparoscopic right segmental liver resections. *Am J Surg* 2008;196:38–42.
- [14] Xiao L, Li JW, Zheng SG. Totally laparoscopic ALPPS in the treatment of cirrhotic hepatocellular carcinoma. *Surg Endosc* 2015;29:2800–1.
- [15] Machado MA, Makdissi FF, Surjan RC. Totally laparoscopic ALPPS is feasible and may be worthwhile. *Ann Surg* 2012;256:e16–9.
- [16] Leonard GD, Brenner B, Kemeny NE. Neoadjuvant chemotherapy before liver resection for patients with unresectable liver metastases from colorectal carcinoma. *J Clin Oncol* 2005;23:2038–48.
- [17] Reddy SK, Pawlik TM, Zorzi D, et al. Simultaneous resections of colorectal cancer and synchronous liver metastases: a multi-institutional analysis. *Ann Surg Oncol* 2007;14:3481–91.
- [18] Capussotti L, Ferrero A, Viganò L, et al. Major liver resections synchronous with colorectal surgery. *Ann Surg Oncol* 2007;14:195–201.