

# Sudden unexpected death in epilepsy in a 14-year-old girl: case report and literature review

Journal of International Medical Research

2018, Vol. 46(5) 2031–2036

© The Author(s) 2018

Reprints and permissions:

[sagepub.co.uk/journalsPermissions.nav](http://sagepub.co.uk/journalsPermissions.nav)

DOI: 10.1177/0300060518762265

[journals.sagepub.com/home/imr](http://journals.sagepub.com/home/imr)



Xinyue Zhang<sup>1</sup>, Lichao Sun<sup>2</sup>, Li Cui<sup>1</sup> and  
Weihong Lin<sup>1</sup>

## Abstract

**Background:** Sudden unexpected death in epilepsy (SUDEP) is the most common cause of death in people with epilepsy. The pathogenesis of SUDEP is still unclear. The majority of SUDEP cases occur in intractable epilepsy, especially in the aftermath of a generalized tonic-clonic seizure. We report an atypical SUDEP case with infrequent seizures in frontal lobe epilepsy.

**Case Report:** A 14-year-old girl presented with a 13-year history of paroxysmal convulsions. She experienced three episodes within 6–10 months after birth. At 14 years old, she experienced an aggravated seizure, manifesting as unconsciousness, hyperventilation, and urinary incontinence. Electroencephalography showed spike-slow waves and slow waves with mixed asynchronized spike waves originating from the frontal lobe during the sleep stage. Transient outbreaks of spike-slow complex waves (1–2 s) were also noted in all leads. The diagnosis of frontal lobe epilepsy (generalized tonic-clonic seizures secondary to focal impaired awareness seizures and myoclonus) was made. Oral sodium valproate was prescribed. However, she suddenly died on her way to school 2 months later.

**Conclusion:** The causes of SUDEP are complicated, and frontal lobe epilepsy may be a potential risk factor. Early diagnosis and appropriate treatment of epileptic seizures, as well as close observation, should be emphasized.

<sup>1</sup>Department of Neurology, Neuroscience Center, The First Hospital of Jilin University, Changchun, Jilin, China

<sup>2</sup>Department of Emergency, The First Hospital of Jilin University, Changchun, Jilin, China

## Corresponding author:

Weihong Lin, Department of Neurology, Neuroscience Center, The First Hospital of Jilin University, 71 Xinmin Street, Changchun, Jilin 130021, China.

Email: [linweihong321@126.com](mailto:linweihong321@126.com)



Creative Commons Non Commercial CC BY-NC: This article is distributed under the terms of the Creative Commons Attribution-NonCommercial 4.0 License (<http://www.creativecommons.org/licenses/by-nc/4.0/>)

which permits non-commercial use, reproduction and distribution of the work without further permission provided the original work is attributed as specified on the SAGE and Open Access pages (<https://us.sagepub.com/en-us/nam/open-access-at-sage>).

**Keywords**

Sudden unexpected death in epilepsy, frontal lobe epilepsy, pediatric epilepsy, electroencephalogram, pathogenesis, tonic-clonic seizure

Date received: 17 October 2017; accepted: 8 February 2018

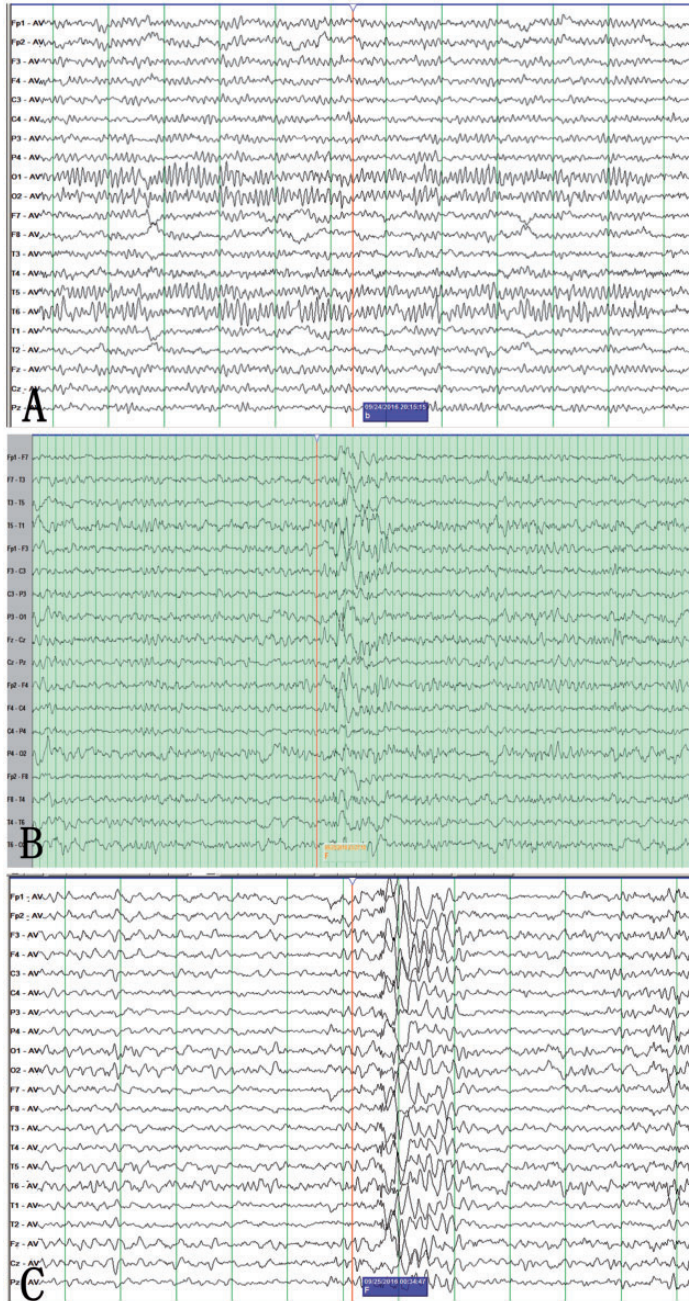
**Introduction**

Sudden unexpected death in epilepsy (SUDEP) is defined as sudden, unexplained, nontraumatic (e.g., head injury), and nondrowning death in an individual with epilepsy, in which the autopsy discloses no toxicological or anatomical cause.<sup>1</sup> The death may be witnessed or unwitnessed, and it may or may not occur after a seizure. SUDEP is the most common cause of death in patients suffering from epilepsy.<sup>2</sup> The pathogenetic mechanisms underlying SUDEP have still not been fully determined, but possible risk factors include the following: 1) uncontrolled or frequent seizures; 2) generalized convulsive/tonic-clonic seizures; 3) seizures beginning at a young age; 4) long epileptic course; 5) missed doses of antiepileptic drugs; and 6) alcohol abuse.<sup>3–5</sup> According to previous studies, the majority of SUDEP cases occur in intractable epilepsy, especially in the aftermath of a generalized tonic-clonic seizure.<sup>6</sup> We report an atypical SUDEP case with infrequent seizures in frontal lobe epilepsy.

**Case report**

A 14-year-old girl presented with a 13-year history of afebrile convulsions. She experienced three episodes within 6–10 months after birth, manifesting as rolling eyes, body stiffness, and unconsciousness. Each seizure occurred during the daytime, lasted for several minutes, and spontaneously resolved. No antiepileptic drugs were used.

At the age of 13 years, the convulsions relapsed, manifesting as turning of the eyes, asynchronous jerks of the limbs, and disturbance of consciousness. Prior to admission to our hospital, she experienced convulsions again, manifesting as unconsciousness, collapse, hyperventilation, and urinary incontinence. The previous medical history was unremarkable. There was no cardiac, pulmonary, or hepatorenal disease. A physical examination and brain magnetic resonance imaging showed no abnormalities. Electroencephalographic (EEG) monitoring for 24 h revealed spike-slow waves and slow waves with mixed asynchronized spike waves originating from the frontal lobe during the sleep stage, and there was also a tendency for slight generalization. Transient outbreaks of spike-slow complex waves (lasting for 1–2 s) were observed in all leads (Figure 1). Laboratory examinations, an electrocardiogram, and cardiac color ultrasound were all normal. The diagnosis of frontal lobe epilepsy (generalized tonic-clonic seizures secondary to focal impaired awareness seizures and myoclonus) was made. Oral sodium valproate with a dosage of 500 mg/day was prescribed, and no epileptic seizures were observed thereafter. However, 2 months later, our patient suddenly died on her way to school. The death was unwitnessed, and surveillance video showed that the girl fell over suddenly during walking with generalized tonic-clonic seizures, which manifested as four-limb convulsions, blood in the mouth, and urinary incontinence.



**Figure 1.** Electroencephalogram of the patient

(A) Electroencephalogram background activity showing a slightly generalized  $\alpha$  rhythm and normal sleep stages. (B) Electroencephalogram showing irregular, high-amplitude, spike-slow, and sharp-slow waves originating from the frontal lobe. (C) Electroencephalogram showing transient outbreaks of spike-slow complex waves (lasting for 1–2 s) in all leads.

No post-mortem examination was performed. The death was considered to be associated with SUDEP.

This study was approved by the Institutional Review Board and Ethics Committee of The First Hospital of Jilin University. Informed consent was obtained from the patient's parents.

## **Discussion**

SUDEP has gained more attention recently, and it has been a hot focus of epilepsy research. There are six SUDEP subtypes that are classified according to the following diagnostic criteria.<sup>7</sup> (1) Definite SUDEP is sudden, unexpected, nontraumatic, and nondrowning death of an individual with epilepsy, occurring in a safe situation, witnessed or unwitnessed, with or without a prior seizure. Status epilepticus can be excluded, and a post-mortem examination shows no specific cause of death. (2) Definite SUDEP plus satisfies the definition of definite SUDEP, as well as the possibility that a concomitant death-causing factor can be identified before or after death, the death may be caused by the combined effect of both conditions, or if post-mortem examination or direct observation of the death cannot identify a definitive cause of death. (3) Probable SUDEP/probable SUDEP plus satisfies the definition of definite SUDEP, but without post-mortem evidence. The individual dies unexpectedly in a healthy condition and in a safe situation, with no definite organic cause of death. (4) Possible SUDEP is defined as when there is a competing cause of death. (5) Near-SUDEP/near-SUDEP plus is defined as when an individual experiences cardiorespiratory arrest without any organic cause, surviving for more than 1 h after resuscitation. (6) Not SUDEP is defined as a definite cause of death rather than epilepsy. (7) Unclassified SUDEP is when information is incomplete, and thus case classification

is impossible. In the current case, the girl suddenly fell over when she was walking on her way to school, and the circumstances were safe. There was no witness and no post-mortem examination was performed. This condition is consistent with probable SUDEP.

According to previous reports, the risk factors of SUDEP are variable, including potential genetic predisposition, male sex, onset at a young age, frequent convulsive seizures, and multidrug therapy<sup>5</sup>. A recent study showed that the foremost and definitive risk factor of SUDEP is frequent, generalized tonic-clonic seizures. Individuals with three or more generalized tonic-clonic seizures per year have a 15-fold higher risk of SUDEP.<sup>8</sup> SUDEP-associated risk factors with low evidence include the following: nocturnal epileptic seizures, use of antiepileptic drugs, use of lamotrigine in female patients, untreated with antiepileptic drugs, the number of antiepileptic drugs used overall, variable heart rate, extratemporal epilepsy, mental/intellectual deficiency, and use of anxiolytic drugs. Other potential risk factors of SUDEP with very low evidence or conflicting evidence are as follows: overall seizure frequency evaluated based on all seizure types, medically refractory epilepsy, uncontrolled seizures, monotherapy or polytherapy with antiepileptic drugs (carbamazepine, phenytoin, or sodium valproate), dosage of antiepileptic drugs (above, below, or within the reference range), onset age of epilepsy, structural lesion on magnetic resonance imaging, duration of epilepsy, use of psychotropic drugs, psychological disorders, idiopathic or localization-related epilepsy, pulmonary disorders, alcohol abuse, use of lamotrigine in patients with refractory epilepsy, frequent changes in antiepileptic drugs, monitoring of antiepileptic drugs, undergoing surgical resection, Engel scores following surgery for epilepsy, postictal EEG suppression, and use of a vagus nerve stimulator.<sup>8</sup>

In the present case, the girl was diagnosed with epilepsy 13 years ago. Despite the long history of epilepsy, seizures were rare (five times in total). According to the EEG characteristics, the diagnosis of frontal lobe convulsive epilepsy with myoclonus was made. In previous reports, researchers found that sleep-related hypermotor epilepsy (nocturnal frontal lobe epilepsy) was associated with SUDEP, with an incidence of 0.36 per 1000 person-years.<sup>9</sup> These findings are inconsistent with the current case. Our patient had infrequent seizures, and the frontal lobe epilepsy attack occurred during the daytime. Therefore, there may be multiple complicated factors underlying the occurrence of SUDEP.

The pathogenesis of SUDEP is still debatable. There have been several theoretical hypotheses, including sinus bradycardia or cardiac arrest, respiratory depression, brain dysfunction, autonomic dysfunction, and abnormal central regulation.<sup>10,11</sup> Sudden cardiac arrest and apnea have been considered as direct causes of SUDEP.<sup>7,12</sup> However, some other researchers have proposed that respiratory and circulation dysfunction is caused by cerebral disturbances.<sup>13</sup>

In most cases, SUDEP occurs following generalized tonic-clonic seizures, suggesting that seizures may play a major role in SUDEP. The pathophysiology of SUDEP appears complex and may involve variable factors, such as loss of arousal, time of day, position of the patient during the seizures, intrinsic pulmonary and cardiac dysfunction, and genetic mutations that predispose patients with epilepsy to seizure-induced cardiorespiratory dysfunction.<sup>14</sup> Impaired breathing is thought to play a critical role in SUDEP. When seizures spread to the amygdala from the forebrain sites, central apnea and O<sub>2</sub> desaturation occur.<sup>15</sup> In the current case, the cause of death was frontal lobe epilepsy. The frontal lobe, which accounts for the majority of the cerebral

cortex, has extensive fiber connections with the temporal lobe and insular cortex.<sup>16</sup> Therefore, we speculate that frontal lobe epilepsy may cause extensive disturbances in the cerebral cortex, eventually leading to cardiac arrest. However, the exact pathogenetic mechanisms still require further research.

## Conclusion

We present a girl with frontal lobe epilepsy who succumbed to SUDEP. The causes of SUDEP are complicated, and frontal lobe epilepsy may be a potential risk factor of this condition. Early diagnosis and appropriate treatment of epileptic seizures, as well as close observation, should be highlighted.

## Declaration of conflicting interest

The authors declare that there is no conflict of interest.

## Funding

This research received no specific grant from any funding agency in the public, commercial, or not for profit sectors.

## References

1. Nashef L. Sudden unexpected death in epilepsy: terminology and definitions. *Epilepsia* 1997; 38: S6–S8.
2. Tu E, Bagnall RD, Dufflou J, et al. Post-mortem review and genetic analysis of sudden unexpected death in epilepsy (SUDEP) cases. *Brain Pathol* 2011; 21: 201–208.
3. Devinsky O. Sudden, unexpected death in epilepsy. *N Engl J Med* 2011; 365: 1801–1811.
4. Tomson T, Nashef L, Ryvlin P. Sudden unexpected death in epilepsy: current knowledge and future directions. *Lancet Neurol* 2008; 7: 1021–1031.
5. Nei M, Hays R. Sudden unexpected death in epilepsy. *Curr Neurol Neurosci Rep* 2010; 10: 319–326.
6. Shankar R, Donner EJ, McLean B, et al. Sudden unexpected death in epilepsy

- (SUDEP): what every neurologist should know. *Epileptic Disord* 2017; 19: 1–9.
7. Nashef L, So EL, Ryvlin P, et al. Unifying the definitions of sudden unexpected death in epilepsy. *Epilepsia* 2012; 53: 227–233.
  8. Harden C, Tomson T, Gloss D, et al. Practice guideline summary: sudden unexpected death in epilepsy incidence rates and risk factors: report of the guideline development, dissemination, and implementation subcommittee of the American academy of neurology and the American epilepsy society. *Neurology* 2017; 88: 1674–1680.
  9. Mostacci B, Bisulli F, Vignatelli L, et al. Incidence of sudden unexpected death in epilepsy in sleep-related hypermotor epilepsy, formerly named nocturnal frontal lobe epilepsy. *Sleep Med* 2017; 29: 98.
  10. Shorvon S and Tomson T. Sudden unexpected death in epilepsy. *Lancet* 2011; 378: 2028–2038.
  11. Li J, Ming Q and Lin W. The insula lobe and sudden unexpected death in epilepsy: a hypothesis. *Epileptic Disord* 2017; 19: 10–14.
  12. Surges R, Adjei P, Kallis C, et al. Pathologic cardiac repolarization in pharmacoresistant epilepsy and its potential role in sudden unexpected death in epilepsy: a case-control study. *Epilepsia* 2010; 51: 233–242.
  13. Terra VC, Cysneiros R, Cavalheiro EA, et al. Sudden unexpected death in epilepsy: from the lab to the clinic setting. *Epilepsy Behav* 2013; 26: 415–420.
  14. Dlouhy BJ, Gehlbach BK and Richerson GB. Sudden unexpected death in epilepsy: basic mechanisms and clinical implications for prevention. *J Neurol Neurosurg Psychiatry*. 2016; 87: 402–413.
  15. Dlouhy BJ, Gehlbach BK, Kreple CJ et al. Breathing Inhibited When Seizures Spread to the Amygdala and upon Amygdala Stimulation. *J Neurosci* 2015; 35: 10281–10289.
  16. Mostacci B, Bisulli F, Vignatelli L, et al. Incidence of sudden unexpected death in nocturnal frontal lobe epilepsy: a cohort study. *Sleep Med* 2015; 16: 232–236.