



Clinical Evaluation of the Reconstruction of the Biceps Brachii using Triceps Graft*

Avaliação clínica da reconstrução do bíceps braquial com enxerto de tríceps

Thiago Medeiros Storti¹ Rafael Gomes Dias² Gabriel Cesar Dias Dantas³
 Rafael Salomon Silva Faria² João Eduardo Simionatto² Alexandre Firmino Paniago²

¹Instituto de Pesquisa e Ensino, Hospital Ortopédico e Medicina Especializada, Brasília, DF, Brazil

²Instituto do Ombro de Brasília, Brasília, DF, Brazil

³Centro Universitário de Brasília, Brasília, DF, Brazil

Address for correspondence Rafael Salomon Silva Faria, Quadra 102 norte, praça Perdiz, Lote 05, Condomínio Residencial Matisse Antares, Águas Claras, DF, 71.907-000, Brazil
 (e-mail: thiago_storti@hotmail.com).

Rev Bras Ortop 2021;56(5):656–663.

Abstract

Objective Clinical and functional evaluation of the surgical treatment for chronic injury of the distal biceps brachii applying a surgical technique with grafting of the distal triceps brachii tendon.

Methods A study based on a review of the medical records and clinical evaluation of the patients submitted to surgical treatment for chronic injury to the distal insertion of the biceps brachii between February 2015 and February 2017. In a 12-month-minimum postoperative follow-up, 7 patients were evaluated regarding the range of motion of the operated and non-operated elbows, flexion, upper-limb extension and supination with a digital dynamometer, the hook test, the satisfaction index, and the Disabilities of the Arm, Shoulder and Hand (DASH) and Mayo Elbow Performance Score (MEPS) instruments.

Results During the postoperative functional evaluation, no patient reported dissatisfaction with the esthetic outcome of the incisions, and all of them were satisfied/very satisfied with the range of motion and strength of the operated limb. No neurovascular complications, surgical site infection or tendon rupture were observed. On the MEPS and DASH scales, all patients scored 100 and 0 respectively. The mean flexion was of 133.5° on the operated side, versus 139.2° on the non-operated side. The mean extension was of 5° on the operated side versus 0° on the non-operated side. The supination was of 86.5° versus 90°, and the pronation, 80° versus 80°, when comparing the operated and non-operated sides respectively. The mean flexion, extension and

Keywords

- ▶ autografting
- ▶ elbow
- ▶ orthopedic procedures
- ▶ tendon injuries
- ▶ upper extremity

* Work performed at Hospital Ortopédico e Medicina Especializada (HOME), Brasília, DF, Brazil.

received
February 12, 2020
accepted
October 28, 2020
published online
August 13, 2021

DOI <https://doi.org/10.1055/s-0041-1729566>.
ISSN 0102-3616.

© 2021. Sociedade Brasileira de Ortopedia e Traumatologia. All rights reserved.

This is an open access article published by Thieme under the terms of the Creative Commons Attribution-NonDerivative-NonCommercial-License, permitting copying and reproduction so long as the original work is given appropriate credit. Contents may not be used for commercial purposes, or adapted, remixed, transformed or built upon. (<https://creativecommons.org/licenses/by-nc-nd/4.0/>)

Thieme Revinter Publicações Ltda., Rua do Matoso 170, Rio de Janeiro, RJ, CEP 20270-135, Brazil

supination corresponded respectively to 92.5%, 96.4% and 86.8% of those of the non-operated limb.

Conclusion Reconstrution of the distal biceps brachii with triceps grafting seems to be an effective and safe option for the treatment of chronic distal biceps injuries.

Resumo

Objetivo Avaliação clínica e funcional do tratamento cirúrgico da lesão crônica do bíceps braquial distal, por aplicação de técnica cirúrgica com enxerto de tendão do tríceps braquial distal.

Métodos Estudo baseado em revisão de prontuários e avaliação clínica de pacientes com lesão crônica da inserção distal do bíceps braquial submetidos a tratamento cirúrgico entre fevereiro de 2015 e fevereiro de 2017. Durante o acompanhamento pós-operatório mínimo de 12 meses, 7 pacientes foram avaliados quanto à amplitude de movimento dos cotovelos operado e não operado, à força de flexão, à extensão e supinação dos membros superiores, determinadas com dinamômetro digital, ao teste do gancho, ao índice de satisfação, e às escalas Disabilities of the Arm, Shoulder and Hand (DASH) e Mayo Elbow Performance Score (MEPS).

Resultados À avaliação funcional pós-operatória, nenhum paciente relatou insatisfação com o aspecto estético das incisões; todos ficaram satisfeitos/muito satisfeitos com a amplitude de movimento e a força do membro operado. Complicações neurovasculares, infecção de sítio cirúrgico, ou ruptura de tendão não foram observadas. Nas escalas MEPS e DASH, todos os pacientes apresentaram pontuações iguais a 100 e 0, respectivamente. A flexão média foi de 133,5° no lado operado, contra 139,2° no lado não operado. A extensão média foi de 5° no lado operado, contra 0° no lado não operado. A supinação foi de 86,5° contra 90°, e a pronação foi de 80° contra 80°, ao se comparar os lados operado e não operado, respectivamente. As forças médias de flexão, extensão e supinação corresponderam, respectivamente, a 92,5%, 96,4%, e 86,8% das forças do membro não operado.

Conclusão A reconstrução do bíceps braquial distal com enxerto de tríceps parece ser uma opção eficaz e segura para o tratamento de lesões crônicas do bíceps distal.

Palavras-chave

- ▶ autoenxerto
- ▶ cotovelo
- ▶ procedimentos ortopédicos
- ▶ lesões tendíneas
- ▶ membro superior

Introduction

The biceps brachii is the primary supinator and secondary flexor of the forearm.¹ Ruptures of the distal tendon of the biceps brachii are rare injuries, and usually affect the dominant limb of middle-aged men. The injury typically occurs with an eccentric contraction with the elbow at 90° of flexion.² The clinical condition is characterized by acute pain, edema and local ecchymosis, associated with an audible click at the moment of the injury, besides the presence of a proximal gap to the cubital fossa and loss of forearm supination force and elbow flexion.

Significant loss of bending force and more pronounced loss of supination force are often associated with chronic ruptures.² The main risk factors are: use of anabolic steroids, weight lifting, and smoking.³ Degenerative tendinopathy and certain endocrine diseases are also implicated in the appearance of this pathology.⁴ The rupture is considered chronic after 4 to 6 weeks of the injury.¹ In these cases, the musculotendinous unit retracts and fibrosis formed, which makes the repair of the radial tuberosity difficult.⁵⁻⁷ However, the conservative treatment has shown unsatisfactory results.⁸

Several procedures have been described to treat chronic ruptures of the distal biceps brachii tendon, including brachial tenodesis and the use of tendon grafting, such as the long palmar, calcaneus tendon, tensor fasciae lata, and semitendinosus.^{4,9,10} The aim of the present study was to describe the clinical and functional results of the distal reconstruction of the biceps brachii using central distal triceps graft by fixating two bioabsorbable anchors in the radial tuberosity in patients with distal biceps injury for more than four weeks. This technique was recently published by the authors.

Material and Methods

From February 2015 to February 2017, 7 patients with distal biceps injury for more than 28 days were submitted to reconstruction of the distal biceps with triceps graft (► **Table 1**). All patients were male, with an average age of 45 years (range: 30 to 60 years). The injury was in the dominant limb in three cases. Three patients reported using anabolic steroids.

Table 1 Patient data

	Patient 1	Patient 2	Patient 3	Patient 4	Patient 5	Patient 6	Patient 7
Affected limb and dominance	Left non-dominant	Left dominant	Right dominant	Left non-dominant	Right dominant	Left non-dominant	Left non-dominant
Gender and age	Male, 47 years	Male, 51 years	Male, 60 years	Male, 57 years	Male, 40 years	Male, 30 years	Male, 32 years
Injury duration	3 months	6 weeks	6 weeks	5 months	4 weeks	5 months	3 months
Use of anabolic steroids	No	No	No	No	Yes	Yes	Yes
Follow-up	18 months	36 months	24 months	24 months	12 months	12 months	12 months
Force: operated side	Flexion: 22.4 N; extension: 19.2 N; supination: 3.1 N	Flexion: 22.4 N; extension: 18.7 N; supination: 3.9 N	Flexion: 17.3 N; extension: 13.4 N; supination: 2.2 N	Flexion: 14.3 N; extension: 13 N; supination: 1.9 N	Flexion: 24.8 N; extension: 24.8 N; supination: 3.3 N	Flexion: 30.7 N; extension: 28.4 N; supination: 4.7 N	Flexion: 33.9 N; extension: 31.9 N; supination: 4.5 N
Force: non-operated side	Flexion: 22.6 N; extension: 20 N; supination: 3.6 N	Flexion: 22.6 N; extension: 18.8 N; supination: 4 N	Flexion: 18.6 N; extension: 15.3 N; supination: 2.5 N	Flexion: 21.5 N; extension: 13.1 N; supination: 2.5 N	Flexion: 26 N; extension: 25.5 N; supination: 3.9 N	Flexion: 31.6 N; extension: 29.5 N; supination: 5.3 N	Flexion: 34.8 N; extension: 32.3 N; supination: 5.2 N
Comparison (%)	Flexion: 99.1%; extension: 96%; supination: 86%	Flexion: 99.1%; extension: 99.4%; supination: 97.5%	Flexion: 93%; extension: 87.5%; supination: 88%	Flexion: 66.5%; extension: 99.2%; supination: 76%	Flexion: 95.3%; extension: 97.2%; supination: 84.6%	Flexion: 97.1%; extension: 96.2%; supination: 88.6%	Flexion: 97.4%; extension: 98.7%; supination: 86.5%
Flexion: operated side	140°	130°	130°	140°	135°	135°	140°
Extension: operated side	5°	0°	0°	10°	0°	0°	0°
Supination: operated side	85°	80°	90°	90°	90°	85°	90°
Pronation: operated side	80°	80°	80°	80°	80°	80°	80°
Score on the MEPS	100	100	100	100	100	100	100
Score on the DASH	0	0	0	0	0	0	0
Satisfaction	Satisfied	Satisfied	Very satisfied	Satisfied	Very satisfied	Very satisfied	Satisfied

Abbreviations: DASH, Disabilities of the Arm, Shoulder and Hand; MEPS, Mayo Elbow Performance Score.

The mean postoperative follow-up was of 18 months (range: 12 to 36 months). The main mechanism of injury was eccentric contraction of the biceps brachii. The patients underwent surgery on average 3 months after injury (range: 1 to 5 months). Upon physical examination, they showed loss of elbow flexion force, especially supination. The hook test was positive for injury in all patients preoperatively, and negative at the last follow-up. All of them had diagnoses confirmed by magnetic resonance imaging to evaluate the degree of the injury and of the tendon shortening.

The complications and risks involved in the treatment were explained to the patients, as well as the need for autologous tissue for grafting if primary reinsertion of the bicipital tendon was not possible. In the postoperative period, the Disabilities of the Arm, Shoulder and Hand (DASH) and Mayo Elbow Performance Score (MEPS) instruments were applied, and the movement test of the operated and non-operated elbows was performed through a manual goniometer. Moreover, the flexion, extension and supination forces of the operated and non-operated limbs were evaluated, comparing the results. A digital dynamometer (Lafayette Hand-Held Dynamometer, model 01163, Lafayette Instrument, Lafayette, IN, US) was used to measure the flexion, extension and supination forces using properly-marked a wooden rod to facilitate the measurement of the supination and not interfere with the momentum of the applied forces. Four measurements were always taken by the same evaluator, and the average of the last three was obtained. The first measurement was disregarded to avoid the learning bias of the way of measuring by the patient. Finally, the patients were evaluated as to the degree of satisfaction (dissatisfied, not satisfied, satisfied and very satisfied).

The work was approved by the ethics committee of the institution under CAAE number 69377517.5.0000.0023.

Surgical Technique

The surgeries were performed under general anesthesia associated with locoregional block of the brachial plexus in horizontal dorsal decubitus without the use of tourniquets. We opted for the two-incision technique described by Boyd and Anderson¹¹ and modified by Morrey et al.,⁷ and used a graft from the distal tendon of the triceps brachii. The criterion used to define the tendon reconstruction was the impossibility of excursion of the remnant tendon up to the radial tuberosity, even after release of the lacertus fibrosus. A transverse incision of ~ 3 cm is made in the anterior cubital fold. The biceps tendon is easily captured when the skin is pulled proximally and is removed from the deep tissues. The most distal portion of the degenerated tendon is resected and repaired with Bunnell stitches using #5 nonabsorbable sutures (► Fig. 1). Then, the radial tuberosity is palpated, and a curved Kelly caliper is passed through the biceps tendon tunnel between the ulna and the radius, advancing until its apex is palpated in the dorsal aspect of the proximal forearm. The second incision is made on the caliper. The tuberosity is exposed by means of muscular divulsion, with the forearm at maximum pronation. The radial

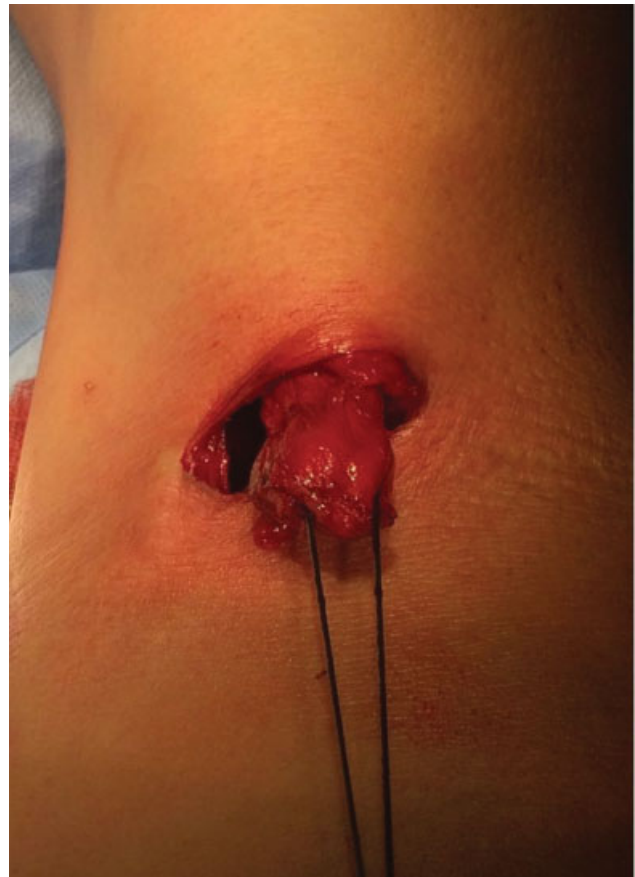

Fig. 1 Distal biceps tendon after release showing the impossibility of direct repair.

tuberosity is scarified until it starts bleeding, and two double-loaded bioabsorbable 2.9-mm anchors are positioned in it.

Next, the graft of the triceps brachii is collected without olecranon bone fragments through a posterior longitudinal incision and subcutaneous dissection until its tendon is exposed. We chose to remove a 1-cm wide and 10-cm long strip of its average portion, without the need for ulnar nerve exploration. Later, we approached the medial and lateral borders to the removed portion and closed the gap that was left (► Fig. 2).

The most distal end of the graft is attached to the tuberosity through four U-stitches with the anchor sutures (► Fig. 3). The other end of the tendon is then passed to the region of the incision of the antecubital fossa with Krackow #5 nonabsorbable sutures to pull the tendon through the tunnel previously occupied by the biceps tendon. The biceps is mobilized and then pulled by using Allis tweezers. We positioned the elbow between 40° and 60° of flexion, with the forearm in full supination. Moderate traction is applied to the graft while distal traction is applied to the tendon stump. The two structures are initially stabilized with a #5 nonabsorbable U-shaped suture, and then several simple stitches are applied to their edges (► Fig. 4). Once the reconstruction is completed, the wounds are closed, and compressive dressings and immobilization are performed with a plaster brachial splint, keeping the elbow at 90° of flexion and the forearm at light supination.

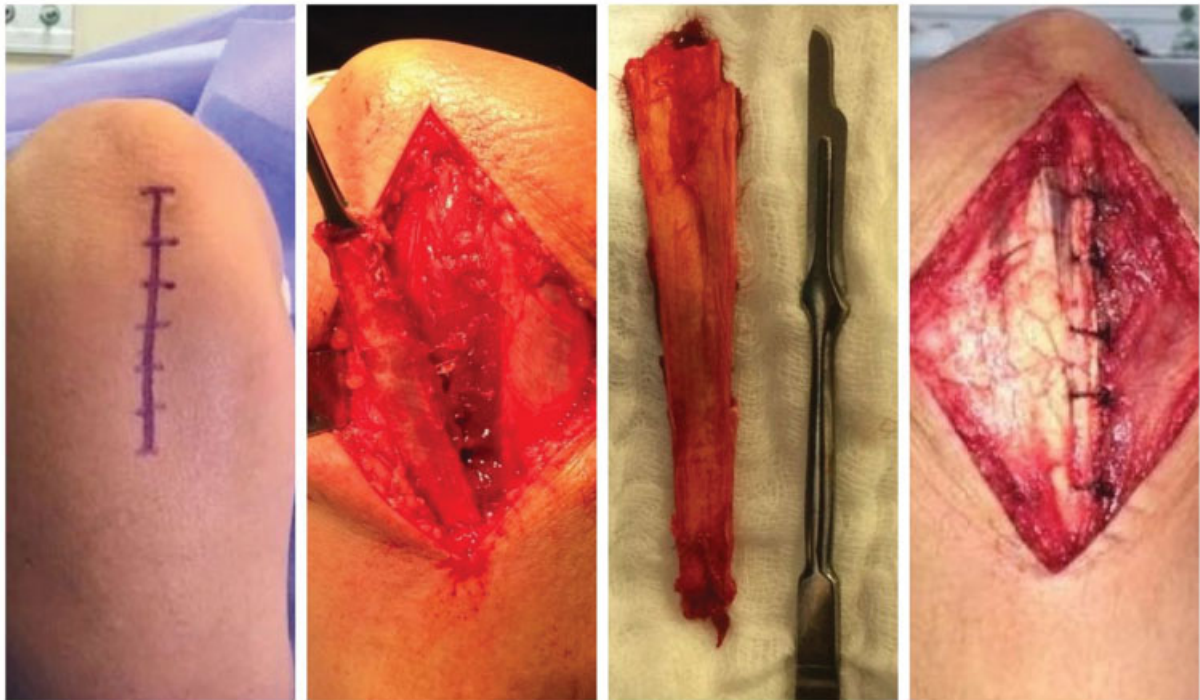


Fig. 2 I) Incision for the triceps tendon graft; II) resection of the central part of the tendon measuring 10 cm x 1 cm; III) triceps tendon graft; IV) suture of the remaining triceps tendon.

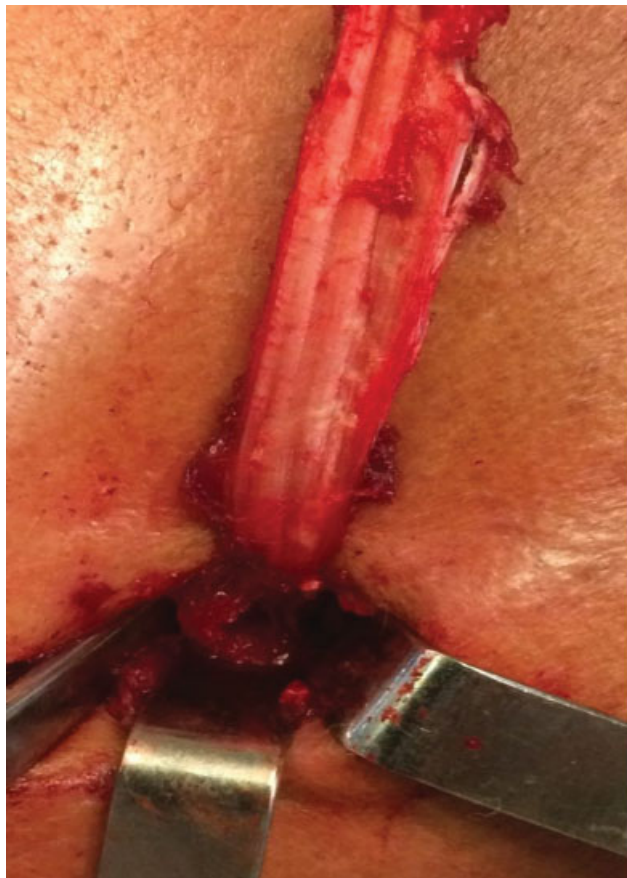

Fig. 3 The distal end of the graft attached to the biceps tuberosity.

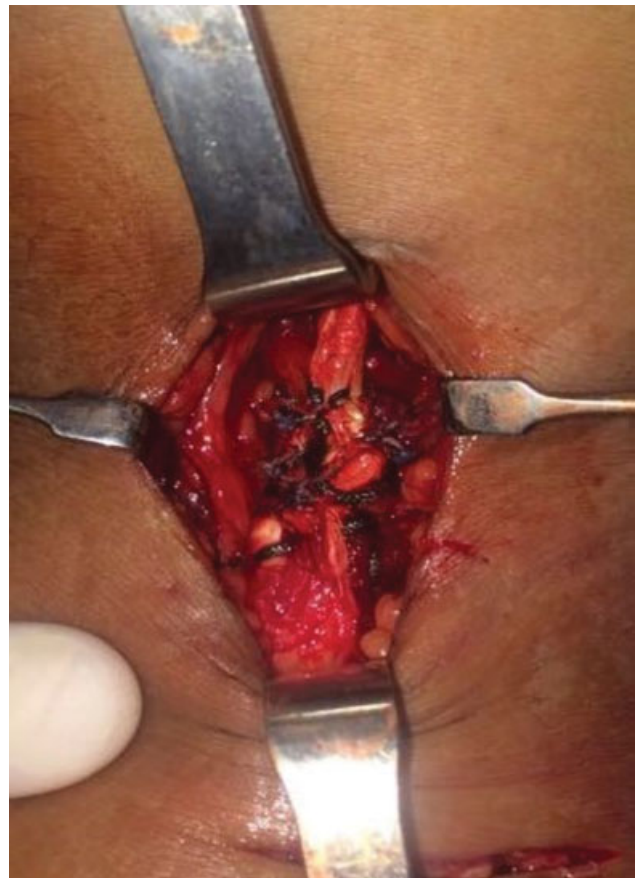

Fig. 4 Suture between the proximal part of triceps graft and the distal biceps tendon.

The immobilization was maintained for two weeks, when the physiotherapeutic treatment was initiated. Initially, passive flexion exercises and limited active extension with the supinated forearm were performed, in addition to passive and active supination-pronation up to 50°. The patients maintained the limb in the sling as long as they were not undergoing physiotherapy. This phase lasted four weeks, when the flexion and active supination gain began without load and the patient was advised to remain without the sling. Light muscle strengthening exercises were started after the sixth week, with progressive increase in the load.

Statistical Analysis

The descriptive analysis presented in tables the observed data, which were expressed as measurements of central tendency and adequate dispersion.

The inferential analysis was composed of the Mann-Whitney test to verify if there was a significant difference in the strength parameter between the operated and non-operated sides.

The normality in the distribution of numerical data was assessed by the Shapiro-Wilk test and graphical analysis of the histograms. The criterion to determine significance was the level of 5%. The statistical analysis was processed using the Statistical Package for the Social Sciences (SPSS, IBM Corp., Armonk, NY, US) software, version 26.

Results

All patients were satisfied/very satisfied with the functional results. The average flexion was of ~ 133.5°, corresponding to 95.9% of that of the non-operated limb. The mean extension was of 3.5°, and it corresponded to 97.5% of that of the non-operated limb. One patient had a flexion contracture of 10° that was maintained at the last follow-up visit (24 months after surgery). The mean supination was of 86.5°, and the pronation level was of 80°, which corresponded to 96% and 100% relative to the contralateral limb respectively (→ **Table 2**).

Based on the MEPS, all patients achieved excellent results, with a score of 100. According to the DASH questionnaire, all patients presented a result of 0. The average flexion force was of 23.7 N, whereas the supination was of 3.4 N, and the extension, 21.3 N, and they corresponded respectively to 92.5%, 86.8% and 96.4% of the average of the force on the non-operated side (→ **Table 3**).

Due to the very small sample size, was proposed to analyze the data using the nonparametric approach. In addition certain parameters under study did not show normal (Gaussian) distribution according to the Shapiro-Wilk test. Therefore, the most appropriate measurements to summarize these data are by quartiles (median and interquartile range: Q1–Q3). There was no statistically significant difference in the strength parameter.

There were no neurovascular complications, surgical site infection, tendon rerupture, cortical radius fracture or heterotopic ossification.

Table 2 Comparison of the range of motion between the operated and non-operated sides

Flexion	Average, Minimum, Maximum	
Operated limb	133.5°, 130°, 140°	95.9%
Non-operated limb	139.2°, 135°, 140°	
Extension		
Operated limb	3.5°, 10°, 0°	97.5%
Non-operated limb	0°, 0°, 0°	
Supination		
Operated limb	86.5°, 80°, 90°	96%
Non-operated limb	90°, 90°, 95°	
Pronation		
Operated limb	80°, 80°, 80°	100%
Non-operated limb	80°, 80°, 80°	

Table 3 Comparison of force between the operated and non-operated sides

Flexion	Average, Median, Interquartile Range	p
Operated side	23.7 N, 22.4 N, 17.3–30.7	0.48
Non-operated side	25.4 N, 22.6 N, 21.5–31.6	
%	92.5, 97.2, 93.0–99.1	
Supination		
Operated side	3.4 N, 3.3 N, 2.2–4.5	0.37
Non-operated side	3.9 N, 3.9 N, 2.5–5.2	
%	86.8, 86.5, 84.6–88.7	
Extension		
Operated side	21.3 N, 19.2 N, 13.4–28.4	0.65
Non-operated side	22.1 N, 20.0 N, 15.3–29.5	
%	96.4, 97.3, 96.0–99.2	

Discussion

The primary repair of a chronic rupture of the distal biceps brachii is technically challenging. Non-anatomical tenodesis in the brachialis muscle has been proposed as a treatment option. However, despite the high satisfaction rate of patients undergoing this procedure, Klonz et al.¹² observed that half of their patients lost more than 50% of the supination force. The risk of supination weakness following the employment of this technique may be unacceptable for patients with high functional demand. Several techniques for the reconstruction of the distal biceps brachii have been described; they differ in terms of access, grafting choice, and type of fixation.^{1,2,5,6} Both autografts and allografts have been used for this purpose.

Several allograft options have been described in the literature,^{1,13,14} including the Achilles tendon, the semitendinosus, the tibialis anterior, and the gracilis. With respect

to autografts,^{1,2,5,6} we find descriptions of the use of the fascia lata, the semitendinosus and the long palmar. We did not find in the literature a description of the use of the distal tendon of the triceps brachii for this purpose. The use of this tendon as an autograft for chronic ruptures of the distal biceps brachii was designed by us to avoid the inconveniences of the recovery period observed when the donor area is not located in the same joint as the recipient area. Additionally, other advantages are the presence of this donor tendon in all members of the population, the absence of neurovascular risks during its collection, and the possibility of variable lengths and sizes, according to the need.

Martin et al.¹⁵ evaluated the biomechanical characteristics of the graft of the central portion of the triceps brachii and concluded that the triceps graft is comparable to the long palmar tendon in terms of final load failure and rigidity. They also observed that the triceps tendon presents greater deformation, but this finding had no statistical significance. In another biomechanical study, Baumfeld et al.¹⁶ evaluated the properties of the medial, central and lateral distal triceps, and concluded that the lateral portion is significantly thinner and less rigid in relation to the central and medial portions, and that the central portion of the triceps brachii presents a final failure load of 704 N, against 357 N of that of the long palmar.

Wiley et al.² compared two groups of patients with chronic ruptures of the distal biceps brachii, one treated conservatively, and the other, submitted to reconstruction with semitendinosus autograft using the two-incision technique. They concluded that the patients submitted to reconstruction obtained an improvement in flexural and supination strength, when compared with patients treated conservatively.

Hallam and Bain¹⁰ evaluated nine patients after repair using autologous semitendinosus grafts, fixation with the Endobutton (Smith & Nephew, Inc., Andover, MA, US) device, and anterior approach in S. As in the present study, they also observed an excellent MEPS score in all cases, range of motion close to normal, and no complications regarding the postoperative results.

Terra et al.¹⁷ evaluated 8 patients after direct repair of chronic injuries, with an average time between injury and surgery of 71.8 days (range: 28 to 180 days). They used the anterior approach, and the fixation method was Endobutton associated with an interference screw. These authors also obtained excellent results on the MEPS; however, a flexion strength of 79.25% of that of the contralateral strength and supination of 89.75% was observed. The results of the present study show a similar supination strength, but superior flexion strength. Furthermore, in our series, direct repair of the lesions was not possible, not even with the elbow in flexion.

Using an Achilles tendon allograft, Sanchez-Sotelo et al.,¹³ in their study with 4 patients, showed excellent results according on the MEPS (score of 100 in all cases), with normal range of motion and normal strength in relation to the contralateral side in 2 patients, and slightly decreased in the other 2.

There are several options for the fixation of the tendon to the radial tuberosity (bone tunnel, interference screw, Endobutton, and suture anchors), with the Endobutton

having the highest biomechanical strength, followed by suture anchors. However, when subjected to physiological forces, there is no statistically significant difference between them.^{18,19} There is also the possibility of repairing the tendon with the Endobutton and interference screw for chronic injuries of the distal biceps, which enable a more rigid and resistant fixation with two implants and early rehabilitation.¹⁷ However, anchorage techniques demonstrate optimal clinical and functional results.²⁰

Although there is still a debate about the best access for the fixation of distal biceps tendon ruptures, whether through double or single incision, recent studies^{21,22} show a negligible difference in results and complications between the two techniques. The choice of the best access for these pathologies should be guided by the experience and familiarity of the surgeon.

The negative points of the present study are: we do not have data for a comparison between the pre- and postoperative periods, due to its retrospective nature; the limited sample size ($n = 7$), a problem also present in most studies in the literature on this subject; and the short follow-up of the patients.

Conclusion

The graft of the central strip of the triceps tendon presents biomechanical characteristics suitable for its use in the reconstruction of the distal biceps. In addition, it presents as advantages the safety of its collection and the possibility of removal of grafts of variable sizes. We observed that, since it is a rare injury, there is great difficulty in carrying out large prospective studies to compare the methods of surgical treatment for such injury. However, the distal reconstruction of the biceps brachii with triceps grafting through double incision, with radial tuberosity fixation with two bioabsorbable suture anchors, seems to be an effective and safe option for the treatment of chronic distal biceps injuries, with good clinical and functional outcomes.

Financial Support

This work was supported by the Instituto de Pesquisa e Ensino Home, Brasilia, DF, Brazil.

Conflict of Interests

The authors have no conflict of interests to declare.

References

- 1 Darlis NA, Sotereanos DG. Distal biceps tendon reconstruction in chronic ruptures. *J Shoulder Elbow Surg* 2006;15(05): 614-619
- 2 Wiley WB, Noble JS, Dulaney TD, Bell RH, Noble DD. Late reconstruction of chronic distal biceps tendon ruptures with a semitendinosus autograft technique. *J Shoulder Elbow Surg* 2006;15 (04):440-444
- 3 Safran MR, Graham SM. Distal biceps tendon ruptures: incidence, demographics, and the effect of smoking. *Clin Orthop Relat Res* 2002;(404):275-283
- 4 Geaney LE, Mazzocca AD. Biceps brachii tendon ruptures: a review of diagnosis and treatment of proximal and distal biceps tendon ruptures. *Phys Sportsmed* 2010;38(02):117-125

- 5 Levy HJ, Mashoof AA, Morgan D. Repair of chronic ruptures of the distal biceps tendon using flexor carpi radialis tendon graft. *Am J Sports Med* 2000;28(04):538–540
- 6 Hang DW, Bach BR Jr, Bojchuk J. Repair of chronic distal biceps brachii tendon rupture using free autogenous semitendinosus tendon. *Clin Orthop Relat Res* 1996;(323):188–191
- 7 Morrey BF, Askew LJ, An KN, Dobyns JH. Rupture of the distal tendon of the biceps brachii. A biomechanical study. *J Bone Joint Surg Am* 1985;67(03):418–421
- 8 Flint JH, Wade AM, Giuliani J, Rue JP. Defining the terms acute and chronic in orthopaedic sports injuries: a systematic review. *Am J Sports Med* 2014;42(01):235–241
- 9 Bell RH, Wiley WB, Noble JS, Kuczynski DJ. Repair of distal biceps brachii tendon ruptures. *J Shoulder Elbow Surg* 2000;9(03):223–226
- 10 Hallam P, Bain GI. Repair of chronic distal biceps tendon ruptures using autologous hamstring graft and the Endobutton. *J Shoulder Elbow Surg* 2004;13(06):648–651
- 11 Boyd HB, Anderson MD. A method for reinsertion of the distal biceps brachii tendon. *J Bone Joint Surg Am* 1961;43(07):1041–1043
- 12 Klonz A, Loitz D, Wöhler P, Reilmann H. Rupture of the distal biceps brachii tendon: isokinetic power analysis and complications after anatomic reinsertion compared with fixation to the brachialis muscle. *J Shoulder Elbow Surg* 2003;12(06):607–611
- 13 Sanchez-Sotelo J, Morrey BF, Adams RA, O'Driscoll SW. Reconstruction of chronic ruptures of the distal biceps tendon with use of an achilles tendon allograft. *J Bone Joint Surg Am* 2002;84(06):999–1005
- 14 Patterson RW, Sharma J, Lawton JN, Evans PJ. Distal biceps tendon reconstruction with tendoachilles allograft: a modification of the endobutton technique utilizing an ACL reconstruction system. *J Hand Surg Am* 2009;34(03):545–552
- 15 Martin CR, Hildebrand KA, Baergen J, Bitting S. Triceps tendon fascia for collateral ligament reconstruction about the elbow: a clinical and biomechanical evaluation. *Am J Orthop* 2011;40(09):E163–E169
- 16 Baumfeld JA, van Riet RP, Zobitz ME, Eygendaal D, An KN, Steinmann SP. Triceps tendon properties and its potential as an autograft. *J Shoulder Elbow Surg* 2010;19(05):697–699
- 17 Terra BB, Rodrigues LM, Lima AL, Cabral BC, Cavatte JM, De Nadai A. Direct repair of chronic distal biceps tendon tears. *Rev Bras Ortop* 2016;51(03):303–312
- 18 Mazzocca AD, Burton KJ, Romeo AA, Santangelo S, Adams DA, Arciero RA. Biomechanical evaluation of 4 techniques of distal biceps brachii tendon repair. *Am J Sports Med* 2007;35(02):252–258
- 19 Olsen JR, Shields E, Williams RB, Miller R, Maloney M, Voloshin I. A comparison of cortical button with interference screw versus suture anchor techniques for distal biceps brachii tendon repairs. *J Shoulder Elbow Surg* 2014;23(11):1607–1611
- 20 Sarda P, Qaddori A, Nauschutz F, Boulton L, Nanda R, Bayliss N. Distal biceps tendon rupture: current concepts. *Injury* 2013;44(04):417–420
- 21 Grewal R, Athwal GS, MacDermid JC, et al. Single versus double-incision technique for the repair of acute distal biceps tendon ruptures: a randomized clinical trial. *J Bone Joint Surg Am* 2012;94(13):1166–1174
- 22 Keener JD. Controversies in the surgical treatment of distal biceps tendon ruptures: single versus double-incision repairs. *J Shoulder Elbow Surg* 2011;20(2, Suppl)S113–S125