



Case report

Optic nerve compression as a late complication of a hydrogel explant with silicone encircling band

Niels Crama^{a,*}, Leo Kluijtmans^b, B. Jeroen Klevering^a^a Department of Ophthalmology, Radboud University Medical Center Nijmegen, Philips van Leydenlaan 15, 6525 EX Nijmegen, The Netherlands^b Department of Radiology and Nuclear Medicine, Radboud University Medical Center Nijmegen, Geert Grooteplein 10, 6525 GA Nijmegen, The Netherlands

ARTICLE INFO

Keywords:

Retinal detachment
Tilted disc
Optic neuropathy
Miragel
Explant
Encircling band

ABSTRACT

Purpose: To present a complication of compressive optic neuropathy caused by a swollen hydrogel explant and posteriorly displaced silicone encircling band.

Observations: A 72-year-old female patient presented with progressive visual loss and a tilted optic disc. Her medical history included a retinal detachment in 1993 that was treated with a hydrogel explant under a solid silicone encircling band. Visual acuity had decreased from 6/10 to 6/20 and perimetry showed a scotoma in the temporal superior quadrant. On Magnetic Resonance Imaging (MRI), compression of the optic nerve by a displaced silicone encircling band inferior nasally in combination with a swollen episcleral hydrogel explant was observed. Surgical removal of the hydrogel explant and silicone encircling band was uneventful and resulted in improvement of visual acuity and visual field loss.

Conclusions and importance: This is the first report on compressive optic neuropathy caused by swelling of a hydrogel explant resulting in a dislocated silicone encircling band. The loss of visual function resolved upon removal of the explant and encircling band.

1. Introduction

Episcleral hydrogel explants (MIRAgel; methylacrylate-2-hydroxyethylacrylate) were introduced in 1985 as an alternative to silicone explants for retinal detachment surgery, but complications related to

hydrolytic degeneration with progressive swelling of this material led to discontinuation in the '90s.¹ Reported complications related to this swelling are numerous and include strabismus, ptosis, scleral erosion, conjunctivitis, and infection around the explant. Similar to silicone explants, episcleral hydrogel explants were used isolated or in combi-

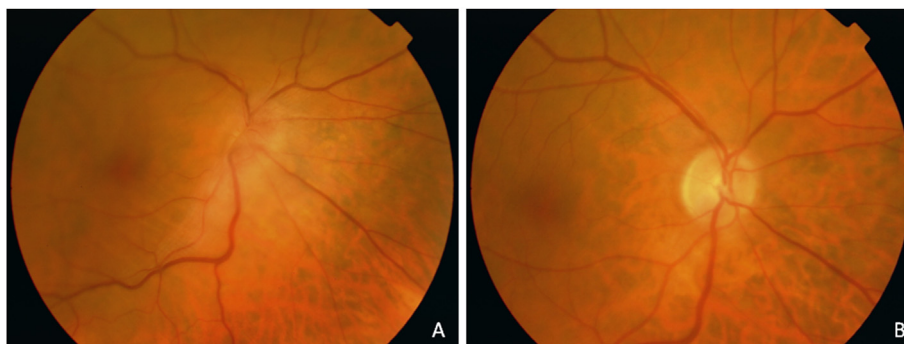


Fig. 1. Fundus view of the right eye, showing tilted disc and peripapillary elevation caused by displaced encircling band (A) and normalization of the optic disc structure four months after surgical removal of the explant and encircling band (B).

* Corresponding author. Department of Ophthalmology, Radboud University Medical Center, PO Box 9101, 6500 HB Nijmegen, The Netherlands.
E-mail address: niels.crama@radboudumc.nl (N. Crama).

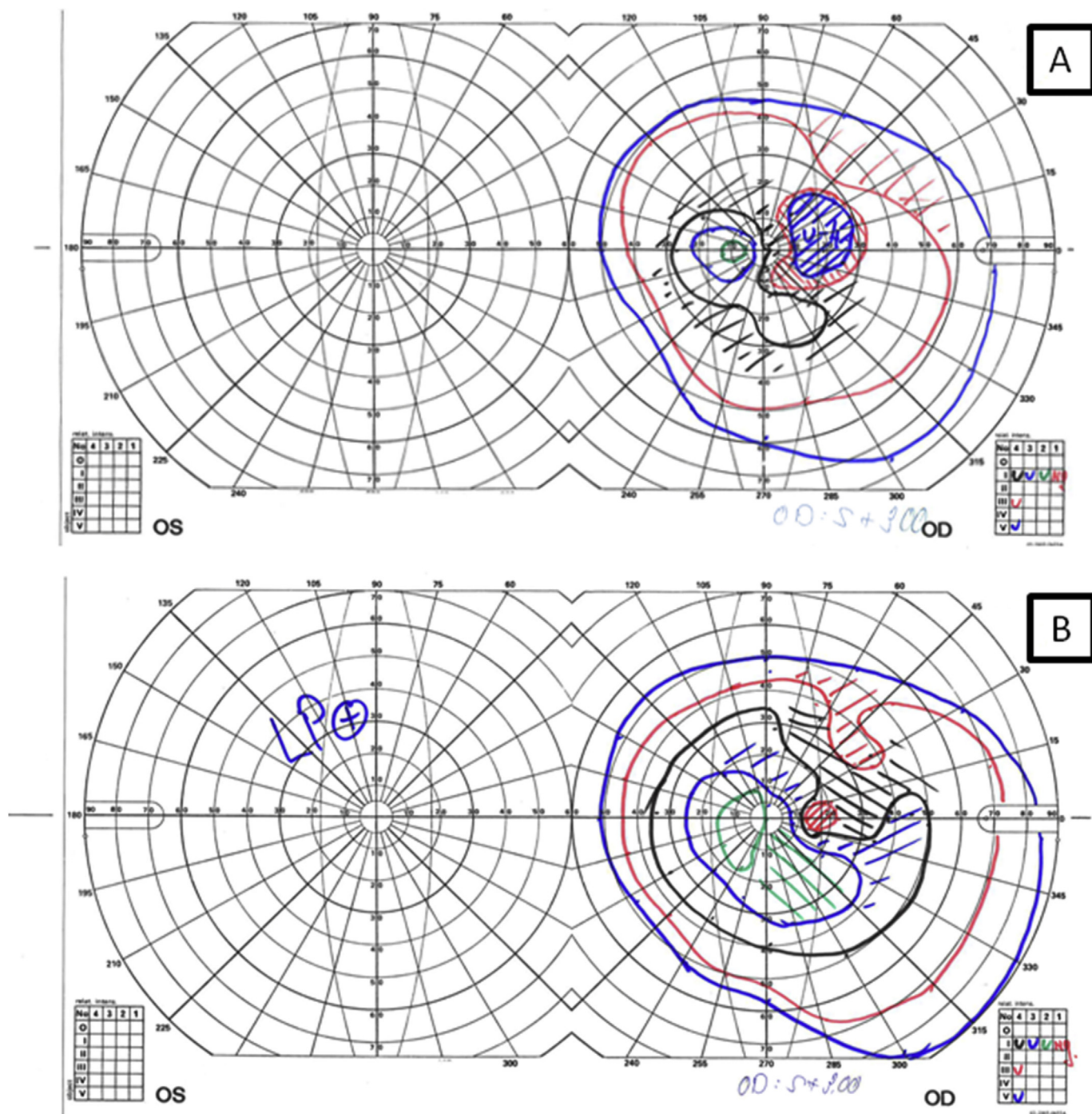


Fig. 2. Kinetic perimetry showing a relative superotemporal scotoma and coecentral scotoma in the right eye (A), partial restoration of the visual field 4 months after surgical removal of the explant and encircling band (B).

nation with a silicone encircling band, with the silicone band adding circumferential indentation. In this report, we describe a complication involving a hydrogel explant and dislocated silicone encircling band.

2. Case report

A 72-year-old woman presented with progressive loss of visual acuity in her right eye. Over the last month, her visual acuity had decreased from 6/10 to 6/20. Ophthalmic history revealed extraocular retinal detachment surgery in her right eye, using a superior temporal hydrogel explant under a solid silicone encircling band, in 1993. Ophthalmic examination showed a swollen subconjunctival hydrogel

explant in the temporal superior quadrant upon downgaze. The superotemporal retina was well attached with an adequate indentation. In addition, we observed a severely tilted optic disc (Fig. 1A). Kinetic perimetry showed a relative superotemporal scotoma in the right eye (Fig. 2A), as well as a coecentral scotoma. Visual acuity in the contralateral (left) eye was only light perception, due to an atrophic optic disc as result of an optic nerve sheath meningioma treated with surgery and radiotherapy. MRI showed a swollen T2 hyperintense episcleral hydrogel explant with minimal impression on the wall of the right eye. More posterior sections clearly showed nasal inferior compression of the optic nerve caused by a posteriorly and superiorly displaced hypointense silicone encircling band (Fig. 3). No signal intensity changes

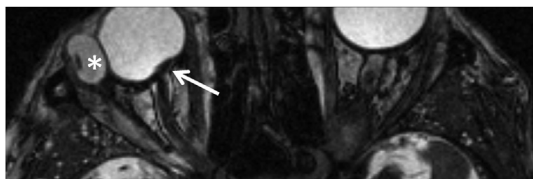


Fig. 3. Magnetic Resonance Imaging; Axial 3D T2W FastFieldEcho image. Impression of the dislocated hypointense silicone encircling band on the optic nerve nasally inferior (arrow). Swollen hydrogel explant on the temporal side of the right eye visible as an oval hyperintense structure with minimal impression on the eye (asterix).

of the right optic nerve were detected. One week later, we removed the explant and encircling band. Inspection after opening the superior temporal conjunctiva showed a silicone encircling band that was still correctly situated in the groove of the grossly swollen hydrogel explant. This swelling caused the nasal inferior portion of the encircling band, which was still under tension, to be dislocated to the posterior aspect of the globe. After cutting and releasing the encircling band, we could remove both encircling band and explant without complications. In the weeks following surgery, the tilting of the optic disc gradually disappeared (Fig. 1B). The visual field loss also restored (Fig. 2B), and visual acuity increased to 6/12 at 10 months post-surgery. The retina remained attached during the follow-up period of 10 months.

3. Discussion

Migration of an encircling element is an uncommon, but known complication of scleral buckling surgery.² Especially when fixation of an encircling element to the sclera is suboptimal, there is an increased risk for dislocation and migration, usually anteriorly sometimes even with migration through the extraocular muscles.^{3,4} In the presented case the dislocation was in the posterior direction. The fact that the encircling band was still fixed to the swollen grooved hydrogel played an important role in this specific case, as the swelling of the explant caused a gradual increase in the tension of the encircling band over years. Over time, the fixating sutures of the encircling band were most likely pulled from the sclera. This enabled the encircling band to move posteriorly over the curvature of the globe until contact with the optic nerve occurred. Further expansion of swollen hydrogel explant resulted in increasing compression of the optic nerve through the silicone encircling band. The relative recent onset and the prompt surgical removal in this case explains the relative good recovery of visual function, in contrast to a previous report on optic nerve compression by a scleral buckle.⁵ The absence of pathologic MRI-signal changes of the optic nerve also indicated absence of structural nerve damage.

4. Conclusion

We report a case where a swollen hydrogel explant indirectly leads to a highly unusual complication of optic nerve compression through the silicone encircling band. This developed many years after retinal detachment surgery, which makes the diagnosis challenging. Early radiologic imaging followed by prompt surgical intervention may help restore optic nerve function.

Acknowledgements

None.

Appendix A. Supplementary data

Supplementary data related to this article can be found at <http://dx.doi.org/10.1016/j.ajoc.2018.04.016>.

Patient consent

Consent to publish the case report was obtained.

Funding

No funding or grant support.

Conflicts of interest

The authors have no financial disclosures.

Authorship

All authors attest that they meet the current ICMJE criteria for Authorship.

References

1. Crama N, Klevering BJ. The removal of hydrogel explants: an analysis of 467 consecutive cases. *Ophthalmology*. 2016 Jan;123(1):32–38.
2. Haynie GD, D'Amico DJ. Scleral buckling surgery. In: Albert DM, Jakobiec F, eds. *Principles and Practice of Ophthalmology*. Philadelphia: W. B. Saunders; 1994:1092–1110.
3. Lanigan LP, Wilson-Holt N, Gregor ZJ. Migrating scleral explants. *Eye*. 1992;6(3):317–321.
4. Lopez MA, Mateo C, Corcóstegui I, Corcóstegui B. Transmuscular migration and straddling of the cornea by an encircling buckle. *Ophthalmic Surg Laser Imag*. 2007;38(5):402–403.
5. Codenotti M, Iuliano L, Fogliato G, De Benedetto U, Bandello F. Scleral buckling dislocation mimicking glaucoma progression. *Eur J Ophthalmol*. 2013;23(2):271–274.