

Motor Mapping with Functional Magnetic Resonance Imaging: Comparison with Electrical Cortical Stimulation

Seiichiro IMATAKA,¹ Rei ENATSU,¹ Tsukasa HIRANO,¹ Ayaka SASAGAWA,¹
Masayasu ARIHARA,¹ Tomoyoshi KURIBARA,¹ Satoko OCHI,¹ and Nobuhiro MIKUNI¹

¹*Department of Neurosurgery, Sapporo Medical University, Sapporo, Hokkaido, Japan*

Abstract

The aim of the present study was to evaluate motor area mapping using functional magnetic resonance imaging (fMRI) compared with electrical cortical stimulation (ECS). Motor mapping with fMRI and ECS were retrospectively compared in seven patients with refractory epilepsy in which the primary motor (M1) areas were identified by fMRI and ECS mapping between 2012 and 2019. A right finger tapping task was used for fMRI motor mapping. Blood oxygen level-dependent activation was detected in the left precentral gyrus (PreCG)/postcentral gyrus (PostCG) along the “hand knob” of the central sulcus in all seven patients. Bilateral supplementary motor areas (SMAs) were also activated (n = 6), and the cerebellar hemisphere showed activation on the right side (n = 3) and bilateral side (n = 4). Furthermore, the premotor area (PM) and posterior parietal cortex (PPC) were also activated on the left side (n = 1) and bilateral sides (n = 2). The M1 and sensory area (S1) detected by ECS included fMRI-activated PreCG/PostCG areas with broader extent. This study showed that fMRI motor mapping was locationally well correlated to the activation of M1/S1 by ECS, but the spatial extent was not concordant. In addition, the involvement of SMA, PM/PPC, and the cerebellum in simple voluntary movement was also suggested. Combination analysis of fMRI and ECS motor mapping contributes to precise localization of M1/S1.

Keywords: functional MRI, electrical cortical stimulation, motor, blood oxygen level-dependent signal

Introduction

Functional magnetic resonance imaging (fMRI) visualizes task-related metabolic changes based on blood oxygen level-dependent (BOLD) signals.¹⁾ This noninvasive imaging technique is used to identify task-specific functional brain areas.¹⁻⁴⁾ Furthermore, fMRI is useful for presurgical brain mapping and provides useful information for surgical planning.^{5,6)} Although electrical cortical stimulation (ECS) with intracranial electrodes is the most established tool for functional brain mapping, the procedure is costly, invasive, and has additional risks of complications. The noninvasive feature and the excellent spatial resolution of fMRI widely expand its application in the neuroscience and clinical fields.^{1,6)}

The dissociation between the areas with BOLD signal

activation in fMRI and primary motor (M1) areas was previously reported.⁷⁻¹⁰⁾ BOLD signal activation is usually detected in several motor-related areas beyond M1.^{7,10)} The data of fMRI motor mapping is frequently used for the implantation plan of intracranial electrodes. The mechanism for generating dissociations needs to be clarified to establish the efficacy of fMRI motor mapping and refine the implantation strategy of intracranial electrodes.

In the present study, we compared fMRI motor mapping with ECS to elucidate the functional role of the fMRI-activated areas during motor tasks and establish the relevance of fMRI motor mapping.

Received July 26, 2021; Accepted January 14, 2022

Copyright © 2022 The Japan Neurosurgical Society

This work is licensed under a Creative Commons Attribution-NonCommercial-NoDerivatives International License.

Table 1 Patient profile

Pt	Age/sex	Handedness	Diagnosis	Type of electrode	Seizure onset zone	Resected area	Engel classification
1	25/M	Rt	Lt. TLE	SD	Lt. T-O junction	Lt. T-O junction	Class I
2	28/F	Rt	Lt. FLE	SD	Lt. inf. PreCG	Lt. inf. PreCG	Class I
3	18/F	Rt	Lt. PLE	SD	Lt. mid. Cing. G	Lt. mid. Cing. G	Class II
4	17/M	Rt	Lt. FLE	SD	Lt. mid. Cing. G	Lt. mid. Cing. G	Class I
5	22/F	Rt	Rt. TLE	SD	Lt. lat. T, Rt. lat. T	Rt. ant. T	Class I
6	35/M	Rt	Lt. TLE	SD	Lt. T pole	Lt. T pole	Class I
7	12/M	Rt	Lt. FLE	SD	Lt. post. SFG	Lt. post. SFG	Class I

ant: anterior, Cing. G: cingulate gyrus, FLE: frontal lobe epilepsy, inf: inferior, lat: lateral, Lt: left, mid: middle, PLE: parietal lobe epilepsy, post: posterior, PreCG: precentral gyrus, Rt: right, SFG: superior frontal gyrus, SD: subdural electrode, T: temporal, TLE: temporal lobe epilepsy, T-O: temporo-occipital

Materials and Methods

Patients

Seven right-handed patients with intractable epilepsy in which M1 was localized by presurgical fMRI and ECS through intracranial electrodes chronically implanted at Sapporo Medical University Hospital between 2012 and 2019 were included (four males and three females, age: 12-35 years old). The characteristics of the patients are shown in Table 1. The patients were diagnosed with temporal lobe epilepsy (n = 3), frontal lobe epilepsy (n = 3), and parietal lobe epilepsy (n = 1). All patients underwent BOLD fMRI using BOLD echo-planar imaging (EPI) during the motor task. ECS was applied to localize eloquent cortices before resective surgeries via subdural electrode. The study was approved by the Ethical Committee of Sapporo Medical University Graduate School of Medicine (No. 23-161), and written informed consent was obtained from all patients.

MRI scanning and task design

Patients performed a motor task of right finger tapping during MRI scanning. The paradigm consisted of 3 blocks of 30 s (10 brain volumes) at rest and 30 s (10 brain volumes) of finger movement.

Functional MRI experiments were conducted on a 3-Tesla whole-body scanner equipped with an 8-ch phased array coil (GE Healthcare, Signa HD 3.0T ver. 14, USA). Functional images were obtained in a T2-weighted gradient-echo EPI sequence. Gradient-echo echo-planar images were collected with the following parameters: repetition time = 3.0 s, echo time = 35 ms, flip angle = 80°, field of view = 192 mm, matrix 64 × 64, and 50 interleaved axial slices with 3-mm thickness without gaps (3-mm cubic voxels).

BOLD activation was processed using Brain Wave PA (GE Healthcare, USA), a clinically applied fMRI post-processing software.¹¹⁾ Activation maps were created using

Generalized Linear Model analysis. The threshold of z-score was set to 4.48 with clusters with a significance threshold of $P = 0.05$. Images were smoothed with an isotropic Gaussian kernel of 8-mm full-width at half-maximum. Brain Wave PA (GE Healthcare, USA)'s 3D image-registration algorithm was applied for the motion correction with six head motion parameters rigid body motion correction via registration to the first volume.¹²⁾

For anatomical images, T1-weighted three-dimensional structural images were obtained using a magnetization-prepared rapid gradient-echo sequence.

Implantation of electrodes

The preimplantation hypothesis was generated using noninvasive evaluation such as MRI, scalp electroencephalography (EEG), positron emission tomography, and magnetoencephalography (MEG). The location of electrodes was determined based on the preimplantation hypothesis for the localization of the epileptogenic zone. Strip or grid subdural electrodes were implanted on the surface of the left or both hemispheres covering the frontal lobe, temporal lobe, or parietal lobe. The grids were composed of two or four lines, and each line comprised eight or five electrodes, respectively. The electrodes were made of platinum with a center-center interelectrode distance of 1 cm (Unique Medical Co., Ltd., Tokyo, Japan). Disc-shaped platinum electrodes with a diameter of 3.0 mm were embedded in silastic sheets. The strips were composed of a single row of four or six electrodes with the same composition as the grids. The positions of the electrodes were confirmed using a presurgical three-dimensional reconstructed MR image based on post-operative high-resolution volumetric computed tomography (1-mm thin slice). The locational relationship between BOLD activation and subdural electrodes were visually correlated based on the anatomical landmarks (e.g., precentral sulcus, central sulcus, postcentral sulcus, superior frontal sulcus, inferior frontal sulcus, and intraparietal sulcus [IPS]) of three-dimensional recon-

structed MRI and intraoperative photograph.

Electrical cortical stimulation

ECS was extraoperatively performed in all patients using Neurofax EEG-1200 with a JE-120 amplifier, an MS-120-EEG cortical stimulator, and a Nihon Kohden PE-210 software stimulator switch box (Nihon Kohden, Tokyo, Japan). Repetitive square wave electrical currents of alternating polarity, with a pulse width of 0.3 ms, were delivered at a frequency of 50 Hz for 5 s. The current was increased from 0 mA to 15 mA in increments of 0.5-2.0 mA until behavioral response was observed or until stimulus intensity reached maximum intensity. In all the trials, the stimulation was performed at least twice to confirm reproducibility. All available electrodes were screened in a bipolar fashion, and the eloquent pair was stimulated in a monopolar fashion for a more precise localization. Electromyography (EMG) was not recorded during ECS. The functional areas and their responses were evaluated and identified.^{13,14)}

- 1) Motor areas: muscle contraction or muscle twitch
- 2) Sensory areas: subjective sensory sensations
- 3) Negative motor area: cessation or slowing of finger tapping or rapid alternating movements of tongue without disturbance of consciousness or muscle contraction
- 4) Auditory areas: subjective auditory symptoms
- 5) Frontal eye field: conjugate deviation and head version to contralateral side to the stimulation
- 6) Language areas: disruption of language tasks (reading sentences, spontaneous speech, object naming, and auditory comprehension)
- 7) No function: no neurological responses

Results

The motor and other functional areas detected by ECS and fMRI during motor task in each of the seven patients are shown in Figs. 1-4. Motor symptoms were induced in the stimulus intensities of 2-8 mA.

With the right upper limb movement, BOLD activation was detected in the left precentral gyrus (PreCG) and postcentral gyrus (PostCG) along the "hand knob" of the central sulcus in all seven patients. Bilateral supplementary motor areas (SMAs) were also activated in six patients (Pts 2-7). The cerebellar hemisphere showed activation on the right side in three patients (Pts 1, 3, and 6), and bilateral sides with right-side dominance in four patients (Pts 2, 4, 5, and 7). Furthermore, the premotor area (PM) and posterior parietal cortex (PPC) were also activated on the left side in one patient (Pt 5: PM at the posterior end of inferior frontal sulcus and PPC at the anterior end of the IPS), and bilateral sides in two patients (Pts 6 and 7: PM at the posterior end of superior frontal sulcus and PPC at the anterior end of IPS).

In comparison with ECS, activated PreCG and PostCG were included within the right arm M1 and sensory (S1)

areas, respectively, in six patients (Pts 1-5 and 7). In these patients, 19 of 27 electrodes within right arm M1 and 20 of 26 electrodes within right arm S1 were located over BOLD-activated areas (Pt 1: M1 4/5 electrodes, S1 2/6 electrodes, Pt 2: M1 2/2, S1 4/6, Pt 3: M1 2/2, S1 4/4, Pt 4: M1 5/5, S1 7/7, Pt 5: M1 2/3, and Pt 7: M1 4/10, S1 3/3). In one patient (Pt 6), concordance was not found due to insufficient coverage of electrodes over BOLD activation.

ECS detected M1/S1 covered by BOLD activation in all patients. ECS induced right arm motor symptom in the activated left SMA in three patients (Pts 2-4), and the electrode was not placed in the SMA in the other four patients (Pts 1 and 5-7). With respect to PM and PPC, these areas were not activated by electrodes; thus, their functional role was unclear.

In summary, BOLD activation was detected in PreCG/PostCG within somatotopically correlated M1/S1. In addition, bilateral SMA, bilateral/ipsilateral cerebellar hemisphere, and bilateral/contralateral PM/PPC may be activated.

Discussion

In the present study, BOLD activation was detected in PreCG/Post CG within M1/S1. In addition, SMA, PM/PPC, and cerebellar hemispheric activation were also detected with individual differences.

Our results reveal good locational correlation between fMRI motor mapping and M1/S1. Previous reports evaluated the mapping accuracy of functional neuroimaging and revealed a maximum mapping accuracy of 5 mm in fMRI and 40 mm in MEG for motor mapping.¹⁵⁾ This study also showed that accuracy varied between language and motor mapping. The present results showed better spatial resolution of motor mapping compared with the results of language mapping that we previously reported,¹⁴⁾ and that fMRI motor mapping provides useful spatial information about motor areas. On the other hand, the extent of M1/S1 detected by ECS was larger than BOLD activation in our result. Technological limitations, such as electrical current spread of ECS, no recording of EMG, sensitivity of BOLD signal in fMRI, different spatial resolution of two modalities, patients' awareness, and difference of extremity sites, may affect the results.^{16,17)} In addition, fMRI evaluates "voluntary movement," whereas ECS induces movement by an active stimulation of the cortex. Therefore, we need to consider that these two modalities are observing a completely different aspect of motor control. The motor-related electrocorticographic (ECoG) activity (e.g., high gamma oscillation and movement related cortical potential) would provide functional mapping of voluntary movement. The comparison between ECoG mapping and fMRI is an interesting consideration for future analysis. The present results show that BOLD-activated PreCG and PostCG were included within a more limited extent of the M1 and S1 ar-

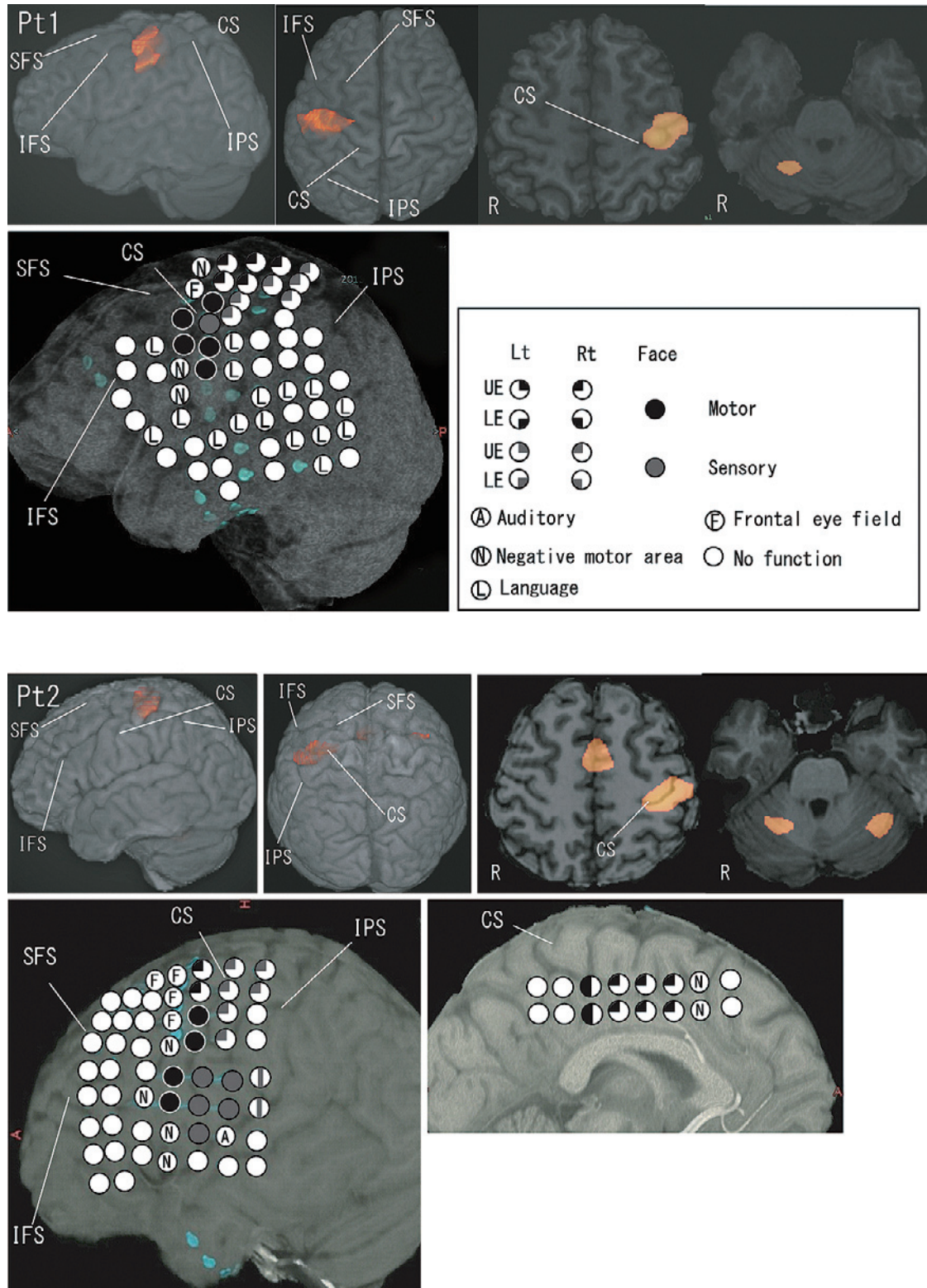


Fig. 1 BOLD signal activation of functional MRI (fMRI) during a motor task and functional mapping with electrical cortical stimulation (ECS) in patients (Pts) 1 and 2. BOLD activation was detected in the left precentral gyrus (PreCG) and postcentral gyrus (PostCG) within the right arm motor (M1) and sensory (S1) areas detected by ECS. Bilateral supplementary motor areas (SMAs) were also activated in Pt 2. The cerebellar hemisphere showed activation on right side in Pt 1 and bilateral sides in Pt 2. CS: central sulcus, IFS: inferior frontal sulcus, IPS: intraparietal sulcus, LE: lower extremity, Lt: left, Rt: right, SFS: superior frontal sulcus, UE: upper extremity.

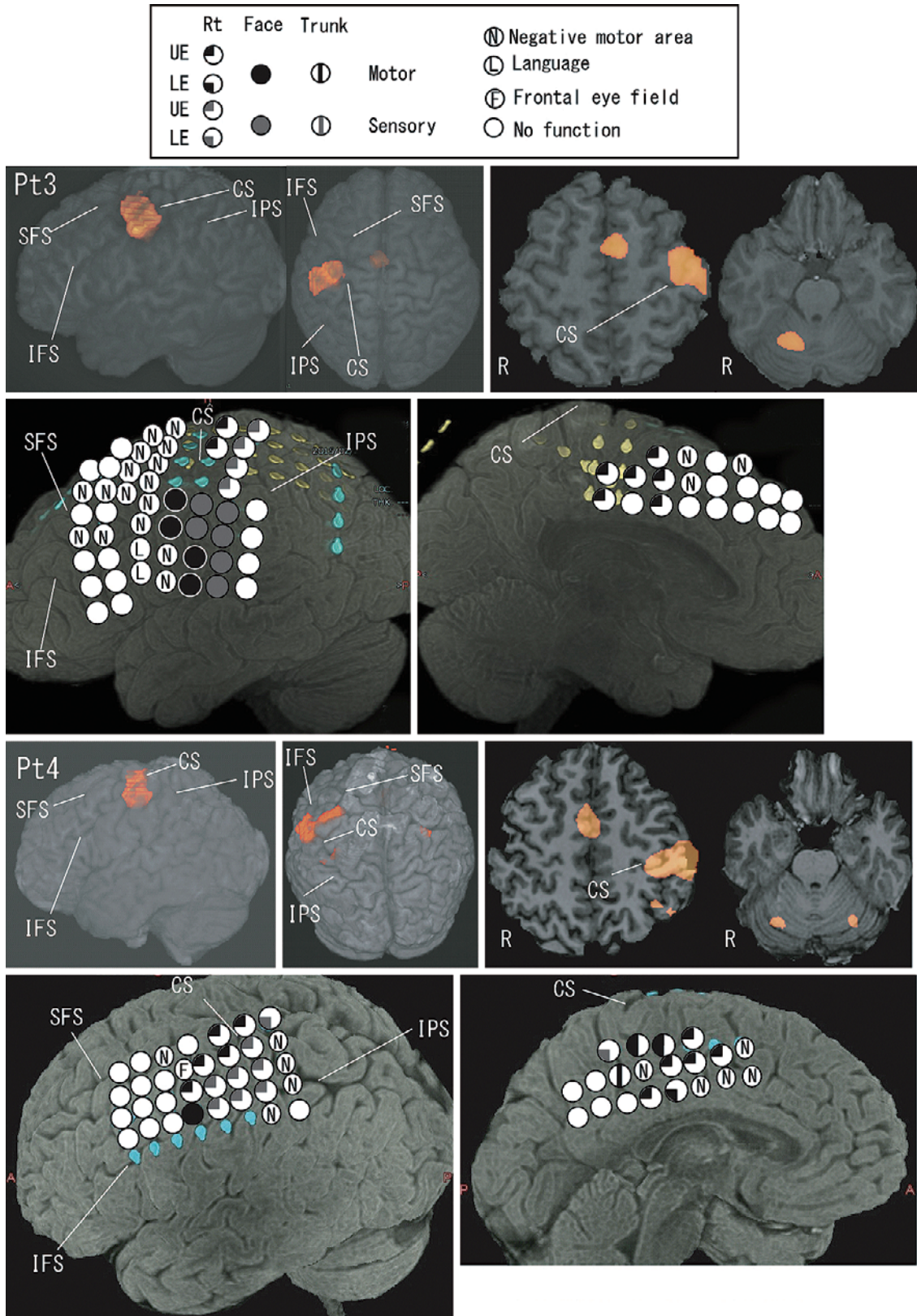


Fig. 2 fMRI during a motor task and ECS mapping in Pts 3 and 4. BOLD activation was detected in the left PreCG/PostCG within M1/S1, bilateral SMAs and cerebellar hemispheres (right in Pt 3 and bilateral in Pt 4).

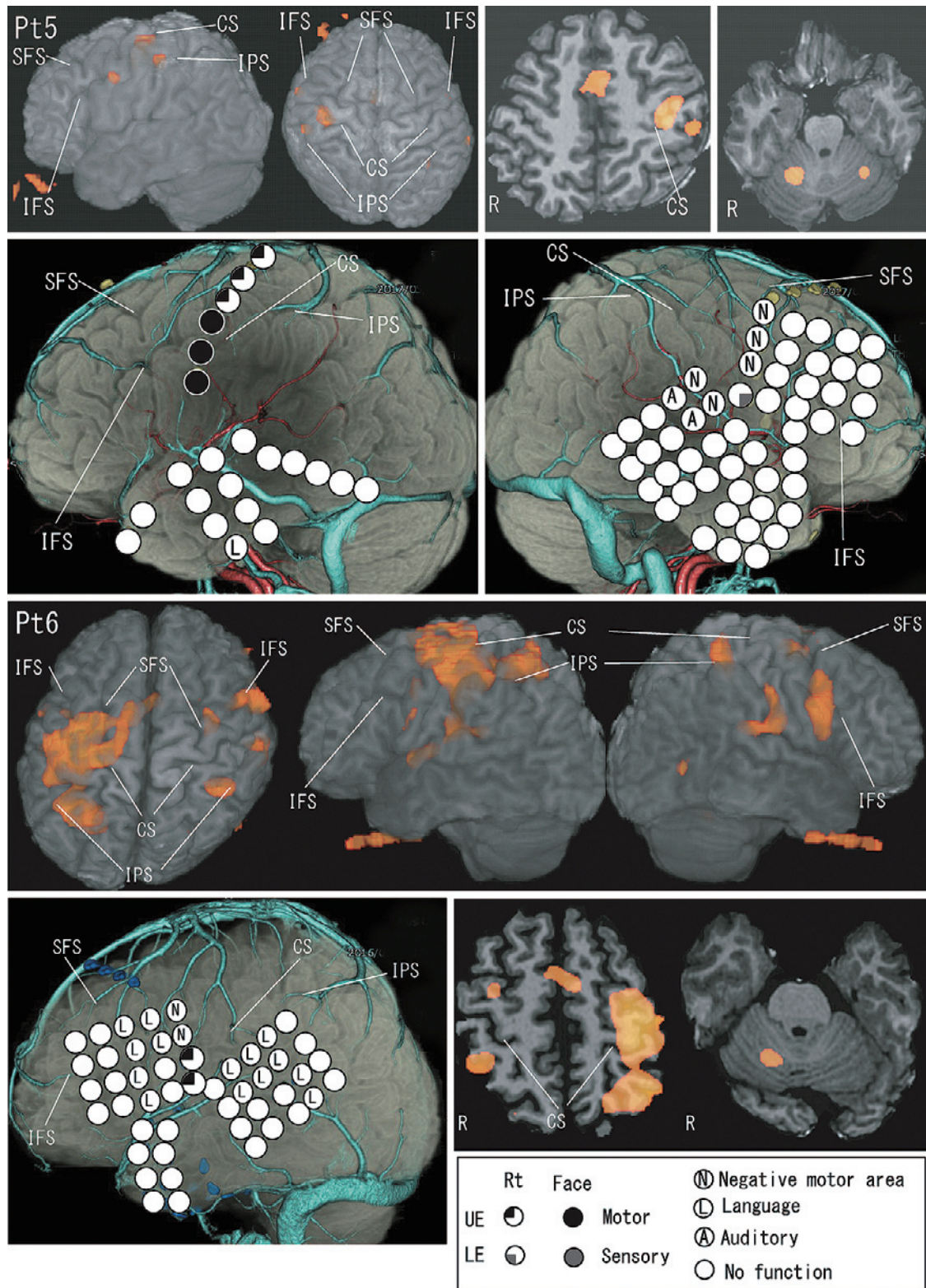


Fig. 3 fMRI during a motor task and ECS mapping in Pts 5 and 6. BOLD activation was detected in the left PreCG/PostCG, bilateral SMAs and cerebellar hemispheres (right in Pt 6 and bilateral in Pt 5). Furthermore, the premotor area (PM) and posterior parietal cortex (PPC) were also activated on the left side in Pt 5 and bilateral side in Pt 6.

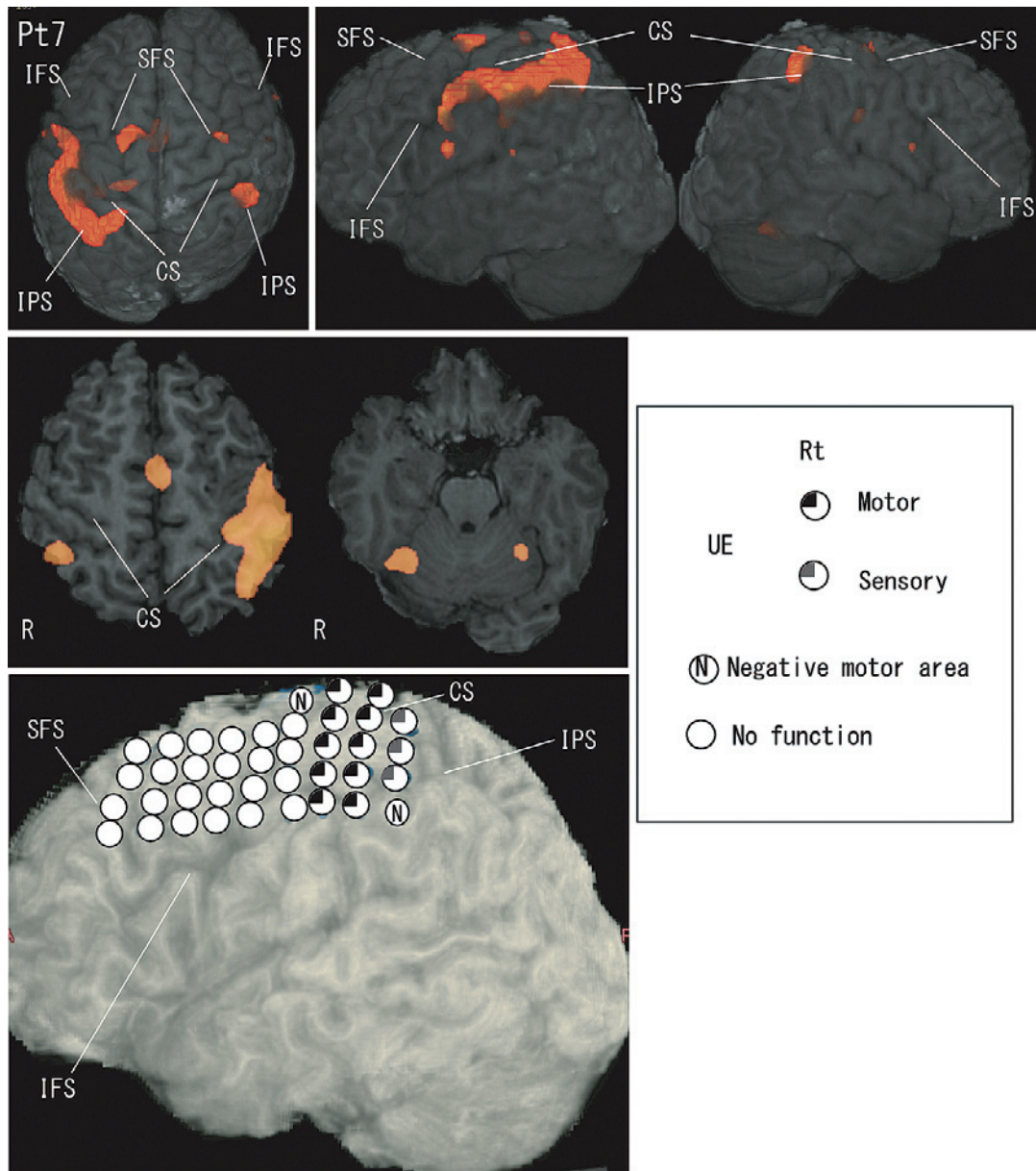


Fig. 4 fMRI during a motor task and ECS mapping in Pt 7. BOLD activation was detected in the left PreCG/PostCG, bilateral SMAs, bilateral cerebellar hemispheres, bilateral PM, and PPC.

eas and indicate that the activated PreCG/PostCG may be the “core” of the motor cortex, and fMRI has a limitation in the spatial extent of motor mapping. For the clinical use of fMRI motor mapping, the different spatial extent between fMRI and ECS should be noted.

Additional activation was detected in SMA, the cerebellar hemisphere, and PM/PPC. SMA activation suggests a somatotopic correlation and bilateral involvement of motor organization. SMA activation during motor tasks has been previously reported.^{7,10} Several reports suggested the supramotor role of SMA on the planning and execution of movement.^{10,18,19} Furthermore, it has been proposed that preSMA plays a role in the preparation of a complex

movement and a new sequential movement, while SMA proper is activated by simple movements.^{10,18} Therefore, our simple motor task of right finger tapping may be related to SMA proper rather than preSMA. Task-specific changes in fMRI findings need to be clarified to elucidate the functional roles of these areas in motor control. The BOLD signal in the cerebellar hemisphere indicates the cerebellum’s influence on voluntary movement.^{20,21} Cerebellar output to the cerebral cortex may be mediated through the cerebello-thalamo-cortical pathway connecting from the cerebellar nuclei to M1 via the thalamus. Tractography of the cerebello-thalamo-cortical pathway was not available in our study and may be a useful tool to clarify the func-

tional significance of activated cerebellar areas. PM/PPC activation was also detected with individual differences. These areas compose the basic functional circuit of the motor system and transform sensory information into action.^{18,22,23)} Donoghue and Sanes reported that PM is involved in coupling arbitrary cues to motor acts, while SMA is involved in internal guidance or planning of movement.²⁴⁾ Therefore, the ununiformed internal cue of movement initiation may affect PM/PPC activation and cause individual differences. fMRI-activated areas may provide useful information concerning the processing and control of voluntary movement; however, the inter-individual variability of the activation and electrode coverage makes it difficult to reach a conclusion. Furthermore, the study population was small, and the study design was retrospective. Further analyses including more cases are needed.

Despite several limitations, this study showed that fMRI motor mapping was locationally well correlated to M1/S1 of ECS, but the spatial extent was not concordant.

In addition, the involvement of SMA, PM/PPC, and the cerebellum in simple voluntary movement was also partly suggested. Combination analysis of fMRI and ECS motor mapping contributes to precise localization of M1/S1.

Acknowledgments

We confirm that we have read the journal's position on issues involved in ethical publication and affirm that this report is consistent with those guidelines.

Conflicts of Interest Disclosure

The authors declare that the article content was composed in the absence of any commercial or financial relationships that could be construed as a potential conflict of interest.

References

- 1) Glover GH: Overview of functional magnetic resonance imaging. *Neurosurg Clin N Am* 22: 133-139, vii, 2011
- 2) Belliveau JW, Kennedy DN Jr, McKinstry RC, et al.: Functional mapping of the human visual cortex by magnetic resonance imaging. *Science* 254: 716-719, 1991
- 3) Herrero MT, Barcia C, Navarro JM: Functional anatomy of thalamus and basal ganglia. *Childs Nerv Syst* 18: 386-404, 2002
- 4) Sharma R, Sharma A: Physiological basis and image processing in functional magnetic resonance imaging: neuronal and motor activity in brain. *Biomed Eng Online* 3: 13, 2004
- 5) Pujol J, Conesa G, Deus J, et al.: Presurgical identification of the primary sensorimotor cortex by functional magnetic resonance imaging. *J Neurosurg* 84: 7-13, 1996
- 6) Orringer DA, Vago DR, Golby AJ: Clinical applications and future directions of functional MRI. *Semin Neurol* 32: 466-475, 2012
- 7) Hanakawa T, Ikeda A, Sadato N, et al.: Functional mapping of human medial frontal motor areas. The combined use of func-

- tional magnetic resonance imaging and cortical stimulation. *Exp Brain Res* 138: 403-409, 2001
- 8) Hermes D, Miller KJ, Vansteensel MJ, Aarnoutse EJ, Leijten FS, Ramsey NF: Neurophysiologic correlates of fMRI in human motor cortex. *Hum Brain Mapp* 33: 1689-1699, 2012
- 9) Jeong JW, Asano E, Brown EC, Tiwari VN, Chugani DC, Chugani HT: Automatic detection of primary motor areas using diffusion MRI tractography: comparison with functional MRI and electrical stimulation mapping. *Epilepsia* 54: 1381-1390, 2013
- 10) Hill VB, Cankurtaran CZ, Liu BP, et al.: A practical review of functional MRI anatomy of the language and motor systems. *AJNR Am J Neuroradiol* 40: 1084-1090, 2019
- 11) Baxter L: Special considerations when using functional MRI as a presurgical mapping tool: SIGNA pulse of MR, Chicago, USA, GE healthcare MR publication, 2009, pp 47-49
- 12) Williams EJ, Stretton J, Centeno M, et al.: Clinical language fMRI with real-time monitoring in temporal lobe epilepsy: online processing methods. *Epilepsy Behav* 25: 120-124, 2012
- 13) Kimura Y, Enatsu R, Yokoyama R, et al.: Eye movement network originating from frontal eye field: electric cortical stimulation and diffusion tensor imaging. *Neurol Med Chir (Tokyo)* 61: 219-227, 2021
- 14) Hirano T, Enatsu R, Sasagawa A, et al.: Anatomical and functional distribution of functional MRI language mapping. *J Clin Neurosci* 77: 116-122, 2020
- 15) Ellis DG, White ML, Hayasaka S, Warren DE, Wilson TW, Aizenberg MR: Accuracy analysis of fMRI and MEG activations determined by intraoperative mapping. *Neurosurg Focus* 48: E13, 2020
- 16) Yokoyama R, Akiyama Y, Enatsu R, et al.: The immediate effects of vagus nerve stimulation in intractable epilepsy: an intraoperative electrocorticographic analysis. *Neurol Med Chir (Tokyo)* 60: 244-251, 2020
- 17) Tamada T, Enatsu R, Suzuki Y, et al.: Psychogenic pseudo-responses in an electrical cortical stimulation. *Neurol Med Chir (Tokyo)* 59: 287-290, 2019
- 18) Rizzolatti G, Luppino G, Matelli M: The organization of the cortical motor system: new concepts. *Electroencephalogr Clin Neurophysiol* 106: 283-296, 1998
- 19) Dinner DS, Luders HO: cortical mapping by electrical stimulation of subdural electrodes: supplementary sensorimotor area in humans. London, Infroma Healthcare, 2008
- 20) Aumann TD: Cerebello-thalamic synapses and motor adaptation. *Cerebellum* 1: 69-77, 2002
- 21) Galloway MN, Jeanmonod D, Liu J, Morel A: Human pallidothalamic and cerebellothalamic tracts: anatomical basis for functional stereotactic neurosurgery. *Brain Struct Funct* 212: 443-463, 2008
- 22) Kaas JH, Stepniewska I, Gharbawie O: Cortical networks subserving upper limb movements in primates. *Eur J Phys Rehabil Med* 48: 299-306, 2012
- 23) Hamadjida A, Dea M, Deffeyes J, Quessy S, Dancause N: Parallel cortical networks formed by modular organization of primary motor cortex outputs. *Curr Biol* 26: 1737-1743, 2016
- 24) Donoghue JP, Sanes JN: Motor areas of the cerebral cortex. *J Clin Neurophysiol* 11: 382-396, 1994

Corresponding author: Nobuhiro Mikuni, MD, PhD
Department of Neurosurgery, Sapporo Medical University, South 1 West 16, Chuo-ku, Sapporo, Hokkaido 060-8543, Japan.
e-mail: mikunin@sapmed.ac.jp