

Primary hydatid cyst of pineal region of brain: A case report from Saudi Arabia

Ahmed Bakhsh, Khalid Mukarram Ali Siddiqui¹, Suad Taraif²

Department of Neurosurgery, Saad Specialist Hospital, Al-Khobar, Kingdom of Saudi Arabia, ¹Consultant Neurosurgeon and Assistant CMO, Rayyan Hospital, SHG, Riyadh, ²Consultant Pathologist, Saad Specialist Hospital, Alkhobar, KSA

ABSTRACT

Preoperative diagnosis of cerebral echinococcosis in an unusual location is always difficult. Nonetheless, this possibility should be kept in mind in all cystic lesions of the brain. Although total excision of the cyst without rupture is a time - tested treatment, but in order to prevent recurrence, adjuvant medical treatment should also be started. Albendazole, mebendazole and praziquantal are commonly used drugs. Albendazole is a drug of choice. Its usual dose for adults is 400 mg twice daily. Exact duration of treatment is still uncertain, but it should not be <6 months. This case report shows primary presentation of hydatid cyst in the pineal region which later disseminated intracranially. However complete excision of the cyst at site of recurrence, combined with medical treatment, proved quite successful. Patient was found recurrence free 3 years after surgery. Last but not least, endoscopic third ventriculostomy and biopsy should be performed very carefully in cystic lesions of posterior third ventricular region.

Key words: Anaphylaxis, *Echinococcus granulosus*, hydatid cyst, pineal region

Introduction

Hydatid disease is caused by the larval stage of the parasites *Echinococcus granulosus* and *Echinococcus multilocularis*.^[1] *E. granulosus* is ubiquitous, but *E. multilocularis* is mainly present in the northern hemisphere. Dogs and foxes are definitive hosts and humans act as intermediate hosts.^[2] *E. granulosus* and *E. multilocularis* produce cystic and solid lesions respectively.^[3]

Hydatid disease primarily involves the liver and lungs. The brain is involved in <2% of cases. The lesions are usually distributed in the territory of the middle cerebral artery. Apart from hemispheric involvement, the orbits, ventricles, hypothalamus, aqueduct of Sylvius, cavernous sinuses, pons,

cerebellum, subarachnoid and extradural spaces have been reported to be affected by this disease.^[4]

To the best of our knowledge, this is the first-case report in which a hydatid cyst has been reported in the pineal region. The cyst was inadvertently ruptured during surgery due to an uncertain preoperative diagnosis. Later histopathology provided the correct diagnosis. Nevertheless, the rupture of the cyst did not cause any anaphylactic shock, but intracranial dissemination occurred, as the cyst finally appeared in the lateral ventricle.

Case Report

The 33-year-old male patient presented with a 3 weeks history of headache, projectile vomiting, double vision and difficulty walking. His neurological examination showed upward gaze palsy (Parinaud syndrome). Computerized tomography (CT) of his brain showed a well-defined, rounded, nonenhancing, cystic lesion in the pineal region along with acute obstructive

Access this article online	
Quick Response Code:	Website: www.asianjns.org
	DOI: 10.4103/1793-5482.146397

Address for correspondence:

Dr. Ahmed Bakhsh, Department of Neurosciences, Saad Specialist Hospital, Prince Faisal Bin Fahd Road, P O. Box 30353, Al-Khobar 31952, Kingdom of Saudi Arabia.
E-mail: ahmedbakhsh@gmail.com, ahmedbakhshmalik@yahoo.com

This is an open access article distributed under the terms of the Creative Commons Attribution-NonCommercial-ShareAlike 3.0 License, which allows others to remix, tweak, and build upon the work non-commercially, as long as the author is credited and the new creations are licensed under the identical terms.

For reprints contact: reprints@medknow.com

How to cite this article: Bakhsh A, Siddiqui KA, Taraif S. Primary hydatid cyst of pineal region of brain: A case report from Saudi Arabia. Asian J Neurosurg 2017;12:314-7.

hydrocephalus. The lesion was considered a pineal cyst, dermoid or epidermoid Figures 1 and 2. The hydrocephalus was relieved by emergency endoscopic third ventriculostomy. The cyst was punctured, and clear fluid came out. A sample sent for histopathology, but no cystic structures were noted. Due to this inconclusive biopsy report, final diagnosis had not been ascertained. However, the patient was discharged in a satisfactory condition.

Six months later, the patient presented with headache, dizziness and double vision. Magnetic resonance imaging (MRI) of the brain showed large multiloculated enhancing cystic lesions in the right lateral ventricle Figure 3. Right parieto-occipital craniotomy was performed to remove the lesion for a definite diagnosis. All accessible cysts were fenestrated, and their walls and septi were removed. Clear fluid came out under pressure. The large anterior cyst could not be removed due to dense adhesions. Histopathology showed a cystic wall made up of chitinous, lamellated membrane Figure 4. The inner part of the cyst was lined by

an intact nucleated, germinative layer. Fragments of glial tissue with chronic inflammation, composed of lymphocytes, plasma cells and eosinophils were also noted. Echinococcal hooklets or scolices were not seen.

All these findings were consistent with a hydatid cyst of brain. Positive serum antibodies for echinococcus antigen further confirmed our diagnosis. CT of chest and abdomen were done to rule out any possible involvement of any other organ, but no such clue was found. Medical therapy in the form of albendazole and praziquinatal was started and continued for 6 months. Patient was recurrence free 3 years after surgery.

Discussion

Cerebral hydatid cysts are slow - growing lesions and remain asymptomatic for a long time. Patient may present either with focal neurological deficits or with signs and symptoms of raised intracranial pressure, depending upon the size and location of the cyst.^[5]

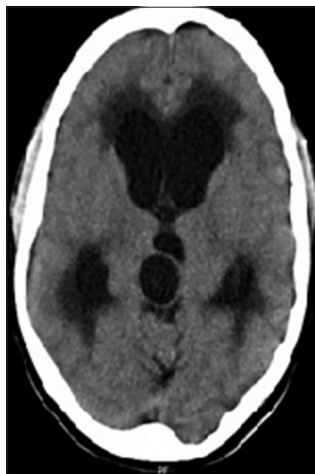

Figure 1: Computerized tomography brain axial view showing cyst in the pineal region

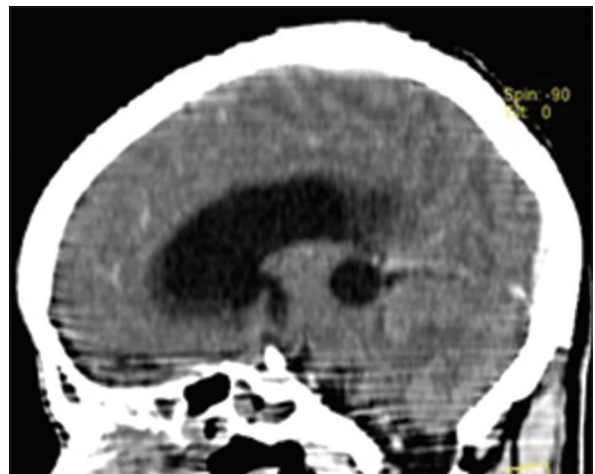


Figure 2: Sagittal view showing cyst in the pineal region

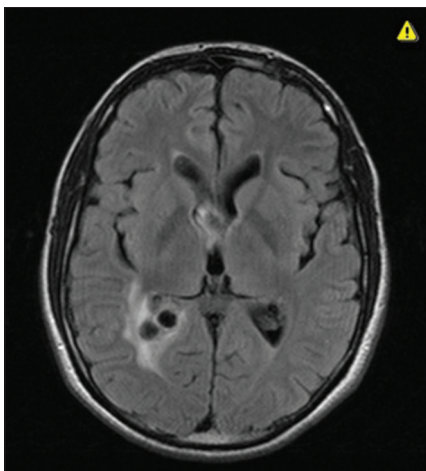


Figure 3: T1-weighted showing lesion in right lateral ventricle

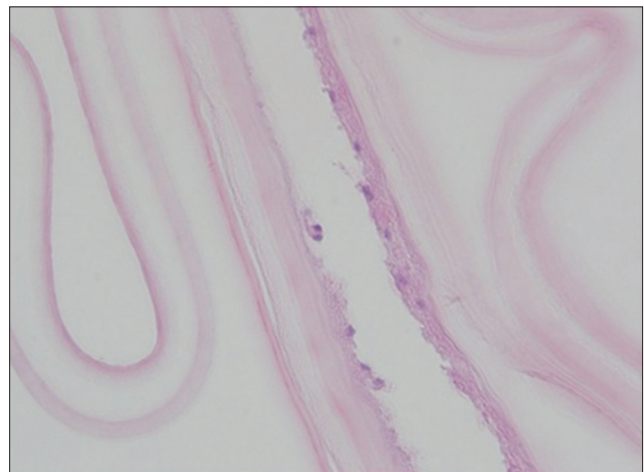


Figure 4: Microscopic picture showing a diagnostic thick laminated a nuclear membrane. A think germinal layer is also evident

Surgery is the mainstay of treatment, but rupture of the cyst is the potential threat of anaphylaxis, recurrence and chemical meningitis.^[6] Therefore, total surgical excision is always recommended. Dowling's technique is most popular surgical procedure, in which cysts are removed intact by mean of hydrodissection.^[7] Nonetheless, the removal of all cysts in toto is in not always possible. Risk of rupture in deep-seated multiple cysts are high. Intraventricular and paraventricular cysts are also difficult to be removed intact due to their thin walls and surrounded adhesions.

In our case, cysts were very much adherent, therefore, all cysts could not be removed. Few cysts were ruptured, but fortunately no allergic or anaphylactic reaction occurred. Anaphylaxis is though much feared complication, but it has rarely been reported. Local recurrence is another common complication. In this case, intracranial dissemination occurred as multiple cysts finally appeared in the lateral ventricle. However, postoperative CT abdomen and chest ruled out any extracranial dissemination.

Preoperatively, we were unable to diagnose the lesion which was considered as pineal cyst, dermoid, or epidermoid. The hydatid cyst was not kept in the differential diagnosis either because of unusual location or rarity of the disease. In fact, cystic lesions in the pineal region are uncommon, and their radiological differentiation is difficult. Nevertheless, an accurate preoperative diagnosis is essential in planning and optimizing the treatment.

Cystic lesions in the pineal region may include pineal cysts, arachnoid cyst, abscess, cystic neoplasms and congenital inclusion cysts like dermoid and epidermoid cysts.^[8] All these cysts can be differentiated on the basis of their characteristic MR features, shape and locations.^[9] Arachnoid and porencephalic cysts are usually not rounded. Brain abscess and cystic neoplasms are contrast-enhancing.^[10] Epidermoid are located in the cerebellopontine angle. Dermoid are more common in midline locations. Moreover, the contents of dermoid, epidermoid and arachnoid cysts are entirely different. Differentiation between hydatid cysts and neurocysticercosis in neuroimaging is always complicated. Pineal cysts are smooth, thin-walled, and unilocular. These are hypointense on T1-weighted and hypointense T2-weighted MR images with enhancement of the cyst wall. Epidermoid are also hypointense on T1-weighted and hyperintense on T2-weighted images but nonenhancing. Dermoid cysts have a variable appearance on MR images due to their lipid and hair contents.^[11,12] Hydatid cysts are usually single, thin-walled, spherical, nonenhancing and without any surrounding edema.^[13] MR spectroscopy and MR diffusion weighted images are useful to differentiate intracranial cystic lesions in such type of cases.^[14]

Due to lack of diagnosis, we could not exercise extra precautions while removing hydatid cysts. As a result, the primary pineal

hydatid cyst was ruptured unintentionally, fortunately without any dire consequences. Secondary multiple ventricular cysts were also ruptured and removed incompletely. Surprisingly, postoperative course remained favorable and uneventful on both occasions.

Drug treatment is an essential adjunctive therapy to surgery. The optimal duration of treatment is uncertain; in general it should be continued for at least 6 months following surgery. Albendazole has a more favorable pharmacokinetic profile and may be given 10-15 mg/kg/day in two divided doses. Albendazole inhibits microtubules assembly, leading to impaired glucose absorption and causing glycogen depletion leading to cell death. Albendazole is generally well tolerated. Adverse effects include hepatotoxicity, cytopenia, and alopecia. Dizziness, headache, vomiting, and rash have also been described. These drugs should not be used in patients with underlying liver disease or bone marrow suppression. Laboratory monitoring including blood count and liver function tests should be checked.^[15]

Conclusion

This case report clearly shows that a hydatid cyst should always be kept in the differential diagnosis of all cystic pineal lesions especially in the endemic areas of the world. Total excision of the cyst is first-line treatment and preferable, but it is not always possible. Postoperatively, medical treatment is advisable in all cases particularly after intra-operative cyst rupture, and in multiple small cysts.^[16-18] Echinococcus remains a serious public health problem in many countries; therefore preventive measures should also be adapted to the break the cycle between the definitive and the intermediate host.

Financial support and sponsorship

Nil.

Conflicts of interest

There are no conflicts of interest.

References

1. Pedrosa I, Saiz A, Arrazola J, Ferreirós J, Pedrosa CS. Hydatid disease: Radiologic and pathologic features and complications. *Radiographics* 2000;20:795-817.
2. Altınörs N, Bavbek M, Caner HH, Erdogan B. Central nervous system hydatidosis in Turkey: A cooperative study and literature survey analysis of 458 cases. *J Neurosurg* 2000;93:1-8.
3. Bükte Y, Kemaloglu S, Nazaroglu H, Ozkan U, Ceviz A, Simsek M. Cerebral hydatid disease: CT and MR imaging findings. *Swiss Med Wkly* 2004;134 (31-32):459-67.
4. Trivedi A, Shukla S, Singh K, Sharma V. Giant intracranial hydatid cyst. *J Pediatr Neurosci* 2007;2:72-4.
5. Ali M, Mahmood K, Khan P. Hydatid cysts of the brain. *J Ayub Med Coll Abbottabad* 2009;21:152-4.
6. Kammerer WS. Echinococcosis affecting the central nervous system. *Semin Neurol* 1993;13:144-7.
7. Izci Y, Tüzün Y, Seçer HI, Gönül E. Cerebral hydatid cysts: Technique and pitfalls of surgical management. *Neurosurg Focus* 2008;24:E15.
8. Smith AB, Rushing EJ, Smirniotopoulos JG. From the archives of the

- AFIP: Lesions of the pineal region: Radiologic-pathologic correlation. *Radiographics* 2010;30:2001-20.
9. Wani NA, Kousar TL, Gojwari T, Robbani I, Singh M, Ramzan A, *et al.* Computed tomography findings in cerebral hydatid disease. *Turk Neurosurg* 2011;21:347-51.
 10. Fakhran S, Escott EJ. Pineocytoma mimicking a pineal cyst on imaging: True diagnostic dilemma or a case of incomplete imaging? *AJNR Am J Neuroradiol* 2008;29:159-63.
 11. Osborn AG, Preece MT. Intracranial cysts: Radiologic-pathologic correlation and imaging approach. *Radiology* 2006;239:650-64.
 12. Tüzün M, Hekimoglu B. Hydatid disease of the CNS: Imaging features. *AJR Am J Roentgenol* 1998;171:1497-500.
 13. Gupta K, Rajeswaran R, Joseph S, Ganesh K. Diagnosis of intracranial hydatid cyst by magnetic resonance spectroscopy. *J Pediatr Neurosci* 2008;3:174-6.
 14. Ntusi NA, Horsfall C. Severe disseminated hydatid disease successfully treated medically with prolonged administration of albendazole. *QJM* 2008;101:745-6.
 15. Gangopadhyay AN, Srivastava P, Upadhyaya VD, Hasan Z. Is primary chemotherapy effective in large hydatid cyst of liver? *J Indian Assoc Pediatr Surg* 2009;14:40.
 16. von Sinner W, te Strake L, Clark D, Sharif H. MR imaging in hydatid disease. *AJR Am J Roentgenol* 1991;157:741-5.
 17. Aydin MD, Ertek M, Yazgi H. Multiple infected cerebral hydatid cysts treated with albendazole. *Turk J Med Sci* 2003;33:393-5.
 18. Abbassioun K, Amirjamshidi A. Diagnosis and management of hydatid cyst of the central nervous system: Part 1: General considerations and hydatid disease of the brain. *Neurosurg Q* 2001;11:1-9.