

First clinical study using HCV protease inhibitor danoprevir to treat COVID-19 patients

Hongyi Chen, BM^{a,*}, Zhicheng Zhang, MM^b, Li Wang, MM^a, Zhihua Huang, BM^c, Fanghua Gong, MM^d, Xiaodong Li, PhD^e, Yahong Chen, MM^e, Jinzi J. Wu, PhD^{e,f,*}

Abstract

Introduction: As coronavirus disease 2019 (COVID-19) outbreak globally, repurposing approved drugs is emerging as important therapeutic options. Danoprevir boosted by ritonavir (Ganovo) is a potent hepatitis C virus (HCV) protease (NS3/4A) inhibitor, which was approved and marketed in China since 2018 to treat chronic hepatitis C patients.

Methods: This is an open-label, single arm study evaluating the effects of danoprevir boosted by ritonavir on treatment naïve and experienced COVID-19 patients for the first time. Patients received danoprevir boosted by ritonavir (100 mg/100 mg, twice per day). The primary endpoint was the rate of composite adverse outcomes and efficacy was also evaluated.

Results: The data showed that danoprevir boosted by ritonavir is safe and well tolerated in all patients. No patient had composite adverse outcomes during this study. After initiation of danoprevir/ritonavir treatment, the first negative reverse real-time PCR (RT-PCR) test occurred at a median of 2 days, ranging from 1 to 8 days, and the obvious absorption in CT scans occurred at a median 3 days, ranging from 2 to 4 days. After 4 to 12-day treatment of danoprevir boosted by ritonavir, all enrolled 11 patients were discharged from the hospital.

Conclusion: Our findings suggest that repurposing danoprevir for COVID-19 is a promising therapeutic option.

Abbreviations: COVID-19 = coronavirus disease 2019, GGO = ground-glass opacity, GT = genotype, HCV = hepatitis C virus, HIV = human immunodeficiency virus, MERS = Middle East respiratory syndrome, RT-PCR = reverse real-time PCR, SARS-COV-2 = severe acute respiratory syndrome coronavirus-2, SVR = sustained virologic response, WHO = World Health Organization, 3CL pro = chymotrypsin-like protease.

Keywords: COVID-19, danoprevir, HCV protease inhibitor, ritonavir, SARS-COV-2, treatment

1. Introduction

The severe acute respiratory syndrome coronavirus-2 (SARS-CoV-2) has spread rapidly since its identification in patients with severe pneumonia in Wuhan, China. The coronavirus disease 2019 (COVID-19), the disease caused by SARS-CoV-2 infection, has been reported more than 118,000 cases in 114 countries, and 4291 people have lost their lives by March 11, 2020. Given its global outbreak and strong human-to-human transmission and high mortality in the elderly or in patients with complications, the

World Health Organization (WHO) has made the assessment on March 11, 2020 that COVID-19 can be characterized as a pandemic.^[1]

Investigation into approved drugs for new therapeutic indications, which is also known as drug repurposing, has been proved to be a practical strategy in the situation of an outbreak such as COVID-19.^[2,3] Danoprevir is a potent hepatitis C virus (HCV) protease inhibitor with an IC₅₀ of 0.29 nM against HCV protease^[4] and was approved and marketed in 2018 in China as

Editor: Mehmet Bakir.

The authors have no funding to disclose.

The authors report no conflicts of interest.

The work described was original research that has not been published previously. All the authors listed have approved the manuscript that is enclosed. No other interest needs to be declared.

Jinzi J Wu, PhD, one of the corresponding authors, is Chief Executive Officer of Ascletris Pharmaceuticals Co., Ltd. and Ascletris Bioscience Co., Ltd. (together "Ascletris") which provided danoprevir and ritonavir and technical support to this study. Xiaodong Li and Yahong Chen are employees of Ascletris Bioscience Co. Ltd. Ascletris markets and sells danoprevir in China.

All data generated or analyzed during this study are included in this published article [and its supplementary information files].

^aThe First Department of Infectious Disease, ^bThe Intensive Care Unit, ^cThe Radiology Department, ^dThe Second Department of Infectious Disease, The Ninth Hospital of Nanchang, Nanchang 330002, Jiangxi Province, ^eAscletris Bioscience Co., Ltd., Hangzhou 310051, ^fAscletris Pharmaceuticals Co., Ltd., Shaoxing 310051, Zhejiang Province, China.

* Correspondence: Jinzi J. Wu, Room 1201, Building 3, No. 371 Xingxing road, Xiaoshan District, Hangzhou 310051, Zhejiang Province, China (e-mail: jinzi.wu@ascletris.com); Hongyi Chen, 167 Hongdu Middle Road, Nanchang 330002, Jiangxi Province, China (e-mail: Chenhongyi8660@163.com).

Copyright © 2020 the Author(s). Published by Wolters Kluwer Health, Inc.

This is an open access article distributed under the terms of the Creative Commons Attribution-Non Commercial License 4.0 (CCBY-NC), where it is permissible to download, share, remix, transform, and buildup the work provided it is properly cited. The work cannot be used commercially without permission from the journal.

How to cite this article: Chen H, Zhang Z, Wang L, Huang Z, Gong F, Li X, Chen Y, Wu JJ. First clinical study using HCV protease inhibitor danoprevir to treat COVID-19 patients. *Medicine* 2020;99:48(e23357).

Received: 18 May 2020 / Received in final form: 22 September 2020 / Accepted: 26 October 2020

<http://dx.doi.org/10.1097/MD.00000000000023357>

an oral direct-acting antiviral agent to treat hepatitis C. The results of a phase 3 clinical trial with 140 patients showed that the triple regimen of ritonavir-boosted danoprevir plus pegylated-interferon α -2a and ribavirin produced a sustained virologic response (SVR12) rate of 97.1% after 12-week treatment in non-cirrhotic HCV genotype 1-infected Chinese patients.^[5] In another phase 2/3 clinical trial, the SVR12 rate is 99% in treatment naïve, non-cirrhotic HCV GT1-infected patients after 12-week all oral treatment of ritonavir-boosted danoprevir combined with vildasvir (an HCV NS5A inhibitor) and ribavirin.^[6] These results indicated that danoprevir boosted by ritonavir is highly efficacious, safe, and well tolerated in HCV patients.

During SARS-COV-2's life cycle, chymotrypsin-like protease (3CL pro) can cleave viral polyprotein to form the RNA replicase-transcriptase complex, which is essential for both viral transcription and replication.^[7,8] The proteases of HCV and human immunodeficiency virus (HIV) showed similar function as SARS-COV-2, so protease inhibitors are hypothesized to have the therapeutic potential against COVID-19. In vitro and clinical studies in patients with SARS and Middle East respiratory syndrome (MERS) to some extent proved this hypothesis.^[9-11] The homology modeling data indicated that HCV protease inhibitors have the highest binding affinity to SARS-CoV-2 protease among approved drugs.^[12] Molecular docking method analysis showed that danoprevir has the best binding energy for inhibition of main protease of SARS-CoV-2 (-9.3 kcal/mol).^[13] Yet there is still a paucity of clinical data on HCV protease inhibitors in treating COVID-19 patients.

In this study, we for the first time demonstrated the therapeutic efficacy of danoprevir boosted by ritonavir in both treatment naïve and experienced COVID-19 patients.

2. Methods

2.1. Diagnosis

According to the "Diagnosis and Treatment Program for Novel Coronavirus Infection (Trial Version 6)" issued by the National Health Commission of the People's Republic of China (China National Standards),^[14] patients with reverse real-time PCR (RT-PCR) positive of SARS-CoV-2 nucleotide acid are diagnosed as SARS-CoV-2 infection. COVID-19 patients, demonstrating pneumonia manifestation in imaging, respiratory tract symptoms, and RT-PCR positive of SARS-CoV-2 nucleotide acid, are categorized as moderate COVID-19 patients per China National Standards.^[14]

2.2. Study design, patients, treatments, and discharge

In this open clinical trial for the treatment of COVID-19 (ClinicalTrials.gov Identifier: NCT04291729), patients were treated with danoprevir boosted by ritonavir in the presence or absence of interferon nebulization (the background therapy). 10 patients were planned to be enrolled and actually 11 patients were enrolled. All patients were moderate COVID-19 patients per China National Standards.^[14] These patients were recruited and screened, and eligible patients were enrolled and treated with danoprevir boosted by ritonavir in the presence or absence of interferon nebulization (as the background therapy) for 4 to 12 days until being discharged from the hospital. Treatment naïve patients never received any antiviral therapies such as lopinavir/ritonavir and interferon nebulization prior to the treatment of

danoprevir boosted by ritonavir. Treatment experienced patients had received at least 1 dose of any antiviral therapies such as lopinavir/ritonavir and interferon nebulization prior to the treatment of danoprevir boosted by ritonavir. Treatment regimen and dosing frequency are

- (1) danoprevir, 100 mg per tablet, 1 tablet at a time, twice per day;
- (2) ritonavir, 100 mg per tablet, 1 tablet at a time, twice per day;
- (3) if administered, aerosol inhalation of α -interferon (interferon nebulization), 5 million units at a time, twice per day.

The conditions of the patients were monitored daily by attending physicians. Routine laboratory test of blood indexes, biochemical parameters, and chest computer tomography (CT) were carried out in need.

According to China National Standards,^[14] the following 4 conditions must be all met prior to the discharge:

- (1) normal body temperature for more than 3 days;
- (2) significantly recovered respiratory symptoms;
- (3) lung imaging shows obvious absorption and recovery of acute exudative lesion; and
- (4) two consecutive RT-PCR negative tests of SARS-CoV-2 nucleotide acid (respiratory track sampling with interval at least 1 day).

Furthermore, patients were reviewed by expert committee comprised of elite clinicians before the discharge. All patients signed informed consent form. The study was approved by the Ethics Committee of the hospital approved the study (No. 2020-1).

2.3. Inclusion criteria

Chinese adult (18–75 years old in both genders) pneumonia patients with SARS-CoV-2 infection confirmed to be positive by RT-PCR; demonstrated respiratory symptoms and imaging-confirmed pneumonia as defined in China National Standards; naïve patients were newly diagnosed patients who never received any antiviral treatments and danoprevir/ritonavir treatment were initiated within 7 days or less from the diagnosis; experienced patients might receive antiviral therapies with dosage and treatment duration recommended by China National Standards;^[14] women and their partners with no planned pregnancy for 6 months after the study and willing to take effective contraceptive measures within 30 days from the first administration of the study drugs; patients agreed that they would not participate in other clinical trials within 30 days from the last administration of the study drugs; patients were willing to sign informed consent form.

2.4. Exclusion criteria

Severe COVID-19 patients met one of the following conditions:

- (1) respiratory rate (RR) ≥ 30 times/min;
- (2) $\text{SaO}_2/\text{SpO}_2 \leq 93\%$ in resting state;
- (3) arterial partial pressure of oxygen (PaO_2)/concentration of oxygen (FiO_2) ≤ 300 mm Hg (1 mm Hg = 0.133 kPa);

Critical COVID-19 patients met one of the following conditions:

- (1) respiratory failure and need mechanical ventilation;
- (2) shock;
- (3) other organ failure combined with ICU treatment;

Severe liver disease (such as child Pugh score $\geq C$, AST > 5 times upper limit); patients with contraindications specified in the label of ritonavir tablets; the pregnancy test of female subjects during the screening period was positive; the researchers judged that the patient was not suitable to participate in this clinical study (for example, patients with multiple basic diseases).

2.5. RT-PCR protocol

Real-time PCR (RT-PCR) testing of SARS-COV-2 ORF1ab gene was performed in the clinical laboratory of the Ninth Hospital of Nanchang following the test kit instruction of DAAN Gene (manufacturer), Guangzhou, China. The lowest detection limit of this kit is 1×10^3 copies/mL. Briefly, Nasal and phlegm swab specimens were collected and then put in a sterile tube containing 2 to 3 mL of viral transport medium. Total cellular RNA was isolated by TRIzol reagent (Invitrogen) from 200 μ L transport medium. RT-PCR was conducted in LightCycler 480 (Roche) by mixing 17 μ L PCR solution A, 3 μ L PCR solution B, and 5 μ L sample RNA in 1 tube. A positive control was used to determine the positivity of the samples.

2.6. CT scans

Chest CT scans were conducted using Highspeed dual-slice spiral CT (GE, USA). All CT images were axial thin-section non-contrast and were undergone 5 mm reconstruction.

2.7. Efficacy endpoints

Primary endpoint is the rate of composite adverse outcomes (defined as $SPO_2 \leq 93\%$ without oxygen supplementation, $PaO_2/FiO_2 \leq 300$ mm Hg or a respiratory rate ≥ 30 breaths per min without supplemental oxygen). Secondary endpoints include

- (1) time to discharge;
- (2) rate of 2 consecutive RT-PCR negative tests of SARS-CoV-2 nucleotide acid (respiratory track sampling and sampling interval at least 1 day apart);
- (3) lung imaging showing obvious absorption and recovery of acute exudative lesion;
- (4) significantly improved respiratory symptoms;
- (5) normal body temperature for at least 3 days.

2.8. Statistical analysis

The values were presented as median with maximum and minimum values.^t

3. Results

3.1. Baseline demographic and clinical characteristics

A total of 11 moderate COVID-19 patients were enrolled, including 2 naive patients and 9 experienced patients. The baseline demographic characteristics for all enrolled patients are illustrated in Table 1. The age range of the patients were 18 to 66 years old, with 4 males in total 11 patients. Two experienced patients, patient 6 and patient 8, had a history of hypertension. The symptoms reported at illness onset were mainly fever, cough, and shortness of breath. Two naive patients were hospitalized for 9 and 7 days, respectively, and the experienced patients were hospitalized for a median duration of 20 days.

Table 1

Baseline demographic characteristics, underlying medical condition, and clinical characteristics of 11 patients receiving danoprevir boosted by ritonavir treatment.

| | Naive (N=2) | Experienced (N=9) |
|------------------------------------|-------------|-------------------------|
| Median age – yr | 44, 18 | 44 (18–66) [*] |
| Median hospitalization – d | 9, 7 | 20 (7–22) [*] |
| Male | 1 | 3 |
| Underlying medical conditions | No, No | 2 [†] |
| Symptoms reported at illness onset | | |
| Fever | No, no | 4 |
| Cough | No, yes | 3 |
| Shortness of breath | No, yes | 6 |

^{*} The values were presented as median with maximum and minimum values in bracket.

[†] Two experienced patients, patient 6 and patient 8, had a history of hypertension.

The key parameters of 11 patients were presented in Table 2 and illustrated graphically in Figure 1. In general, 9 patients experienced lopinavir/ritonavir along with interferon nebulization treatment were enrolled and switched to danoprevir/ritonavir treatment, including 4 patients with interferon nebulization and 5 patients without interferon nebulization after switching. Two naive patients received danoprevir/ritonavir plus interferon nebulization treatment. After initiation of danoprevir/ritonavir treatment, the first negative RT-PCR test occurred at a median of 2 days, ranging from 1 to 8 days, and the obvious absorption in CT scans occurred at a median 3 days, ranging from 2 to 4 days.

3.2. Naïve patients receiving danoprevir/ritonavir plus interferon nebulization

Two treatment naïve patients received danoprevir/ritonavir plus interferon nebulization upon hospitalization. No patient had composite adverse outcomes during this study. The medical history, treatment, and various examinations for 1 of 2 patients, patient 1, were described in details below.

On February 19, 2020, a woman aged 44, who had a close contact with a COVID-19 patient, was tested positive SARS-COV-2 in nasal swab with RT-PCR and thus admitted to the hospital. The vital sign of the patient showed body temperature (BT) of 36.4°C and oxygen saturation (SPO_2) of 99% under ambient air. The breathing sound was normal initially. She had no other underlying disease before this onset. In the morning of February 20, she was given the first dose of danoprevir boosted by ritonavir, along with interferon nebulization. On February 20, both lower lungs showed multiple diffuse patch-shape areas and ground-glass opacity (GGO), especially obvious in the left lower lung, based on chest CT scans (Fig. 2A). The laboratory results revealed lymphopenia ($0.62 \times 10^9/L$) and elevated platelet ($322 \times 10^9/L$) (Table 3). On February 22, 3 days after receiving danoprevir boosted by ritonavir treatment, the patient did not show abnormal symptoms or vital signs. The lower lobe of bilateral lung showed decreased GGO and patch-shaped areas compared to the previous image on February 20, indicating partial absorption (Fig. 2B). The RT-PCR results of nasal swab became negative. These results indicated the patient had a quick response to the treatment of danoprevir boosted by ritonavir, along with interferon nebulization. On February 24, 5 days after receiving danoprevir boosted by ritonavir treatment, the GGO and patch-shaped areas in both lungs significantly decreased in density and scale (Fig. 2C) compared to the

Table 2
Key parameters of 11 patients receiving danoprevir boosted by ritonavir treatment.

| | Days of hospitalization | Antiviral experience before danoprevir/ritonavir treatment | Days of lopinavir/ritonavir plus IFN nebulization treatment prior to the study | Days of danoprevir/ritonavir plus IFN nebulization treatment during the study | Days of danoprevir/ritonavir treatment without IFN nebulization during the study | Days of first negative RT-PCR test after initiation of danoprevir/ritonavir treatment* | Days of obvious absorption in CT scans after initiation of danoprevir/ritonavir treatment |
|------------|-------------------------|--|--|---|--|--|---|
| Patient 1 | 9 | Naive | NA | 9 | NA | 2 | 4 |
| Patient 2 | 7 | Naive | NA | 7 | NA | 4 | 2 |
| Patient 3 | 7 | Experienced | 3 | 4 | NA | 1 | 2 |
| Patient 4 | 10 | Experienced | 2 | 8 | NA | 1 | 4 |
| Patient 5 | 17 | Experienced | 5 | 12 | NA | 2 | 3 |
| Patient 6 | 9 | Experienced | 3 | 6 | NA | 3 | 3 |
| Patient 7 | 22 | Experienced | 13 | NA | 9 | 2 | 3 |
| Patient 8 | 20 | Experienced | 11 | NA | 5 | 2 | 3 |
| Patient 9 | 21 | Experienced | 13 | NA | 8 | 2 | 4 |
| Patient 10 | 21 | Experienced | 13 | NA | 8 | 4 | † |
| Patient 11 | 22 | Experienced | 10 | NA | 9 | 8 | 3 |

NA, not applicable; RT-PCR=reverse real-time PCR.

* First negative tests were confirmed by second RT-PCR tests with at least 1-d interval.

† Patient 10's lung imaging did not show obvious lesion at admission and during the hospitalization.

previous image on February 22. And the RT-PCR results of nasal swab were repeatedly negative on February 24 and February 26. On February 28, patient #1 was given the last dose of danoprevir boosted by ritonavir, along with interferon nebulization. Since she met all 4 discharge standards described in Section 2, the patient was discharged from the hospital on the same day.

3.3. Experienced patients treated with lopinavir/ritonavir plus interferon nebulization and switched to danoprevir/ritonavir with or without interferon nebulization

Nine treatment experienced patients were on lopinavir/ritonavir plus interferon nebulization treatment ranging from 2 to 13 days. Four patients experienced lopinavir/ritonavir plus interferon

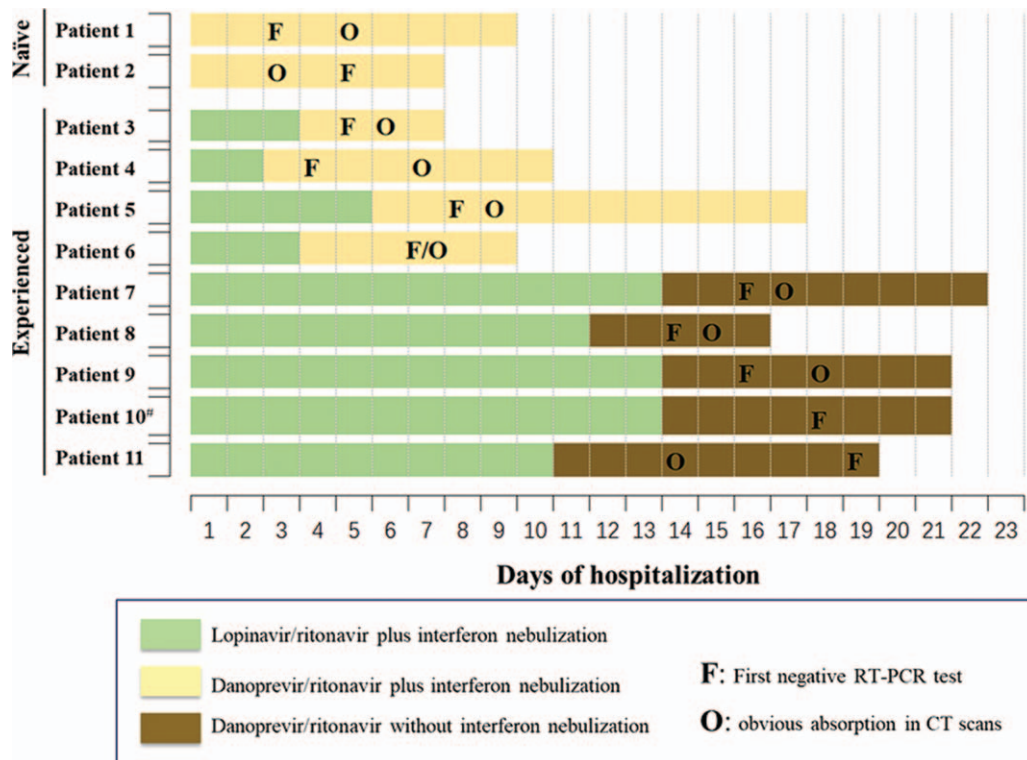


Figure 1. Timeline of RT-PCR tests, CT scans, and antiviral treatments of the enrolled patients. [#]Patient 10's lung imaging did not show obvious lesion at admission and during the hospitalization.

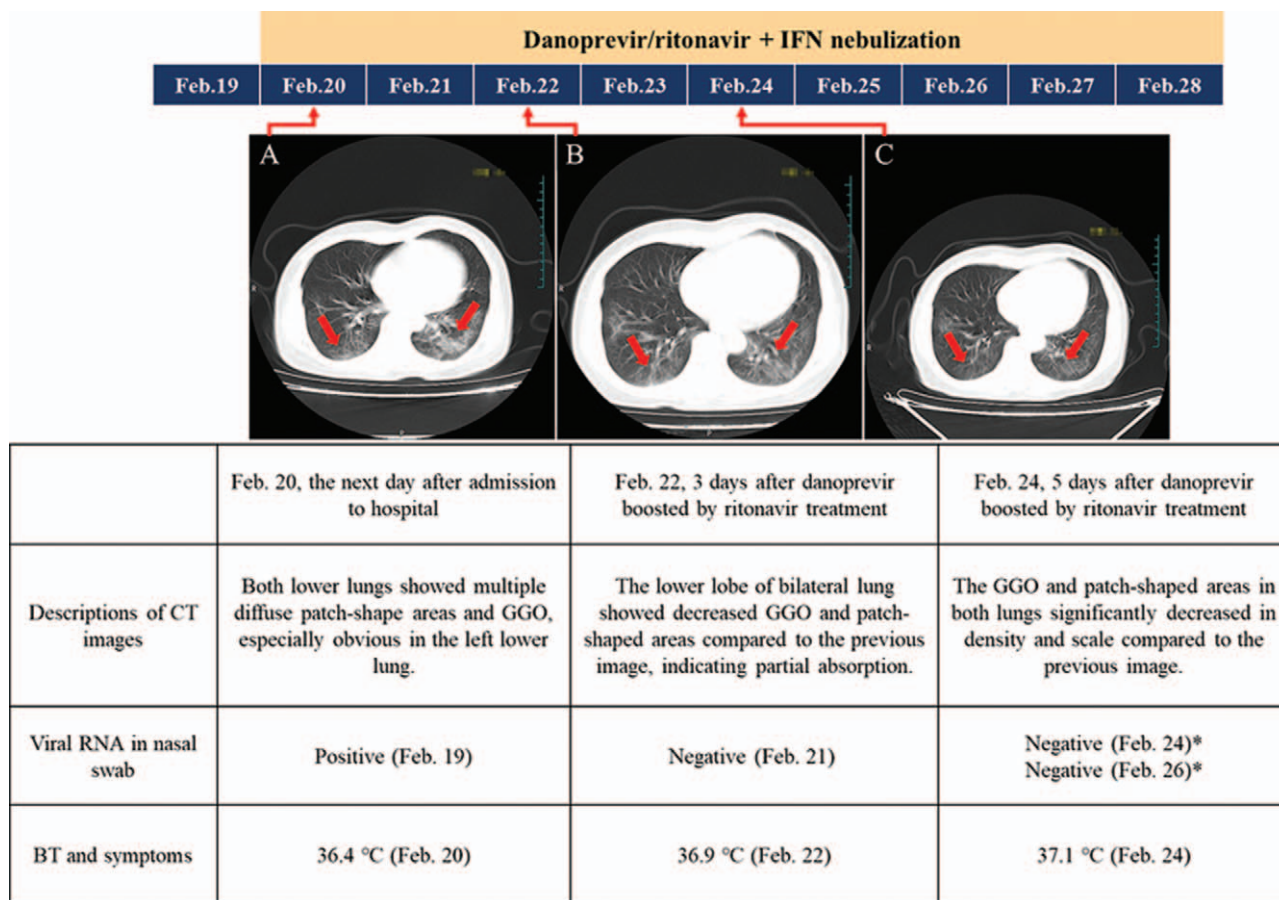


Figure 2. Naïve patient receiving danoprevir/ritonavir plus interferon nebulization (patient 1). GGO, ground-glass opacity. Red arrows indicate the possible lesions.

nebulization treatment for 2 to 5 days with CT scans worsened and switched to danoprevir/ritonavir with interferon nebulization. No patient had composite adverse outcomes during this study. The medical history, treatment, and various examinations for one of the patients, patient 6, were described in details below.

On February 14, 2020, a man aged 47 was admitted in to the hospital for positive RT-PCR nucleic acid test of SARS-CoV-2 in nasal swab. His family member was diagnosed with COVID-19 on February 11. Based on chest CT scans, subpleural area of the right lower lung showed GGO (Fig. 3A). On admission, the patient reported a 3-day history of chest distress and fatigue. He showed no signs of fever, shortness of breath, nausea, and diarrhea. He had a history of hypertension. In the evening of February 14, he was given the first dose of Kaletra (lopinavir (200mg)/ritonavir (50mg), per tablet), 2 tablets at a time, twice per day, along with interferon nebulization. On February 15, the patient reported he still had chest distress. Soft thin stool was still reported and occasional cough and white sputum appeared. The patient continued lopinavir/ritonavir treatment and received rehydration supportive care. On February 17, 3 days after receiving lopinavir/ritonavir treatment, the lower lung showed further consolidation, along with GGO and patch-shape areas based on CT scans (Fig. 3B). Therefore, in the evening of February 17, lopinavir/ritonavir treatment was stopped and the patient was switched to danoprevir boosted by ritonavir, along with interferon nebulization. On February 18, patient had a weak positive RT-PCR test for viral RNA in nasal swab. On February

20, 4 days after receiving danoprevir boosted by ritonavir treatment, the right lower lung showed shrunken patch-shape areas and decreased density of GGO (Fig. 3C). On the same day, RT-PCR test with the nasal swab became negative and remained negative at the next day RT-PCR test. In the morning of February 23, the patient received the last dose of danoprevir boosted by ritonavir treatment. Since he met all 4 discharge standards described in Section 2, the patient was discharged from the hospital on the same day.

Five patients failed lopinavir/ritonavir plus interferon nebulization and switched to danoprevir/ritonavir without interferon nebulization. The medical history, treatment, and various examinations for 1 of patients, patient 8, were described in details below.

On February 9, a woman aged 42, who was a permanent resident in Wuhan City, was admitted to the hospital due to maximum BT 38°C and RT-PCR positive SARS-CoV-2 in nasal swab. She had occasional coughs with white sputum. The vital sign of the patient showed BT of 37.4°C and SPO₂ of 99% under ambient air. The patient had half-year history of hypertension. The patient was given the first dose of lopinavir/ritonavir, 2 tablets at a time, twice per day, along with interferon nebulization in the evening of February 9. On February 10, based on CT scans, subpleural areas of both lower lungs and the tongue-like segment of the left lung showed GGO and patch-shape areas (Fig. 4A). From February 10 to February 13, the patient showed slightly fluctuating BT (maximum 37.3°C to minimum 36.4°C), coughs

Table 3

Laboratory tests and underlying disease of 3 representative patients before and after receiving danoprevir boosted by ritonavir treatment.

| | Patient 1 (naïve) | | Patient 6 (lopinavir/ritonavir experienced) | | Patient 8 (lopinavir/ritonavir experienced) | |
|---------------------------------------|---|---|---|---|---|---|
| | 44 | 47 | 42 | 42 | 42 | 42 |
| Age (yr) | 44 | 47 | 42 | 42 | 42 | 42 |
| Sex | Female | Male | Female | Female | Female | Female |
| Underlying disease | No | Hypertension | Hypertension | Hypertension | Hypertension | Hypertension |
| | Hospital day 1, before danoprevir/ritonavir treatment | Hospital day 1, before danoprevir/ritonavir treatment | Hospital day 1, before danoprevir/ritonavir treatment | Hospital day 1, before danoprevir/ritonavir treatment | Hospital day 1, before danoprevir/ritonavir treatment | Hospital day 1, before danoprevir/ritonavir treatment |
| White-cell count (10 ⁹ /L) | 4–10 | – | 6.5 | 6.34 | 5.58 | 5.58 |
| Red-cell count (10 ⁹ /L) | 3.5–5.5 | – | 5.69† | 3.95 | 4.77 | 4.77 |
| Neutrophil count (10 ⁹ /L) | 2–7.7 | – | 3.66 | 4.42 | 4.46 | 4.46 |
| Lymphocyte count (10 ⁹ /L) | 0.8–4 | – | 2.23 | 1.36 | 0.65↓ | 0.65↓ |
| Platelet count (10 ⁹ /L) | 100–300 | – | 170 | 211 | 145 | 145 |
| Hemoglobin (g/L) | 110–160 | – | 112 | 101 | 147 | 147 |
| Hematocrit (%) | 36–50 | – | 36 | 27.3↓ | 43.0 | 43.0 |
| Sodium (mmol/L) | 136–144 | – | 142.3 | 141.41 | 139.8 | 139.8 |
| Potassium (mmol/L) | 3.6–5.5 | 139.5 | 3.54↓ | 4.18 | 3.21↓ | 3.21↓ |
| Chloride (mmol/L) | 96–108 | 4.47 | 96.76 | 97.96 | 98.7 | 98.7 |
| Calcium (mmol/L) | 2.2–3.2 | 96.0 | 2.22 | 2.19↓ | 2.31 | 2.31 |
| Glucose (mmol/L) | 3.88–6.11 | – | 10.2† | 6.06 | 6.06 | 6.06 |
| Urea (mmol/L) | 2.9–6.42 | 4.76 | 4.82 | 4.55 | 2.83↓ | 2.83↓ |
| Creatinine (mmol/L) | 56–97 | 3.07 | 85 | 93 | 69 | 69 |
| Total protein (g/L) | 60–87 | 68 | 71 | 63.7 | 74.1 | 74.1 |
| Albumin (g/L) | 35–55 | 37.7 | 42.8 | 37.5 | 47.9 | 47.9 |
| Total bilirubin (μmol/L) | 3.42–20.5 | 10.5 | 9.6 | 9 | 12.9 | 12.9 |
| Procalcitonin (ng/ml) | 0–0.5 | – | <0.1 | <0.1 | – | – |
| ALT (U/L) | 0–40 | 10.4 | 24 | 18.8 | 26.4 | 26.4 |
| AST (U/L) | 0–40 | 14.2 | 22.6 | 15.5 | 21.0 | 21.0 |
| ALP (U/L) | 0–150 | 53 | 79 | 75 | 72 | 72 |
| Fibrinogen (g/L) | 2–4 | – | 4.38† | – | 3.86 | 3.86 |
| LDH (U/L) | 109–245 | – | 177 | 150 | 219 | 219 |
| PT (s) | 10–14 | – | 12.3 | – | 12.1 | 12.1 |

ALP = alkaline phosphatase; ALT = alanine aminotransferase; AST = aspartate aminotransferase; INR = International normalized ratio; LDH = lactate dehydrogenase; PT = prothrombin time. † indicates the value is lower than the minimum reference value. ‡ indicates the value is higher than the maximum reference value.

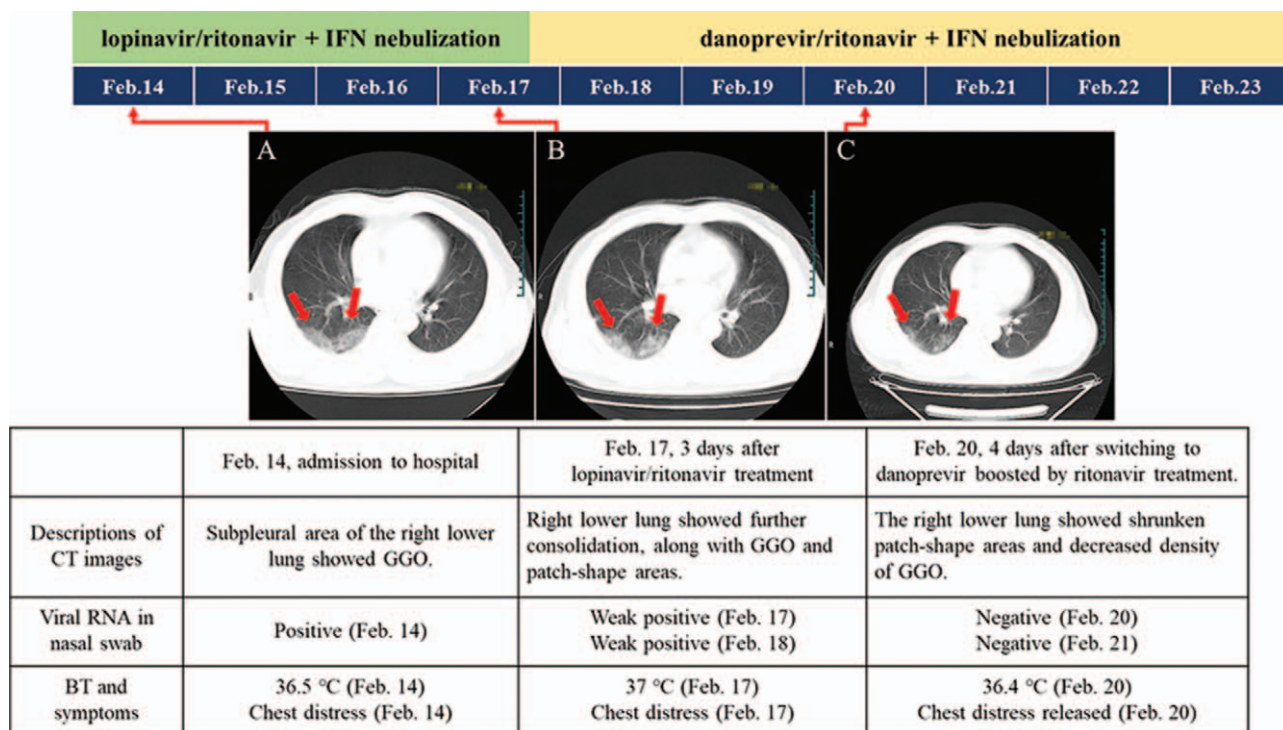


Figure 3. Experienced patient treated with lopinavir/ritonavir plus interferon nebulization for 3d and switched to danoprevir/ritonavir plus interferon nebulization (patient 6). GGO, ground-glass opacity. Red arrows indicate the possible lesions.

with white sputum, anorexia, and diarrhea with yellow thin stool. The laboratory results revealed leukopenia ($3.40 \times 10^9/L$) and lymphopenia ($0.7 \times 10^9/L$) (Table 3). On February 13, 4 days after receiving lopinavir/ritonavir treatment, GGO and patch-shape areas showed a slightly higher density (Fig. 4B) compared to previous CT image on February 10. On February 17, 8 days after receiving lopinavir/ritonavir treatment, the patient reported improved appetite and sleeping while coughing with white

sputum remained. CT scan showed that no significant changes were observed compared to previous CT image on February 13 and the opacities at tongue-like segment increased (Fig. 4C). On February 19, the patient received the last dose of lopinavir/ritonavir and interferon nebulization. The treatment duration of both lopinavir/ritonavir and interferon nebulization exceeded the recommendation by China National Standards.^[14] As a result, both lopinavir/ritonavir and interferon nebulization were

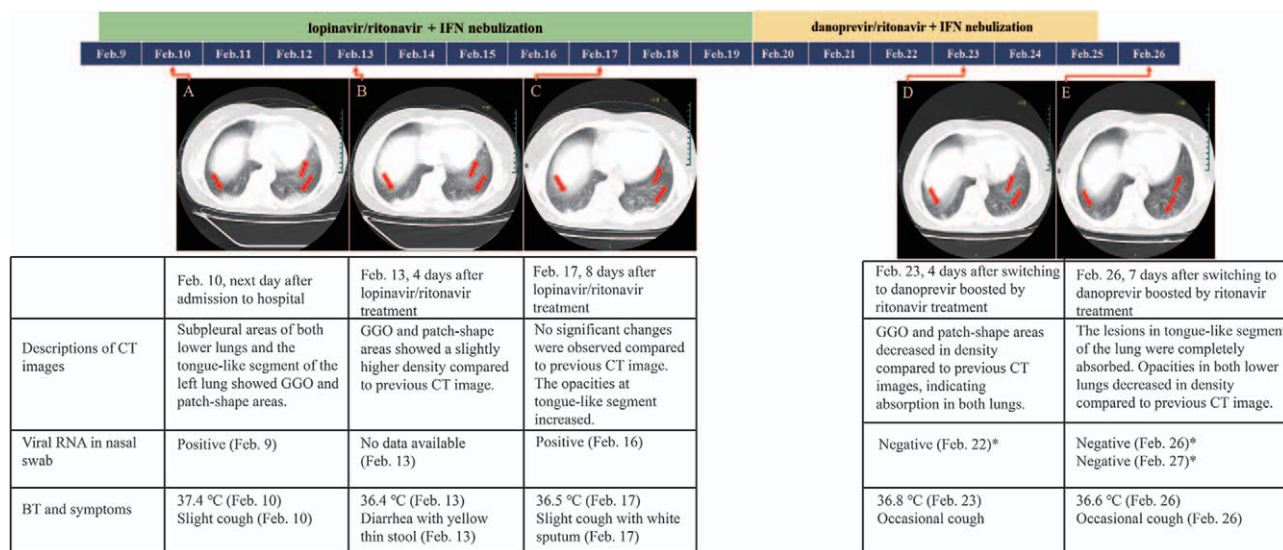


Figure 4. Patient failed lopinavir/ritonavir plus interferon nebulization and switched to danoprevir/ritonavir without interferon nebulization (patient 8). GGO, ground-glass opacity. Red arrows indicate the possible lesions. *Viral RNA was undetectable in both nasal and phlegm swabs.

stopped. On February 20, she was switched to danoprevir boosted by ritonavir without interferon nebulization. On February 22, 3 days after receiving danoprevir/ritonavir treatment, RT-PCR test was negative in both nasal and phlegm swabs. On February 23, 4 days after switching to danoprevir boosted by ritonavir, the patient showed improved white blood cell count ($4.31 \times 10^9/L$) (Table 3). CT scans showed GGO and patch-shape areas decreased in density compared to previous CT images on February 17, indicating absorption in both lungs (Fig. 4D). On February 25, the patient received the last dose of danoprevir boosted by ritonavir. On February 26, CT scans showed the lesions in tongue-like segment of the lung were completely absorbed. Opacities in both lower lungs decreased in density compared to previous CT images (Fig. 4E). RT-PCR tests were repeatedly negative in both nasal and phlegm swabs on February 26 and February 27. On February 29, the patient was discharged from the hospital since she met all 4 discharge standards as described in Section 2.

4. Discussion

Our study for the first time demonstrated the therapeutic efficacy in moderate COVID-19 patients with the treatment of danoprevir, an HCV NS3/4A protease inhibitor marketed in China, boosted by ritonavir, a pharmacokinetic enhancer of danoprevir and an HIV protease inhibitor. As a marketed drug, danoprevir has been demonstrated safe and well tolerated in thousands of HCV patients in China. Ritonavir is approved HIV drug and pharmacokinetic booster with more than 15-year clinical use.

Although many clinical trials involving many different drugs are ongoing in China and globally, including protease inhibitors, RNA-dependent RNA polymerase (RDRP) inhibitors, none of them has been approved for COVID-19 indication by regulatory authorities of major countries. In a randomized, controlled, open-label trial involving hospitalized adult patients with severe illness caused by SARS-CoV-2 infection (SaO_2 of 94% or less while they were breathing ambient air or $PaO_2/FiO_2 \leq 300$ mm Hg), there were no significant differences between lopinavir-ritonavir treatment and standard care in terms of time to clinical improvement, mortality at 28 days, and percentages of patients with detectable viral RNA at various time points.^[15] A retrospective study of COVID-19 patients demonstrated that no significant differences were observed between lopinavir/ritonavir group (all 52 patients were moderate) and control group (without receiving any antiviral drugs; 91.67% of 48 patients were moderate) in terms of median time to temperature normalization, median time to PCR negative, PCR negative rates at day 7 after admission and radiological worsening at day 7.^[16]

Around 5% of COVID-19 cases were critical with a mortality of over 50%,^[17] so it is essential to treat and prevent the mild or moderate cases progressing into severe or critical ones. Our report demonstrated that danoprevir boosted by ritonavir can suppress viral replication in less than 1 week and effectively reduce GGO and patch-shape areas. Viral nucleic acids in nasal swabs turned negative at a median of 2 days and the absorption occurred at a median of 3 days after the initiation of danoprevir/ritonavir treatment.

The mortality rate of COVID-19 patients with hypertension, cardiovascular diseases, and with preexisting comorbid conditions was much higher than normal patients (6.0–10.5% vs 2.3%).^[18] Two patients involved in this report had a history of

hypertension, but they showed a quick response with negative PCR tests in 2 days and normalized lung imaging in 3 days after the initiation of danoprevir/ritonavir treatment, respectively. However, we still need large-scale study to investigate the efficacy of danoprevir/ritonavir in COVID-19 patients with hypertension.

Of 11 patients enrolled, 8 patients showed significant clinical manifestations such as fever, cough, and dry coughing, while 3 patients did not show significant clinical manifestations. Therefore, the most reliable indicators for treatment efficacy should be improved lung imaging via CT scans and dramatically reduced virus load through RT-PCR tests.

This study highlights the first-time successful treatment of 3 COVID-19 patients by HCV protease inhibitor. Nucleic acid testing results suggested 4 to 12-day treatment of danoprevir/ritonavir can effectively suppress viral replication and improve patient's health conditions, especially for those patients with moderate COVID-19. This report also highlights the therapeutic effect of danoprevir/ritonavir treatment on both antiviral naive and experienced patients. SARS-CoV-2 is an RNA virus and thus prone to mutate under the antiviral drug pressure. In the real world of clinic practice, patients usually experience various kinds of treatments, which could lead to drug-resistant mutations. Combination of agents that target different phases of viral life cycle should minimize the incidents of drug-resistance. However, there were several limitations in this study. First, lack of a control group limited the comparability to other studies since failure in therapy may be due to the factors otherwise the investigational regimen. Second, due to the adequate control of SARS-CoV-2 pandemic in China, the sample size is small. Thus, large-scale study with control is needed to investigate the efficacy and safety of danoprevir on the COVID-19.

5. Conclusions

In conclusion, repurposing danoprevir, a marketed HCV protease inhibitor, represents a promising therapeutic option for COVID-19 patients.

Acknowledgments

We thank all the patients involved in this study; the nurses and clinical staff who are providing care for the patients; staff at the clinical laboratory of the Ninth hospital of Nanchang.

Author contributions

HC and JW conceived and designed the study. ZZ, FG, ZH, and LW contributed and performed data collection and analysis. HC, XL, and JW contributed to the literature search and manuscript drafting. YC, HC, and JW contributed to the planning and operation of the clinical study. All authors provided critical review of the manuscript and approved the final draft for publication.

Conceptualization: Hongyi Chen, Jinzi Wu.

Data curation: Zhicheng Zhang, Li Wang, Zhihua Huang, Fanghua Gong.

Investigation: Hongyi Chen, Xiaodong Li, Jinzi Wu.

Project administration: Hongyi Chen, Yahong Chen, Jinzi Wu.

Writing – original draft: Hongyi Chen, Xiaodong Li, Jinzi Wu.

Writing – review & editing: Hongyi Chen, Zhicheng Zhang, Li Wang, Zhihua Huang, Fanghua Gong, Xiaodong Li, Yahong Chen, Jinzi Wu.

References

- [1] WHO Director-General's opening remarks at the media briefing on COVID-19-11 March 2020. 2020 [cited 2020 March 12th]; Available from: <https://www.who.int/dg/speeches/detail/who-director-general-s-opening-remarks-at-the-media-briefing-on-covid-19-11-march-2020>.
- [2] Morse JS, Lalonde T, Xu S, et al. Learning from the past: possible urgent prevention and treatment options for severe acute respiratory infections caused by 2019-nCoV. *Chembiochem* 2020;21:730–8.
- [3] Garcia-Serradilla M, Risco C, Pacheco B. Drug repurposing for new, efficient, broad spectrum antivirals. *Virus Res* 2019;264:22–31.
- [4] Seiwert SD, Andrews SW, Jiang Y, et al. Preclinical characteristics of the hepatitis C virus NS3/4A protease inhibitor ITMN-191 (R7227). *Antimicrob Agents Chemother* 2008;52:4432–41.
- [5] Wei L, Shang J, Ma Y, et al. Efficacy and safety of 12-week interferon-based danoprevir regimen in patients with genotype 1 chronic hepatitis C. *J Clin Transl Hepatol* 2019;7:221–5.
- [6] Xu X, Feng B, Guan Y, et al. Efficacy and safety of all-oral, 12-week ravidasvir plus ritonavir-boosted danoprevir and ribavirin in treatment-naïve noncirrhotic HCV genotype 1 patients: results from a phase 2/3 clinical trial in China. *J Clin Transl Hepatol* 2019;7:213–20.
- [7] Wan Y, Shang J, Graham R, et al. Receptor recognition by the novel coronavirus from Wuhan: an analysis based on decade-long structural studies of SARS coronavirus. *J Virol* 2020;94:e00127-20.
- [8] Liu Z, Xiao X, Wei X, et al. Composition and divergence of coronavirus spike proteins and host ACE2 receptors predict potential intermediate hosts of SARS-CoV-2. *J Med Virol* 2020;92:595–601.
- [9] Yao TT, Qian JD, Zhu WY, et al. A systematic review of lopinavir therapy for SARS coronavirus and MERS coronavirus – a possible reference for coronavirus disease-19 treatment option. *J Med Virol* 2020;92:556–63.
- [10] Chu CM, Cheng VC, Hung IF, et al. Role of lopinavir/ritonavir in the treatment of SARS: initial virological and clinical findings. *Thorax* 2004;59:252–6.
- [11] Brown AJ, Won JJ, Graham RL, et al. Broad spectrum antiviral remdesivir inhibits human endemic and zoonotic deltacoronaviruses with a highly divergent RNA dependent RNA polymerase. *Antiviral Res* 2019;169:104541.
- [12] Nguyen D, Gao K, Chen J, et al. Potentially highly potent drugs for 2019-nCoV. *bioRxiv* 2020;[Preprint]: 2020.02.05.936013.
- [13] S.T. Virtual High Throughput Screening Based Prediction of Potential Drugs for COVID-19. Preprints 2020.
- [14] Lee JW, Lim HS, Kim DW, et al. The development and implementation of stroke risk prediction model in National Health Insurance Service's personal health record. *Comput Methods Programs Biomed* 2018;153:253–7.
- [15] Cao B, Wang Y, Wen D, et al. A trial of lopinavir–ritonavir in adults hospitalized with severe Covid-19. *N Engl J Med* 2020;382:1787–99.
- [16] Chen J, Ling Y, Xi X, et al. Efficacies of lopinavir/ritonavir and abidol in the treatment of novel coronavirus pneumonia. *J Chin J Infect Dis* 2020;38:E008.
- [17] Huang C, Wang Y, Li X, et al. Clinical features of patients infected with 2019 novel coronavirus in Wuhan, China. *Lancet* 2020;395:497–506.
- [18] Guan WJ, Ni ZY, Hu Y, et al. Clinical characteristics of coronavirus disease 2019 in China. *N Engl J Med* 2020;382:1708–20.