








Injection Laryngoplasty for Children with Dysphagia after Cardiac Surgery

Derek Sheen, MD¹ , Thomas K. Houser, MD¹ ,
Sofia E. Olsson, BS² , Helene Dabbous, MD³ ,
Yann-Fuu Kou, MD^{1,4} ,
Romaine F. Johnson, MD, MPH, FACS^{1,4} , and
Stephen R. Chorney, MD, MPH^{1,4} 

OTO Open
2024, Vol. 8(2):e142
© 2024 The Authors. OTO Open
published by Wiley Periodicals LLC
on behalf of American Academy of
Otolaryngology-Head and Neck
Surgery Foundation.
DOI: 10.1002/oto2.142
<http://oto-open.org>

WILEY

Abstract

Objective. To determine whether injection laryngoplasty (IL) resolves thin liquid aspiration among children with unilateral vocal cord paralysis (UVCP) after cardiac surgery.

Study Design. Retrospective case-control.

Setting. Tertiary children's hospital.

Methods. Consecutive children (<5 years) between 2012 and 2022 with UVCP after cardiac surgery were included. Resolution of thin liquid aspiration after IL versus observation was determined for children obtaining videofluoroscopic swallow studies (VFSS).

Results. A total of 32 children with left UVCP after cardiac surgery met inclusion. Initial surgeries were N = 9 (28%) patent ductus arteriosus ligations, N = 7 (22%) aortic arch surgeries, N = 9 (28%) surgeries for hypoplastic left heart syndrome, and N = 7 (22%) other cardiac surgeries. The mean age at initial surgery was 1.8 months (SD: 3.7). All children had a VFSS obtained after surgery that confirmed aspiration. There were 17 children that obtained an IL at 33.6 months (SD: 20.9) after cardiac surgery and 15 children observed without IL procedure. No surgical complications after IL were noted. The rate of aspiration resolution based on postoperative VFSS was N = 14 (82%) for the IL group and N = 9 (60%) for the control group $P = .24$. Documented VFSS aspiration resolution after cardiac surgery occurred by 9.6 months (SD: 10.0) in the observation group and 47.4 months (SD: 24.1) in the IL group ($P < .001$).

Conclusion. IL can help treat aspiration in children with UVCP after cardiac surgery but the benefit beyond observation remains unclear. Future studies should continue to explore the utility for IL in managing dysphagia in this pediatric population.

Keywords

aspiration, cardiac surgery, injection medialization laryngoplasty, pediatric dysphagia, unilateral vocal cord paralysis

Received November 8, 2023; accepted April 7, 2024.

Cardiac disease is among the most common congenital defects, affecting 0.8% to 1.5% of live births worldwide.¹ Advances in cardiovascular medicine have led to surgical interventions being offered within the first year of life. During cardiac surgery, especially with sternotomy, there is a recognized risk of iatrogenic injury to the recurrent laryngeal nerve that occurs in as many as 65% of procedures.^{2–5}

Unilateral vocal cord paralysis (UVCP) from recurrent laryngeal nerve injury in children can cause dysphagia and respiratory difficulties.^{6–8} Aspiration, which is 2.5 times more likely in patients with UVCP, results in significant morbidity.⁹ This impact on swallowing is particularly challenging given the variable recovery rates that can span months to years.^{6,10} The potential for spontaneous UVCP recovery after recurrent laryngeal nerve injury leads to the pursuit of temporary interventions such as injection laryngoplasty (IL) to address dysphagia.

To date, there is limited objective data on swallowing outcomes after IL for UVCP in the pediatric cardiac population. Recent evidence has suggested that pediatric patients who undergo IL within 6 months of UVCP make greater dietary progress.¹⁰ Most studies, however, offer varying definitions of improvement, include a variety of

¹Department of Otolaryngology-Head and Neck Surgery, University of Texas Southwestern Medical Center, Dallas, Texas, USA

²Burnett School of Medicine at Texas Christian University, Fort Worth, Texas, USA

³Department of Otolaryngology-Head and Neck Surgery, West Virginia University, Morgantown, West Virginia, USA

⁴Department of Pediatric Otolaryngology, Children's Health, Dallas, Texas, USA

This manuscript was presented at the AAO-HNSF 2023 Annual Meeting & OTO Experience; September 30-October 4, 2023; Nashville, Tennessee.

Corresponding Author:

Stephen R. Chorney, MD, MPH, Department of Otolaryngology-Head and Neck Surgery, University of Texas Southwestern Medical Center, 2350 N. Stemmons Freeway, F6.221, Dallas, TX 75207, USA.
Email: stephen.chorney@utsouthwestern.edu

UVCP etiologies, and lack a control group. The primary objective of this study was to determine resolution of thin liquid aspiration after IL on videofluoroscopic swallow studies (VFSS) among children with UVCP from cardiac surgery. Using a control group observed without IL, contributions from spontaneous improvement in pediatric dysphagia over time could be captured. We hypothesized that IL would offer a higher proportion of aspiration resolution compared to children not receiving this intervention.

Methods

The University of Texas Southwestern Institutional Review Board (IRB) approved the study of children diagnosed with dysphagia at Children's Health in Dallas, Texas (STU-2018-0284). A retrospective case-control study was designed for consecutive children referred to the aerodigestive providers in the pediatric otolaryngology department between 2012 and 2022. All included children were diagnosed with UVCP by bedside flexible fiberoptic laryngoscopy (FFL) and had a history of cardiac surgery in the first 5 years of life. Cardiac procedures were determined based on operative reports and included: patent ductus arteriosus ligations, aortic arch surgeries, surgeries for tetralogy of Fallot, as well as repair of hypoplastic left heart syndrome (Norwood and Fontan procedures). All children needed to have a VFSS confirming thin liquid aspiration.

The study population was then separated into two groups. The intervention group included all children that underwent vocal cord IL medialization. These procedures occurred with the child placed under general anesthesia for suspension microlaryngoscopy, bronchoscopy, and vocal cord injection. A carboxymethylcellulose gel was injected to the paraglottic space via transoral approach to provide sufficient medialization of the immobile true vocal cord (**Figure 1A–C**). Only children that obtained a

postintervention VFSS were captured. The control group were children who met similar inclusion criteria but did not obtain a vocal cord injection. These children also had a history of cardiac surgery, UVCP diagnosed by FFL, and underwent a second VFSS to monitor progression in swallowing outcomes. The patients were allocated to study or control groups according to clinician preference.

Exclusion criteria for this study were children who: were older than 5 years old at the time of cardiac surgery, underwent other major airway surgery, had vocal cord paralysis not secondary to a cardiac procedure, did not have preoperative and postoperative VFSS, did not obtain serial VFSS if in the control group, and those with incomplete follow up. Children who had cardiac or vocal cord surgery outside of Children's Medical Center Dallas were also excluded.

The primary objective was the proportion of children who had interval resolution of thin liquid aspiration. This was determined based on VFSS results. Secondary objectives assessed intraoperative and 30-day complication rates, improvement in pharyngeal dysphagia severity as assessed by our speech-language therapists, duration of time to recorded resolution of aspiration from injection, ability to wean thickening agents, and liberation of alternative means of nutrition including nasogastric tubes or gastrostomy tubes.

We collected the following variables including age at initial surgery (months), sex (male or female), cardiac procedure performed, dates of instrumental swallow studies, presence or absence of feeding tubes, and consistency of feeds tolerated. Additionally, gestational age (weeks), weight at surgery (kilograms), syndromic diagnosis (yes/no), history of extracorporeal membrane oxygenation (ECMO) (yes/no), intraventricular or cerebral hemorrhage history (yes/no), and developmental delay diagnosis (yes/no) were also recorded.

All statistics were performed with Stata (StataCorp, 2023, Stata Statistical Software: Release 18; StataCorp

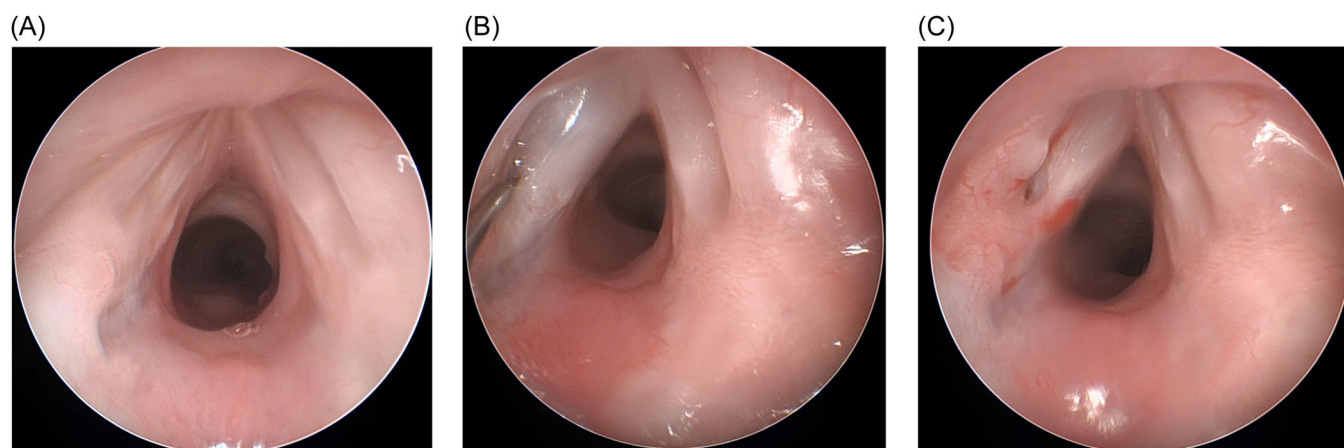


Figure 1. (A) Direct microlaryngoscopy of a 6-month-old male with left unilateral vocal cord paralysis following a history of coarctation of the aorta repair. (B) Injection laryngoplasty (IL) of the left vocal cord using carboxymethylcellulose gel. (C) post IL view of the glottis with medialization of left vocal cord.

LLC.). Continuous data are presented as means with standard deviations (SD) or medians with interquartile range (IQR), where appropriate. Categorical data are presented as counts with percentage. Univariable analysis utilized Student's *t*-testing for continuous variables and Fisher's exact test for categorical variables. Statistical significance was set at $P < .05$. Strengthening the Reporting of Observational Studies in Epidemiology (STROBE) guidelines were followed.¹¹

Results

A total of 32 children met inclusion criteria with 17 children obtaining an IL and 15 children observed without an IL procedure. Mean age at initial cardiac surgery was 1.8 months among all children (SD: 3.7). The cardiac surgeries included were N = 9 (28%) patent ductus arteriosus ligations, N = 7 (22%) aortic arch surgeries, N = 9 (28%) surgeries for hypoplastic left heart syndrome, and N = 7 (22%) other cardiac surgeries. All children had thin liquid aspiration on initial VFSS and all had left vocal cord paralysis.

The children in the intervention group received an injection at 33.6 months (SD: 20.9) after cardiac surgery. Of note, no surgical complications after injection laryngoplasty were documented. Intraoperatively, there were no cases of bronchospasm or laryngospasm. Post-operatively there were no cases of stridor, reintubation within 30 days, or increased oxygen requirements necessitating supplementation. There were also no documented long-term sequelae on chart review within 30 days of IL after a mean of 4.4 years (SD: 2.1) of follow-up.

A subsequent VFSS was obtained 9.2 months (SD: 18.9) after IL or 16.3 months (SD: 19.7) after initial VFSS in the control group. **Table 1** compares key characteristics

between the IL group and control group. The proportion of children with a syndromic diagnosis (12% vs 27%, $P = .38$), history of intraventricular or cerebral hemorrhage (18% vs 13%, $P = .99$), developmental delay diagnosis (35% vs 33%, $P = .99$), and history of ECMO (24% vs 13%, $P = .66$) were no different between IL and control groups. Further, weight at surgery was also no different between groups (3.3 kg [SD: 2.3] vs 3.3 kg [SD: 1.3], $P = .98$). Six children had a syndromic diagnosis, which included two with DiGeorge syndrome, and one each of Trisomy 21, Phelan-McDermid syndrome, 5p partial monosomy syndrome, and Turner syndrome.

When comparing swallowing outcomes, more children in the IL group necessitated modified consistencies preoperatively 82% versus 40% ($P = .03$). The rate of aspiration resolution based on postoperative or interval VFSS was N = 14 (82%) for the IL group and N = 9 (60%) for the control group ($P = .24$). Documented VFSS aspiration resolution cardiac surgery occurred by 9.6 months (SD: 10.0) in the observation group and 47.4 months (SD: 24.1) in the IL group ($P < .001$). The removal of a feeding tube (64% vs 60%, $P = .99$), requirement of consistency thickening modification (35% vs 36%, $P = .99$), and rates of pharyngeal dysphagia severity improvement (82% vs 73%, $P = .68$) were no different between groups.

Discussion

This case-control study explored the relationship between IL for UVCP and aspiration resolution in the pediatric cardiac population. Though previous reports have looked at pediatric vocal cord immobility and dysphagia, this is the first study to focus on cardiac patients with objective swallow data using a control group. While IL is safe,

Table 1. Patient Characteristics and Swallowing Outcomes by IL Group

Characteristic	IL group (N = 17)	Control group (N = 15)	P value
Age at cardiac surgery mo. (SD)	2.7 (4.8)	0.9 (1.7)	.18
Male sex, no. (%)	13 (76)	8 (57)	.44
Weight surgery, kg.	3.3 (2.3)	3.3 (1.3)	.98
Gestational age, wk. (SD)	32.8 (6.9)	36.1 (5.0)	.14
Syndromic, no (%)	2 (12)	4 (27)	.38
Intraventricular hemorrhage, no. (%)	3 (18)	2 (13)	.99
Developmental delay, no. (%)	6 (35)	5 (33)	.99
History of ECMO, no. (%)	4 (24)	2 (13)	.66
Feeding tube, no. (%)	14 (82)	15 (100)	.23
Modified consistencies initially, no. (%)	14 (82)	6 (40)	.03
Initial NPO, no. (%)	3 (18)	7 (47)	.13
Initial tolerate thin liquids, no. (%)	0	0	-
Interval tolerate thin liquids, no. (%)	14 (82)	9 (60)	.24
Feeding tube removed, no. (%)	9 (64)	9 (60)	.99
Modified consistencies subsequently, no. (%)	6 (35)	5 (36)	.99
Improved dysphagia severity, no. (%)	14 (82)	11 (73)	.68

well-tolerated and can offer improvement in swallowing function, the added benefit over observation may be less certain. Specifically, 60% of untreated patients experienced resolution of their dysphagia, compared to 82% of the IL intervention group. This difference was not statistically significant and suggests that observation may be reasonable in some cardiac patients. Additionally, the time to documented resolution of aspiration was significantly longer with our intervention group, 47 months versus 9.6 months and an IL may prolong the confidence in advancing oral intake until these procedures are completed. The failure to demonstrate a statistically significant improvement in outcome following injection laryngoplasty may have been related to the timing of the follow up VFSS, being 9 months after the procedure, at a time when the injected gel would have been resorbed. Future studies may benefit from shorter interval swallow assessments to better characterize the improvement status immediately following IL. Though our intervention of IL aimed to address the protection of the airway, our data does not definitively show a benefit to the resolution of thin liquid aspiration.

In adults, early intervention using IL within 6 months after vocal cord injury can reduce the need for further surgical intervention.¹² However, there is limited data among pediatric patients. Physiologically, the vocal cords contribute to phonation and airway protection. Anatomically, glottic adduction helps create a physical barrier against aspiration. When the ability to adduct is compromised, there is a decreased ability to protect the airway during swallowing. This results in a 2.5-fold increase in aspiration risk among patients with vocal cord immobility.⁹ Studies of children with vocal cord immobility find that as many as 87.5% of patients will develop voice and swallowing dysfunction.^{3,13,14} The dysphagia and aspiration risk can necessitate dietary modification, supplemental enteral feeds, or complete enteral feeds in 68.5% to 80.5% of children.^{3,13} In this series, a nasogastric tube was placed in nearly all patients and dietary modification or NPO status was common. Consequently, this population of children after cardiac surgery will struggle frequently with swallowing that may be challenged by factors beyond just the vocal cords. Offering IL is a reasonable approach to try and mitigate the broader dysphagia challenges, even if the improvement may be modest in some children.

There are several advantages to an IL procedure for children with UVCP. IL augments the immobile cord to reduce the glottic gap and can improve protection of the airway from thin liquids.^{10,14} Objective improvement in swallow function following IL can be found for 63.6% to 89% based on VFSS aspiration rates.^{10,13,15} Additionally, a systematic review of objective and subjective improvement of swallow noted an improvement in 84.5% following IL.¹⁶ Encouragingly, complications rates remain low, reported after 0% to 17% of IL procedures with most characterized as minor; including transient increased oxygen requirement, prolonged operative time, and intraoperative laryngospasm or bronchospasm.^{10,13,15}

Based on the findings shown here, we corroborate that injection laryngoplasty can potentially provide improvement in objective swallowing outcomes. IL has a favorably low rate of complications, though this was a secondary objective. Clinicians can therefore consider this modality when assuming they are of acceptable cardio-pulmonary risk for spontaneous ventilation under general anesthesia.

Prior studies offer a wide range of follow-up times between IL and instrumental swallowing assessments, ranging from days to years.^{10,13–15,17} Ultimately, there has been no clear data on the anticipated time to aspiration recovery for vocal cord injection pediatric patients. This timeline variability can distort improvement percentages, as children may naturally experience a spontaneous improvement in dysphagia and vocal cord function over time without interventions. Multiple studies looking at pediatric UVCP have shown varying rates of spontaneous return of vocal cord function, ranging from 28% to 86.5%.^{3,7,14} Published data on time to vocal cord function recovery, particularly in pediatric cardiac patients, showed resolution in 18.9% by 3 months, 63% by 6 months, 78.4% by 12 months, and 86.5% within 24 months.³ While we did not look specifically at rates of recovery of vocal cord immobility, the use of a control group and the improvements made over time, suggest that observation is a reasonable strategy if IL is not being considered. The added step of an IL may, in fact, prolong the objective measurement of swallowing skills, and delay confidence in advancing oral feeding. This suggests combining instrumental evaluations with clinical assessments so that children obtaining an IL do not need to wait unnecessarily to advance swallowing.

The association between UVCP and dysphagia within the pediatric population requires additional exploration. As noted, a primary goal of IL is to counteract the immobility of the vocal cord by closing the glottic space and preventing thin liquid aspiration. Some studies examining vocal cord immobility resolution assume an improvement in dysphagia, yet dysphagia improvement can occur independently of improvements in vocal cord immobility. One group noted that of all patients with vocal cord immobility on initial assessment, only 68.5% were unable to feed orally. At follow-up only 42.6% had resolution of vocal cord mobility, but only 20.5% were still unable to feed orally.¹⁴ The use of a control group in the findings shown here suggest that improvement in thin liquid aspiration, need for thickened consistencies, or need for enteral feeding may evolve in the pediatric cardiac population with UVCP even without intervention. Additional work will be needed to further identify the optimal candidates for IL for UVCP along with characteristics that would correlate with increased benefit on swallowing skills.

Limitations to this study include the retrospective investigation of a small sample size. This can lead to selection bias since children selected for an IL procedure

were clinician-dependent and not randomized. There was also an inability to determine whether improvement in dysphagia in the observation group is due to better compensatory mechanisms in children over time versus speech therapy assistance. In children for example, a more anterior and superiorly positioned larynx is more protective overall against aspiration.^{18,19} In the intervention group, there was also inconsistent variation in the timing of an IL, which may be a confounding factor on the results. Additionally, while more children in the IL group were cleared for oral intake at the time of the initial VFSS, most of them necessitated thicker consistencies. This difference in oral intake clearance and consistency modification between groups may reflect differences in dysphagia severity that impacted the time to swallowing improvement. In the future, a larger, perhaps multi-center study would be beneficial to collect more patient data over time and evaluate other secondary endpoints. This might further clarify a difference between IL and observation and help identify characteristics associated with swallowing improvement.

Conclusion

Pediatric swallowing is a complex process and UVCP can contribute to feeding challenges after cardiac surgery. While IL can lead to improvement in swallowing based on postoperative VFSS, there are still children who can improve without this intervention. Given the low risk and potential benefits to phonation and aspiration for some patients, utilization of IL should continue to be considered. Providers should recognize that this procedure does not guarantee resolution of dysphagia and it may not expedite the recovery of swallowing dysfunction. With this current data, it may even sometimes be wise to delay intervention in some children who may be at higher risk for general anesthesia. Future studies should continue to explore the utility for IL in managing dysphagia secondary to vocal cord paralysis.

Author Contributions

Derek Sheen, data curation, writing—original draft, review & editing, visualization; **Thomas K. Houser**, data curation, writing—original draft, review & editing, visualization; **Sofia E. Olsson**, data curation, writing—review & editing, visualization; **Helene Dabbous**, data curation, writing—review & editing, visualization; **Yann-Fuu Kou**, data curation, writing—review & editing, visualization; **Romaine F. Johnson**, conceptualization, data curation, writing—review & editing, visualization; **Stephen R. Chorney**, conceptualization, data curation, writing—original draft, review & editing, formal analysis, visualization, and supervision.

Disclosures

Competing interests: None.

Funding source: None.

ORCID iD

Derek Sheen  <http://orcid.org/0009-0007-3463-4895>
 Thomas K. Houser  <http://orcid.org/0000-0001-6199-7084>
 Sofia E. Olsson  <http://orcid.org/0000-0002-4678-9962>
 Helene Dabbous  <http://orcid.org/0000-0002-3971-9405>
 Yann-Fuu Kou  <http://orcid.org/0000-0001-6801-7544>
 Romaine F. Johnson  <http://orcid.org/0000-0002-2322-5347>
 Stephen R. Chorney  <http://orcid.org/0000-0003-1419-6019>

References

1. Wu W, He J, Shao X. Incidence and mortality trend of congenital heart disease at the global, regional, and national level, 1990–2017. *Medicine*. 2020;99(23):e20593. doi:10.1097/md.0000000000020593
2. Alfares FA, Hynes CF, Ansari G, et al. Outcomes of recurrent laryngeal nerve injury following congenital heart surgery: a contemporary experience. *J Saudi Heart Assoc*. 2016;28(1):1-6. doi:10.1016/j.jsha.2015.05.002
3. Barr JM, Bowman K, Deshpande M, et al. Incidence and recovery of vocal fold immobility following pediatric cardiac operations. *World J Pediatr Congenit Heart Surg*. 2021;12(4):535-541. doi:10.1177/21501351211015922
4. Meisner J, Zendejas B, Choi S, et al. Intra-operative recurrent laryngeal nerve monitoring decreases post operative vocal cord dysfunction in complex pediatric esophageal, cardiac, and airway surgery. *Pediatrics*. 2022;149:887.
5. Strychowsky JE, Rukholm G, Gupta MK, Reid D. Unilateral vocal fold paralysis after congenital cardiothoracic surgery: a meta-analysis. *Pediatrics*. 2014;133(6):e1708-e1723. doi:10.1542/peds.2013-3939
6. Hseu A, Choi S. When should you perform injection medialization for pediatric unilateral vocal fold immobility. *Laryngoscope*. 2018;128(6):1259-1260. doi:10.1002/lary.26997
7. Jabbour J, Martin T, Beste D, Robey T. Pediatric vocal fold immobility: natural history and the need for long-term follow-up. *JAMA Otolaryngol Head Neck Surg*. 2014;140(5):428-433. doi:10.1001/jamaoto.2014.81
8. Orzell S, Joseph R, Ongkasuwan J, Bedwell J, Shin J, Raol N. Outcomes of vocal fold motion impairment and dysphagia after pediatric cardiothoracic surgery: a systematic review. *Otolaryngol Head Neck Surg*. 2019;161(5):754-763. doi:10.1177/0194599819858594
9. Leder SB, Suiter DM, Duffey D, Judson BL. Vocal fold immobility and aspiration status: a direct replication study. *Dysphagia*. 2011;27(2):265-270. doi:10.1007/s00455-011-9362-0
10. Meister KD, Johnson A, Sidell DR. Injection laryngoplasty for children with unilateral vocal fold paralysis: procedural limitations and swallow outcomes. *Otolaryngol Head Neck Surg*. 2019;160(3):540-545. doi:10.1177/0194599818813002
11. Von Elm E, Altman DG, Egger M, Pocock SJ, Gøtzsche PC, Vandenbroucke JP. The Strengthening of Reporting of Observational Studies in Epidemiology (STROBE) statement: guidelines for reporting observational studies. *PLoS Med*. 2007;4(10):e296.
12. Coulter M, Marvin K, Brigger M, Johnson CM. Dysphagia outcomes following surgical management of unilateral vocal

- fold immobility: a systematic review and meta-analysis. *Otolaryngol Head Neck Surg.* 2022;168(1):14-25. doi:10.1177/01945998211072832
13. Bertelsen C, Jacobson L, Osterbauer B, Hochstim C. Safety and efficacy of early injection laryngoplasty in pediatric patients. *Laryngoscope.* 2018;129(7):1699-1705. doi:10.1002/lary.27436
 14. Tibbetts KM, Wu D, Hsu JV, Burton WB, Nassar M, Tan M. Etiology and long-term functional swallow outcomes in pediatric unilateral vocal fold immobility. *Int J Pediatr Otorhinolaryngol.* 2016;88:179-183. doi:10.1016/j.ijporl.2016.07.008
 15. Ayoub N, Balakrishnan K, Meister K, et al. Safety and effectiveness of vocal fold injection laryngoplasty in infants less than one year of age. *Int J Pediatr Otorhinolaryngol.* 2023;168:111542. doi:10.1016/j.ijporl.2023.111542
 16. Aires MM, Marinho CB, & Vasconcelos SJ. Surgical interventions for pediatric unilateral vocal fold paralysis: a systematic review and meta-analysis. *Int J Pediatr Otorhinolaryngol.* 2021;141:110553. doi:10.1016/j.ijporl.2020.110553
 17. Kang MG, Seo HG, Chung EJ, et al. Effects of percutaneous injection laryngoplasty on voice and swallowing problems in cancer-related unilateral vocal cord paralysis. *Laryngoscope Investig Otolaryngol.* 2021;6(4):800-806. doi:10.1002/lio2.618
 18. Zuniga S, Ebersole B, Jamal N. Improved swallow outcomes after injection laryngoplasty in unilateral vocal fold immobility. *Ear Nose Throat J.* 2018;97(8):250-256. doi:10.1177/014556131809700822
 19. Friedman AD, Burns JA, Heaton JT, Zeitels SM. Early versus late injection medialization for unilateral vocal cord paralysis. *Laryngoscope.* 2010;120(10):2042-2046. doi:10.1002/lary.21097