

## Running-down phenomenon captured with chronic electrocorticography

\*Aaron S. Geller , \*Daniel Friedman , †May Fang, ‡Werner K. Doyle, \*Orrin Devinsky, and \*Patricia Dugan

*Epilepsia Open*, 3(4):528–534, 2018  
doi: 10.1002/epi4.12265

### SUMMARY

The running-down phenomenon refers to 2 analogous but distinct entities that may be seen after epilepsy surgery. The first is clinical, and denotes a progressive diminution in seizures after epilepsy surgery in which the epileptogenic zone could not be completely removed (Modern Problems of Psychopharmacology 1970;4:306, Brain 1996:989). The second is electrographic, and refers to a progressive deactivation of a secondary seizure focus after removal of the primary epileptogenic zone. This progressive decrease in epileptiform activity may represent a reversal of secondary epileptogenesis, where a primary epileptogenic zone is postulated to activate epileptiform discharges at a second site and may become independent.<sup>3</sup> The electrographic running-down phenomenon has been reported in only limited numbers of patients, using serial postoperative routine scalp electroencephalography (EEG) (Arch Neurol 1985;42:318). We present what is, to our knowledge, the most detailed demonstration of the electrographic running-down phenomenon in humans, made possible by chronic electrocorticography (ECoG). Our patient's left temporal seizure focus overlapped with language areas, limiting the resection to a portion of the epileptogenic zone, followed by implantation of a direct brain-responsive neurostimulator (RNS System, NeuroPace Inc.) to treat residual epileptogenic tissue. Despite the limited extent of the resection, the patient remains seizure-free more than 2 years after surgery, with the RNS System recording ECoG without delivering stimulation. We reviewed the chronic recordings with automated spike detection and inspection of electrographic episodes marked by the neurostimulator. These recordings demonstrate progressive diminution in spiking and rhythmic discharges, consistent with an electrographic running-down phenomenon.

**KEY WORDS:** Running-down phenomenon, Electrocorticography, Responsive neurostimulation.



Aaron S. Geller is an epileptologist with the Northeast Regional Epilepsy Group, in New Jersey.

Accepted August 19, 2018.

\*Department of Neurology, NYU School of Medicine, New York, New York, U.S.A.; †NeuroPace, Inc, Mountain View, California, U.S.A.; and ‡Department of Neurosurgery, NYU School of Medicine, New York, New York, U.S.A.

Address correspondence to Aaron S. Geller, Department of Neurology, NYU School of Medicine, 223 E 34th St., New York, New York, U.S.A. E-mail: ageller@epilepsygroup.com

© 2018 The Authors. *Epilepsia Open* published by Wiley Periodicals Inc. on behalf of International League Against Epilepsy.

This is an open access article under the terms of the Creative Commons Attribution-NonCommercial-NoDerivs License, which permits use and distribution in any medium, provided the original work is properly cited, the use is non-commercial and no modifications or adaptations are made.

### CASE REPORT

In February 2014, we evaluated this 18-year-old right-handed man for surgical treatment of drug-resistant epilepsy. He had focal seizures with impaired awareness, characterized clinically by a vague “pleasant” feeling associated with a feeling of “familiarity” and a need to “figure something out.” He sometimes verbalized feelings of an impending seizure. These sensations were followed by staring, unresponsiveness, and occasionally, cyanosis. He would have postictal fatigue and confusion. He experienced auras approximately daily and full seizures 1–2 times per week.

His seizures were refractory to levetiracetam XR, 2,000 mg twice daily, lamotrigine XR, 200 mg twice daily, and lacosamide, 100 mg twice daily.

Video–electroencephalography (VEEG) monitoring demonstrated seizure onsets over the left frontotemporal region. A 3 Tesla magnetic resonance imaging (MRI) study did not reveal a structural abnormality, including encephalocele. Magnetoencephalography demonstrated left frontal (precentral) and lateral temporal sharp waves and slowing, and bilateral temporal activation with language tasks. Positron emission tomography demonstrated left temporal hypometabolism. The intra-arterial amobarbital (Wada) test demonstrated left hemispheric language dominance, with intact memory bilaterally.

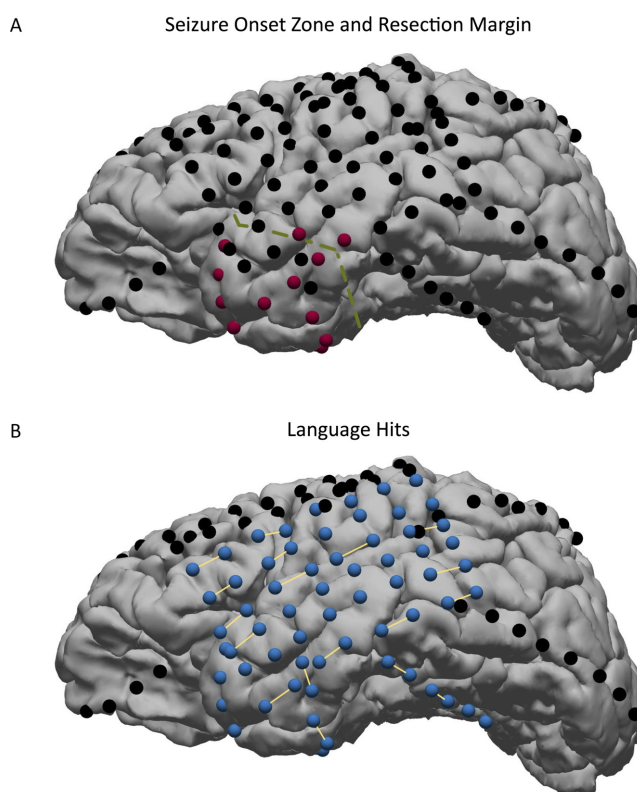
An intracranial EEG (IEEG) study was performed to localize the epileptogenic zone and map eloquent cortex. A left perisylvian grid, 2 depth electrodes inserted through the temporal lobe into the mesial temporal structures, and 8 subdural strip electrodes were implanted. Three of the subdural strips were placed on the left temporal neocortex, 3 were placed on the left frontal lobe, and one each was placed on the left parietal and occipital lobes. Typical seizures were captured, with onsets in the anterior and basal left temporal neocortex, with spread to the left hippocampal depth electrodes within 4–10 s (Fig. 1A). Cortical stimulation mapping showed significant overlap between the seizure-onset zone and language areas (Fig. 1B).

A limited resection of the anterior-inferior left temporal lobe was performed, and histopathologic evaluation demonstrated focal cortical dysplasia, type 2A. This was followed by implantation of electrodes for the RNS System with a depth electrode along the long axis of the hippocampus, and strip electrodes over the mesial, basal, and lateral aspects of the left temporal neocortex. After reviewing intraoperative electrocorticography (ECoG) from all electrodes, the hippocampal depth electrode (see H, Fig. 2) and mesial temporal strip (see MT, Fig. 2) were connected to the neurostimulator.

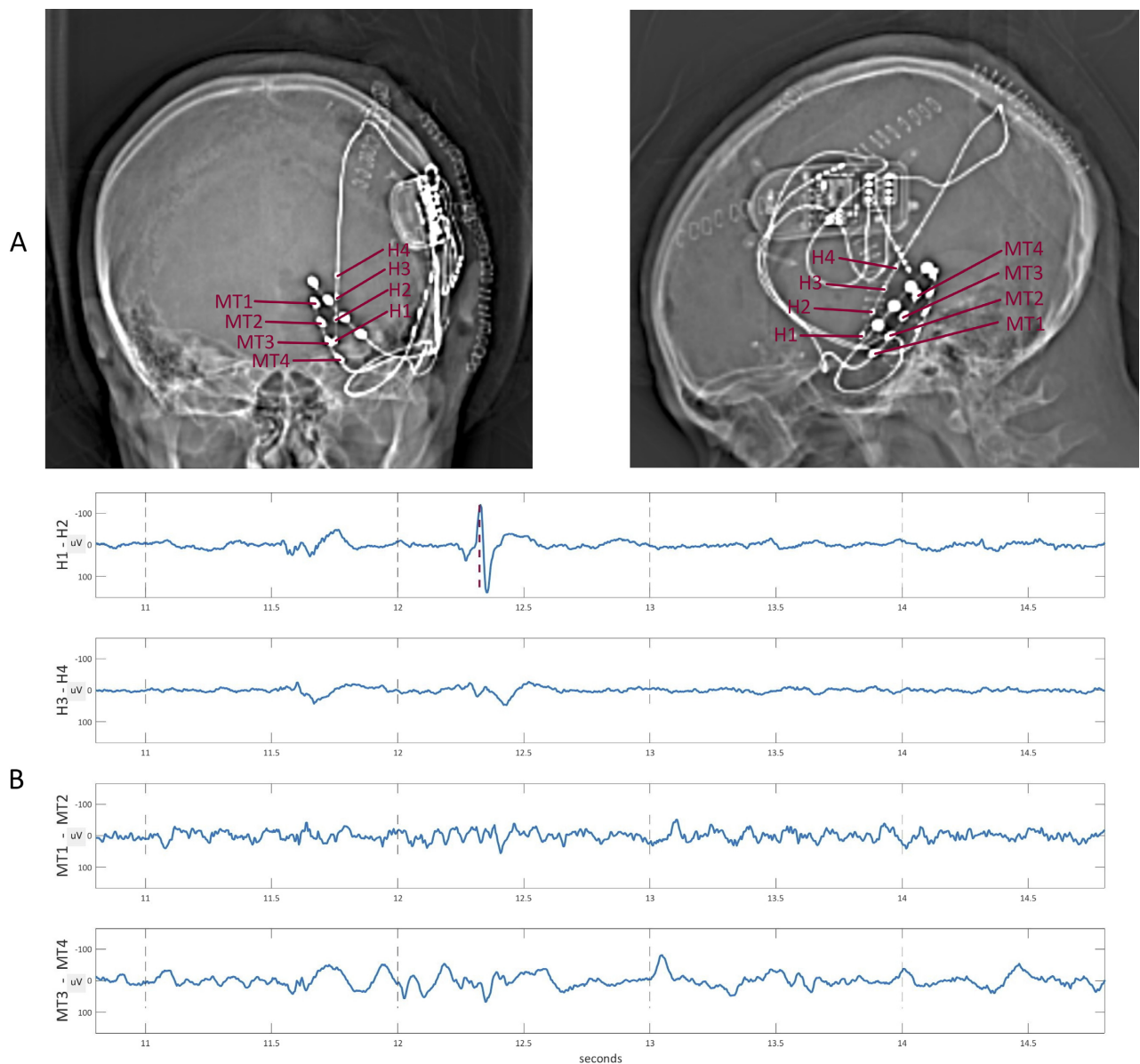
Although resection of the seizure focus was limited by eloquent cortex, it rendered the patient seizure-free as of his last visit, over 2 years since surgery. During this period, levetiracetam dose was decreased at 4 months postoperatively to 1,500 mg twice daily by the patient, and again at 13 months to 1,000 mg twice daily. Lacosamide was discontinued at 18 months. No language deficits were seen in the immediate postoperative period or thereafter. Cognition has been stable or improved since his operation (with reported improvement in academic performance), although a formal postoperative neuropsychiatric evaluation has not been performed.

A long-term electrophysiologic record was obtained postoperatively, as the patient diligently interrogated his device. The data show a progressive decrease in epileptiform activity, the interictal analog of the running-down phenomenon. Notably, the RNS System, unlike inpatient IIEEG, does not

provide a continuous record of a patient's EEG. The neurostimulator has a limited internal memory, which, as typically configured, can store a total of 6 min of ECoG for 4 bipolar channels. Because of this, ECoG storage occurs only when one of 3 criteria are met: (1) ongoing ECoG activity meets criteria for epileptiform morphology and duration specified by the clinical team; (2) the patient or clinician triggers storage by swiping a magnet over the neurostimulator; or (3) storage is scheduled at specific times of day for random sampling of the ECoG. Our data are all of this third type. If the patient does not interrogate his or her device and transmit the currently stored data to the NeuroPace servers (uploading), then new events which satisfy the above



**Figure 1.** Inferolateral views of the patient's left-hemispheric IIEEG study, with electrode positions as demonstrated on postimplantation CT co-registered to preoperative MRI.<sup>13</sup> (A) Electrodes at which seizure onsets occurred are colored red, and the dashed olive green line indicates the resection margin; the resection was limited posteriorly by broad language hits (see panel B). Because suspected residual epileptogenic tissue remained posterior to the resection, an RNS System was implanted (see Fig. 2). Depth electrodes (targeting the mesial temporal lobe) are not shown, but did not capture any seizure onsets. (B) Language results of bedside cortical stimulation mapping. Contacts at which stimulation was delivered are colored blue. Bipolar pairs at which stimulation caused language disruption (i.e., disrupted recitation of rehearsed text, sentence completion, or visual naming) are indicated by a yellow bar. *Epilepsia Open* © ILAE



**Figure 2.**

(A) Postimplantation CT of the head demonstrating the locations of the implanted electrodes and RNS System. One depth electrode and 3 subdural strip electrodes were implanted. After intraoperative recording from each implanted electrode, electrodes H (a depth electrode through the long axis of the hippocampus) and MT (a strip electrode along the mesial temporal lobe) were selected for connection to the neurostimulator. (B) Sample ECoG traces with detected spike (dashed red line) from day 5 postimplantation.

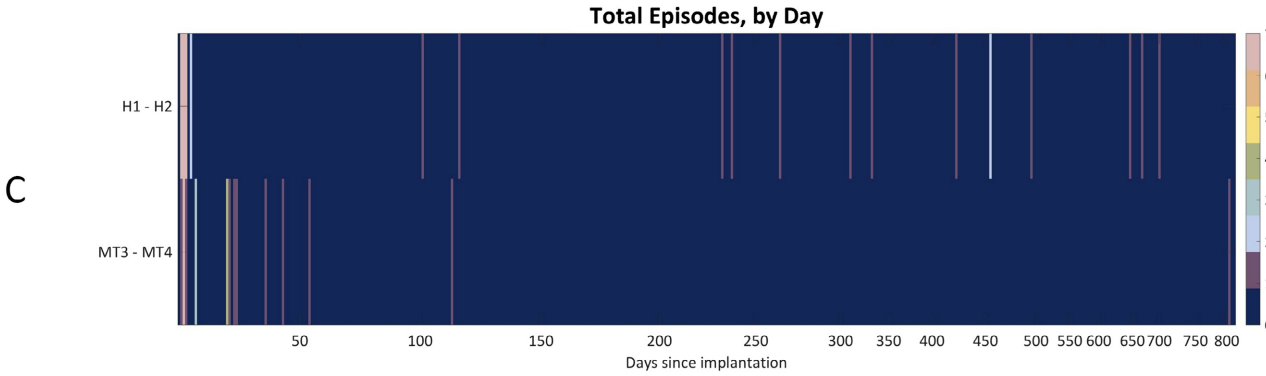
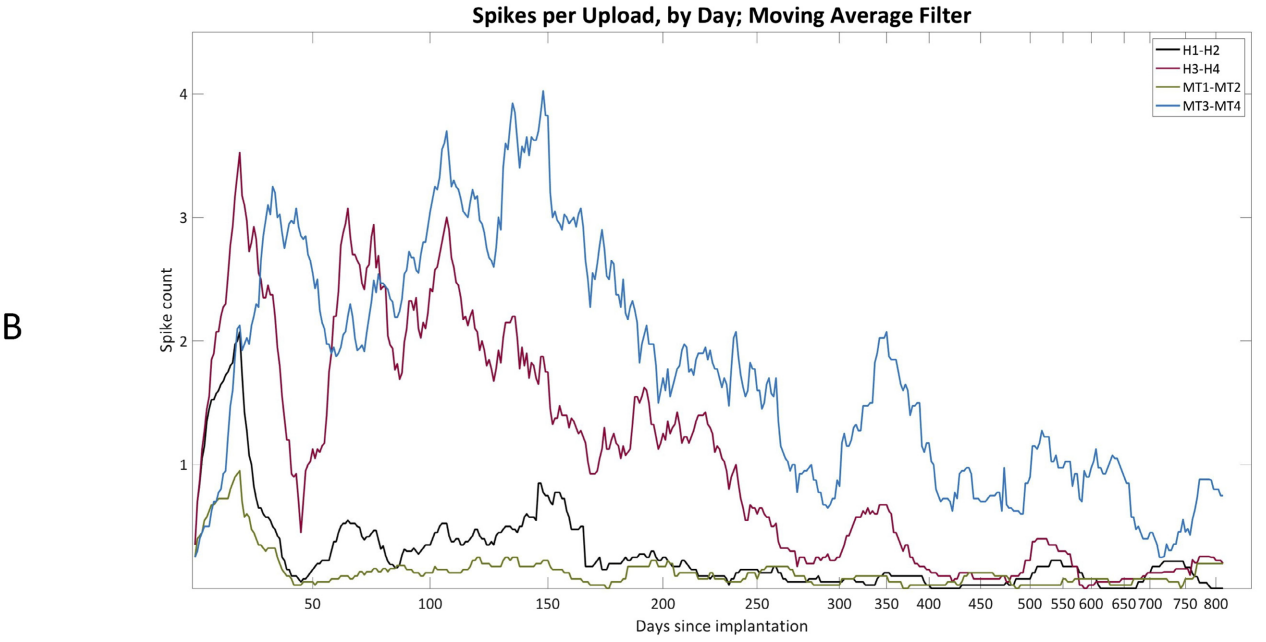
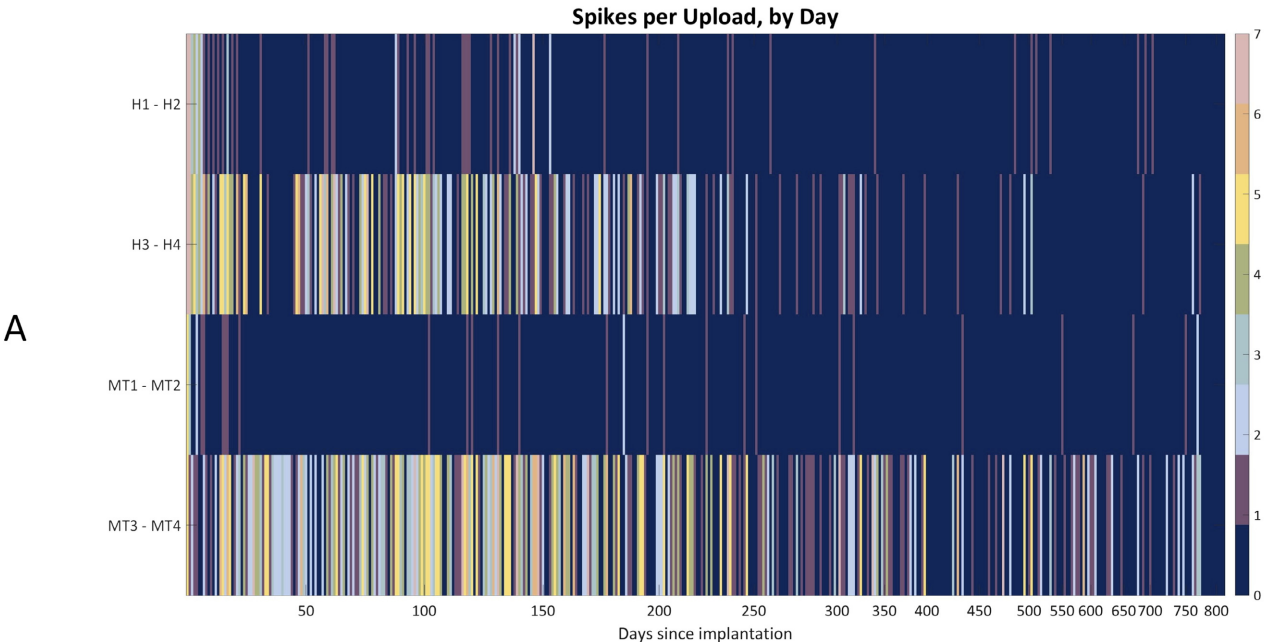
*Epilepsia Open* © ILAE

**Figure 3.**

(A) Spikes per upload, by day, for each of the 4 recording channels, in the scheduled 90 s ECoG readings uploaded by the patient; the shortening intervals on the X-axis reflect decreasing frequency of uploads by the patient, which occurred at least daily for approximately the first 200 days after implantation. For days with multiple uploads that day's mean count is shown. (B) Spikes per upload, after transformation of the counts in (A) with a moving average filter. (C) Episodes (intervals in which the line-length measure significantly increased from baseline) captured by the neurostimulator, for the 2 channels designated for continuous automated ECoG processing, as a function of time.

*Epilepsia Open* © ILAE

Running-down Phenomenon on ECoG



criteria will start to overwrite the previously stored data, which will be lost. For our patient, ECoG studies were scheduled for storage daily at 02:00 and 14:00.

The RNS System provides 2 methods for assessing interictal activity. The first is direct review of the uploaded ECoG segments and quantification of interictal epileptiform discharges. Figure 2B shows a sample brief ECoG epoch with spikes marked by a spike-detecting algorithm.<sup>1</sup> Figure 3A–B shows the mean number of spikes detected by the algorithm in each 90 s ECoG epoch uploaded by the patient for each postoperative day. There is frequent spiking in the immediate postoperative period in channels H1–H2 and H3–H4, followed by a fairly rapid decline in spiking in H1–H2, and a more gradual decline in H3–H4. Epileptiform activity in this region, it should be noted, was seen in the IEEG study. The bottom channel, MT3–MT4, which was not as active in the immediate postoperative period, nonetheless demonstrates the greatest spiking in the first 100 days, with progressive decrease thereafter.

The second RNS tool for evaluating interictal activity is tallying of periods of possible seizure onsets, or “episodes” (see criterion 1, above). The RNS System typically uses running line-length calculation as a marker for incipient seizures.<sup>2</sup> The line length measure for the most recent 4 s of ECoG is compared to that of the prior 2 min, and if it exceeds the baseline by a specified threshold, that segment is taken as the onset of an episode. Episodes that exceed a specified duration (termed “long episodes” and for this patient defined as 30 s or longer) can trigger stimulation if this is enabled for the patient; no long episodes were captured. Because he has been seizure-free since resection, stimulation was never enabled, but his neurostimulator continues to count episodes. Figure 3C shows that his electrographic events have occurred only on channels H1–H2 and MT3–MT4. On H1–H2, episodes were relatively frequent in the immediate postoperative period, with a rapid subsequent drop-off, and subsequent low-frequency re-emergence after day 100. On MT3–MT4, episodes occurred with decreasing frequency during the first 100 postoperative days, and then none between days 112 and 797, when there was a single episode detected. Because suspicion for subclinical seizures was low, the default line-length detector described above has not been modified.

## DISCUSSION

The running-down phenomenon is of interest because it illuminates a compelling issue in epilepsy pathophysiology: the process by which a focal epileptogenic lesion spreads. This process, called secondary epileptogenesis, has been studied extensively in the laboratory,<sup>3–5</sup> and in human clinical situations.<sup>3,6</sup>

In his definitive review of secondary epileptogenesis, Morrell<sup>3</sup> showed that the spread of epileptogenicity can be

progressive, and the nature of this progression depends on the age of the primary epileptogenic lesion. The longer the lesion has been present, the more likely and better established remote epileptogenic disturbances become. After time, resection of the primary epileptogenic lesion may not immediately abolish the activity at the secondary sites, and a running down of their epileptogenic activity is seen. If the primary lesion becomes chronic, however, the secondary sites become independent, and will persist in their epileptiform activity indefinitely, even after resection of the primary site. In our case, a primary epileptogenic lesion (a focal cortical dysplasia) is believed to have induced epileptiform activity in relatively distant temporal neocortex. Removal of the primary lesion triggered subsequent progressive deactivation of the epileptiform activity in the areas of spread.

The running-down phenomena may either be clinical, referring to decreasing seizure frequency, or electrographic, referring to decreasing interictal discharge frequency. Morrell’s review includes 2 cases of electrographic running down in humans, in the form of follow-up scalp EEG studies done on patients with a secondary epileptogenic focus. In the first case, spikes at the secondary focus were present at 10 days postresection but absent at 6 months. In the second case, spikes at the secondary focus were present at 1- and 2-year follow-up, but absent at years 3 and thereafter. Our intracranial data provide a more direct, detailed, and quantitative view of an electrographic running-down phenomenon.

Of note, Morrell’s studies all pertain to “mirror foci,” secondary epileptogenic regions arising contralateral to a preexisting primary focus. Mirror foci are presumed to arise from commissural communication of epileptogenic discharges to homotopic contralateral cortical areas. The lesion in our case is ipsilateral to, in fact neighboring, the territory displaying the running-down phenomenon, and therefore the pertinent secondary epileptogenesis would likewise have been via local spread, and not commissural. Evidence for this kind of secondary epileptogenesis comes from reports demonstrating the clinical running-down phenomenon after incomplete resections.<sup>7,8</sup>

A recent study<sup>9</sup> examined long-range trends in the ECoG of patients implanted chronically with the recording-only NeuroVista device. Several physiologic measures of interest, such as power at various frequency bands, line length were calculated. Despite much intersubject variability, the overall trend across subjects was a large drop in power (or line length) followed by stabilization. These effects were felt to reflect histologic changes at the brain–electrode interface, which may degrade the ECoG over time. Their findings raise a question regarding the results we are reporting, namely, is the running-down effect seen here simply an artifact of the deterioration of the ECoG due to similar changes at the brain–electrode interface? We believe that the answer is no.

First, the impedances recorded by the RNS System were stable during the period analyzed in this report. For electrode MT, there was an initial rise during the first 3 months from approximately 500 to approximately 1,000 k $\Omega$ . During the subsequent 24 months, impedances remained within an envelope of  $900 \pm 300$  k $\Omega$ . Impedances for electrode H have been flat for the duration analyzed in this study and contained within the envelope  $400 \pm 300$  k $\Omega$ . Second, the running-down effect shown by our patient is fairly gradual and persists over the course of the 2 years. The drop in the signal features in the NeuroVista data, by contrast, is complete within 100–200 days, after which the measures stabilize. Third, it is implausible that a decrease in spike rate, based on a discrete all-or-none event, would be the result of histologic change at the brain–electrode interface, without significant decrease in signal-to-noise in the relevant channel. No such loss was found.

Similar concerns may be raised about the possible confounding factor of the “implant effect” of the RNS System. This refers to a set of phenomena, including seizure reduction, which occur in the first weeks and months following implantation, prior to enabling neurostimulation. A review of a large set of RNS System ECoG results<sup>10</sup> reported significant fluctuation in spike counts, particularly for strip electrodes; however, the overall trend seen was of increased spiking, which was sustained in the case of strip electrodes, but which leveled off in the case of depth electrodes. The data presented here would therefore not be typical of the overall trend reported in this review, both in the direction of change (decreased spiking instead of increase), and the sustained duration of this change over 2 years. A case of prolonged seizure freedom, apparently from implantation of the RNS System alone, has also been reported,<sup>11</sup> but the authors do not describe the associated spike-rate trend; direct comparison with our case is therefore difficult.

Another group of concerns pertains to the limitations of the RNS System in recording ECoG, and its dependence for seizure detections on user-provided criteria. First, as mentioned earlier, the system typically captures only several minutes of ECoG per day. In principle, limited sampling is susceptible to significant selection bias, particularly given the known circadian fluctuations in epileptiform activity.<sup>12</sup>

Regarding this concern, although we acknowledge that the EEG reviewed is clearly a limited sample, our concerns for circadian sampling bias are low, particularly as the sampled ECoG recordings were scheduled for both sleep (at 02:00) and wakefulness (at 14:00). Second, one may be concerned that the patient’s RNS System may have missed epileptiform activity due to insufficiently sensitive settings. As mentioned earlier, because of low suspicion for subclinical seizure activity, the criteria for marking an epileptiform “episode” were not changed to try to increase the device’s sensitivity. On the one hand, we concede that it is impossible to exclude definitively that electrographic seizures may have occurred that the device was not set to capture. On the

other, however, we contend that this is unlikely because of the following: (1) the absence of subclinical seizures on prior studies, including the patient’s inpatient IEEG; and (2) the patient’s clinical course, which has demonstrated (in addition to freedom from clinical seizures) stable to improved cognitive function and improved academic performance.

We acknowledge that channel H1–H2 in Figure 3C indicates a re-emergence of epileptiform activity after day 100, and particularly after day 200. Because these episodes did not trigger ECoG storage, it is impossible to characterize these events definitively. Although presumably they reflect genuine epileptiform activity (it appears they correlate with spiking activity in the same channel in Fig. 3A), we do not believe that this is generally incompatible with a long-trend running-down phenomenon; the latter requires epileptiform potential to occur in the first place.

The territory implicated in language function, illustrated by Figure 1B, is abnormally broad. One may speculate that this is a result of the patient’s disease process, specifically, that chronic epileptiform activity in the left temporal neocortex triggered reorganization and abnormal expansion of indigenous physiologic functional networks, such as that subserving language.

In conclusion, this case illustrates a phenomenon hypothesized to occur frequently in cases of successful resective epilepsy surgery, but which has never before been demonstrated with comparable detail in a human.

## DISCLOSURE

None of the authors have any conflicts of interest to disclose. We confirm that we have read the Journal’s position on issues involved in ethical publication and affirm that this report is consistent with those guidelines.

## REFERENCES

1. Brown MW, Porter BE, Dlugos DJ, et al. Comparison of novel computer detectors and human performance for spike detection in intracranial EEG. *Clin Neurophysiol* 2007;118:1744–1752.
2. Esteller R, Echazu J, Tchong T, et al. Line length: an efficient feature for seizure onset detection. *Conf Proc IEEE Eng Med Biol Soc* 2001;2:1707–1710.
3. Morrell F. Secondary Epileptogenesis in Man. *Arch Neurol* 1985;42:318–335.
4. Morrell F. Secondary epileptogenic lesions. *Epilepsia* 1959;1:538–560.
5. McNamara JO, Constant Byrne M, Dasheiff RM, et al. The kindling model of epilepsy: a review. *Prog Neurobiol* 1980;15:139–159.
6. Morrell F, Wada JA, Engel JJ. Potential relevance of kindling and secondary epileptogenesis to the consideration of surgical treatment for epilepsy. In Engel JJ (Ed) *Surgical treatment of the epilepsies*. Chap. Appendix I. 1987:701–707.
7. Rasmussen T. The neurosurgical treatment of focal epilepsy. In Niedermeyer E (Ed) *Epilepsy. Modern Problems of Psychopharmacology*. Vol. 4. 1970:306–325.
8. Salanova V, Andermann F, Rasmussen T, et al. The running down phenomenon in temporal lobe epilepsy. *Brain* 1996;119:989–996.
9. Ung H, Baldassano SN, Bink H, et al. Intracranial EEG fluctuates over months after implanting electrodes in human brain. *J Neural Eng* 2017;14:056011.

10. Sun FT, Arcot Desai S, Tchong TK, et al. Changes in the electrocorticogram after implantation of intracranial electrodes in humans: the implant effect. *Clin Neurophysiol* 2018;129:676–686.
11. Rao VR, Leonard MK, Kleen JK, et al. Chronic ambulatory electrocorticography from human speech cortex. *NeuroImage* 2017;153:273–282.
12. Baud MO, Kleen JK, Mirro EA, et al. Multi-day rhythms modulate seizure risk in epilepsy. *Nat Commun* 2018;9:88.
13. Groppe DM, Bickel S, Dykstra AR, et al. iELVis: an open source MATLAB toolbox for localizing and visualizing human intracranial electrode data. *J Neurosci Methods* 2017;281:40–48.