

Single-Portal, Single-Anchor Repair of a Superior Third Subscapularis Tear Using a Self-Punching Knotless Soft Suture Anchor



Shane Rayos Del Sol, M.S., Alvarho Guzman, B.A., Sophia Sarang Shin Yin, B.A.,
Brandon Gardner, M.D., Ph.D., Stewart Bryant, M.D., Moyukh O. Chakrabarti, M.B.B.S.,
Patrick J. McGahan, MD, and James L. Chen, M.D., M.P.H.

Abstract: Numerous techniques exist for arthroscopic subscapularis repair with varying degrees of complexity based on tear morphology, all of which have established satisfactory outcomes in function and patient satisfaction. Arthroscopic subscapularis repair can require several working portals and suture anchors, increasing both technical complexity and operative time. This Technical Note describes an arthroscopic repair of a superior one-third subscapularis tear using a self-punching knotless soft suture anchor through a single anterior working portal. Thus, we offer a unique approach to arthroscopic repair of superior one-third subscapularis tears that is time-saving, reproducible, and highly efficient while minimizing iatrogenic damage and postoperative complications.

Introduction

The subscapularis is the largest muscle of the rotator cuff and facilitates internal rotation and stabilizes the shoulder anteriorly.¹ Isolated subscapularis tears are frequently caused by anterior forces against an externally rotated glenohumeral joint and anterior glenohumeral dislocations.²⁻⁴ Partial and complete subscapularis tendon ruptures have been reported as acute, traumatic incidents in sports, such as water skiing, arm wrestling, and baseball that involve forceful hyperextension, adduction, and external rotation.⁵ In contrast, chronic and degenerative tears are caused by subcoracoid impingement or subluxation of the long head of the biceps tendon.⁶⁻⁸

The prevalence of subscapularis tears requiring repair is substantial, comprising nearly one-third of arthroscopic rotator cuff repairs.^{9,10} Numerous studies have demonstrated good to excellent clinical results after an arthroscopic repair and, therefore, recommend repair of partial or full-thickness subscapularis tears in shoulders that have failed conservative treatment.¹¹⁻²⁴ The Lafosse classification grading system, which classifies subscapularis tear morphology, is a useful tool to help guide overall treatment for the patient (Table 1).^{15,25} Since the advent and advancement of arthroscopic techniques, many techniques have recently evolved for arthroscopic subscapularis repair.^{18,26-32} To our knowledge, in regard to arthroscopic repair of Lafosse type II/superior third subscapularis tears, there exists no published literature highlighting the efficacy of using a single, knotless soft suture anchor solely through an anterior working portal. The purpose of this Technical Note and video (Video 1) is to present an arthroscopic repair of a full-thickness superior third subscapularis tear using a knotless, soft anchor through a single anterior portal. This technique is reproducible, time efficient, and uses fewer surgical tools compared to surgical techniques using traditional suture anchors.

Surgical Technique

A demonstration of the repair of a partially torn subscapularis with a knotless suture anchor is available

From *Advanced Orthopaedics and Sports Medicine, San Francisco, California, U.S.A.*

The authors report the following potential conflicts of interest or sources of funding: J.L.C. is an educational consultant for Arthrex and receives compensation for medical educational lectures and instruction only. Full ICMJE author disclosure forms are available for this article online, as supplementary material.

Received April 21, 2021; accepted May 14, 2021.

Address correspondence to Shane Rayos Del Sol, *Advanced Orthopaedics and Sports Medicine, 450 Sutter St., Ste. 400, San Francisco, CA 94108, U.S.A.* E-mail: rayosdsm@mail.uc.edu

© 2021 THE AUTHORS. Published by Elsevier Inc. on behalf of the Arthroscopy Association of North America. This is an open access article under the CC BY-NC-ND license (<http://creativecommons.org/licenses/by-nc-nd/4.0/>).
2212-6287/21593

<https://doi.org/10.1016/j.eats.2021.05.003>

Table 1. Laffosse Classification Grading System of Subscapularis Tears

Type	Morphology
I	Partial tear of the superior third
II	Complete tear of superior third
III	Complete tear of superior two-thirds
IV	Complete tear, head concentric, fatty degeneration 1-3
V	Complete tear, head eccentric, fatty degeneration >3

in [Video 1](#). Important pearls and pitfalls are provided in [Table 2](#).

Preoperative Assessment

Preoperative assessment to evaluate for subscapularis pathology consists of a detailed history, comprehensive physical examination, and corresponding imaging studies. Physical examination is pertinent to evaluate for subscapularis integrity. The patient will demonstrate pain and difficulty with the bear hug, lift-off, and belly press tests.³³ Plain radiographs may be obtained to evaluate for acute trauma and develop a differential diagnosis. Ultrasound and magnetic resonance imaging are helpful to confirm a diagnosis prior to surgical intervention.

Patient Positioning and Preparation

Once the patient is administered general anesthesia, the patient is placed in the lateral decubitus position with a lateral wedge, and all bony prominences are well padded. The arm is prepped and draped in the usual sterile fashion prior to placing it in an Arthrex arm holder (Arthrex, Naples, FL), with 10 pounds of weight for traction.

Arthroscopic Portal Placement and Diagnostic Arthroscopy

Landmarks of the shoulder are identified and marked. A #11 blade is used to establish a standard posterior portal 1-2 cm inferior and medial to the posterolateral corner of the acromion. A blunt trocar and scope sheath are used to enter the glenohumeral space, creating a standard posterior portal. A standard

glenohumeral diagnostic arthroscopy is conducted at this time with a 30° 4.0-mm arthroscope, and an isolated upper-border subscapularis tendon tear is identified ([Fig 1](#)). With direct arthroscopic visualization, an anteromedial portal is needle-localized through the rotator cuff interval using an 18-gauge spinal needle. The anterior portal is created with a #11 blade, dilated with a trocar, and an 8.25-mm cannula is placed (Arthrex, Naples, FL).

Subscapularis Repair

Viewing from the posterior portal, the lesser tuberosity of the humerus is identified and debrided with a shaver in order to prepare the footprint of the subscapularis tendon. The subscapularis tendon fibers are debrided with a shaver, and a knotless 2.6-mm self-punching soft anchor (Arthrex Fibertak, Naples FL) is introduced through the anterior cannula. The tip of the anchor is used to pierce through the tendon of the subscapularis ~1 cm proximal from the edge of the tear ([Fig 2](#)). With the arm held in internal rotation, the anchor is then brought up superiorly onto the lesser tuberosity, approximating the tendon's natural insertion. Once an adequate length-tension relationship is established, the anchor is malleted down to its laser line. The #5 blue FiberWire repair suture is pulled to deploy the self-bunching mechanism of the anchor ([Fig 3](#)). At this point, three suture ends (the blue repair suture, and the two ends of a black and white FiberLink (Arthrex, FL) shuttle suture) are present. The blue repair suture is retrieved from the humeral side of the subscapularis muscle, which pulls it out of the tendon. The blue suture is then looped around the superior border of the subscapularis tendon, and out the anterior portal ([Fig 4](#)). The blue repair suture is then loaded on the looped end of the shuttle suture with enough length to ensure safe delivery through the anchor. The white and black shuttle suture is then pulled to deliver the blue repair suture through the subscapularis tendon and anchor ([Fig 5](#)). Appropriate tension is placed on the blue suture to secure the tendon to bone. Finally, excess

Table 2. Pearls and Pitfalls

Pearls	Pitfalls
Bluntly pierce the subscapularis at least 1 cm proximal to the free tendon edge, allowing for a secure anchor point with thick borders.	Avoid piercing surrounding structures when entering the subscapularis with the FiberTak anchor by using a two-handed technique and having adequate visualization.
Adequately apply tension to the subscapularis prior to anchor placement at the lesser tuberosity to maintain length-tension dynamics.	Proper subscapularis tensioning may require a second assistant to place the arm into internal or external rotation, and the assistant should be available to hold this position steady during anchorage.
Debride subscapularis tendon to maintain visualization during the repair.	Test the repair through gentle external rotation and anterior translation to avoid risk of slippage due to redundant tissue folding underneath the repair.
Feed an adequate amount of the blue suture repair stitch into the looped end of the black FiberLink shuttle suture to provide enough suture to anchor while tensioning.	

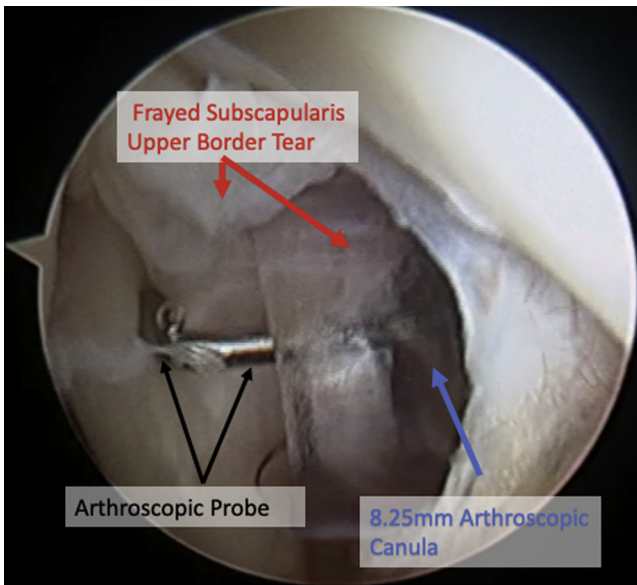


Fig 1. Patient is positioned in the right lateral decubitus position. Diagnostic arthroscopy of the left shoulder is performed through the posterior portal with a 30° arthroscope that confirms a Lafosse type II/superior third subscapularis tendon tear at the superior attachment.

suture is cut to complete the knotless subscapularis repair (Fig 6).

Final Examination and Postoperative Care

The repair is inspected and ranged through gentle external rotation and posterior translation of the

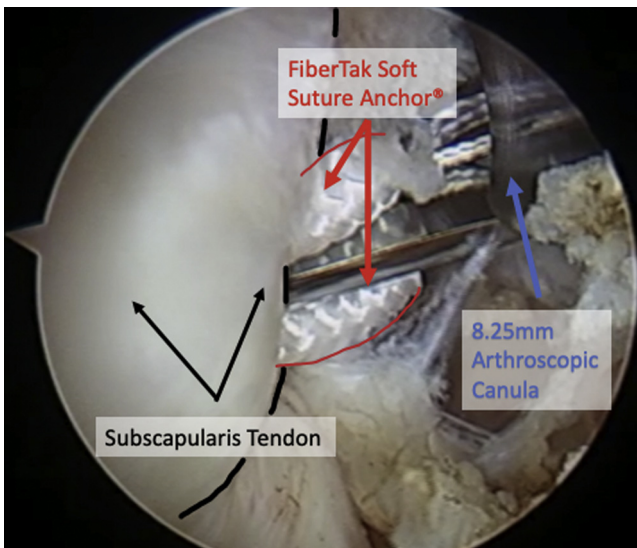


Fig 2. Patient is positioned in the right lateral decubitus position. Arthroscopic image of the left shoulder depicts the FiberTak anchor placement through the subscapularis tendon. Viewed from the posterior portal with a 30° arthroscope, a knotless 2.6-mm soft suture anchor is positioned 1 cm proximal to the edge of the subscapularis tendon tear with the shoulder internally rotated.

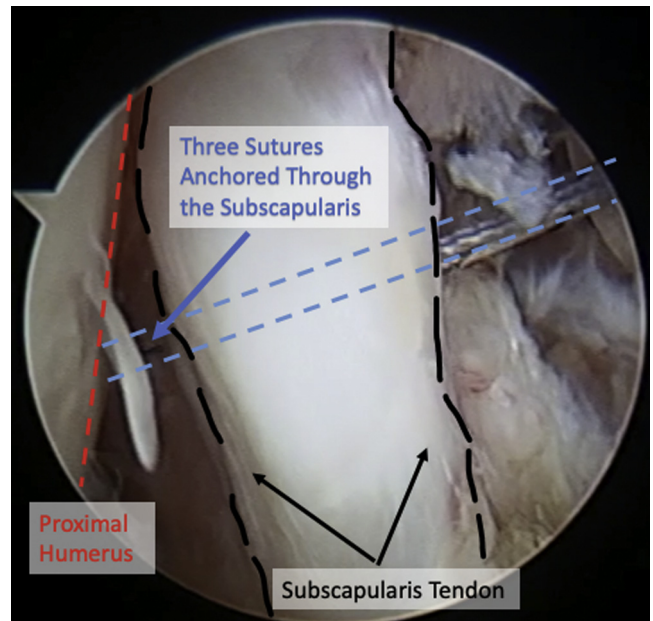


Fig 3. Patient is positioned in the right lateral decubitus position. Arthroscopic image shows the left shoulder through the posterior portal with a 30° arthroscope depicting stable fixation of a knotless 2.6-mm FiberTak suture anchor to the lesser tuberosity through the subscapularis tendon. The no. 5 blue FiberWire suture is firmly pulled, which deploys the self-bunching mechanism of the anchor and fixes the anchor in the lesser tuberosity. Three sutures, which are anchored in the lesser tuberosity and pierce the subscapularis tendon, exit the 8.25 mm arthroscopic cannula.

humerus. The anterior and posterior portals are closed in a standard fashion with 3-0 nylon, and dressings are applied. To ensure proper healing of the repaired rotator cuff, the patient's arm is placed in an adductor sling and immobilized for 6 weeks.

The patient is encouraged to initiate passive range of motion exercises from 0-2 weeks postoperatively to avoid the risk of stiffness. Exercises include pendulums and passive forward flexion and external rotation. Active ROM of the operative shoulder is discouraged. Active flexion and extension of the elbow of the operative extremity is allowed. From weeks 2-6, the patient can progress to full passive ROM exercises but will continue wearing the adductor sling. From week 6, discontinuation of the sling is encouraged, and the patient will progress to active ROM exercises of the operative shoulder but will avoid exercises that cause acute discomfort or pain.

Discussion

Arthroscopic repair of subscapularis tears can be performed with excellent outcomes.¹¹⁻²⁴ Through the advancements of arthroscopic techniques, numerous investigators have proposed various techniques of varying complexity for repair of isolated subscapularis

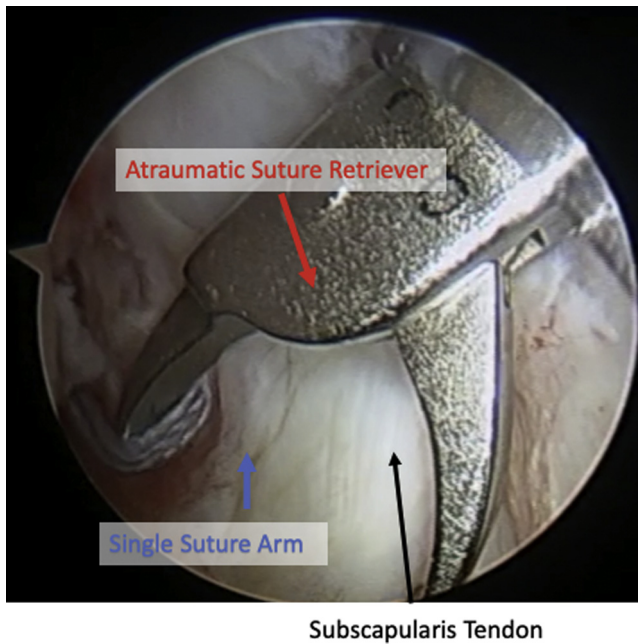


Fig 4. Patient is positioned in the right lateral decubitus position. Arthroscopic image of the left shoulder through the posterior portal with a 30° arthroscope depicts a suture retriever grasping one end of the blue no. 5 FiberWire repair stitch, which is then retrieved under the subscapularis tendon and out of the anterior portal.

tears.^{18,26–32} Van der Zwaal et al. proposed that an additional anchor should be placed for every 1 cm of the subscapularis involved in the tear.²² Moreover, Denard et al. suggested a double-row repair with two medial and two lateral anchors if the tear involved more than 1.5 cm of the subscapularis tendon.³⁴ Although there have been various proposals for the number of anchors needed for various tears, a biomechanical study determined that a single anchor for subscapularis tears that involved up to 50% of the

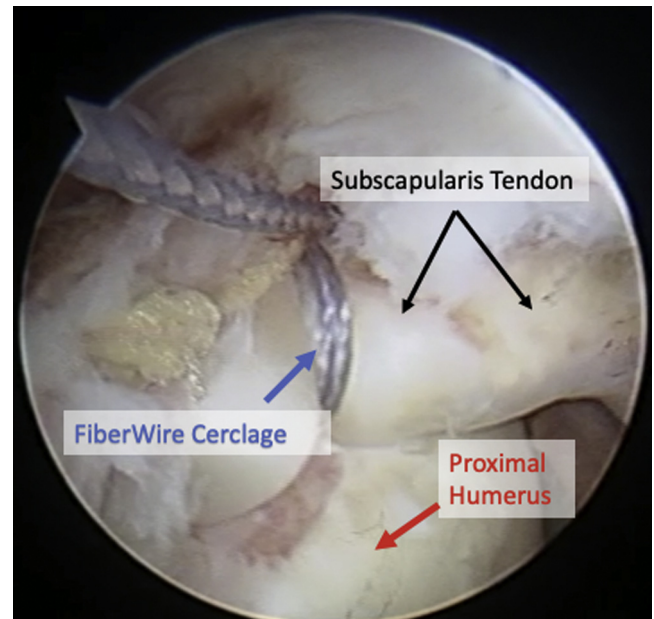


Fig 6. Patient is positioned in the right lateral decubitus position. Arthroscopic image of the left shoulder through the posterior portal with a 30° arthroscope depicts the knotless FiberTak soft anchor subscapularis repair after the FiberLink shuttle suture guides the no. 5 FiberWire through the soft suture anchor. Pulling on the free nonlooped end of the shuttlelink suture delivers the repair stitch down to the anchor.

subscapularis tendon provided adequate stability and fixation.³⁵

This surgical technique and accompanying technical video demonstrates an efficient repair for a complete, upper-third subscapularis tendon tear using a single knotless, soft-suture anchor through a single anterior working portal. Some advantages include providing the physician with the ability to provide tension to the repair under direct visualization after anchor insertion, avoiding potential complications associated with

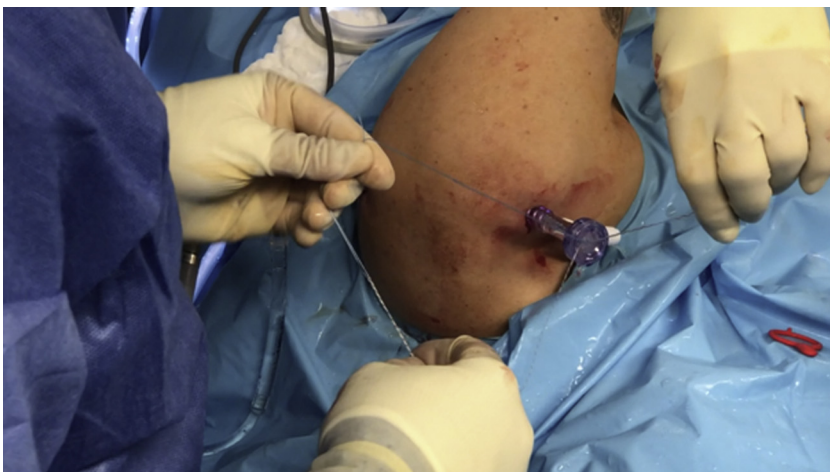

Fig 5. Patient is positioned in the right lateral decubitus position. Intraoperative image of the left shoulder depicts the end of the blue no. 5 FiberWire repair stitch loaded into the rounded end of the FiberLink shuttle. The free, nonlooped end of the shuttle suture is pulled, delivering the repair stitch down to the anchor. A knot pusher is used to properly tension the repair stitch before excess suture is cut.

Table 3. Advantages and Disadvantages

Advantages	Disadvantages
<p>Single anterior portal reduces risk of infection and neurovascular injury.</p> <p>Technique does not require a suture passer and involves fewer steps than alternative repairs involving traditional suture anchors.</p> <p>Knotless cerclage technique allows for a lower profile repair.</p>	<p>FiberTak anchor system engages differently than other anchors and may require an additional learning curve for new users.</p> <p>A second operator should be used for humeral manipulation to engage proper anchor placement.</p> <p>There is a risk of injury to underlying bone surface during blunt entry through the subscapularis, so this step should be performed under direct visualization.</p> <p>Technique is limited to superior third subscapularis tendon tears.</p>
<p>FiberTak system allows surgeon to dial in tension of the repair after anchor fixation into the lesser tuberosity.</p> <p>FiberTak soft anchors avoid risks associated with traditional suture anchors.</p>	

traditional suture anchors, and obtaining overall time efficiency because surgical instruments that are typically involved with the use of traditional suture anchors are not required. A key advantage of this technique is the ability to adjust tension of the repair with direct visualization following anchor fixation into the lesser tuberosity; thus, the surgeon can dial in additional tension as necessary to ensure an accurate repair.^{36,37} The use of a soft anchor avoids concerns associated with traditional suture anchors, such as osteolysis, chondrolysis, revision drilling, anchor loosening, fatigue fractures, and difficulties acquiring magnetic resonance imaging.^{38–43} In addition, a soft suture anchor occupies less space and volume compared to traditional suture anchors, which can be helpful in revision situations.^{42,44} Knotless suture anchors have also shown decreased variability in biomechanical properties and greater than or equal to biomechanical strength vs traditional suture anchors, offering a more consistent biomechanical outcome compared to knot repair.^{45,46} Furthermore, given the variety and complexity of repairs with excellent outcomes, the technique presented in this note reduces steps, tools, implants, and time to perform the repair, while offering a similar high-quality repair. For instance, this technique simultaneously passes sutures through the tendon and places the anchor into the lesser tuberosity, eliminating the use of traditional suture passers that are typically needed to pass sutures through the tendon. Moreover, the self-locking mechanism of a knotless suture anchor is time efficient and avoids inconsistencies of knot tying that lead to knot stacks, knot abrasions, and undesirable soft tissue trauma.³⁶ The use of a knotless suture anchor reduces complications associated with patient discomfort, knot migration, knot impingement, and chondral abrasion.^{45,47,48} This surgical technique effectively reduces difficulties associated with traditional suture anchors and knot repairs, offers strong fixation and biomechanical performance, and minimizes both operative time and potential postoperative complications.

Because our surgical technique is limited to superior subscapularis tendon tears of the upper third, a potential concern arises regarding technique reproducibility due to innate anatomical differences in tear morphology. This technique involves a single anchor to the lesser tuberosity footprint, so tears that have resulted in the retraction of the subscapularis or involve a larger portion of the subscapularis tendon may require additional anchors or anchor row.¹⁶ Furthermore, because of the limited visualization, the risk of causing unwanted damage to the underlying bone while piercing the subscapularis exists, so constant visual verification that the anchor has only progressed far enough to only pierce the tendon is warranted. Furthermore, given a single anterior portal and limited working area, it may be difficult to properly visualize the soft anchor entering the lesser tuberosity if the subscapularis is obstructing the anchor's path to fixation. Additionally, a second operator is required for humerus manipulation to either externally or internally rotate the shoulder for proper anchor placement. A complete list of disadvantages and advantages to this surgical technique are provided in [Table 3](#).

This Technical Note presents a single-portal, single-soft suture anchor repair of a full-thickness superior subscapularis tear. Using a single knotless, self-punching soft suture anchor minimizes potential complications and disadvantages associated with knot repair and traditional suture anchors. Given the reproducibility and time-efficient nature of our technique, we recommend this procedure as a reliable option for arthroscopic repair of full thickness superior subscapularis tendon tears.

References

1. Aguirre K, Mudreac A, Kiel J. Anatomy, Shoulder and Upper Limb, Subscapularis Muscle, StatPearls. *Treasure Island, FL: StatPearls Publishing*. 2021, <http://www.ncbi.nlm.nih.gov/books/NBK513344/>. Accessed March 19, 2021.
2. Deutsch A, Altchek DW, Veltri DM, Potter HG, Warren RF. Traumatic tears of the subscapularis tendon:

- Clinical diagnosis, magnetic resonance imaging findings, and operative treatment. *Am J Sports Med* 1997;25:13-22. <https://doi.org/10.1177/036354659702500104>.
3. Gerber C, Krushell R. Isolated rupture of the tendon of the subscapularis muscle. Clinical features in 16 cases. *J Bone Joint Surg Br* 1991;73-B:389-394. <https://doi.org/10.1302/0301-620X.73B3.1670434>.
 4. Symeonides PP. The significance of the subscapularis muscle in the pathogenesis of recurrent anterior dislocation of the shoulder. *J Bone Joint Surg Br* 1972;54-B:476-483. <https://doi.org/10.1302/0301-620X.54B3.476>.
 5. Piasecki DP, Nicholson GP. Tears of the subscapularis tendon in athletes—Diagnosis and repair techniques. *Clin Sports Med* 2008;27:731-745. <https://doi.org/10.1016/j.cs.m.2008.06.005>.
 6. Ferrick MR. Coracoid impingement: A case report and review of the literature. *Am J Sports Med* 2000;28:117-119. <https://doi.org/10.1177/03635465000280010501>.
 7. Walch G, Nové-Josserand L, Boileau P, Levigne C. Subluxations and dislocations of the tendon of the long head of the biceps. *J Shoulder Elbow Surg* 1998;7:100-108. [https://doi.org/10.1016/S1058-2746\(98\)90218-X](https://doi.org/10.1016/S1058-2746(98)90218-X).
 8. Richards DP, Burkhart SS, Campbell SE. Relation between narrowed coracohumeral distance and subscapularis tears. *Arthrosc J Arthrosc Relat Surg* 2005;21:1223-1228. <https://doi.org/10.1016/j.arthro.2005.06.015>.
 9. Narasimhan R, Shamse K, Nash C, Dhingra D, Kennedy S. Prevalence of subscapularis tears and accuracy of shoulder ultrasound in pre-operative diagnosis. *Int Orthop* 2016;40:975-979. <https://doi.org/10.1007/s00264-015-3043-9>.
 10. Garavaglia G, Ufenast H, Taverna E. The frequency of subscapularis tears in arthroscopic rotator cuff repairs: A retrospective study comparing magnetic resonance imaging and arthroscopic findings. *Int J Shoulder Surg* 2011;5:90-94. <https://doi.org/10.4103/0973-6042.91000>.
 11. Saltzman BM, Collins MJ, Leroux T, et al. Arthroscopic repair of isolated subscapularis tears: A systematic review of technique-specific outcomes. *Arthrosc J Arthrosc Relat Surg* 2017;33:849-860. <https://doi.org/10.1016/j.arthro.2016.10.020>.
 12. Jo Y-G, Park I, Kang J-S, Shin S-J. Clinical outcomes and tendon integrity in patients with chronic retracted subscapularis tear after arthroscopic single-row oblique mattress suture repair technique. *Arthrosc J Arthrosc Relat Surg* 2019;35:1973-1981. <https://doi.org/10.1016/j.arthro.2019.01.057>.
 13. Monroe EJ, Flores SE, Chambers CC, et al. Patient-reported outcomes after isolated and combined arthroscopic subscapularis tendon repairs. *Arthrosc J Arthrosc Relat Surg* 2019;35:1779-1784. <https://doi.org/10.1016/j.arthro.2019.01.034>.
 14. Nové-Josserand L, Collin P, Godenèche A, Walch G, Meyer N, Kempf J-F. Ten-year clinical and anatomic follow-up after repair of anterosuperior rotator cuff tears: Influence of the subscapularis. *J Shoulder Elbow Surg* 2017;26:1826-1833. <https://doi.org/10.1016/j.jse.2017.03.037>.
 15. Lee J, Shukla DR, Sánchez-Sotelo J. Subscapularis tears: hidden and forgotten no more. *JSES Open Access* 2018;2:74-83. <https://doi.org/10.1016/j.jses.2017.11.006>.
 16. Lafosse L, Jost B, Reiland Y, Audebert S, Toussaint B, Gobezie R. Structural integrity and clinical outcomes after arthroscopic repair of isolated subscapularis tears. *J Bone Jt Surg* 2007;89:1184-1193. <https://doi.org/10.2106/JBJS.F.00007>.
 17. Seppel G, Plath JE, Völk C, et al. Long-term results after arthroscopic repair of isolated subscapularis tears. *Am J Sports Med* 2017;45:759-766. <https://doi.org/10.1177/0363546516676261>.
 18. Goh Keng Meng J, Chen JYQ, Lie DTT. A new technique of arthroscopic subscapularis repair with 2-year clinical outcomes in an Asian population. *J Orthop Surg* 2017;25:2309499017727902. <https://doi.org/10.1177/2309499017727902>.
 19. Toussaint B, Audebert S, Barth J, et al. Arthroscopic repair of subscapularis tears: Preliminary data from a prospective multicentre study. *Orthop Traumatol Surg Res* 2012;98:S193-S200. <https://doi.org/10.1016/j.otsr.2012.10.004>.
 20. Nové-Josserand L, Hardy M-B, Leandro Nunes Ogassawara R, Carrillon Y, Godenèche A. Clinical and structural results of arthroscopic repair of isolated subscapularis tear. *J Bone Jt Surg* 2012;94:e125. <https://doi.org/10.2106/JBJS.K.00008>.
 21. Kim S-H, Oh I, Park J-S, Shin S-K, Jeong W-K. Intra-articular repair of an isolated partial articular-surface tear of the subscapularis tendon. *Am J Sports Med* 2005;33:1825+.
 22. van der Zwaal P, Schuller L, Urlings TAJ, Coerkamp EG, van Arkel ERA, van der List MPJ. Clinical outcome and structural integrity of all-arthroscopic repair of degenerative subscapularis tendon tears. *Knee Surg Sports Traumatol Arthrosc* 2013;21:1620-1625. <https://doi.org/10.1007/s00167-012-2147-7>.
 23. Shen Y, Zhao X, Qi C, et al. Surgical outcomes after arthroscopic single row anchor repair for subscapularis tears concomitant with injury of the long head of the biceps tendon. *Orthop Surg* 2020;12:498-504. <https://doi.org/10.1111/os.12649>.
 24. Hasler A, Boyce G, Schallberger A, Jost B, Catanzaro S, Gerber C. Arthroscopic repair of isolated subscapularis tears: clinical outcome and structural integrity with a minimum follow-up of 4.6 years. *J Shoulder Elbow Surg* 2019;28:2171-2180. <https://doi.org/10.1016/j.jse.2019.03.024>.
 25. Lafosse L, Van Isacker T, Wilson JB, Shi LL. A concise and comprehensive description of shoulder pathology and procedures: The 4D Code System. *Adv Orthop* 2012;2012:930543. <https://doi.org/10.1155/2012/930543>.
 26. Chernchujit B, Sharma PN. Arthroscopic repair of massive subscapularis and supraspinatus tear by double-row knotless technique. *Arthrosc Tech* 2017;6:e2255-e2258. <https://doi.org/10.1016/j.eats.2017.08.033>.
 27. Elena N, Woodall BM, Mac Hale WP, et al. Single portal technique for subscapularis tendon repair. *Arthrosc Tech* 2018;7:e645-e649. <https://doi.org/10.1016/j.eats.2018.02.014>.
 28. You JS, Monroe EJ, Friedman JM, et al. Arthroscopic single-portal subscapularis tendon repair. *Arthrosc Tech* 2020;9:e1447-e1452. <https://doi.org/10.1016/j.eats.2020.06.005>.

29. Ek ET, Perret MC, Borbas P. Arthroscopic knotless repair of complete full-thickness tears of the subscapularis tendon through a single portal. *Arthrosc Tech* 2020;9:e439-e443. <https://doi.org/10.1016/j.eats.2019.11.015>.
30. Barlow JD, Everhart JS. Arthroscopic subscapularis repair through a single anterior portal. *Arthrosc Tech* 2017;6:e1593-e1598. <https://doi.org/10.1016/j.eats.2017.06.014>.
31. Baker CE, Camp CL, Barlow JD. Knotless arthroscopic repair of subscapularis avulsion fracture using a single anterior portal. *Arthrosc Tech* 2020;9:e1453-e1458. <https://doi.org/10.1016/j.eats.2020.06.004>.
32. Lenart BA, Ticker JB. Subscapularis tendon tears. *EFORT Open Rev* 2017;2:484-495. <https://doi.org/10.1302/2058-5241.2.170015>.
33. Barth JRH, Burkhart SS, De Beer JF. The bear-hug test: A new and sensitive test for diagnosing a subscapularis tear. *Arthrosc J Arthrosc Relat Surg* 2006;22:1076-1084. <https://doi.org/10.1016/j.arthro.2006.05.005>.
34. Denard PJ, Burkhart SS. Arthroscopic recognition and repair of the torn subscapularis tendon. *Arthrosc Tech* 2013;2:e373-e379. <https://doi.org/10.1016/j.eats.2013.05.007>.
35. Lorbach O, Trennheuser C, Kieb M, Efe T, Kohn D, Anagnostakos K. Reconstruction of 25 and 50% subscapularis tears: a single anchor with a double-mattress suture is sufficient for the reconstruction. *Knee Surg Sports Traumatol Arthrosc* 2016;24:3855-3862. <https://doi.org/10.1007/s00167-015-3767-5>.
36. Lacheta L, Dekker TJ, Anderson N, Goldenberg B, Millett PJ. Arthroscopic knotless, tensionable all-suture anchor Bankart repair. *Arthrosc Tech* 2019;8:e647-e653. <https://doi.org/10.1016/j.eats.2019.02.010>.
37. Dekker TJ, Lacheta L, Goldenberg B, Grantham WJ, Millett PJ. Rotator cuff sparing arthroscopic SLAP repair with knotless all-suture anchors. *Arthrosc Tech* 2019;8:e993-e998. <https://doi.org/10.1016/j.eats.2019.05.009>.
38. Athwal GS, Shridharani SM, O'Driscoll SW. Osteolysis and arthropathy of the shoulder after use of bioabsorbable knotless suture anchors: A report of four cases. *J Bone Jt Surg* 2006;88:1840-1845. <https://doi.org/10.2106/JBJS.E.00721>.
39. Glueck D, Wilson TC, Johnson DL. Extensive osteolysis after rotator cuff repair with a bioabsorbable suture anchor: a case report. *Am J Sports Med* 2005;33:742-744. <https://doi.org/10.1177/0363546504269254>.
40. Agrawal V, Pietrzak WS. Triple labrum tears repaired with the JuggerKnot™ soft anchor: Technique and results. *Int J Shoulder Surg* 2015;9:81-89. <https://doi.org/10.4103/0973-6042.161440>.
41. Kaar TK, Schenck RC, Wirth MA, Rockwood CA. Complications of metallic suture anchors in shoulder surgery: A report of 8 cases. *Arthrosc J Arthrosc Relat Surg* 2001;17:31-37. <https://doi.org/10.1053/jars.2001.18246>.
42. Dhawan A, Ghodadra N, Karas V, Salata MJ, Cole BJ. Complications of bioabsorbable suture anchors in the shoulder. *Am J Sports Med* 2012;40:1424-1430. <https://doi.org/10.1177/0363546511417573>.
43. Ozbaydar M, Elhassan B, Warner JJP. The use of anchors in shoulder surgery: A shift from metallic to bioabsorbable anchors. *Arthrosc J Arthrosc Relat Surg* 2007;23:1124-1126. <https://doi.org/10.1016/j.arthro.2007.05.011>.
44. Mazzocca AD, Chowaniec D, Cote MP, et al. Biomechanical evaluation of classic solid and novel all-soft suture anchors for glenoid labral repair. *Arthrosc J Arthrosc Relat Surg* 2012;28:642-648. <https://doi.org/10.1016/j.arthro.2011.10.024>.
45. Li H, Xu H, Hua Y, Chen W, Li H, Chen S. Anatomic knot suture anchor versus knotless suture anchor technique for anterior talofibular ligament repair: a biomechanical comparison. *Orthop J Sports Med* 2020;8:2325967119898125. <https://doi.org/10.1177/2325967119898125>.
46. Denard PJ, Adams CR, Fischer NC, Piepenbrink M, Wijdicks CA. Knotless fixation is stronger and less variable than knotted constructs in securing a suture loop. *Orthop J Sports Med* 2018;6:2325967118774000. <https://doi.org/10.1177/2325967118774000>.
47. Bents EJ, Brady PC, Adams CR, Tokish JM, Higgins LD, Denard PJ. Patient-reported outcomes of knotted and knotless glenohumeral labral repairs are equivalent. *Am J Orthop Belle Mead NJ* 2017;46:279-283.
48. Thal R, Nofziger M, Bridges M, Kim JJ. Arthroscopic Bankart repair using knotless or BioKnotless suture anchors: 2- to 7-year results. *Arthroscopy* 2007;23:367-375. <https://doi.org/10.1016/j.arthro.2006.11.024>.