

Open Access

Addition of Endoscopic Ultrasound (EUS)-Guided Fine Needle Aspiration and On-Site Cytology to EUS-Guided Fine Needle Biopsy Increases Procedure Time but Not Diagnostic Accuracy

Rajesh N. Keswani¹, Kumar Krishnan¹, Sachin Wani², Laurie Keefer¹ and Srinadh Komanduri¹

¹Division of Gastroenterology, Northwestern University Feinberg School of Medicine, Chicago, IL, ²Division of Gastroenterology, University of Colorado, Denver, CO, USA

See commentary on page 207-209

Background/Aims: Although the diagnostic accuracy of endoscopic ultrasound with fine needle aspiration (EUS-FNA) in pancreas adenocarcinoma is high, endoscopic ultrasound with fine needle biopsy (EUS-FNB) is often required in other lesions; in these cases, it may be possible to forgo initial EUS-FNA and rapid on-site cytology evaluation (ROSE). The aim of this study was to compare the diagnostic accuracy of EUS-FNB alone (EUS-FNB group) with a conventional sampling algorithm of EUS-FNA with ROSE followed by EUS-FNB (EUS-FNA/B group) in nonpancreas adenocarcinoma lesions.

Methods: Retrospective cohort study of subjects who underwent EUS sampling of nonpancreatic adenocarcinoma lesions between February 2011 and May 2013.

Results: Over the study period, there were 43 lesions biopsied in 41 unique patients in the EUS-FNB group and 53 patients in the EUS-FNA/B group. Overall diagnostic accuracy was similar between the EUS-FNB and EUS-FNA/B groups (83.7% vs. 84.9%; $p=1.0$). In the subgroup of subepithelial mass lesions, diagnostic accuracy remained similar in the EUS-FNB and EUS-FNA/B groups (81.0% and 70.6%; $p=0.7$). EUS-FNB procedures were significantly shorter than those in the EUS-FNA/B group (58.4 minutes vs. 73.5 minutes; $p<0.0001$).

Conclusions: EUS-FNB without on-site cytology provides a high diagnostic accuracy in nonpancreas adenocarcinoma lesions. There appears to be no additive benefit with initial EUS-FNA but this requires further study in a prospective study.

Key Words: Endosonography; Biopsy, fine-needle; Submucosal; Subepithelial masses

INTRODUCTION

Endoscopic ultrasound with fine needle aspiration (EUS-FNA) has become the dominant technique for sampling masses within and adjacent to the gastrointestinal tract. It has been shown to have a high diagnostic yield and excellent safety profile in the diagnosis of pancreas adenocarcinoma.¹ Further-

Received: November 19, 2013 **Revised:** January 1, 2014

Accepted: January 13, 2014

Correspondence: Rajesh N. Keswani

Division of Gastroenterology, Northwestern University Feinberg School of Medicine, 676 N. St Clair, Suite 1400, Chicago, IL 60611, USA

Tel: +1-312-695-5620, **Fax:** +1-312-695-5620

E-mail: raj-keswani@northwestern.edu

© This is an Open Access article distributed under the terms of the Creative Commons Attribution Non-Commercial License (<http://creativecommons.org/licenses/by-nc/3.0>) which permits unrestricted non-commercial use, distribution, and reproduction in any medium, provided the original work is properly cited.

more, on-site cytology has been shown to be critical in ensuring an accurate diagnosis when evaluating solid pancreatic lesions.^{2,3} In contrast, the diagnostic accuracy of EUS-FNA for subepithelial masses (SEMs), lymphadenopathy or retroperitoneal/mediastinal masses (LRMMs), or nonadenocarcinoma pancreas lesions is variable.⁴⁻⁶ In these cases, the lower diagnostic accuracy may be related to the need for histology to facilitate immunohistochemical staining or cellular architecture to solidify a final diagnosis. EUS with fine needle biopsy (FNB) has been recently shown to have a high diagnostic accuracy in these lesions.^{7,8}

Despite higher diagnostic accuracy, on-site cytology with rapid on-site evaluation (ROSE) of EUS-FNB has had limited benefit due to lower specimen adequacy.⁹ Given the lower diagnostic accuracy of EUS-FNA for nonpancreatic lesions and

the lower specimen adequacy of ROSE for EUS-FNB, it is unclear whether EUS-FNA and/or ROSE has an additive benefit to EUS-FNB alone with regards to diagnostic accuracy. The aim of this study was to evaluate the diagnostic accuracy of EUS-FNB without ROSE versus EUS-FNA followed by EUS-FNB, both with ROSE, in nonpancreatic adenocarcinoma cases. The secondary aim of this study was to determine the associated difference in procedure time between these two methods of tissue acquisition.

MATERIALS AND METHODS

Study population

Our institutional EUS database was reviewed for patients who underwent EUS evaluation for the following indications: 1) LRMM, 2) SEM, 3) atypical pancreatic mass (adenocarcinoma not suspected), or 4) gastrointestinal wall thickening, over a 28-month time period (February 2011 to May 2013). Patients who underwent attempted EUS-FNB without EUS-FNA or ROSE were identified (EUS-FNB group). These patients were compared to a cohort of patients who underwent EUS-FNA with ROSE and if needed, attempted EUS-FNB (EUS-FNA/B group) over an overlapping 15-month period (September 2010 to December 2011). Beginning in December 2011, our group began to forgo routine EUS-FNA for these lesions due to initial clinical experience with EUS-FNB; thus no further EUS-FNA/B patients were included after this to reduce the risk of selection bias.

Endoscopic, cytology, and surgical data were abstracted from identified patients. This retrospective cohort study was approved by the institutional review board at Northwestern University.

EUS-FNA and EUS-FNB

EUS was performed by one of two experienced endosonographers using the Olympus Aloka Alpha 5 system (Olympus America, Center Valley, PA, USA). Curvilinear array endosonography with FNA was performed using standard 22- or 25-gauge needles (Echo Tip Ultra; Cook Medical, Winston-Salem, NC, USA). Procedures were performed with either general anesthesia, monitored anesthesia, or conscious sedation depending on endoscopist and/or anesthesia provider preference. Our EUS-FNA technique utilizes the stylet during puncture, negative pressure suction, and between 10 and 20 movements of the needle per pass. EUS-FNB was performed with the Echotip Procore needle (Cook Medical) using 19-, 22-, and/or 25-gauge needles at the discretion of the endoscopist. FNB was performed as follows: 1) fine needle puncture of the lesion similar to FNA; 2) slow steady withdrawal of the stylet as the lesion was sampled with pincer like move-

ments (capillary aspiration); 3) removal of the needle followed by advancement of the stylet to express the core specimen.

In the EUS-FNA/B group, EUS-FNB was performed if EUS-FNA with ROSE was deemed inadequate or if core biopsy was specifically requested by the attending cytopathologist. The number of initial EUS-FNA passes prior to crossover to EUS-FNB was at the discretion of the endosonographer. ROSE was also performed on at least one EUS-FNB specimen in this group if EUS-FNB was required.

In the EUS-FNB group, core biopsies were submitted directly in formalin to the surgical pathology department where they were reviewed by a board certified surgical pathologist. ROSE was not performed on any specimens. In all groups, a pass was defined as an attempt at puncturing the lesion, regardless of the number of 'to and fro' movements within the lesion. The number of passes was at the discretion of the endosonographer. More than one needle size was used if an inadequate sample was obtained, determined by visual inspection.

Cytologic preparation

Only specimens in the EUS-FNA/B group utilized on-site cytology evaluation, described by us in detail previously.⁹ Briefly, assessment of adequacy was performed initially by a cytopathology trainee or technologist; slides were subsequently reviewed during the procedure by an attending board certified cytopathologist to determine adequacy. Specimen adequacy was defined as having tissue which is representative of the lesion in question and which will be adequate to make a final diagnosis. Thus, a specimen which was representative of the lesion but in which histology was requested by the attending cytopathologist to make a diagnosis was considered inadequate. Cell block was performed in all cases. The process of ROSE for FNB was as follows: on-site evaluation technique was determined by the presence or absence of a visible core. If the tissue acquired was an adequate visible core, standard touch preparation was utilized. In the event that only fragmented or scant tissue was obtained, the tissue was put on a slide, and a second slide was used to gently crush the tissue between the two slides to prepare an air-dried crush preparation; any residual tissue was fixed in 10% formalin for subsequent H&E staining.

Outcome measures

The primary outcome of this study was to compare diagnostic accuracy between the EUS-FNB and EUS-FNA/B groups. Diagnostic accuracy was defined as the percentage of total cases where an accurate cytologic or histologic diagnosis was achieved; accuracy was confirmed by clinical and/or surgical follow-up via review of the electronic medical record. Clinical follow-up in nonsurgical cases ranged between 6 to 33 months.

The secondary outcome was total procedure time. This was defined as time elapsed between the patient entering and leaving the procedure room and was extracted from the anesthesia record. These times were only calculated for procedures utilizing monitored anesthesia and were not assessed when a second procedure (e.g., endoscopic retrograde cholangiopancreatography [ERCP] or colonoscopy) was also performed.

Statistics

Data was subjected to analysis as a whole and by group using SPSS version 20 (IBM Co., Armonk, NY, USA). Demographic, lesion characteristics and outcomes were described as means, standard deviation or as medians and ranges for continuous variables and by proportions for categorical variables. Diagnostic accuracy was calculated as a percentage. Bivariate analysis was performed to determine differences between the groups using *t*-tests for continuous variables and Fisher exact or chi-square tests for categorical variables.

RESULTS

Procedures

The chart review yielded 43 lesions biopsied in 41 unique patients in the EUS-FNB group. These patients were compared to 53 patients in the EUS-FNA/B group (Fig. 1). The procedure indications were significantly different between the two cohorts. In the EUS-FNB cohort, SEMs were the most common indication (48.8%) followed by LRMM (20.0%). In the cohort of 53 EUS-FNA/B patients, LRMM (50.9%) was the most common indication followed by SEMs (26.4%; *p*=0.009) (Table 1). Mean lesion diameter was similar between EUS-FNB and EUS-FNA/B groups (23.8 mm vs. 27.6 mm;

p=0.35).

Procedure outcomes

Diagnostic accuracy in the EUS-FNB group was 83.7% (95% confidence interval [CI], 72.7 to 94.7) and 84.9% in the EUS-FNA/B group (95% CI, 75.3 to 94.5; *p*=1.0) (Table 2). In the subgroup of SEM lesions, diagnostic accuracy remained similar in the EUS-FNB (81.0%) and EUS-FNA/B groups (70.6%; *p*=0.7). Diagnosis accuracy was also similar for LRMM and all non-pancreatic lesions between the two groups. Prior EUS-FNA was nondiagnostic in eight patients in the EUS-FNB group; EUS-FNB was diagnostic in six of these patients. The most common final diagnosis in both groups was spindle cell neoplasm (Table 3). There were two cases in which follow-up determined that the EUS diagnosis was incorrect, both in the EUS-FNB group. In one case, a serous cystadenoma was biopsied and incorrectly interpreted as a neuroendocrine neoplasm; in the other case, the biopsy of the esophageal wall was normal but the clinical follow-up confirmed a diagnosis of achalasia. There were no observed adverse events in either group.

In the EUS-FNA/B group, a median of 4 (range, 2 to 8) EUS-FNA passes were performed prior to either procedure termination or EUS-FNB. The procedure was terminated after EUS-FNA only in 10 lesions (18.9%), nine of which were procedures for LRMM. EUS-FNA on-site evaluation was adequate in only nine cases; in the remaining cases, either no representative tissue was present or histology was requested to make a diagnosis (as determined by the attending cytopathologist). EUS-FNB was performed in the remaining patients (*n*=43) with inadequate on-site evaluation after EUS-FNA. A median of two EUS-FNB passes were performed in both the EUS-FNB (range,

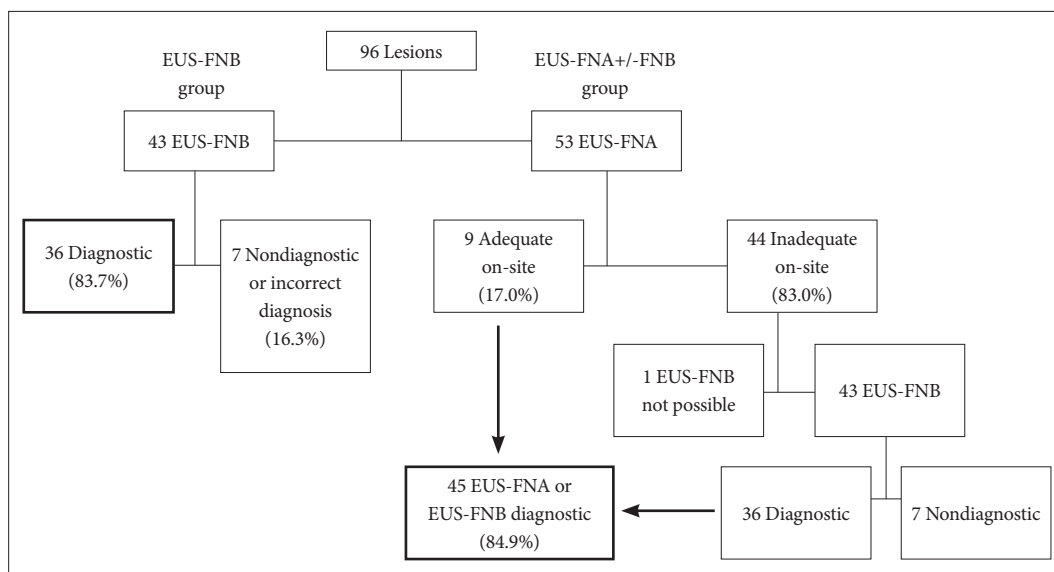


Fig. 1. Study flow. EUS-FNB, endoscopic ultrasound with fine needle biopsy; FNA, fine needle aspiration.

Table 1. Patient Demographics and Lesion Characteristics

Characteristic	EUS-FNB (<i>n</i> =43) ^{a)}	EUS-FNA/B (<i>n</i> =53)
Age, yr	59.0±12.7 (30–86.5)	62.2±13.0 (27–86.5)
Male gender	23 (56.1) ^{a)}	21 (39.6)
Preprocedure diagnosis		
LRMM	9 (20.9)	27 (50.9) ^{b)}
Subepithelial gastric mass	19 (44.2)	14 (26.4)
Other subepithelial mass	2 (4.6)	3 (5.7)
Atypical pancreas	5 (11.6)	8 (15.1)
Intestinal wall thickening	7 (16.3)	1 (1.9)
Bile duct	1 (2.3)	0
Mean lesion diameter, mm	23.8±18.4 (6–119)	27.6±19.8 (7–100)
Biopsy location		
Transepophageal biopsy	6 (14.0)	14 (26.4)
Transgastric biopsy	26 (60.5)	27 (50.9)
Transduodenal biopsy	11 (25.6)	9 (17.0)
Transrectal biopsy	0 (0)	3 (5.7)

Values are presented as mean±SD (range) or number (%).

EUS-FNB, endoscopic ultrasound with fine needle biopsy; EUS-FNA, endoscopic ultrasound with fine needle aspiration; LRMM, lymphadenopathy or retroperitoneal/mediastinal mass.

^{a)}43 lesions biopsied in 41 patients; ^{b)}*p*=0.009.

Table 2. Diagnostic Accuracy and Final Diagnoses

	EUS-FNB (<i>n</i> =43)	EUS-FNA/B (<i>n</i> =53)	<i>p</i> -value
Overall diagnostic accuracy	83.7 (72.7–94.7)	84.9 (75.3–94.5)	1.0
Diagnostic accuracy by indication			
LRMM	100	92.6 (85.6–99.7)	1.0
Subepithelial mass lesions	81.0 (69.3–92.7)	70.6 (58.3–82.9)	0.7
Nonpancreatic lesions ^{a)}	84.2 (73.3–95.1)	84.4 (74.6–94.2)	1.0

Values are presented as percent (range).

EUS-FNB, endoscopic ultrasound with fine needle biopsy; EUS-FNA, endoscopic ultrasound with fine needle aspiration; LRMM, lymphadenopathy or retroperitoneal/mediastinal mass.

^{a)}Includes sampling of LRMM, subepithelial mass lesions, intestinal wall, and bile duct thickening.

1 to 4) and EUS-FNA/B (range, 1 to 5) groups. In the EUS-FNB group, use of a 19-gauge needle was successful in 18/21 attempts; in three cases, the needle could not be advanced into the lesion. A 22-gauge needle was used 20 times and 25-gauge needle was used 10 times; advancement of these needles was successful in all cases. Multiple needle sizes were used in seven patients. In cases where only a single needle size was used, diagnostic accuracy was numerically greater when a 19-gauge needle was used (93.3%) compared to 22-gauge (78.6%) or 25-gauge (71.4%) needles (*p*=0.36). In the 43 patients who underwent FNB in the EUS-FNA/FNB group, a 19-gauge needle was used in 34 lesions (79.1%) and a 22-gauge needle was used in nine lesions (20.9%). For lymph node sampling, a 19-gauge needle was used more frequently (78%) than a 22-gauge needle (22%). For SEMs, a 19-gauge needle was also used most frequently (57.1%) compared to 22-gauge (28.6%) and 25-gauge

(14.3%) needles.

Procedure time

Mean procedure duration (defined as the total time in procedure room) for EUS-FNB procedures was 58.4 minutes (±13.1); mean EUS-FNA/B procedure duration was 73.5 minutes (±11.4; *p*<0.0001). EUS-FNB procedure duration was also shorter than the duration of the subgroup of 10 EUS-FNA/B patients who only required EUS-FNA (58.4±13.1 minutes vs. 72.8±12.1 minutes; *p*=0.003).

DISCUSSION

EUS-FNA has repeatedly been shown to have a high sensitivity and specificity in the diagnosis of pancreas adenocarcinoma. In contrast, for other lesions such as lymphoma or

Table 3. Final Diagnoses

	EUS-FNB (n=43)	EUS-FNA/B (n=53)
Spindle cell neoplasm	15 (34.9)	11 (20.8)
Normal (e.g., benign lymph node, normal wall thickening) or benign pathology (e.g., chronic pancreatitis or achalasia)	13 (30.2)	14 (26.4)
Metastatic carcinoma	4 (9.3)	9 (17.0)
Other malignant neoplasm (e.g., lymphoma, pheochromocytoma)	3 (7.0)	7 (13.2)
Neuroendocrine lesion	1 (2.3)	4 (7.5)
Nondiagnostic	5 (11.6)	8 (15.0)
Incorrect diagnosis (i.e., surgical pathology did not confirm EUS-FNB diagnosis)	2 (4.7)	0 (0)

Values are presented as number (%).

EUS-FNB, endoscopic ultrasound with fine needle biopsy; EUS-FNA, endoscopic ultrasound with fine needle aspiration.

spindle cell neoplasms, histology is often required to secure a diagnosis.¹⁰⁻¹² The acquisition of a histologic core biopsy allows for a detailed assessment of morphology and/or immunohistochemistry when needed. Methods of obtaining histology via EUS have traditionally produced variable rates of success which have not always been reproducible. The introduction of new EUS-guided core biopsy needle has significantly improved diagnostic accuracy for these nonpancreatic adenocarcinoma lesions.^{7,9} Given the high diagnostic yield of EUS-FNB in these lesions, it is unclear whether EUS-FNA has additive benefit.

Previous studies have clearly demonstrated increased diagnostic accuracy with ROSE for EUS-FNA.^{2,3} ROSE provides endosonographers with immediate feedback regarding specimen adequacy which may impact method of FNA (e.g., altering use of suction or change in needle gauge) and which portion of the lesion is targeted; a high sensitivity and specificity is essential to both ensure a final diagnosis is obtained and minimize unnecessary additional EUS-FNA passes. In contrast to EUS-FNA, the value of ROSE for EUS-FNB is not well established. We have previously shown an excellent positive predictive value (100%) for ROSE of EUS-FNB specimens, but with an unacceptable sensitivity (65%).⁹ The lack of concordance between final diagnosis and ROSE for EUS-FNB might be explained by fragmented samples or technique for slide preparation. Regardless, current strategies for ROSE for EUS-FNB remain suboptimal. Given the additional time and resources with both EUS-FNA and ROSE, EUS-FNB alone would be preferred if it maintained a sufficient diagnostic accuracy in these nonpancreas adenocarcinoma lesions.

The current study compared a cohort of lesions in which EUS-FNB without ROSE was performed with a cohort of similar lesions which were subjected to EUS-FNA with ROSE followed by EUS-FNB with ROSE if needed. The study excluded patients suspected to have pancreas adenocarcinoma, as an immediate diagnosis is often required for these patients to

guide ERCP. We found that there was no difference in final diagnostic accuracy between the EUS-FNB and EUS-FNA/B groups with both strategies demonstrating a high diagnostic accuracy. This diagnostic accuracy remained similar in the subgroup of patients with gastrointestinal SEMs. The diagnostic accuracy of lymph node sampling was high in both groups, though in contrast to SEMs, several lesions were adequately sampled with EUS-FNA alone. However, for all lesions, the total procedural time for the EUS-FNB group was 20% shorter than the EUS-FNA/B group. These results suggest that ROSE may not be necessary in cases where histologic specimens may be preferred and an immediate diagnosis is not needed. This study also adds to the growing literature that EUS-FNB improves the diagnostic accuracy of traditionally difficult lesions.

A few centers have previously shown that a core biopsy can be obtained with large gauge traditional aspiration needles.^{13,14} Thus, although a single core biopsy needle was used in this study, it is likely that any reliable method of obtaining a core biopsy would produce similar results in cases where histology is generally required.

The major limitation of the current study is its retrospective design. Although the distribution of lesions in the two cohorts was dissimilar at baseline, the diagnostic accuracy remained similar in subgroup analysis including diagnostic accuracy in gastrointestinal SEMs. However, a bias towards more complex patients undergoing EUS-FNA/B remains possible. The adequacy of EUS-FNA alone in the EUS-FNA/B group was lower than would be expected from the literature. This is likely due to two reasons. The number of EUS-FNA passes in the EUS-FNA/B group was not standardized and thus with more EUS-FNA passes, a diagnosis might have been obtained either on-site or via evaluation of the cell block. Furthermore, given the option to make a diagnosis via cell block (i.e., more EUS-FNA passes directly for cell block) or histology, the cytopathologists may prefer histology and thus request core biopsy given

the option. This is unlikely to change the overall outcomes, however, as it is unlikely to increase the diagnostic accuracy of EUS-FNA/B. EUS-FNA technique in this study included use of negative pressure suction which may have altered the diagnostic yield of certain lesions, notably lymph node sampling, as the efficacy of negative pressure suction is still unclear. Finally, we did not include patients with pancreas adenocarcinoma in this study, though EUS-FNB has previously been shown to have high diagnostic accuracy in this cohort as well. Thus, these results cannot be generalized to this group.

In summary, our data suggests that in select patients, EUS-FNB without ROSE provides a high diagnostic accuracy. Thus, an algorithmic approach to EUS-guided tissue acquisition may be appropriate. While EUS-FNA with ROSE remains the gold standard for diagnosis of pancreatic adenocarcinoma, this retrospective, uncontrolled study should prompt further investigation as to whether EUS-FNB without ROSE may be the optimal technique for other lesions and ultimately may be more cost-effective. Further prospective studies are underway to further validate this approach.

Conflicts of Interest

Dr. Keswani and Dr. Komanduri are consultants for Cook Medical; the remaining authors have no conflicts to disclose.

Acknowledgments

The results of this study was presented as an oral presentation at the American College of Gastroenterology 2013 Annual Meeting in San Diego, CA, USA.

REFERENCES

- Hewitt MJ, McPhail MJ, Possamai L, Dhar A, Vlavianos P, Monahan KJ. EUS-guided FNA for diagnosis of solid pancreatic neoplasms: a meta-analysis. *Gastrointest Endosc* 2012;75:319-331.
- Klapman JB, Logrono R, Dye CE, Waxman I. Clinical impact of on-site cytopathology interpretation on endoscopic ultrasound-guided fine needle aspiration. *Am J Gastroenterol* 2003;98:1289-1294.
- Iglesias-Garcia J, Dominguez-Munoz JE, Abdulkader I, et al. Influence of on-site cytopathology evaluation on the diagnostic accuracy of endoscopic ultrasound-guided fine needle aspiration (EUS-FNA) of solid pancreatic masses. *Am J Gastroenterol* 2011;106:1705-1710.
- Dumonceau JM, Polkowski M, Larghi A, et al. Indications, results, and clinical impact of endoscopic ultrasound (EUS)-guided sampling in gastroenterology: European Society of Gastrointestinal Endoscopy (ESGE) Clinical Guideline. *Endoscopy* 2011;43:897-912.
- Watson RR, Binmoeller KF, Hamerski CM, et al. Yield and performance characteristics of endoscopic ultrasound-guided fine needle aspiration for diagnosing upper GI tract stromal tumors. *Dig Dis Sci* 2011; 56:1757-1762.
- Sepe PS, Moparty B, Pitman MB, Saltzman JR, Brugge WR. EUS-guided FNA for the diagnosis of GI stromal cell tumors: sensitivity and cytologic yield. *Gastrointest Endosc* 2009;70:254-261.
- Iglesias-Garcia J, Poley JW, Larghi A, et al. Feasibility and yield of a new EUS histology needle: results from a multicenter, pooled, cohort study. *Gastrointest Endosc* 2011;73:1189-1196.
- Kim GH, Cho YK, Kim EY, et al. Comparison of 22-gauge aspiration needle with 22-gauge biopsy needle in endoscopic ultrasonography-guided subepithelial tumor sampling. *Scand J Gastroenterol* 2014;49: 347-354.
- Krishnan K, Dalal S, Nayar R, Keswani RN, Keefer L, Komanduri S. Rapid on-site evaluation of endoscopic ultrasound core biopsy specimens has excellent specificity and positive predictive value for gastrointestinal lesions. *Dig Dis Sci* 2013;58:2007-2012.
- Storch I, Jorda M, Thurer R, et al. Advantage of EUS Trucut biopsy combined with fine-needle aspiration without immediate on-site cytopathologic examination. *Gastrointest Endosc* 2006;64:505-511.
- Storch I, Shah M, Thurer R, Donna E, Ribeiro A. Endoscopic ultrasound-guided fine-needle aspiration and Trucut biopsy in thoracic lesions: when tissue is the issue. *Surg Endosc* 2008;22:86-90.
- Saftoiu A, Vilmann P, Guldhammer Skov B, Georgescu CV. Endoscopic ultrasound (EUS)-guided Trucut biopsy adds significant information to EUS-guided fine-needle aspiration in selected patients: a prospective study. *Scand J Gastroenterol* 2007;42:117-125.
- Larghi A, Verna EC, Ricci R, et al. EUS-guided fine-needle tissue acquisition by using a 19-gauge needle in a selected patient population: a prospective study. *Gastrointest Endosc* 2011;74:504-510.
- Varadarajulu S, Bang JY, Hebert-Magee S. Assessment of the technical performance of the flexible 19-gauge EUS-FNA needle. *Gastrointest Endosc* 2012;76:336-343.