



Contents lists available at ScienceDirect

International Journal of Surgery Case Reports

journal homepage: www.casereports.com

Prednisolone-induced virginal mammary hypertrophy: Case report

Samir Jabaiti^a, Luma Fayyad^{b,c}, Ula Isleem^{d,*}^a Department of Plastic and Reconstructive surgery, Jordan University Hospital, Amman, Jordan^b Department of Pathology, Jordan University Hospital, Amman, Jordan^c Department of Pathology, King Hussein Medical Center, Amman, Jordan^d Faculty of Medicine, University of Jordan, Amman, Jordan

ARTICLE INFO

Article history:

Received 30 January 2019

Received in revised form 22 March 2019

Accepted 16 April 2019

Available online 16 May 2019

Keywords:

Virginal mammary hypertrophy

Prednisolone

Mammoplasty

Case report

ABSTRACT

INTRODUCTION: Virginal mammary hypertrophy (VMH) is a rare benign disorder of the breast characterized by excessive enlargement of one or both breasts. It usually presents during adolescence. Drug-induced VMH has been scarcely reported in case reports. Review of the literature showed that prednisolone-induced gigantomastia was reported in a single study on a 47-year-old female. In this study, a case of VMH in a 17-year-old girl following prednisolone treatment will be described. Clinical presentation, clinical findings, diagnostic work-up, management and follow up are discussed.

PRESENTATION OF CASE: A 17-year-old, single female presented to the plastic surgery department at our institute with progressive enlargement of both breasts, 2 months following treatment with prednisolone. Incisional biopsy excluded other breast differential diagnoses. The patient was managed surgically with bilateral mammoplasty with free nipple-areola graft. A total of 8.325 kg of breast tissue was resected. Follow-up 48 months postoperatively revealed good patient satisfaction with no recurrence of breast hypertrophy.

DISCUSSION: Although the estrogen theory is regarded as the most credible explanation for VMH, several cases of drug-induced mammary hypertrophy have been reported. This study may be the first reported case of adolescent prednisolone-induced VMH. Mammoplasty is an accepted treatment despite its possible association with a higher recurrence rate.

CONCLUSION: VMH may be a rare complication of prednisolone treatment. It should be considered in patients presenting with breast hypertrophy following steroid administration.

© 2019 The Authors. Published by Elsevier Ltd on behalf of IJS Publishing Group Ltd. This is an open access article under the CC BY license (<http://creativecommons.org/licenses/by/4.0/>).

1. Introduction

This case report has been reported in accordance with the SCARE criteria [1].

Virginal mammary hypertrophy (VMH) is a benign disorder of the breast characterized by excessive enlargement of one or both breasts, which usually presents during adolescence. This condition may cause physical and psychological disability to patients at a critical stage of their life [2]. A variety of names have been given to this pathology in literature: juvenile hypertrophy, virginal/ juvenile macromastia, gigantomastia, juvenile gigantomastia, virginal breast hypertrophy, and macromastia [3].

There is no universal consensus on the definition of this pathology. Dafydd et al. defined gigantomastia as excess breast tissue that contributes 3% or more to the patient's total body weight [4].

The etiology of VMH has not yet been elucidated [3]. The estrogen theory discussed by Griffith is still regarded as the most credible explanation for abnormal breast enlargement. The estrogen theory includes excess local estrogen production within the breast tissue, enhanced estrogen receptor sensitivity to normal levels of estrogen, and the presence of an estrogen-like substance that mimics the effects of estrogen-producing ductal proliferation, or any combination of these factors [5]. This theory was supported by reports revealing increased estrogen receptor activity in the resected breast tissue [6], although other studies show normal receptor activity [7].

However, drug-induced mammary hypertrophy has been increasingly reported in a number of case reports. VMH has been associated with certain medications, such as neohetazone, cyclosporine, D-penicillamine, bucillamine, and propylthiouracil [8–12].

Drug-induced mammary hypertrophy secondary to steroid use was reported only once by Troccola et al who described a case of gigantomastia in a 47-year-old patient, in the setting of ovarian cancer, treated with cycles of chemotherapy combined with prednisolone [2]. In the following report, a case of juvenile mammary hypertrophy in a 17-year-old girl following prednisolone treatment for mixed connective tissue disease is presented.

* Corresponding Author at: Faculty of Medicine, University of Jordan, Queen Rania Al Abdullah Street, Amman, PO Box 6162, Jordan.

E-mail addresses: sjabaiti@yahoo.co.uk (S. Jabaiti), l.fayyad@yahoo.com (L. Fayyad), ulaisleem289@gmail.com (U. Isleem).

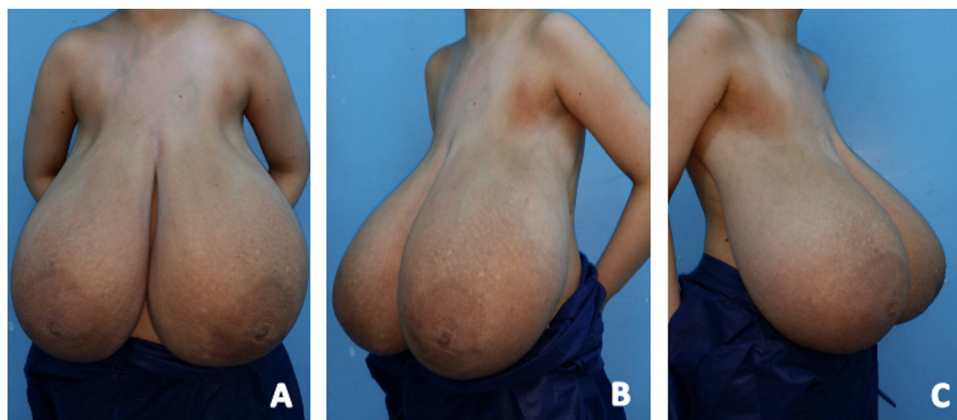


Fig. 1. (A) Anterior view of a 17-year old with bilateral mammary hypertrophy (B) Left lateral view (C) Right lateral view.

2. Presentation of case

In August of 2014, a 17-year-old female patient was referred to the Plastic Surgery Department of our institute. The patient complained of progressive enlargement of both breasts over a period of 14 months. Upon presentation to the outpatient clinic, the patient also complained of neck, shoulder, and back pain that caused marked limitation of their daily activities, as well as significant social embarrassment. The patient began menarche at 12 years of age. The patient denied a family history of similar breast disorders or of breast cancer.

Sixteen months prior to presentation to our hospital, the patient presented to another hospital complaining of diffuse joint pain, malar rash, skin rash, chest pain, digital swelling, and Raynaud's phenomena. The patient's work-up then showed anemia, neutropenia, and a positive ANA serology. The patient was diagnosed as a case of mixed connective tissue disease.

The patient was then started on a treatment course of 16 mg of oral prednisolone twice daily for eight months. The medication was then tapered to 10 mg daily for another six months. The enlargement began two months after initiating treatment, however, her treatment was maintained. The patient did not receive penicillamine, bucillamine, cyclosporine, or any other related drugs. When the patient presented to our hospital, they had undergone improvement in her symptoms.

On clinical examination, the patient's weight was 75 kg, height was 1.60 m, and body mass index (BMI) was calculated as 29.3 kg/m². Breast examination showed massive bilateral enlargement with marked ptosis, widened areolas, and dilated subcutaneous veins. Shoulder grooving from brassiere straps and intertrigo at the inframammary folds were also noted. (Fig. 1: (A) Anterior view of a 17-year old with bilateral mammary hypertrophy (B) Left lateral view (C) Right lateral view) Palpation revealed firm breast texture with diffuse nodularity. There was no axillary lymphadenopathy.

Routine biochemical examinations and endocrine investigations were within normal limits. The patient's hormonal workup included LH, FSH, prolactin, progesterin, 17-estradiol, T3, T4, TSH, and cortisol. Breast CT scan showed both breasts were hugely enlarged with dense parenchymal tissue bilaterally, associated with dependent fluid accumulation.

Incisional biopsy was performed to exclude other breast pathologies, such as virginal fibroadenoma, fibrocystic disease, phyllodes tumor, and breast lymphoma. It showed markedly increased collagenization of the stroma with areas of pseudoangiomatous stromal hyperplasia (PASH). The glandular component showed focal adenosis and foci of fibroadenomatoid hyperplasia were also seen.

The patient and her family were counseled regarding surgical options for treatment of the patient's condition, namely, subcutaneous mastectomy versus bilateral mammoplasty. They were informed of the likelihood of higher recurrence, yet a more desirable cosmetic outcome of the second option. They were also informed of possible complications, as well as the possibility of additional interventions that may be required in the future.

Bilateral breast reduction with nipple-areola complex transfer as a free graft was performed under general endotracheal intubation. A total of 8.325 kg of breast tissue was resected. (4225 g from the right side and 4100 g from the left side). The patient had an uneventful postoperative recovery with excellent graft take of the nipple-areola complex. The patient was discharged after 5 days and was followed up in the outpatient clinic.

The final histopathology report showed similar features to those seen in the incisional biopsy; with additional findings in the form of patchy infiltration of the ductal epithelium by lymphocytes and concentric "onion skin" type fibrosis surrounding small blood vessels with perivascular lymphoplasmacytic infiltration were also seen. The findings were consistent with juvenile macromastia and lymphocytic inflammation. There was no evidence of in-situ or invasive malignancy, lymphoma, or vasculitis. (Fig. 2: (A) Marked Collagenization and hyalinizing fibrosis of the breast stroma with compression of benign breast ducts into slit-like spaces in a fibroadenomatoid pattern. Hematoxylin and Eosin stain x40 (B) Higher power view; Black Arrow: Hyalinizing fibrosis of breast tissue stroma; Green Arrows: Pseudoangiomatous stromal hyperplasia; Star: Benign ductal epithelium. Hematoxylin and Eosin stain x100)

The patient did not receive any hormonal treatment, neither preoperatively or postoperatively. Twenty months after breast reduction, the patient underwent a scar revision procedure. Forty-eight months after the original procedure, the patient was found to be satisfied and there was no recurrence of breast hypertrophy. (Fig. 3: (A) Anterior view post mammoplasty at 34 months follow-up (B) Left lateral view (C) Right lateral view)

3. Discussion

Virginal mammary hypertrophy is a rare condition. It has been reported sporadically in medical literature with no prospective or observational trials [3]. Adolescent females suffering from this debilitating condition are vulnerable to developing a negative body image and significant psychological stresses. In addition, social issues arise secondary to poor fitting clothing, trouble exercising, and public scrutiny as a result of their enlarged breasts [13]. Furthermore, there are physical complications including back, neck

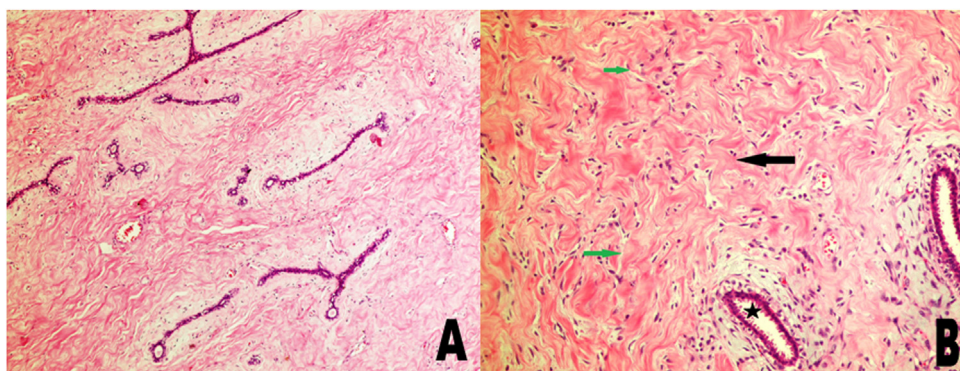


Fig. 2. (A) Marked Collagenization and hyalinizing fibrosis of the breast stroma with compression of benign breast ducts into slit-like spaces in a fibroadenomatoid pattern. Hematoxylin and Eosin stain x40 (B) Higher power view; Black Arrow: Hyalinizing fibrosis of breast tissue stroma; Green Arrows: Pseudoangiomatous stromal hyperplasia; Star: Benign ductal epithelium. Hematoxylin and Eosin stain x100.

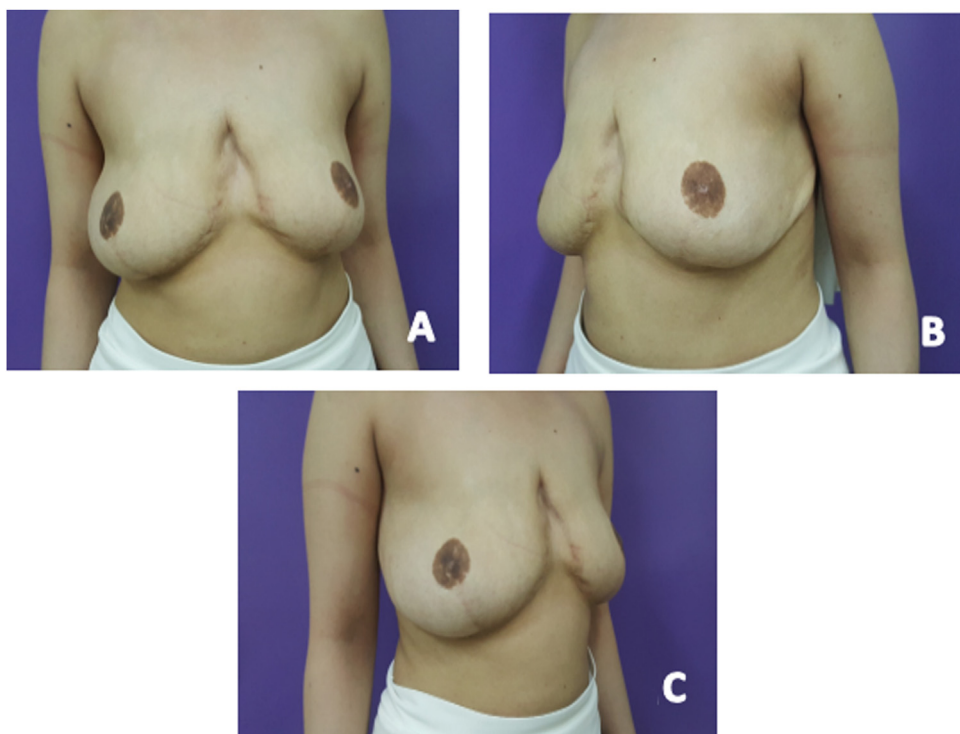


Fig. 3. Anterior view post mammoplasty at 34 months follow-up (B) Left lateral view (C) Right lateral view.

and shoulder pains, as well as intertrigo at the inframammary folds [14].

Drug-induced mammary hypertrophy has been reported in scattered case reports in the literature. Scott reported a possible relation between the antibiotic Neothetazone and the gigantomastia [8]. Penicillamine is the drug most commonly reported as an etiological factor in mammary hypertrophy, however, the mechanism of action is poorly understood [10]. Sakai et al reported the first case of bucillamine-induced giant mammary hyperplasia in a 25-year-old woman who was treated for rheumatoid arthritis. The authors believed that bucillamine was the cause of the giant hypertrophy because of its structural similarity to D-penicillamine [11]. O'Hare reported a case of a 12-year-old girl who developed bilateral mammary hypertrophy four months after initiation of propylthiouracil for the treatment of thyrotoxicosis [12].

A literature review revealed that prednisolone induced gigantomastia was reported only once by Troccola et al in 2011 [2]. The report described a case of gigantomastia in a 47-year-old

woman within 2 months of starting adjuvant chemotherapy protocol, including prednisolone, for ovarian cancer. The patient was treated with a bilateral breast reduction. The authors believed that prednisolone was implicated in gigantomastia since the same patient did not develop breast hypertrophy when treated with the adjunctive chemotherapy protocol without prednisolone for the treatment of cancer recurrence 2 years later. Our case report may support the correlation between prednisolone and breast hypertrophy.

Treatment of VMH is challenging. There are no accepted, evidence-based guidelines for its management due to the scarcity of reported cases and the absence of prospective or observational trials regarding the condition. Surgical treatment, medical treatment, or a combination of both have been attempted to manage this pathology. The two main surgical options discussed include reduction mammoplasty as a pedicle-based procedure or with free nipple graft, the second option is mastectomy with immediate or delayed breast reconstruction [3].

Reduction mammoplasty is a safe and effective treatment that can greatly alleviate the social, psychological, and physical strain caused by macromastia in adolescents [14]. Moreover, reduction mammoplasty has been associated with good overall satisfaction and improvements in quality of life on long-term follow-up [13].

The drawback of reduction mammoplasty is its higher reported recurrence rate compared with subcutaneous mastectomy, as shown in a meta-analysis of the case reports conducted by Hoppe et al. in 2011 [3]. Nevertheless, considering the depressing psychological consequences and negative cosmetic outcome of mastectomy on these adolescent patients, reduction mammoplasty is still the most popular approach to manage virginal mammary hypertrophy [3,13].

Many drugs, including several hormone-modulators, have been reported either alone or combined with surgery to manage VMH. Dydrogesterone (a progesterone analog) and tamoxifen (selective estrogen receptor modulator) prove to be the most popular choices. Tamoxifen has been used preoperatively to arrest breast growth and postoperatively to decrease recurrence with a variable success rate. However, at this time, there is inadequate reported experience with medical therapy for adolescents with juvenile breast hypertrophy to predict risks and benefits [15].

Furthermore, Tamoxifen has been associated with serious side effects that should be considered, especially in the younger population that suffers from virginal mammary hypertrophy. Side effects include endometrial hyperplasia—increasing the risk of endometrial cancer—hot flashes, increased risk of venous thrombosis, and bone density changes [16]. Taking into consideration these potential side effects of Tamoxifen versus its unverified benefits, it was not used preoperatively or postoperatively in our patient.

4. Conclusion

VMH is a very rare complication of prednisolone treatment. This correlation should be considered in patients presenting with breast hypertrophy while on steroids or related medications. Reduction mammoplasty is a reasonable option of surgical treatment owing to its positive psychological and cosmetic benefits. However, the patient and their family should be informed regarding the higher likelihood of recurrence.

Conflicts of interest

There is no conflict of interest to be declared.

Funding

This research did not receive any specific grant from funding agencies in the public, commercial, or not-for-profit sectors.

Ethical approval

The study was approved by the IRB of our institute.

Consent

Written informed consent was obtained from the patient for publication of this case report and the accompanying images. All

identifying details have been omitted. A copy of the written consent is available for review by the Editor-in-Chief of this journal on request.

Author contribution

Samir Jabaiti → Conceptualization, supervision, and data curation, as well as writing—Original draft

Luma Fayyad → Data curation, as well as writing—original draft
Ula Isleem → Writing—Review and Editing and Project administration

Registration of research studies

NA.

Guarantor

Samir K Jabaiti
Ula N Isleem

Provenance and peer review

Not commissioned, externally peer-reviewed.

References

- [1] R.A. Agha, M.R. Borrelli, R. Farwana, K. Koshy, A. Fowler, D.P. Orgill, For the SCARE Group, The SCARE 2018 statement: updating consensus surgical CARE Report (SCARE) guidelines, *Int. J. Surg.* 60 (2018) 132–136.
- [2] A. Trocchia, M. Maruccia, L.A. Dessy, M.G. Onesti, Cortisone-induced gigantomastia during chemotherapy, *G. Chir.* 32 (2011) 266–269.
- [3] I.C. Hoppe, P.P. Patel, C.J. Singer-Granick, M.S. Granick, Virginal mammary hypertrophy: a meta-analysis and treatment algorithm, *Plast Reconstr. Surg.* 127 (2011) 2224–2231, <http://dx.doi.org/10.1097/PRS.0b013e3182131bd1>.
- [4] H. Dafydd, K.R. Roehl, L.G. Phillips, A. Dancey, F. Peart, K. Shokrollahi, Redefining gigantomastia, *J. Plast. Reconstr. Aesthet. Surg.* 64 (2011) 160–163, <http://dx.doi.org/10.1016/j.bjps.2010.04.043>.
- [5] J.R. Griffith, Virginal breast hypertrophy, *J. Adolesc. Health Care* 10 (1989) 423–432.
- [6] A. Noczyńska, R. Wasikowa, T. Myczkowski, Hypersensitivity of estrogen receptors as a cause of gigantomastia in two girls (in Polish), *Pol. Merkur Lekarski.* 11 (2001) 507–509.
- [7] A. Gliosci, F. Presutti, Virginal gigantomastia: validity of combined surgical and hormonal treatments, *Aesthetic. Plast. Surg.* 17 (1993) 61–65.
- [8] E.H. Scott, Hypertrophy of the breast, possibly related to medication: a case report, *S. Afr. Med. J.* 44 (1970) 449–450.
- [9] V. Cerveli, G. Orlando, F. Giudiceandre, M. Grimaldi, F. Pisani, F. Strati, G. Iaria, E. Piccione, E. Torri, C. Carluccio, G. Tisone, C.U. Casciani, Gigantomastia and breast lumps in a kidney transplant recipient, *Transplant. Proc.* 31 (1999) 3224–3225.
- [10] J.E. Desautels, Breast gigantism due to D-penicillamine, *Can. Assoc. Radiol. J.* 45 (1994) 143–144.
- [11] Y. Sakai, S. Wakamatsu, K. Ono, N. Kumagai, Gigantomastia induced by bucillamine, *Ann. Plast. Surg.* 49 (2002) 193–195.
- [12] P.M. O'Hare, I.J. Frieden, Virginal breast hypertrophy, *Pediatr. Dermatol.* 17 (2000) 277–281.
- [13] J.T. Nguyen, H. Palladino, A.J. Sonnema, P.M. Petty, Long-term satisfaction of reduction mammoplasty for bilateral symptomatic macromastia in younger patients, *J. Adolesc. Health* 53 (2013) 112–117, <http://dx.doi.org/10.1016/j.jadohealth.2013.01.025>.
- [14] E.M. Wolfswinkel, V. Lemaine, W.M. Weathers, C.J. Chike-Obi, A.S. Xue, L. Heller, Hyperplastic breast anomalies in the female adolescent breast, *Semin. Plast. Surg.* 27 (2013) 49–55, <http://dx.doi.org/10.1055/s-0033-1347167>.
- [15] S. Pruthi, K.N. Jones, Nonsurgical management of fibroadenoma and virginal breast hypertrophy, *Semin. Plast. Surg.* (2013) 62–66, <http://dx.doi.org/10.1055/s-0033-1343997>.
- [16] I.H. Koves, M. Zacharin, Virginal breast hypertrophy of an 11-year-old girl, *J. Paediatr. Child. Health* 4 (2007) 315–317.

Open Access

This article is published Open Access at [sciencedirect.com](https://www.sciencedirect.com). It is distributed under the [IJSCR Supplemental terms and conditions](#), which permits unrestricted non commercial use, distribution, and reproduction in any medium, provided the original authors and source are credited.