

Supratentorial haemangioblastoma without von Hippel–Lindau syndrome in an adult: A rare tumor with review of literature

Sharad Pandey, Vivek Sharma, Deepa Pandey¹, Vikul Kumar, Mohan Kumar²

Departments of Neurosurgery and ²Pathology, Sir Sunderlal Hospital, IMS, BHU, ¹Department of Clinical Microbiology, Central Hospital, DLW, Varanasi, Uttar Pradesh, India

ABSTRACT

Supratentorial hemangioblastomas (HBLs) are rare, benign vascular tumors of the central nervous system neoplasms. Very scarce literature is available regarding supratentorial HBL without von Hippel–Lindau (VHL) syndrome in an adult. We reviewed the literature and PubMed advanced search showed only a few results of supratentorial HBL without VHL syndrome. We reported a rare case of cystic supratentorial HBL in 39-year-old male affecting the parietal lobe without VHL syndrome. Supratentorial HBL is a rare tumor and supratentorial HBL without VHL syndrome are even rarer. Being a rare entity, not much clinical data is currently available regarding supratentorial HBLs, thus necessitating the need for further reporting and review of such cases.

Key words: Cystic, supratentorial hemangioblastomas, without von Hippel–Lindau

Background

Hemangioblastomas (HBLs) are benign vascular tumors of the central nervous system (CNS) that are composed of vessels and neoplastic stromal cells.^[1] They can occur sporadically (66–80% of tumors) or in the context of the familial neoplasia syndrome von Hippel–Lindau (VHL) disease (20–33% of tumors).^[2] They are usually infratentorial in a location with supratentorial HBLs being rare. We reported a rare case of supratentorial HBL in 39-year-old male involving the parietal lobe without VHL syndrome.

Case Presentation

A 40-year-old male patient presented with a headache, weakness of left side body for past 6 months, and seizure since 2 months. There was no history of any inherited disease or cancer in

his family. He was well orientated to time, place, and person. Abnormal physical signs were limited to the CNS. Neurological examination revealed decreased the power of 4a/5 in both left upper and lower limb with no sensory involvement. The tendon reflexes were normal and plantar responses flexor. VHL disease was ruled out by chest radiograph, abdominal ultrasonography, fundoscopic examination, and workup for mutation of VHL gene. His blood pressure was 120/80 mmHg. There were no apparent abnormalities in cranial nerves. Investigations revealed hemoglobin of 17.3 g/dl, white cell count 5900 cells/mm³ with a normal differential, and platelet count of 170,000 cells/mm³. Blood urea, serum creatinine, serum electrolytes, liver function tests, blood sugar, serum transaminase, and a midstream specimen of urine were all normal.

Contrast-enhanced computed tomography (CT) head revealed well defined oval hypodense intra-axial lesion of approximate size 6.2 cm × 4.6 cm in anterior posterior and transverse axis respectively with mild perilesional edema, mass effect with epicentre in right frontoparietal junctional region. Lesion is

Access this article online	
Quick Response Code:	Website: www.asianjns.org
	DOI: 10.4103/1793-5482.165782

Address for correspondence:

Dr. Sharad Pandey, Department of Neurosurgery, Sir Sunderlal Hospital, IMS, BHU, Varanasi - 221 005, Uttar Pradesh, India.
E-mail: drsharad23@yahoo.com

This is an open access article distributed under the terms of the Creative Commons Attribution-NonCommercial-ShareAlike 3.0 License, which allows others to remix, tweak, and build upon the work non-commercially, as long as the author is credited and the new creations are licensed under the identical terms.

For reprints contact: reprints@medknow.com

How to cite this article: Pandey S, Sharma V, Pandey D, Kumar V, Kumar M. Supratentorial haemangioblastoma without von Hippel–Lindau syndrome in an adult: A rare tumor with review of literature. Asian J Neurosurg 2016;11:8-14.

predominantly cystic with intra-lesion enhancing septa and eccentric solid enhancing tissue. No significant haemorrhage and calcification was shown in Figure 1.

Intra-operatively the tumor was purplish, highly vascular intra-axial, with a good plane, and with multiple small feeders, with normal surrounding brain tissue [Figure 2]. Gross total excision of a vascular tumor measuring 5 cm × 3.7 cm × 3.6 cm from the right frontoparietal lobe was performed and sent for histopathological examination [Figure 3]. Histopathological finding showed a fine vascular network of capillary channels lined by endothelial cells and fine reticulin fibers between the stromal cells which was reported to be “HBL” [Figure 4]. The postoperative course was uneventful, and the patient’s hemoglobin gradually fell to 12.1 g/dl, remaining at a similar level on subsequent follow-up. Follow-up CT scan after 3 months showed no significant intracranial lesion [Figure 5].

Discussion and Review of Literature

HBLs are benign neoplasms that originate in the CNS.^[3] They represent 1.5–2.5% of all intracranial neoplasms and 7–12% of posterior fossa tumors.^[3] They are highly vascular well circumscribed solid or cystic neoplasms of CNS or retina.^[4]

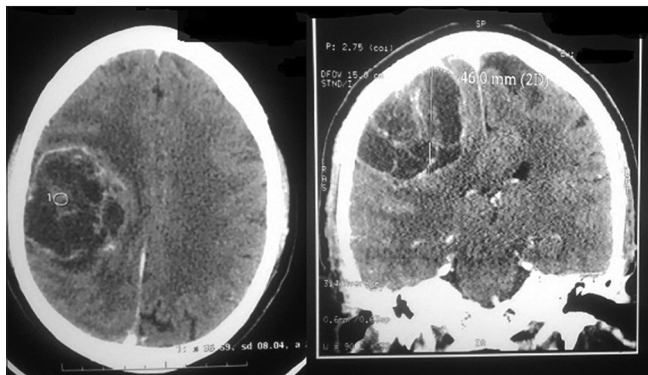


Figure 1: Contrast-enhanced computed tomography head showing well defined oval hypodense cystic intra-axial lesion with mild perilesional edema and mass effect; axial, coronal view

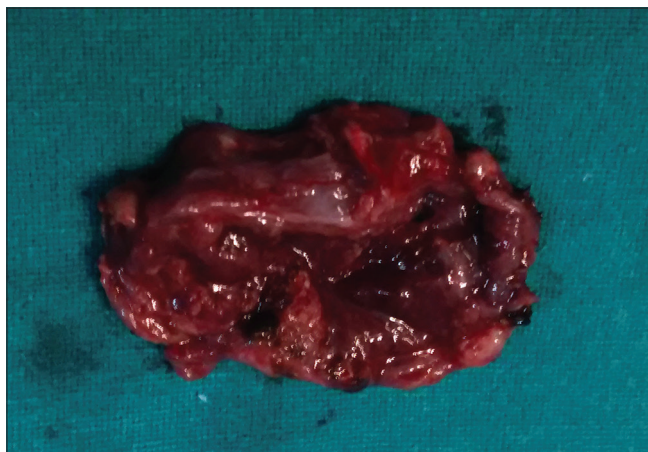


Figure 3: Excised tumor specimen

Also, they are the most common primary intra-axial posterior fossa tumor in adults.^[4] They are usually infratentorial, with a majority of them occurring in the cerebellum (76%) around the fourth ventricle and less commonly in the cerebral hemispheres (9%), spinal cord (7%), and brainstem (5%).^[5,6]

Supratentorial HBLs, which are quite rare,^[7] were first described by Bielschowsky in 1902.^[8,9] They are most commonly found in the frontal lobe of the cerebrum followed by parietal and temporal lobe. There is a handful of reported cases of congenital HBLs.^[10,11] In the present case, the tumor was present in the parietal region. They often result from loss of function of both alleles of the VHL gene.^[12,13] Supratentorial HBLs are rare and have been reported to comprise only 1–6% of all HBLs associated with VHL disease.^[14-16]

We reported a case of supratentorial HBL in an adult male without VHL syndrome and reviewed the literature. Till date, approximately 139 cases of supratentorial HBLs have been described in the literature out of which 82 cases had VHL

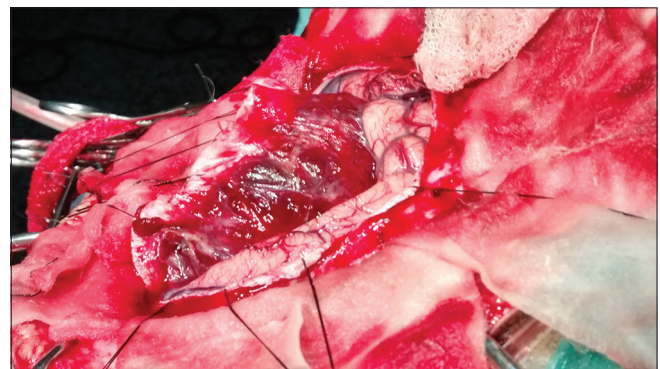

Figure 2: Intra-operative photograph of the highly vascular cystic tumor

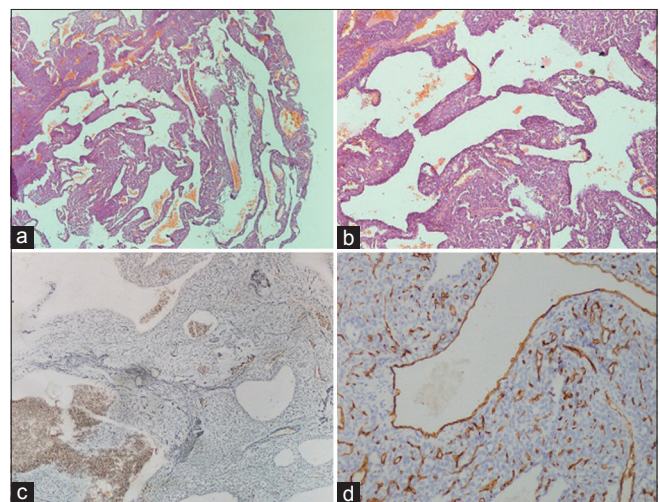


Figure 4: (a and b) Microphotograph shows multiple dilated blood vessels of variable dimension lined by single layer of endothelial cells with intervening stromal cells (H and E, ×40); (c) reticulin stain delineating the vessels and stromal cells (Reticulin, ×100); (d) CD34 negative; immunoreactivity not demonstrated by the endothelial cells and the tumor cells (IHC, CD34, ×400)

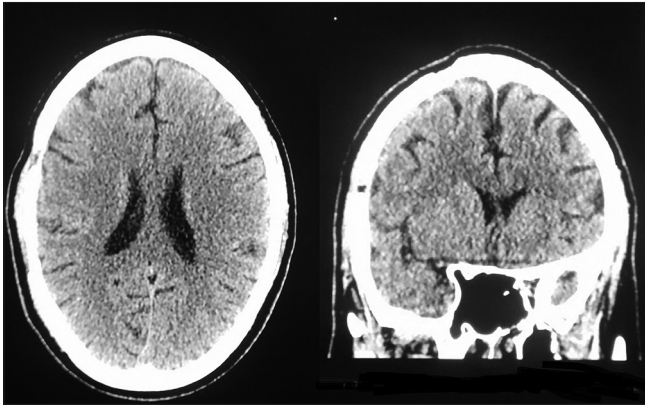


Figure 5: Postoperative computed tomography head showing craniotomy defect, no significant intracranial lesion; axial, coronal view

syndrome.^[16] On reviewing the literature from 1902 to 2014, we found 57 cases of supratentorial HBL without VHL as shown in Table 1.^[6,8,9,15,17-65] On reviewing the literature, we found that supratentorial HBL affected patients ranging from 3 months to 80 years with maximum cases belonging to 20–30 years and 40–50 years age group. Among the infants, only one case was found, thus making it a rare tumor in infancy. Most of the cases were found in males. The reported cases either presented as isolated or multiple lesions. On analyzing the tumor consistency, we found most of them were solid whereas only less than one-third were cystic. In this review, we found supratentorial HBL in various locations viz., frontal, parietal, temporal, occipital, third ventricle, lateral ventricle, pituitary, pituitary stalk, suprasellar, hippocampus, falx cerebri, corpus callosum, meninges, and choroidal fissure.

In HBLs, first and second peaks of incidence are in the third and fifth decades of life respectively. HBLs are more common in males than in females (1.3:1 ratio). They may be either asymptomatic or symptomatic.^[3]

Clinical characteristics of supratentorial HBL are specific to their location and growth patterns.^[66] They are benign lesions thus sign, and symptoms manifest late.^[66] Patients usually have no history or the long history of minor neurological symptoms. In maximum cases, it presents as sudden onset of neurological symptoms demanding neurosurgical intervention.^[61]

Interestingly, HBLs are the only brain tumors associated with polycythaemia, which is encountered in 9–20% of intracranial tumors, which is not seen with spinal lesions. Polycythaemia is due to unregulated secretion of erythropoietin which is an alpha globulin or similar substance by the neoplastic tissue.^[67] Perks *et al.* in 1976 reported the first case of polycythaemia associated with supratentorial HBL although its association with infratentorial HBLs is well known.^[29,68,69]

In supratentorial HBLs, cyst formation seems to be independent of tumor size.^[16] In this, peritumoral cysts which originate from peritumoral edema^[69] occur more frequently in regions

demonstrating anatomic barriers (grey–white matter interface, ventricles) such as the hippocampal region and the basal ganglia.^[16] Vasogenic edema diffuses along white-matter tracts and optic system. Edema develops by the diffusion of plasma ultrafiltrate to surrounding brain. The larger volume of cerebrum provides space for edema formation. Cyst develops as an excess of absorptive capacities of the surrounding tissue.^[16] Whether cyst in HBL is intratumoral or peritumoral, it is due to vascular leakage because protein content of cyst fluid and blood serum are similar.^[70] Cyst formation is less frequent in the supratentorial region compared with the posterior fossa, and extended areas of edema occur with small tumors as the cerebrum offers a bigger volume for edema diffusion compared to cerebellum.^[16]

Hemangioblastomas occur either as a part of VHL disease (inherited mutation of VHL gene on 3p25–26 chromosome) or as sporadic tumors (often with somatic mutation of VHL gene). In both settings, activation of the VHL-hypoxia inducible factor-1 (HIF-1) pathway is thought to be important in tumor biology.^[71] The VHL gene product pVHL is a master regulator of HIF-1 alpha (HIF-1 α). pVHL is involved in the inhibition of HIF-1 α by ubiquitin mediated proteosomal degradation. Due to mutation, pVHL cannot degrade HIF-1 α , causing it to accumulate. HIF-1 α causes the production of vascular endothelial growth factor (VEGF), platelet derived growth factor B (PDGF), erythropoietin, and transforming growth factor alpha, which act to stimulate the growth of cells within the tumor.^[72] Overproduction of hypoxia inducible factor and its target gene products such as VEGF-2 protein induces recruitment of abundant reactive vascular cells into the tumor and, therefore, seems to be responsible for hypervascularity of these lesions.^[73,74]

On histology, these tumors are benign, highly vascular, and composed of stromal cells and vessels. The vascular component consists of small capillaries with a single layer of plump, uniform endothelial cells, whereas the cellular component is characteristic of large and vacuolated stromal cells. Based on the abundance of the stromal cell component, it has been subclassified into two variants: The rarer cellular HBLs defined by zellballen-like cellular clusters of uniform tumor cells, and the more common reticular subtype showing abundant capillaries and stromal cells that may be glial fibrillary acidic protein-immunoreactive leading to erroneous glioma diagnosis.^[61,70,75,76] Histological differential diagnosis of HBL includes metastatic renal cell carcinoma and angiomatous meningioma.^[60] Intratumoral blood cells island formation on morphology indicates extramedullary hematopoiesis.^[75,76]

Radiological imaging by CT scan shows tumor as well circumscribed solid or cystic lesion with a mural nodule.^[77] Usually, the nodule is smaller than the cyst that helps to differentiate it from cystic astrocytoma, which has a larger nodule. CT can detect the tumoral pseudocyst as higher

Table 1: Reported cases of supratentorial hemangioblastoma without VHL

Author	Age/sex	Year	Supratentorial location	Gross
Bielschowsky ^[9]	24/female	1902	Frontal	Solid
Berger and Guleke ^[17]	24/male	1927	Parietal	Cystic
Schley ^[18]	48/female	1927	Occipital	Cystic
Marriot ^[19]	NA	1936	Posterior part of the corpus callosum	Solid
Zeitlin ^[20]	54/male	1942	Meningeal parasagittal	Solid
Kautzky and Vierdt ^[21]	55/male	1953	Right cerebrum-occupied thalamus, globus pallidus, basal surface of brain	Solid
Floris <i>et al.</i> ^[22]	32/male	1954	Frontal	Solid
Grattarola ^[23]	18/male	1955	Temporal	Cystic
Morello and Bianchi ^[24]	10/male	1958	Temporal	Solid
Stein <i>et al.</i> ^[25]	49/male	1960	Temporal	Solid
Stein <i>et al.</i> ^[25]	12/female	1960	Frontal	Cystic
Morello and Bianchi ^[24]	27/male	1960	Parieto-occipital	Solid
Papo <i>et al.</i> ^[26]	NA	1961	Frontal	NA
Morello and Bianchi ^[24]	27/male	1960	Parieto-occipital	Solid
Rivera and Chason ^[27]	16/male	1966	Meningeal parietal	Solid
Ishwar <i>et al.</i> ^[28]	62/female	1971	Meningeal falx, occipital	Solid
Perks <i>et al.</i> ^[29]	21/female	1976	Frontal	Highly vascular
Grisoli <i>et al.</i> ^[30]	28/female	1984	Pituitary stalk	NA
Katayama <i>et al.</i> ^[31]	NA	1987	Third ventricle	NA
Neuman <i>et al.</i> ^[32]	35/female	1989	Pituitary stalk	NA
Black <i>et al.</i> ^[33]	15/male	1991	Third ventricle	Solid
Sharma <i>et al.</i> ^[8]	72/male	1995	Meningeal Parietal	Solid
Kachhara <i>et al.</i> ^[34]	57/female	1998	Sella sphenoid sinus	NA
Choi <i>et al.</i> ^[35]	26/female	1998	Meningeal parietal	Solid
Isaka <i>et al.</i> ^[36]	47/female	1999	Third ventricle	Solid
Tarantino <i>et al.</i> ^[37]	female	2000	Cerebral	-
Yamakawa <i>et al.</i> ^[38]	17/male	2000	Parietal	Cystic
Kim <i>et al.</i> ^[39]	45/male	2001	Meningeal convexity, frontal	Solid
Ikeda <i>et al.</i> ^[40]	62/male	2001	Suprasellar	
Ozveren <i>et al.</i> ^[41]	40/female	2001	Right supratentorial lesion near the splenium	Solid lesion with cystic component
Acikalin <i>et al.</i> ^[6]	43/male	2003	Frontal	Cystic
Rumboldt <i>et al.</i> ^[42]	60/male	2003	Sellar suprasellar	
Agostinelli <i>et al.</i> ^[43]	10/female	2004	Meningeal convexity, frontal	Solid
Iyigun <i>et al.</i> ^[44]	61/male	2004	Meningeal Convexity, frontal	Solid
Peker <i>et al.</i> ^[45]	54/male	2005	Suprasellar	
Tekkök and Sav ^[46]	18 maleonths/female	2006	Lateral ventricle	Cystic
Cosar <i>et al.</i> ^[47]	50/male	2006	Meningeal parasagittal, parietal	Solid
Ohata <i>et al.</i> ^[48]	27/female	2006	Hippocampus	Solid
Murali <i>et al.</i> ^[49]	57/male	2007	Meningeal parasagittal	Solid
Sherman <i>et al.</i> ^[50]	52/female	2007	Meningeal convexity, frontal	Solid
Jang ^[51]	68/female	2007	Meningeal convexity, frontal	Solid
Takeuchi <i>et al.</i> ^[52]	58/male	2008	Meningeal parasagittal, frontal	Solid
Jaggi <i>et al.</i> ^[53]	30/male	2009	Third ventricle	Solid
Peyre <i>et al.</i> ^[54]	3 months/male	2009	Lateral ventricle	Cystic
Elguezabal <i>et al.</i> ^[55]	67/female	2010	Meningeal falx frontal	Solid-cystic
Crisi <i>et al.</i> ^[56]	-	2010	Hippocampus	-
Schär <i>et al.</i> ^[57]	80/female	2011	Pituitary	
Yang <i>et al.</i> ^[58]	19/female	2011	Temporal-occipital lobe	Solid-cystic
Kaloostian and Taylor ^[59]	49/female	2012	Meningeal falx frontal	Solid
Sarkari and Agrawal ^[60]	45/female	2012	Midline basifrontal	Solid
She <i>et al.</i> ^[61]	60/female	2013	Cerebral falx	Mainly cystic with solid component within
She <i>et al.</i> ^[61]	24/male	2013	Temporal, choroidal fissure	Solid

Contd...

Table 1: Contd...

Author	Age/sex	Year	Supratentorial location	Gross
She <i>et al.</i> ^[61]	21/male	2013	Frontal	Cystic
Kishore <i>et al.</i> ^[62]	50/male	2013	Parietal	Cystic with peripheral solid nodule
Al-Najar <i>et al.</i> ^[63]		2013	Lateral ventricle	
Xie <i>et al.</i> ^[64]	64/female	2013	Suprasellar	Solid
Raghava <i>et al.</i> ^[65]	50/male	2014	Frontal	Solid
Present study	39/male	2015	Parietal	Cystic

NA – Not available; VHL – Von Hippel–Lindau

density than that of the cerebrospinal fluid, while the nodule is isodense compared with the cerebral white matter. Following intravenous administration of the contrast agent, the nodule typically enhances intensely, whereas the cystic component, generally, does not enhance. Multiplanar CT and magnetic resonance imaging (MRI) helps in identifying the subpial localization as the nodule usually abuts the pial surface.

MRI is preferred as it has high resolution and sensitivity. The most common finding on MRI is significantly enhancing mural nodule with an adjacent nonenhancing smooth cyst. On gadolinium T1-weighted images, the tumor nodule enhances markedly and homogeneously, while the cystic part is hyperintense on T2-weighted images without enhancement. On angiography, a highly vascular tumor within the avascular cyst and feeding vessels directed from the dural arteries is seen.

Proton MRS studies show high mobile lipids (Lip) peaks between 0.9 and 1.4 ppm with no lactate peak, low creatine/phosphocreatine peak, increased, choline-containing compounds in HBL. The absence of N-acetylaspartate peak indicates the nonneurogenic origin of the tumor.^[74] Combined with the absence of the necrotic component on MRI, presence of Lip peak on proton MRS is hypothesized to be one of the characteristics of HBL. These unique results of proton MRS can play an important role in the differential diagnosis of intracranial HBL.^[78]

According to the World Health Organization classification of CNS tumors, HBL is considered as Grade I meningeal neoplasm of uncertain origin.^[79] Although benign they cause a mass effect on tumor growth, cyst formation, and peritumoral edema. Thus, surgical resection is the treatment of choice. Mural nodule in tumor must be completely excised to avoid cyst recurrence. Resection of the tumor may be difficult due to hypervascularity of the nidus and location of the tumor.^[80] To reduce severe bleeding in tumors located in eloquent locations like medulla and brainstem, presurgical endovascular embolization of the solid component of the tumor, has been tried but has its own complications such as brain ischemia, subarachnoid haemorrhage, and intratumoral haemorrhage.^[81]

Stereotactic radiosurgery tumor using either a linear accelerator or a Gamma Knife has also been attempted.^[80,82,83]

In a study by Sayer *et al.*, which included patients treated with Gamma Knife radiosurgery (GKRS), 15% tumors were stable in volume, 54% decreased, and 31% increased. Local tumor control rates at 1, 5, and 10 years was 89%, 74%, and 50%, respectively. There was a trend toward tumor progression in sporadic patients ($P = 0.10$), women ($P = 0.09$), and larger tumors ($P = 0.10$). In patients with multiple HBLs as compared to those with only a solitary HBL, the radiosurgically treated lesion was 7.9 times more likely to progress after GKRS treatment ($P = 0.018$). They concluded that stereotactic radiosurgery offers a reasonable rate of tumor control and preservation of neurologic function in patients with HBLs, but patients with multiple HBLs are less likely to exhibit long-term tumor control of treated lesions following radiosurgery.^[84]

Antiangiogenic treatment employing VEGF inhibitors may represent a new treatment option. In cases with unresectable lesions, where alternative treatment options such as radiotherapy and chemotherapy fail to produce significant responses, antiangiogenic treatment has been attempted.^[85] High levels of VEGF in clinical samples provide the basis for the use of specific antiangiogenic treatment of HBL targeting VEGF signaling. Schuch *et al.* used antiangiogenic therapy with SU5416, a small molecule inhibiting receptor tyrosine kinases such as the VEGF receptor kinase domain region and the PDGF receptor and found that soon after the start of treatment, paresis resolved and preexisting hypesthesia and dysesthesia in decreased.^[85] Treatment of VHL-associated HBLs with SU5416 has been reported on a series of three patients^[86] where the follow-up of 3 months was too short to evaluate therapeutic success. Another report described a stable clinical remission in one patient with VHL disease and optic nerve HBLs treated with SU5416 over a period of 18 months.^[87]

However, which treatment modality is most definitive in supratentorial HBL is not yet known because of the rarity of this tumor and available literature. MRI is recommended as regular follow-up for sporadic supratentorial HBL. Complete resection of hemangioblastoma is curative and is associated with minimum morbidity and 2% mortality.^[3]

Conclusion

Supratentorial HBL is a rare and benign neoplasm with a favorable prognosis. Being a rare entity, not much clinical

data is currently available regarding supratentorial HBL, thus necessitating the need for further reporting, research, and review of such cases.

Financial support and sponsorship

Nil.

Conflicts of interest

There are no conflicts of interest.

References

- Vortmeyer AO, Gnarr JR, Emmert-Buck MR, Katz D, Linehan WM, Oldfield EH, *et al.* von Hippel-Lindau gene deletion detected in the stromal cell component of a cerebellar hemangioblastoma associated with von Hippel-Lindau disease. *Hum Pathol* 1997;28:540-3.
- Browne TR, Adams RD, Roberson GH. Hemangioblastoma of the spinal cord. Review and report of five cases. *Arch Neurol* 1976;33:435-41.
- Hussein MR. Central nervous system capillary haemangioblastoma: The pathologist's viewpoint. *Int J Exp Pathol* 2007;88:311-24.
- Greenberg MS. Tumor. In: *Handbook of Neurosurgery*. 7th ed New York: Thieme Publisher; 2010. p. 582-768.
- Kepes JJ, Slowik F. Arvid Lindau's cerebellar hemangioblastoma 70 years later. Some pediatric aspects. *Ann N Y Acad Sci* 1997;824:112-23.
- Acikalin MF, Oner U, Tel N, Pasaoglu O, Altinel F. Supratentorial hemangioblastoma: A case report and review of the literature. *Arch Pathol Lab Med* 2003;127:e382-4.
- Mills SA, Oh MC, Rutkowski MJ, Sughrue ME, Barani IJ, Parsa AT. Supratentorial hemangioblastoma: Clinical features, prognosis, and predictive value of location for von Hippel-Lindau disease. *Neuro Oncol* 2012;14:1097-104.
- Sharma RR, Cast IP, O'Brien C. Supratentorial haemangioblastoma not associated with von Hippel Lindau complex or polycythaemia: Case report and literature review. *Br J Neurosurg* 1995;9:81-4.
- Bielschowsky M. For Histology and Pathologic the Gehirngeschwülste. *Dtsch Z Nervenheilkd* 1902;22:54-99.
- Iplikcioglu AC, Yaradanakul V, Trakya U. Supratentorial haemangioblastoma: Appearances on MR imaging. *Br J Neurosurg* 1997;11:576-8.
- Richmond BK, Schmidt JH 3rd. Congenital cystic supratentorial hemangioblastoma. Case report. *J Neurosurg* 1995;82:113-5.
- Latif F, Tory K, Gnarr J, Yao M, Duh FM, Orcutt ML, *et al.* Identification of the von Hippel-Lindau disease tumor suppressor gene. *Science* 1993;260:1317-20.
- Wait SD, Vortmeyer AO, Lonser RR, Chang DT, Finn MA, Bhowmick DA, *et al.* Somatic mutations in VHL germline deletion kindred correlate with mild phenotype. *Ann Neurol* 2004;55:236-40.
- Lonser RR, Glenn GM, Walther M, Chew EY, Libutti SK, Linehan WM, *et al.* von Hippel-Lindau disease. *Lancet* 2003;361:2059-67.
- Neumann HP, Eggert HR, Scheremet R, Schumacher M, Mohadjer M, Wakhloo AK, *et al.* Central nervous system lesions in von Hippel-Lindau syndrome. *J Neurol Neurosurg Psychiatry* 1992;55:898-901.
- Peyre M, David P, Van Effenterre R, François P, Thys M, Emery E, *et al.* Natural history of supratentorial hemangioblastomas in von Hippel-Lindau disease. *Neurosurgery* 2010;67:577-87.
- Berger, Guleke. About Brain tumors and their surgical treatment. *Dtsch Z Chir* 1927;203-204:104-67.
- Schley W. About the occurrence a gehirncysten with simultaneous formation of tumors. *Virchows Arch* 1927;265:665-82.
- Marriotti D. Angioreticuloma of corpus callosum. *Pathologica* 1936;28:1-8.
- Zeitlin H. Hemangioblastomas of meninges and their relation to Lindau's disease. *J Neuropathol Exp Neurol* 1942;1:14-23.
- Kautzky R, Vierdt N. An Angioblastoma of the cerebrum. *Zbl Neurochir* 1953;13:158-63.
- Floris V, Severini P, Castorina G. Angioreticuloma of brain. *Contribution clinical and angiographic. Riv Neurol* 1954;24:642-58.
- Grattarola FR. Hemangioblastoma of the brain. Clinical and anatomical pathology. *Cancer* 1955;8:3-28.
- Morello G, Bianchi M. Cerebral hemangioblastomas: Review of literature and report of two personal cases. *J Neurosurg* 1963;20:254-64.
- Stein AA, Schilp AO, Whitfield RD. The histogenesis of hemangioblastoma of the brain. A review of twenty-one cases. *J Neurosurg* 1960;17:751-61.
- Papo I, Colombo F, Dorizzi A. Considerations about 45 cases of angioreticuloma brain. Historical introduction. *Minerva Neurochir* 1961;5:90-100.
- Rivera E, Chason JL. Cerebral hemangioblastoma. Case report. *J Neurosurg* 1966;25:452-4.
- Ishwar S, Taniguchi RM, Vogel FS. Multiple supratentorial hemangioblastomas. Case study and ultrastructural characteristics. *J Neurosurg* 1971;35:396-405.
- Perks WH, Cross JN, Sivapragasam S, Johnson P. Supratentorial haemangioblastoma with polycythaemia. *J Neurol Neurosurg Psychiatry* 1976;39:218-20.
- Grisoli F, Gambarelli D, Raybaud C, Guibout M, Leclercq T. Suprasellar hemangioblastoma. *Surg Neurol* 1984;22:257-62.
- Katayama Y, Tsukokawa T, Miyagi A, Goto T, Miyagami M, Suzuki K. Solitary hemangioblastoma within the third ventricle. *Surg Neurol* 1987;27:157-62.
- Neumann HP, Eggert HR, Weigel K, Friedburg H, Wiestler OD, Schollmeyer P. Hemangioblastomas of the central nervous system. A 10-year study with special reference to von Hippel-Lindau syndrome. *J Neurosurg* 1989;70:24-30.
- Black ML, Tien RD, Hesselink JR. Third ventricular hemangioblastoma: MR appearance. *AJNR Am J Neuroradiol* 1991;12:553.
- Kachhara R, Nair S, Radhakrishnan VV. Sellar-sphenoid sinus hemangioblastoma: Case report. *Surg Neurol* 1998;50:461-3.
- Choi DH, Kim HS, Mok JH, Kim DH, Lee KC, Lee YB. Supratentorial meningeal hemangioblastoma: Case report. *J Korean Neurosurg Soc* 1998;27:1299-303.
- Isaka T, Horibe K, Nakatani S, Maruno M, Yoshimine T. Hemangioblastoma of the third ventricle. *Neurosurg Rev* 1999;22:140-4.
- Tarantino R, Isidori A, Raco A, Missori P. Supratentorial hemangioblastoma in a patient with breast cancer. A case report. *J Neurosurg Sci* 2000;44:137-9.
- Yamakawa N, Noda M, Ohyama T, Furuno M, Tsutsumi A, Taki W. A cellular variant of supratentorial hemangioblastoma. *Brain Tumor Pathol* 2000;17:15-9.
- Kim HS, Park SH, Cho BM, Kim DH, Oh SM. Supratentorial hemangioblastoma, occurred after total removal of recurrent cerebellar hemangioblastoma – Case report. *J Korean Neurosurg Soc* 2001;30:348-51.
- Ikeda M, Asada M, Yamashita H, Ishikawa A, Tamaki N. A case of suprasellar hemangioblastoma with thoracic meningioma. *No Shinkei Geka* 2001;29:679-83.
- Ozveren MF, Topsakal C, Erol FS, Kaplan M, Uchida K, Tanik C. Tentorial vascularization in solid hemangioblastoma – Case report. *Neurol Med Chir (Tokyo)* 2001;41:201-5.
- Rumboldt Z, Gnjidic Z, Talan-Hranilovic J, Vrkljan M. Intracellar hemangioblastoma: Characteristic prominent vessels on MR imaging. *AJR Am J Roentgenol* 2003;180:1480-1.
- Agostinelli C, Roncaroli F, Galassi E, Bernardi B, Acciarri N, Tani G. Leptomeningeal hemangioblastoma. Case illustration. *J Neurosurg* 2004;101 (Suppl): 122.
- Iyigun OL, Cogluk C, Aydin K, Yildiz L, Rakunt C, Celik F. Supratentorial leptomeningeal hemangioblastoma mimicking a meningioma without von Hippel-Lindau complex. *Turk Neurosurg* 2004;14:25-7.
- Peker S, Kurtkaya-Yapicier O, Sun I, Sav A, Pamir MN. Suprasellar haemangioblastoma. Report of two cases and review of the literature. *J Clin Neurosci* 2005;12:85-9.
- Tekkök IH, Sav A. Supratentorial cystic hemangioblastoma with infratentorial extension – A unique location and a rare infant case. *Childs Nerv Syst* 2006;22:1177-81.

47. Cosar M, Hatiboglu MA, Iplikcioglu AC, Ozcan D. Parasagittal leptomeningeal hemangioblastoma – Case report. *Neurol Med Chir (Tokyo)* 2006;46:294-7.
48. Ohata K, Takami T, Tsuyuguchi N, Hara M, Haque M. Hemangioblastoma of hippocampus without von Hippel-Lindau disease: Case report and review of literature. *Neurol India* 2006;54:89-90.
49. Murali R, Jones WI, Ma Wyatt J. A 57-year-old man with a dural-based parietal lobe tumor. *Brain Pathol* 2007;17:460-3, 474.
50. Sherman JH, Le BH, Okonkwo DO, Jane JA. Supratentorial dural-based hemangioblastoma not associated with von Hippel Lindau complex. *Acta Neurochir (Wien)* 2007;149:969-72.
51. Jang H. Supratentorial leptomeningeal hemangioblastoma: Case report. *Yeungnam Univ J Med* 2007;24:S770-4.
52. Takeuchi H, Hashimoto N, Kitai R, Kubota T. A report of supratentorial leptomeningeal hemangioblastoma and a literature review. *Neuropathology* 2008;28:98-102.
53. Jaggi RS, Preamsagar IC, Abhishek. Hemangioblastoma of the lateral ventricle. *Neurol India* 2009;57:677-9.
54. Peyre M, Di Rocco F, Varlet P, Giraud S, Richard S, Sainte-Rose C, *et al.* Supratentorial hemangioblastoma in the neonatal period. *Pediatr Neurosurg* 2009;45:155-6.
55. Elguezabal A, Diaz ML, Landeyro J, Gené M, Boutayeb L, Escosa M, *et al.* Solid-cystic supratentorial hemangioblastoma affecting the falx cerebri. Report of a case. *Neurocirugia (Astur)* 2010;21:401-4.
56. Crisi G, Giombelli E, Ventura E. Non-von Hippel-Lindau hemangioblastoma in the hippocampus: Characterization with time-resolved MRA using TRICKS sequence at 3T. A case report. *Neuroradiol J* 2010;23:416-9.
57. Schär RT, Vajtai I, Sahli R, Seiler RW. Manifestation of a sellar hemangioblastoma due to pituitary apoplexy: A case report. *J Med Case Rep* 2011;5:496.
58. Yang B, Luan S, Cao X, Bao W. Supratentorial hemangioblastoma. *Neurosciences (Riyadh)* 2011;16:150-2.
59. Kaloostian P, Taylor C. Supratentorial dural-based haemangioblastoma in a Native American patient without von Hippel Lindau syndrome. *J Surg Case Rep* 2012;2012:11.
60. Sarkari A, Agrawal D. Midline basifrontal solid hemangioblastoma in non von Hippel Lindau syndrome patient. *J Neurosci Rural Pract* 2012;3:399-401.
61. She DJ, Xing Z, Liu Y, Cao DR. Supratentorial hemangioblastomas: Three case reports and review of the literature. *Clin Neuroradiol* 2013;23:243-7.
62. Kishore PV, Ratnan H, Dharmapuri A, Ravinder T, Srinivas V. Supratentorial hemangioblastoma: A case report and review of literature. *J Chalmeda Anand Rao Inst Med Sci* 2013;6:67-9.
63. Al-Najar M, Al-Hadidy A, Saleh A, Al-Tamimi A, Al-Darawish A, Obeidat F. Sporadic Lateral Ventricular Hemangioblastoma presenting with Intraventricular and Subarachnoid Haemorrhage. *Sultan Qaboos Univ Med J* 2013;13:597-600.
64. Xie T, Zhang X, Hu F, Wang X, Wang J, Yu Y, *et al.* Suprasellar hemangioblastoma mimicking a craniopharyngioma: Result of extended endoscopic transphenoidal approach – Case report. *Neurol Med Chir (Tokyo)* 2013;53:735-9.
65. Raghava M, Joshi U, Mathur A. Hemangioblastoma of cerebral cortex-unusual presentation and review of literature. *Int J Basic Appl Med Sci* 2014;4:165-7.
66. Yasargill MG, editor. Vascular tumors. In: *Microneurosurgery IV B Microneurosurgery of CNS Tumors*. Stuttgart: George Thieme Verlag; 1996. p. 385-97.
67. So CC, Ho LC. Polycythemia secondary to cerebellar hemangioblastoma. *Am J Hematol* 2002;71:346-7.
68. Palmer JJ. Haemangioblastomas. A review of 81 cases. *Acta Neurochir (Wien)* 1972;27:125-48.
69. Lonsner RR, Vortmeyer AO, Butman JA, Glasker S, Finn MA, Ammerman JM, *et al.* Edema is a precursor to central nervous system peritumoral cyst formation. *Ann Neurol* 2005;58:392-9.
70. Crisi G, Filice S, Pertinhez T, Ventura E, Servadei F. *In vivo* and *ex vivo* magnetic resonance spectroscopy in the characterization of hemangioblastoma cyst fluid: Case report. *J Comput Assist Tomogr* 2014;38:29-32.
71. Li M, Song J, Pytel P. Expression of HIF-1 regulated proteins vascular endothelial growth factor, carbonic anhydrase IX and hypoxia inducible gene 2 in hemangioblastomas. *Folia Neuropathol* 2014;52:234-42.
72. Kaelin WG. Von Hippel-Lindau-associated malignancies: Mechanisms and therapeutic opportunities. *Drug Discov Today Dis Mech* 2005;2:225-31.
73. Richard S, Martin S, David P, Decq P. Von Hippel-Lindau disease and central nervous system hemangioblastoma. *Progress in genetics and clinical management. Neurochirurgie* 1998;44:258-66.
74. Chan CC, Vortmeyer AO, Chew EY, Green WR, Matteson DM, Shen DF, *et al.* VHL gene deletion and enhanced VEGF gene expression detected in the stromal cells of retinal angioma. *Arch Ophthalmol* 1999;117:625-30.
75. Rickert CH, Hasselblatt M, Jeibmann A, Paulus W. Cellular and reticular variants of hemangioblastoma differ in their cytogenetic profiles. *Hum Pathol* 2006;37:1452-7.
76. Hasselblatt M, Jeibmann A, Gerss J, Behrens C, Rama B, Wassmann H, *et al.* Cellular and reticular variants of haemangioblastoma revisited: A clinicopathologic study of 88 cases. *Neuropathol Appl Neurobiol* 2005;31:618-22.
77. Available from: <http://www.emedicine.medscape.com/article/340994-overview>. [Last accessed on 2015 Jun 02].
78. Isobe T, Yamamoto T, Akutsu H, Anno I, Shiigai M, Zaboronok A, *et al.* Proton magnetic resonance spectroscopy findings of hemangioblastoma. *Jpn J Radiol* 2010;28:318-21.
79. Louis DN, Ohgaki H, Wiestler OD, Cavenee WK, Burger PC, Jouvet A, *et al.* The 2007 WHO classification of tumours of the central nervous system. *Acta Neuropathol* 2007;114:97-109.
80. Takeuchi S, Tanaka R, Fujii Y, Abe H, Ito Y. Surgical treatment of hemangioblastomas with presurgical endovascular embolization. *Neurol Med Chir (Tokyo)* 2001;41:246-51.
81. Sakamoto N, Ishikawa E, Nakai Y, Akutsu H, Yamamoto T, Nakai K, *et al.* Preoperative endovascular embolization for hemangioblastoma in the posterior fossa. *Neurol Med Chir (Tokyo)* 2012;52:878-84.
82. Chang SD, Meisel JA, Hancock SL, Martin DP, McManus M, Adler JR Jr. Treatment of hemangioblastomas in von Hippel-Lindau disease with linear accelerator-based radiosurgery. *Neurosurgery* 1998;43:28-34.
83. Pan L, Wang EM, Wang BJ, Zhou LF, Zhang N, Cai PW, *et al.* Gamma knife radiosurgery for hemangioblastomas. *Stereotact Funct Neurosurg* 1998;70 Suppl 1:179-86.
84. Sayer FT, Nguyen J, Starke RM, Yen CP, Sheehan JP. Gamma knife radiosurgery for intracranial hemangioblastomas – Outcome at 3 years. *World Neurosurg* 2011;75:99-105.
85. Schuch G, de Wit M, Höltje J, Laack E, Schilling G, Hossfeld DK, *et al.* Case 2. Hemangioblastomas: Diagnosis of von Hippel-Lindau disease and antiangiogenic treatment with SU5416. *J Clin Oncol* 2005;23:3624-6.
86. Richard S, Croisille L, Yvart J, Casadevall N, Eschwège P, Aghakhani N, *et al.* Paradoxical secondary polycythemia in von Hippel-Lindau patients treated with anti-vascular endothelial growth factor receptor therapy. *Blood* 2002;99:3851-3.
87. Aiello LP, George DJ, Cahill MT, Wong JS, Cavallerano J, Hannah AL, *et al.* Rapid and durable recovery of visual function in a patient with von Hippel-Lindau syndrome after systemic therapy with vascular endothelial growth factor receptor inhibitor su5416. *Ophthalmology* 2002;109:1745-51.