

## Case Report

### Scabies Crustosa in a Patient with Insufficiencia Renalis-Case Report

\*Antigona Begolli Gerqari<sup>1</sup>, Mybera Ferizi<sup>1</sup>, Sadije Halimi<sup>1</sup>, Ilir Begolli<sup>2</sup>, Mirije Begolli<sup>2</sup>, Idriz Gerqari<sup>3</sup>

<sup>1</sup>Dermatology Clinic, University Clinical Center of Kosovo

<sup>2</sup>AAB University-Prishtina

<sup>3</sup>Nuclear Medicine Department, University Clinical Center of Kosovo

\*Corresponding author: Dr Antigona Begolli Gerqari, E-mail: antigonagerqari@gmail.com

(Received 09 Oct 2019; accepted 31 Dec 2021)

---

#### Abstract

**Background:** Scabies is caused by the parasite *Sarcoptes scabiei*. The disease was first described in ancient Greece, while Ferdinand Von Hebra described the stages of development of the arthropodite from the egg to larvae and the adult form of sarcoptosis. The final stage is characterized by the travel of the female parasite and the laying of eggs in stratum corneum and followed by the death of the causer. The main characteristic symptom of scabies is relentless pruritus which is a result of such an infestation inside the skin, as the body reacts to parasites and their excretions, where mites burrow and lay eggs.

**Methods:** Here we present the 85-year-old patient with scabies crustosa, latent diabetes and renal insufficiency.

**Results:** Persistent pruritus and scabies rash, where large numbers of mites were detected, was left untreated and further progressed into sores due to scratching. Weakened immunity and chronic illness in the patient resulted in a more severe form of the disease which was diagnosed as scabies crustosa. After treatment with a supplemented antiscabiotic regimen, the patient remained symptom free.

**Conclusion:** Large population movements, one of the main factors of spread and frequent incidence of scabies, contact with the sick, hygiene means, exchange of wardrobes, sharing bed with the sick, schools, preschools, old-age-care institutions and hospitals, enable spread of the disease. In addition, severe types of scabies that form thick crusts on the skin and present with pruritus as a symptom should be considered in immunocompromised and elderly patients with renal insufficiency where pruritus is also prevalent.

**Keywords:** Scabies crustose; Pruritus; *Sarcoptes scabiei*

---

## Introduction

Scabies is a parasitic infectious disease caused by the parasitic mite *Sarcoptes scabiei* (Acari: Sarcoptidae) (1). Disease in humans is usually caused by *Sarcoptes scabiei hominis*, the parasitic itch mite that burrows in the epidermis. The female of the parasite has a size of 0.4 x 0.3 mm and the male 0.2 x 0.15 mm. In the skin, the female parasite opens canals where she lays 10 to

25 eggs, and after which the parasite dies. The egg develops into nymph octopode scabies, then into hexapod larvae and after approximately 2–3 weeks develops into an adult parasite by resuming the cycle (1-2). Copulation is performed in places where the skin has dents and wrinkles.

Excretions and decomposing bodies of the parasite provide the characteristic

appearance of type IV immunological reactions, accompanied with pruritus and scratching symptoms which become even more pronounced in cases of superinfections with other pathogens and skin eczema. Scabies crustosa (*Scabies Norvegica*) is the most advanced condition of scabies in patients with reduced sensitivity, such as damaged nerves in syphilis, leprosy, neuropathy of various forms, as well as in immunodeficient persons such as AIDS patients. The clinical picture is abundant with dry and thick crusty skin in different parts with a tendency towards enlargement throughout the body. The number of parasites is large and the conformability is high. Treatment consists of the application of antiscabiotics in the form of sulphur in cream, Peruvian balm and permethrin cream as well as in resistant cases and scabies crustosa, particularly ivermectin administered orally (3). In practise, topical application of medication (cream) is recommended to all family members who have been in contact with the severely affected patients to prevent recurrence and spread. European guidelines suggest first-line treatment with permethrin 5% cream with two additional treatments with a pause of one week apart in order to destroy mature forms of larvae (3-4).

## Case Presentation

We present the case of an 85-year-old patient with renal insufficiency, latent diabetes and post-cerebral stroke presenting with intensive pruritus. The patient was admitted to the clinic due to obtuse thick skin layers on the hands and body (Figs. 1 and 2), follicular papules and excoriation. Itching was obvious. The patient had been treated for three months for symptomatic pruritus based on previous history of latent diabetes and unidentified kidney problems.

The obtained laboratory test results in the clinic were as follows: Glycemia 7.8, erythro sedimentation rate 50, urea 20.44 (maximal reference value 8.30), creatinine 206.2 (maximum reference value 100), AST 52 (maximal reference value 37)

and CRP 29 (maximal reference value 6). Full blood count results were without pathological deviations, FPSA 0.215 (normal) and IgE 2500 (maximum reference value 100). Staphylococci were isolated from the swab of the skin, while upon admission microscopy revealed *Sarcoptes scabiei* mites (Figs. 3 and 4). We consulted an infectiologist, a nephrologist, a cardiologist and a haematologist. In consultation with the nephrologist and after routine review of creatinine clearance and kidney scintigraphy, the nephrologist detects renal insufficiency, while the infectiologist diagnoses secondary infection with Cephalosporin susceptible strain of *Staphylococcus aureus*.

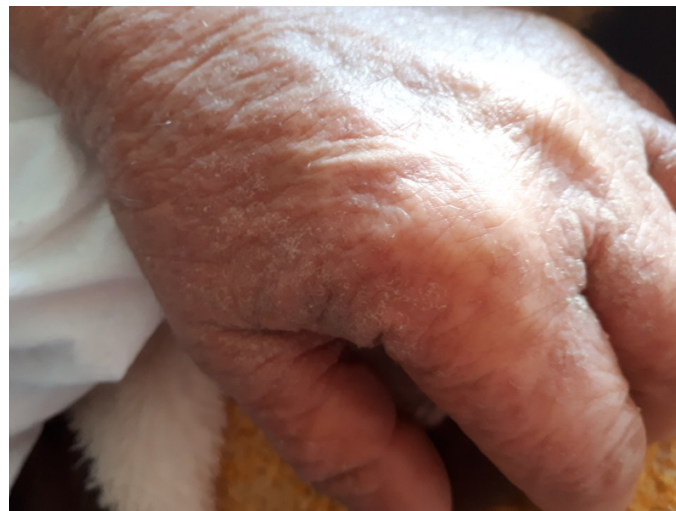To exclude chronic haematological diseases accompanied with chronic intensive pruritus, we performed a peripheral blood smear test which resulted in normal appearance. During the patient's stay in our clinic, we treated her with antibiotics (Cephalosporin ampule) and antihistaminic with antiscabiotic - sulphur precipitate 15%, while the inflamed surfaces were treated with fusidic acid antibiotic cream and corticosteroid creams applied on eczemaic areas. After treatment, the patient was discharged and continued treatment by a nephrologist. During the patient's treatment for scabies, other members of the family were all invited for consultation with the dermatologist and were also treated with antiscabiotic. The patient responded very well to 15% precipitated sulphur that allowed the convenience of not initiating oral ivermectin to begin with. During the patient's check-ups, the patient presented with a few post-inflammatory hyperpigmentations, without itching symptoms or re-appearance of the disease.

## Discussion

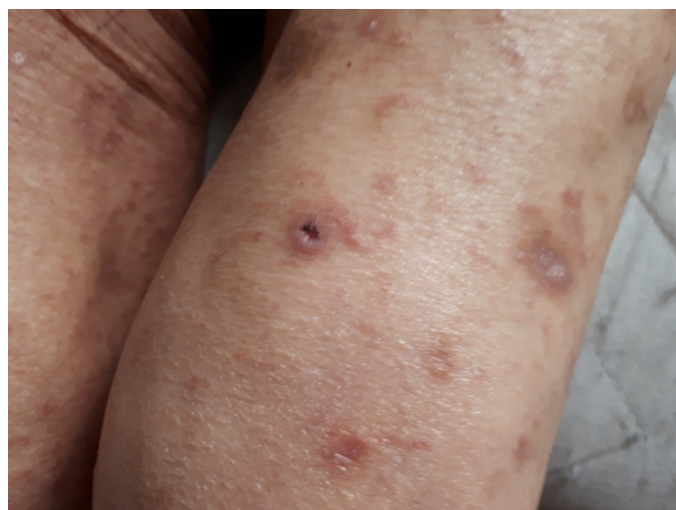Scabies is a frequent parasitic infectious disease with the main symptoms of persistent pruritus due to large numbers of mites in the skin (1, 5). Characteristic is the relentless itching during the night. However, it is not unusual for itching to also

persist during the day, particularly during changes in the weather to warmer. The typical skin changes are follicular papules accompanying excoriations that in cases of long-term persistent pruritus can lead to scabies rash, pimples, blisters and pus. The severe form of the disease develops in immunocompromised individuals and elderly patients. Diagnosis of the disease is done through a typical clinical picture and anamnesis of the disease (2, 6). In the native skin preparation in untreated or poorly treated cases, we can observe the presence of the *Sarcoptes scabiei* and/

or its damaged and degraded parts (Figs. 3 and 4). The treatment consists in the application of antiscabiotic (3-4), whereas per European guidelines topical Permethrin 5% (first-line treatment) is recommended (7). Sulphur in neutral creams is also suggested in uncomplicated cases, while in crust and resistant forms of scabies the drug of choice is considered ivermectin (7) taken orally. In pyodermized and eczematous extreme cases in order to prevent glomerulonephritic complications, antibiotics are applied according to the scheme and antibiogram (8). Pruritus as



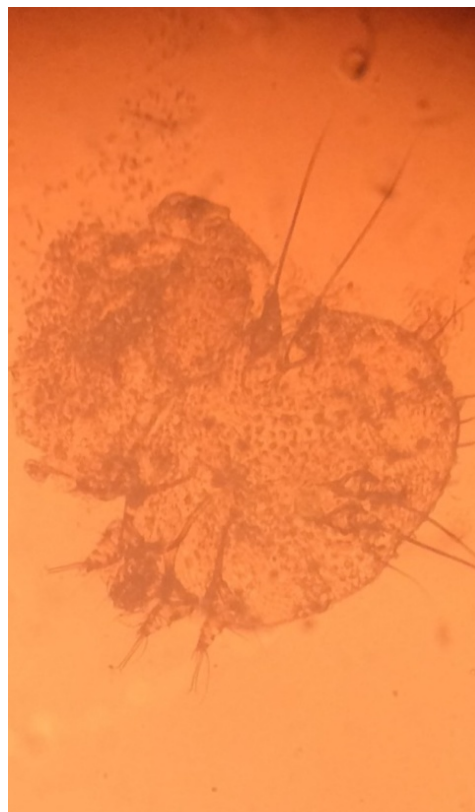
**Fig. 1.** Scabies crustosa presenting with diffuse cutaneous redness and obtuse thick skin layers



**Fig. 2.** Scabies crustosa characterised by areas of scaly rash, hyperkeratotic plaques and crusted skin, involving body and arms



**Fig. 3.** *Sarcoptes scabiei hominis*, the human parasitic itch mite (material taken from the patient)



**Fig. 4.** *Sarcoptes scabiei* dead form observed by microscopy (taken from the crust of the same patient)

a symptom may accompany various other diseases such as melanoma, lymphoma and leukosis, especially diabetes and renal insufficiency (9-10), which can be disorienting when scabies is present. In many situations, the scabies is overlooked, as diagnostics may be outdated, and as a consequence, even more severe forms of development are possible (6, 11). This is more true, for example, in cases of dialysis patients (12) where intensive pruritus is expected (9, 13-14), and therefore may escape the fact that the patient has scabies. In this instance, as a result of non-intentional negligence, the illness may escalate into a micro-epidemic character in the dialysis unit that combined with the poor immune system of the patients allows the possibility of presenting even more severe forms. In conclusion, it is of great importance that in the chronic diseases cases accompanied with pruritus the patient is also tested for scabies. A small commitment in this regard

saves the patient from severe suffering and protects others from possible infections.

### Abbreviations

AIDS: Acquired immune deficiency syndrome; CRP: C reactive protein; Free PSA: Free prostate specific antigen test; IgE: Immunoglobulin E

### Funding

No source of founding to be declared.

### Ethic approval and consent to participate

Not applicable.

### Competing interests

The authors declared that they have no competing interests.

## References

1. Hengge UR, Currie BJ, Jäger G, Lupi O, Schwartz RA(2006) Scabies: a ubiquitous neglected skin disease. *Lancet Infect Dis.* 6(12):769-79.
2. Ramos-e-Silva M (1998) Giovan Cosimo Bonomo (1663–1696): discoverer of the etiology of scabies. *Int J Dermatol.* 37(8):625-30.
3. Salavastru C M, Chosidow O, Boffa M J, Janier M, Tiplica G S (2017) European guideline for the management of scabies. *J Eur Acad Dermatol Venereol.* 31(8):1248-1253.
4. Strong M, Johnstone P (2007) Interventions for treating scabies. *Cochrane Database Syst Rev.* 2007(3):CD000320.
5. Yates JE, Bleyer AJ, Yosipovitch G, Sanguenza OP, Murea M(2013) Enigmatic pruritus in a kidney transplant patient. *Clin Kidney J.* 6(2):194-8.
6. Heukelbach J, Feldmeier H(2006) Scabies. *Lancet.* 367(9524):1767-74.
7. Currie BJ, McCarthy JS(2010) Permethrin and ivermectin for scabies. *N Engl J Med.* 362(8):717-2.
8. Hoy WE, White AV, Dowling A, Sharma SK, Bloomfield H, Tipiloura BT, Swanson CE, Mathews JD, McCredie DA(2012) Post-streptococcal glomerulonephritis is a strong risk factor for chronic kidney disease in later life. *Kidney Int.* 81(10):1026-1032.
9. Pisoni RL, Wikström B, Elder SJ, Akizawa T, Asano Y, Keen ML, Saran R, Mendelssohn DC, Young EW, Port FK(2006) Pruritus in haemodialysis patients: International results from the Dialysis Outcomes and Practice Patterns Study (DOPPS). *Nephrol Dial Transplant.* 21(12):3495-505.
10. Tseng WC, Chu SY, Tarng NC (2011) A neglected cause of pruritus in a hemodialysis patient. *Acta Nephrol.* 25: 209–210.
11. Roberts L J, Huffam S E, Walton S F, Currie B J (2005) Crusted scabies: clinical and immunological findings in seventy-eight patients and a review of the literature. *J Infect.* 50(5):375- 81.
12. Lempert K D, Baltz P S, Welton W A, Whittier F C (1985) Pseudouremic pruritus: a scabies epidemic in a dialysis unit. *Am J Kidney Dis.* 5(2):117-9.
13. Keithi-Reddy S R, Patel T V, Armstrong A W, Singh A K (2007) Uremic pruritus. *Kidney Int.* 72(3):373-7.
14. Patel TS, Freedman BI, Yosipovitch G(2007) An update on pruritus associated with CKD. *Am J Kidney Dis.* 50(1):11-20.