

Cerebrovascular ultrasonography: Technique and common pitfalls

Lokesh Bathala, Man Mohan Mehndiratta¹, Vijay K. Sharma²

Department of Neurology, Narayana Medical College and Hospital, Nellore, Andhra Pradesh, ¹Department of Neurology GB Pant hospital, Delhi, India, ²Division of Neurology, National University Hospital, Singapore

Abstract

Although the clinical features in some patients with cerebrovascular ischemia may be ill defined, majority of the patients present with focal neurological deficits caused by an arterial occlusion, and the clinical presentations are usually referable to the involved arterial territory. Therefore, vascular imaging constitutes an important component of the diagnostic workup. Cervical duplex ultrasonography of carotid and vertebral arteries is employed to evaluate the extracranial vasculature while transcranial Doppler provides important information about intracranial hemodynamic changes in cerebrovascular ischemia. These two components of cerebrovascular ultrasonography are fast and reproducible, and can be performed at the bedside. They provide real-time information about the status of cervico-cranial arterial patency and various hemodynamic alterations, including collateral flow. The information obtained from cerebrovascular ultrasonography is useful for diagnostic as well as prognostic purposes. Furthermore, it can be used to monitor cerebral blood flow for extended periods and aid in decision making for various interventions. The hemodynamic information obtained from cerebrovascular ultrasonography helps in determining the underlying mechanisms of brain ischemia, and is complementary to the clinical examination and other imaging modalities. We describe the technique of performing cervical duplex sonography, diagnostic criteria for arterial stenosis, characterizing plaque morphology, measuring intima-media thickness and various pitfalls while performing the test.

Key Words

Cervical duplex, ischemic stroke, transcranial Doppler, ultrasonography

For correspondence:

Dr. Lokesh Bathala, ASN cert Neurosonology, Department of Neurology, Narayana Medical College and Hospital, Nellore-524002, Andhra Pradesh, India. E-mail: lokeshbdvt@yahoo.co.in

Ann Indian Acad Neurol 2013;16:121-7

Introduction

Stroke is emerging as a major public health problem in India due to improving economy, health standards and life expectancy.^[1] Cervical duplex ultrasonography (CDU) is widely used in patients with cerebrovascular ischemia to screen the extracranial carotid and vertebral occlusive diseases.^[2] CDU is relatively cheap bedside tool that provides real-time information regarding the status of vascular lumen and atherosclerotic burden in major cervical arteries. Information obtained from CDU is complementary to other neuroimaging modalities, and adds physiological information to the anatomical details obtained from the latter. CDU

helps in determining the etiopathogenesis of acute ischemic stroke (AIS) by identifying various steno-occlusive diseases. When performed with transcranial Doppler (TCD), CDU is useful in understanding the hemodynamic consequences of extracranial arterial stenoocclusive disease and selecting the lesions amenable for interventional treatment (LAIT).^[3] CDU may serve as an important tool for evaluating a significant carotid stenosis within 2 weeks of onset of symptoms and aid in therapeutic decision-making.^[4]

Carotid plaque characterization helps in establishing the risk of cerebral ischemic events. CDU can be used to monitor the natural course and progression of arterial stenosis. Thus, CDU is an important tool in the armamentarium of clinicians treating AIS patients. Accordingly, the Brain Attack Coalition group recommends cerebrovascular ultrasonography as an integral component of a comprehensive stroke center.^[5]

The current ultrasound equipments have become more compact and provide excellent image quality. With increasing interest among the stroke neurologists, the concept of an "ultrasound stethoscope" is rapidly moving from the "theory to reality." In this article, we describe the technique of CDU,

Access this article online	
Quick Response Code: 	Website: www.annalsofian.org
	DOI: 10.4103/0972-2327.107723

common carotid artery (CCA)–intima media thickness (IMT) measurement, characterizing plaque morphology and grading of arterial stenosis.

Anatomy of Cervico-Cerebral Arteries

Knowledge of the anatomy of cervical arteries is a prerequisite for successful CDU evaluation. On the right hand side, the brachiocephalic trunk (innominate artery) originates from the aortic arch and bifurcates into right subclavian and CCA. The left CCA and subclavian arteries arise directly from the aortic arch. Carotid bifurcation into internal carotid artery (ICA) and external carotid artery (ECA) usually occurs at the level of the fourth cervical vertebra (Adam's apple in males). However, it may occur at lower (pre-fixed) or higher (post-fixed) levels in some patients. ICA usually arises postero-lateral to the ECA. The proximal part of the ICA often has a focal dilatation (carotid bulb), and it has no branches in the neck. ECA is usually smaller in diameter and can be reliably identified by its branches.

Vertebral artery (VA) originates from the first part of the subclavian artery. VAs are variable in size, and usually one VA is larger in diameter (dominant) as compared with the other side (non-dominant or hypoplastic). From its origin (V_0), VA ascends up in the neck as a free segment (V_1) before entering the transverse foramina of the 6th cervical vertebra. It traverses through the intertransverse segments (V_2) and comes out at the axis vertebra to loop around the atlas vertebra (V_3) before entering into the foramen magnum.

Ultrasound Equipment

Current CDU systems are based on the pulse-echo technique. Pulses of ultrasound waves, produced by the lead zirconium zirconate piezoelectric crystal (PZT), travelling in the tissues produce echoes at different structural boundaries. The transducer generates ultrasound pulses only for a short period (about 1% of the total time) and works as a receiver (ear) for the reflected ultrasound signals for most of the period. The frequency of ultrasound used for clinical imaging ranges from 2 to 15 MHz. Higher ultrasound frequencies are used in the CDU systems to obtain images with better resolution.

Doppler Ultrasound – Basic Principles

“Doppler effect” is responsible for detecting the blood flow (determined by Doppler shift). The Doppler shift may be positive (reflected frequency higher than the transmitted frequency) or negative (reflected frequency lower than the transmitted frequency). Doppler shift is strongly dependent on the angle of insonation, and it is important to maintain an angle of less than 60 degrees to avoid overestimation of the flow velocities at higher angles. Blood in the arteries flows in a laminar fashion, and the spectra of velocities obtained from various layers are represented on the screen by Fast Fourier Transform (FFT).

Ultrasound Imaging Modes

Various ultrasound modes used in the modern imaging systems are:

Brightness mode (B-mode)

Depending on the difference in densities of various tissue layers, ultrasound signals are reflected back with variable strengths and displayed as dots of variable brightness on the screen. The images are made up of 256 shades of gray, called the Gray scale or brightness-mode imaging [Figure 1]. B-mode provides the anatomical details of tissues and helps in evaluating any abnormalities seen within the lumen or on the arterial wall.

Color mode

Blood flow is evaluated with color flow imaging, represented by different shades of red or blue color, determined by the positive and negative Doppler frequency shifts, respectively. Color indicates the flow direction in reference to the transducer (not the direction of blood flow), and the color scheme can be adjusted manually. High-flow velocities lead to flow turbulence and result in a “mixture” of colors of different shades (aliasing). “Aliasing” along a stenosed segment is often a reliable guide to select the optimal place for measuring highest velocities. However, abrupt change in color scheme in an artery or aliasing can also occur along the sharp bends in tortuous arteries due to centripetal force-induced secondary flow^[6] and inappropriate Doppler angle.^[7] “Aliasing” on color-flow can be corrected by increasing the pulse repetition frequency (scale) [Figure 2].

Power doppler

Power Doppler represents blood flow as various shades of a single color. It reflects the strength of the returned echoes [Figure 2]. It is sensitive for detecting the slow flow and evaluating tortuous arteries. However, it lacks the information about flow direction.

Doppler spectra

The Doppler spectral waveform on the FFT reflects the flow speed in various layers within the sample volume (gate). Flow velocities are fastest in the center of the arterial lumen due to the parabolic and laminar flows.

Performing CDU for carotid arteries

Carotid arteries run vertically as “pipes.” For proper evaluation of the arterial walls and the lumen, scanning should be

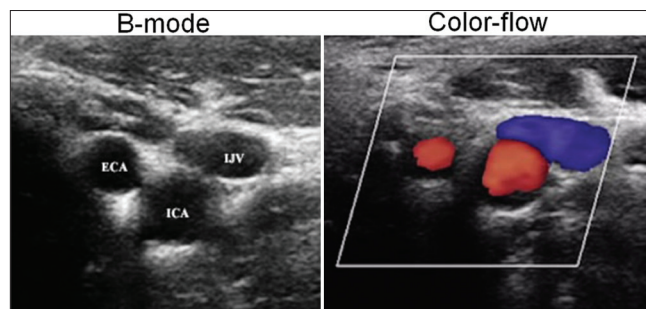


Figure 1: Transverse B-mode and color-flow imaging of carotid artery obtained at the level of carotid bifurcation into internal carotid artery (ICA) and external carotid artery (ECA). Internal jugular vein (IJV) is seen overlying the two. Note the difference in the colors – both ECA and ICA show positive Doppler frequency shift (red), while IJV shows negative Doppler frequency shift (blue)

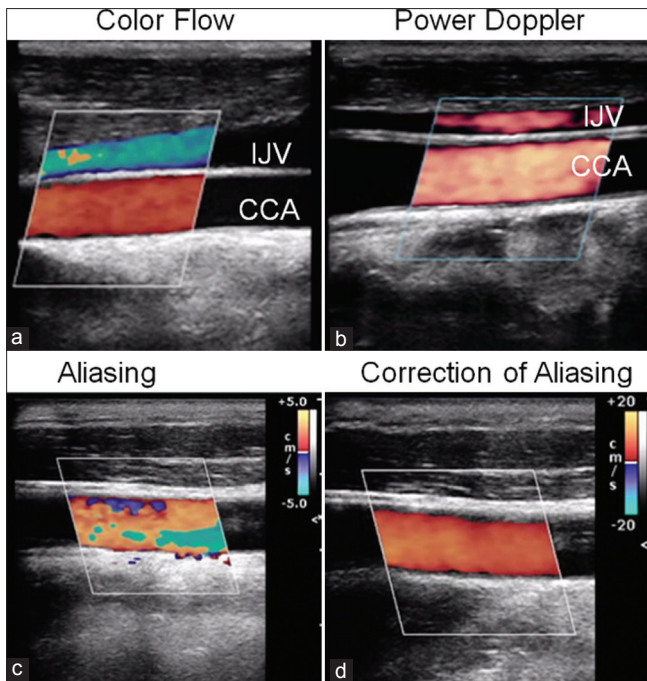


Figure 2: Color flow imaging (a) shows the direction of flow – blue in internal jugular vein (IJV) and red in common carotid artery (CCA). Power Doppler imaging (b) reflects only the strength of signals in one single color. Note that both IJV and CCA show the same color on power Doppler imaging. Note the pulse repetition frequency (PRF) in panel (c) is 5. Increasing PRF to 20 corrects the aliasing artifact as shown in panel (d)

performed in the transverse as well as the longitudinal planes [Figure 3a and 3b].^[8]

Patient Position

Supine position is considered best for performing CDU. The sonographer should preferably sit at the head-end of the patient to avoid any obstruction to the attending medical/paramedical personnel. Hyperextension of the neck is usually not required.

Transverse plane: Transverse plane enables the sonographer to identify the jugular vein, CCA, carotid bulb, carotid bifurcation, ECA and ICA. Start scanning from the most proximal CCA and follow its course to the bifurcation and trace ICA as distally as possible. Transverse scanning provides valuable information about the arterial wall, plaques, arterial patency and the level of carotid bifurcation. It prepares the sonographer to anticipate various important findings as well as technical difficulties during the procedure.

Longitudinal plane: It is essential to visualize the arterial lumen in the longitudinal plane. Again, start scanning from the most proximal CCA and move cephalad. Locate the bifurcation, flow-divider, carotid bulb, ICA and ECA. ICA should be visualized as distally as possible in the neck. Compared with the anterior, the lateral approach is considered better because a longer segment of distal ICA can be evaluated. CCA bifurcation as typical “Y” is usually not visualized as the ICA and ECA overlap each other. ICA and ECA are often evaluated by

the “rocking” movement of the transducer. During B-mode imaging, atheromatous plaques and IMT are also evaluated.

B-mode findings are confirmed by the color mode. Color gain settings may need adjustment to optimize filling of the arterial lumen. Color mode might help in the detection of hypoechoic/isoechoic plaques, often difficult to visualize on B-mode. Fresh blood clots are usually anechoic, appear dark on B-mode and can be detected only with color mode as filling defects. Aliasing, often produced by focal arterial stenosis, helps in locating the site of highest flow velocity. An area of flow reversal in the carotid bulb is a normal finding, occurring due to the opening of a “small pipe (CCA) into a larger pipe (bulb).” Color flow can distinguish ECA from ICA by the presence of branches in the former.

After B-mode and color-flow imaging, Doppler spectra are obtained from a small sample volume, placed in the center of the lumen and maintaining steering angle parallel to the arterial wall. It shows the flow characteristics as well as velocities. Measurements of flow velocities should be avoided at the bends in tortuous arterial segments to avoid overestimation. Doppler spectra and velocities should be obtained from proximal and distal CCA, carotid bulb, proximal and distal ICA and ECA. Additional sampling is performed if stenotic segments are seen.

Doppler spectra reflect peak systolic velocity (PSV) and the end diastolic velocity (EDV). Because cerebral circulation is characterized by significant flow, both during systole and diastole, ICA Doppler spectra demonstrate a “low resistance” pattern (EDV about 30-50% of PSV). ECA supplies the muscular structures of scalp and, hence, shows blood flow predominantly in systole, with a high resistance pattern (EDV less than 25% of PSV). In the event of uncertainty, ECA may be distinguished from ICA by “temporal tapping” maneuver. Doppler spectra obtained from CCA are usually a combination of spectra of ECA and ICA [Figure 3].

Pitfalls

1. The position of the sample volume box in a normal artery should be in the center of the lumen and parallel to the vessel wall, whereas in a diseased vessel (with plaque) it should be aligned parallel to the direction of blood flow.^[6,7]
2. The sample volume box should not be placed on the sharp curves of a tortuous artery, as this may result in a falsely high-velocity reading. It may show changes in the color flow and even aliasing at the bends in the arteries. Do not measure velocities at bends.^[6,7]
3. Proximal CCA spectral waveforms might show very low EDV or diastolic flow reversal in patients with cardiac valvular regurgitant disease.
4. Temporal tapping may differentiate ECA from ICA. However, it should not be used as the sole diagnostic criterion as the tapping may be transmitted into ICA.
5. In ICA occlusion, ECA becomes a collateral pathway for intracranial circulation, and might show a low resistance flow pattern (internalization) and appear like ICA, leading to a serious error.
6. The relationship between carotid stenosis and flow velocities is not linear. A short arterial stenosis produces focal velocity increases on the upslope of the so-called

Spencer's curve of cerebral hemodynamics. However, with progression of the stenosis, flow velocities may even decrease, reflected on the down-slope of the Spencer's curve [Figure 3]^[9]

Carotid Arterial Wall Imaging

Currently available carotid imaging modalities (digital subtraction angiography, magnetic resonance angiography and computerized tomographic angiography) provide information about the arterial lumen only. CDU possesses a unique ability to evaluate the arterial wall as well as the lumen. Two important parameters obtained from carotid wall imaging are CCA-IMT and atheromatous plaques.

CCA-IMT

Increased IMT is considered the earliest sign of carotid atherosclerosis.^[10] It is measured either manually or by in-built software in some ultrasound equipments. IMT is measured on the far wall of distal CCA. Thickness is measured as the distance between lumen/intima interface to the media/adventitia interface [Figure 4].

Several studies have shown a clear association between thickened CCA-IMT and vascular events.^[11,12] Polak *et al.* showed that increased CCA-IMT and presence of plaque in ICA are strong predictors of cardiovascular disease.^[13]

Carotid Plaques

An atheromatous carotid plaque is described as a focal increase in the IMT (more than 1.2 mm). Carotid plaques are described by their composition (echogenicity) and surface.

Plaque Echogenicity

Owing to their different compositions, plaques differ in their echogenicity [Figure 4]. Anechoic region in a plaque represents either a necrotic or hemorrhagic lesion, while the echogenic plaques contain predominantly fibrotic tissue.^[14] Qualitatively, carotid plaques can be classified as Type 1: Hypoechoic or echolucent, with uniform distribution of echoes; Type 2: Hypoechoic or echolucent, with heterogeneous distribution of echoes ($\geq 50\%$ of the plaque is hypoechoic); Type 3: Hyperechoic or echodense, with heterogeneous distribution of echoes ($\geq 50\%$ of the plaque is hyperechoic); Type 4: Hyperechoic or echodense, with homogeneous distribution of bright echoes; and Type 5: Calcified plaque with bright echoes and acoustic shadowing.^[15]

Echogenicity of a plaque should be standardized against three reference structures: flowing blood for anechoic, sternocleidomastoid muscle for isoechogenic and transverse vertebral apophysis for hyperechogenicity.^[16]

Plaque Surface

The plaque is usually covered by a thin hyperintense rim of fibrous tissue, while "ulceration" corresponds to an irregularity or break in its surface. A significant ulceration recess must be at least 2 mm deep and 2 mm long. Carotid plaque surface irregularity/ulceration exposes the thrombogenic layers, leading to thrombus formation and embolisation.

Plaque Morphology and Subsequent Stroke Risk

The pivotal Tromso study showed that echolucent plaques are associated with increased risk of cerebrovascular events independent of the degree of stenosis and other cardiovascular

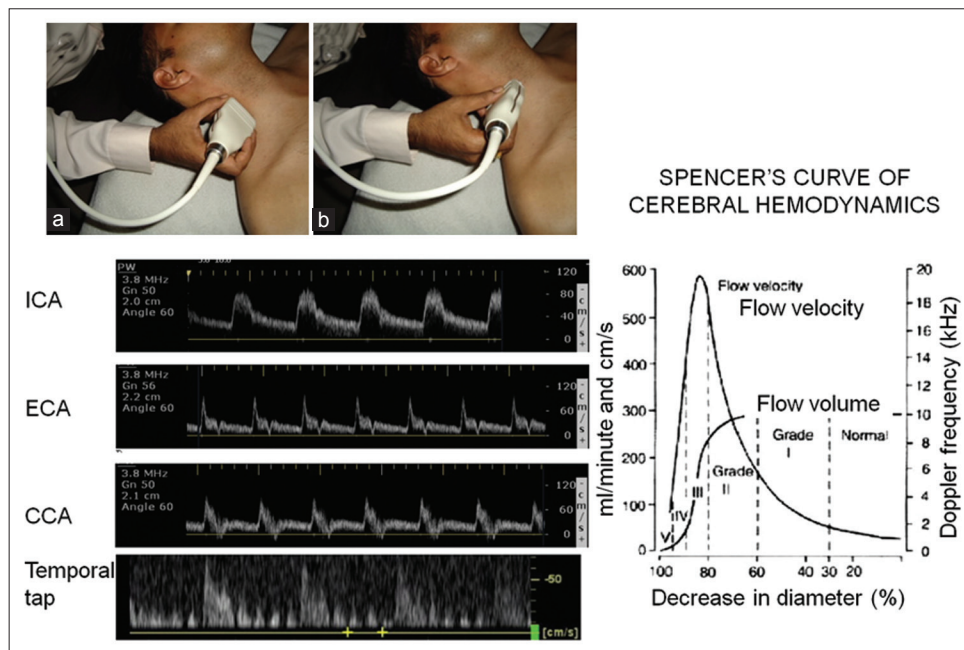


Figure 3: Orientation and position of transducer during the longitudinal (a) and transverse (b) imaging of the carotid arteries. Lower panels show the flow spectral characteristics from internal carotid artery, external carotid artery (ECA) and common carotid artery. ECA can also be identified with temporal tapping maneuver. The right panel shows the Spencer's curve of cerebral hemodynamics. Spencer and Reid showed the correlation between degree of an arterial stenosis, flow velocity and blood flow volume in an axis symmetric flow model

risk factors.^[17] Similarly, hypo- or anechogenic plaques and plaques with complex pattern of echogenicity carry higher risk of cerebrovascular events than echogenic and heterogeneous plaques.^[18]

Performing CDU for Extracranial VAs

In contrast to the carotid arteries, ultrasonographic evaluation of VAs starts from the inter-transverse foramina segments (between 2nd and 6th cervical vertebrae). Identify CCA in longitudinal view, note flow direction and slowly orient the transducer posterolaterally until the shadows of transverse processes are noted. VA runs between these shadows [Figure 5a and b]. VAs are traced proximally to their free segment (V1) and the origin (V0) from subclavian arteries. It is important to visualize the V0, as this segment is a common site for atherosclerosis. Like ICAs, VA flow spectra also show low-resistance waveform profile. However, the flow velocities are generally lower as compared with the carotids.

Grading of ICA Stenosis

ICA stenosis accounts for about 20% of all strokes.^[19] ICA stenosis can cause cerebral ischemia due to thromboembolism, hypoperfusion or a combination of these two phenomena. PSV is the most important parameter to gauge the severity of carotid stenosis. Additional criteria include EDV, spectral configuration and carotid index.

Degree of carotid stenosis is the most important predictor of cerebrovascular events. Duplex imaging is often considered as the primary diagnostic modality for carotid stenosis. The criteria for quantifying carotid stenosis have been derived through comparisons of ultrasonographic findings against contrast arteriography. Diagnosis of an ICA stenosis of 50-99% by CDU has sensitivity and specificity between 90 and 95%.^[20] Current diagnosis and grading of carotid stenosis on CDU is based on the consensus criteria [Table 1].^[21]

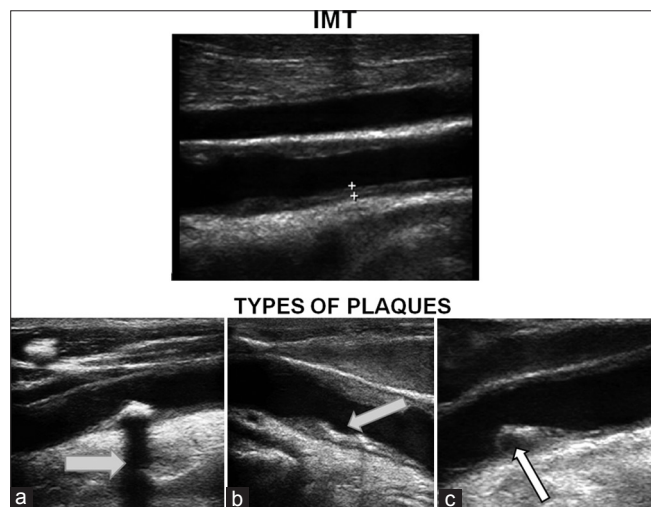


Figure 4: Intima-media thickness (IMT) measurement in common carotid artery (CCA) and various types of plaques. IMT is measured on the far wall in distal CCA. Panel (a) shows a heterogeneous plaque with a shadow artifact (arrow). Panel (b) shows a homogeneous plaque with a possible ulcerated surface. A homogeneous plaque is seen in panel (c) with a dark area within, suggesting intraplaque hemorrhage

CDU can be used to monitor the progression of carotid stenosis in asymptomatic patients. Furthermore, it can also be used to monitor the results of carotid revascularization procedures.

Stenosis of ECA and Vertebral and Subclavian Arteries

Although stenocclusive disease of CCA and ICA contribute the most to cerebrovascular ischemic events, other major cervical arteries may also be involved in some cases.

Carotid bulb is the most common site for the development of atherosclerotic plaques and, in some patients, the plaques may extend into the ECA. PSV of more than 150 cm/s is considered to represent a moderate (more than 50%) stenosis. While embolization from ECA plaques may result in embolic skin and tongue infarcts, hypoperfusion due to a severe stenosis can manifest as jaw or tongue claudication.

VAs are usually variable, with one side larger in diameter (dominant) as compared with the other side. Even the dominant VA might be irregular in diameter during its cervical course. VA origin is the most common site of atherosclerotic stenocclusive disease, and a focally elevated PSV (more than 150 cm/s) represents a moderate stenosis.

Subclavian arteries may also be involved in systemic atherosclerosis. Compared with the left side, the right subclavian artery is reported to be far less commonly affected by atherosclerosis. A blood pressure difference of more than 20 mmHg between the two arms often suggests subclavian artery stenosis. While a mild-to-moderate stenosis

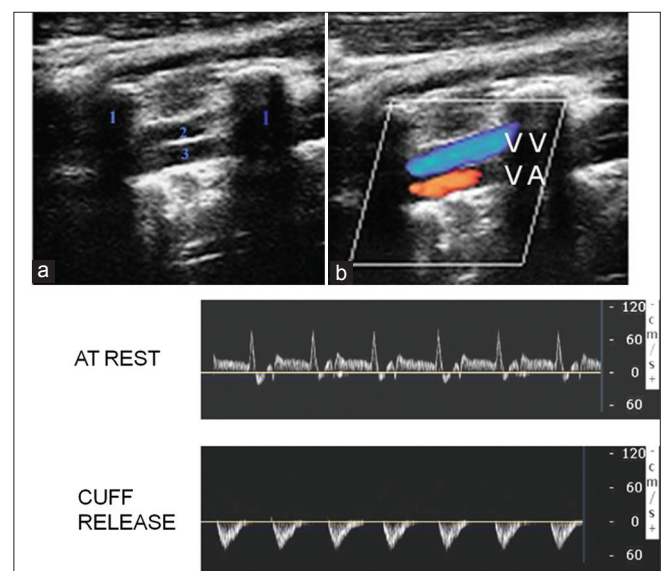


Figure 5: Appearance of vertebral arteries (VAs) on longitudinal imaging. VA runs in between the transverse processes of VAs. Vertebral vein runs parallel to the VA. Lower panels show hyperaemia-ischemia cuff test in a patient with subclavian steal syndrome. Spectra obtained at rest show “to and fro” flow pattern. Note that sudden release of the blood pressure cuff shows complete reversal of flow in the VA

Table 1: Consensus panel: Grayscale and Doppler US Criteria for Diagnosis of ICA Stenosis (Ref²¹)

Degree of stenosis,%	ICA PSV	ICA/CCA PSV ratio	ICA EDV	Plaque
Normal	<125 cm/s	<2.0	<40 cm/s	None
<50%	<125 cm/s	<2.0	<40 cm/s	<50% diameter reduction
50-69%	125-230 cm/s	2.0-4.0	40-100 cm/s	>50% diameter reduction
70% to near occlusion	>230 cm/s	>4.0	>100 cm/s	>50% diameter reduction
Near occlusion	May be low or undetectable	Variable	Variable	A significant detectable lumen
Occlusion	Undetectable	Not applicable	Not applicable	A significant but no detectable lumen

of the subclavian artery is usually asymptomatic, severe stenooclusive disease may cause posterior circulation ischemia. Significant ischemia of the upper extremity is rare even in patients with complete occlusion of the proximal subclavian artery due to various collateral channels. Reversed flow in the ipsilateral VA serves as one of the effective primary collateral pathways for the affected upper extremity, often referred to as subclavian steal syndrome (SSS). Sometimes, on CDU, VA with reversed blood flow and SSS are found in patients without any posterior circulation symptoms.^[22] It has been suggested that patients with SSS who develop symptoms usually have additional intracranial or extracranial vascular obstructions.^[23] Symptoms of cerebral ischemia due to SSS may be precipitated or aggravated in some patients by arm exercise.

Reduced flow resistance due to exercise-induced vasodilation in the upper extremity might result in diversion of cerebral blood flow to critical levels in some patients, rendering them at higher risk of ischemic stroke in the posterior circulation.^[24] This pathophysiological phenomenon forms the basis of performing the hyperaemia-ischemia cuff test in patients with SSS. Accordingly, blood pressure cuff, placed on the arm on the side of SSS, is inflated to about 30 mmHg above the systolic blood pressure to create a transient ischemia. While maintaining the pressure, the patient performs exercise of the hand to induce transient hypoxia. Combination of hypoxia-ischemia induces vasodilatation, creating a low-resistance vascular bed. Intracranial VA is continuously monitored during the test for any change in flow velocities and spectral pattern. Sudden release of the blood pressure cuff may result in transient "rush" of blood into the upper extremity, promoting vertebrosubclavian steal and significant reduction in flow velocities in the vertebrobasilar system. This may be associated with transient posterior circulation ischemia in some cases [Figure 5].

Conclusions

CDU is a quick and reliable bedside tool for the assessment of arterial patency and various stenooclusive lesions responsible for cerebrovascular ischemic events. The information regarding atherosclerotic plaques and intima-media complex can be used for risk stratification of patients with multiple vascular risk factors. Carotid stenosis detected by CDU following an acute stroke guides the treating clinicians to opt for various revascularization procedures urgently. Thus, CDU should be considered as an integral component for the evaluation and management of ischemic stroke patients.

References

1. Das SK, Banerjee TK, Biswas A, Roy T, Raut DK, Mukherjee CS, *et al.* A prospective community-based study of stroke in Kolkata, India. *Stroke* 2007;38:906-10.
2. Latchaw RE, Alberts MJ, Lev MH, Connors JJ, Harbaugh RE, Higashida RT, *et al.* Recommendations for imaging of acute ischemic stroke: A scientific statement from the American Heart Association. *Stroke* 2009;40:3646-78.
3. Chernyshev OY, Garami Z, Calleja S, Song J, Campbell MS, Noser EA, *et al.* Yield and accuracy of urgent combined carotid/transcranial ultrasound testing in acute cerebral ischemia. *Stroke* 2005;36:32-7.
4. Furie KL, Kasner SE, Adams RJ, Albers GW, Bush RL, Fagan SC, *et al.* Guidelines for the prevention of stroke in patients with stroke or transient ischemic attack: A guideline for healthcare professionals from the American heart association/American stroke association. *Stroke* 2011;42:227-76.
5. Alberts MJ, Latchaw RE, Selman WR, Shepard T, Hadley MN, Brass LM, *et al.* Recommendations for comprehensive stroke centers: A consensus statement from the Brain Attack Coalition. *Stroke* 2005;36:1597-618.
6. Bergman HL, Chesler NC, Ku DN, Wootton DM. Hemodynamics and atherosclerosis. In: Hennerici M, Meairs S, editors. *Cerebrovascular ultrasound-theory, practice and future developments*. Edinburgh: Cambridge University press; 2001. p. 134-151.
7. Tahmasebpour HR, Buckley AR, Cooperberg PL, Fix CH. Sonographic examination of the carotid arteries. *Radiographics* 2005;25:1561-75.
8. Neumyer MM, Alexandrov AV. Cerebrovascular anatomy and principles of extracranial ultrasound examination. In: Andrei V. Alexandrov, editors. *Cerebrovascular Ultrasound in Stroke Prevention and Treatment*. 2nd ed. New York: Wiley-Blackwell; 2011. p. 3-16.
9. Spencer MP, Reid JM. Quantitation of carotid stenosis with continuous-wave (C-W) Doppler ultrasound. *Stroke* 1979;10:326-30.
10. Pignoli P, Tremoli E, Poli A, Oreste P, Paoletti R. Intimal plus medial thickness of the arterial wall: A direct measurement with ultrasound imaging. *Circulation* 1986;74:1399-406.
11. Heiss G, Sharrett AR, Barnes R, Chambless LE, Szklo M, Alzola C. Carotid atherosclerosis measured by B-mode ultrasound in populations: Associations with cardiovascular risk factors in the ARIC study. *Am J Epidemiol* 1991;134:250-6.
12. Salonen JT, Salonen R. Ultrasonographically assessed carotid morphology and the risk of coronary heart disease. *Arterioscler Thromb* 1991;11:1245-9.
13. Polak JF, Pencina MJ, Pencina KM, O'Donnell CJ, Wolf PA, D'Agostino RB Sr. Carotid wall intima-media thickness and cardiovascular events. *N Engl J Med* 2011;365:213-21.
14. Reilly LM, Lusby RJ, Hugues L, Ferrell LD, Stoney RJ, Ehrenfeld WK. Carotid plaque histology using real-time ultrasonography. Clinical and therapeutic implications. *Am J Surg* 1997;113:1352-8.
15. Widder B, Paulat K, Hachspacher J. Morphological characterization of carotid artery stenoses by ultrasound duplex scanning. *Ultrasound Med Biol* 1990;16:349-54.

16. De Bray JM, Baud JM, Dauzat M. Consensus concerning the morphology and the risk of carotid plaques. *Cerebrovasc Dis* 1996;7:289-96.
17. Joakimsen O, Bønaa KH, Stensland-Bugge E. Reproducibility of ultrasound assessment of carotid plaque occurrence, thickness, and morphology. The Tromsø Study. *Stroke* 1997;28:2201-7.
18. Johnson JM, Kennely M, Decesale D, Morgan S, Sparrow S. Natural history of asymptomatic plaque. *Arch Surg* 1985 120:1010- 12.
19. Sacco RL, Ellenberg JH, Mohr JP, Tatemichi TK, Hier DB, Price TR, *et al.* Infarcts of undetermined cause: The NINCDS Stroke Data Bank. *Ann Neurol* 1989;25:382-90.
20. Colhoun E, MacElean D. Carotid artery imaging using duplex scanning and bidirectional arteriography: A comparison. *Clin Radiol* 1984;35:101-6.
21. Grant EG, Benson CB, Moneta GL, Alexandrov AV, Baker JD, Bluth EI, *et al.* Carotid artery stenosis: Gray-scale and Doppler US diagnosis—Society of Radiologists in Ultrasound Consensus Conference. *Radiology* 2003;229:340-6.
22. Gosselin C, Walker PM. Subclavian steal syndrome: Existence, clinical features, diagnosis and management. *Semin Vasc Surg* 1996;9:93-7.
23. Walker PM, Paley D, Haris KA, Thompson A, Johnson KW. What determines the symptoms associated with subclavian artery occlusive disease. *J Vasc Surg* 1985;2:154-7.
24. Yonas H, Smith HA, Durham SR, Pentheny SL, Johnson DW. Increased stroke risk predicted by compromised cerebral blood flow reactivity. *J Neurosurg* 1993;79:483-9.

How to cite this article: Bathala L, Mehndiratta MM, Sharma V. Cerebrovascular ultrasonography: Technique and common pitfalls. *Ann Indian Acad Neurol* 2013;16:121-7.

Received: 21-01-12, **Revised:** 12-02-12, **Accepted:** 04-07-12

Source of Support: Nil, **Conflict of Interest:** Nil