

An overview on prostate-specific membrane antigen uptake in malignancies other than prostate cancer: A pictorial essay

ABSTRACT

Prostate-specific membrane antigen (PSMA) is a Type II transmembrane glycoprotein which is extremely overexpressed in prostate cancer epithelial cells. Recently, PSMA-targeted small molecule labeled with ^{68}Ga and $^{99\text{m}}\text{Tc}$ allowed precise molecular imaging of prostate cancer and PSMA-targeted small molecule labeled with ^{177}Lu leads to the development of radionuclide-targeted therapy of prostate cancer. Despite its name, it has been shown that PSMA has been expressed in several malignancies which can be due to significant neovascularization. Present pictorial essay reports the nonspecific tracer uptake in some malignancies during ^{68}Ga -PSMA positron-emission tomography/computed tomography imaging and $^{99\text{m}}\text{Tc}$ -PSMA scintigraphy.

Keywords: ^{68}Ga -prostate-specific membrane antigen positron-emission tomography/computed tomography, $^{99\text{m}}\text{Tc}$ -prostate-specific membrane antigen scintigraphy, prostate cancer, prostate-specific membrane antigen and nonspecific uptake

INTRODUCTION

Prostate-specific membrane antigen (PSMA) is a Type II transmembrane glycoprotein which is extremely overexpressed in prostate cancer epithelial cells.^[1] Higher tumor stage and grade, tumor dedifferentiation, hormone resistance, and metastatic disease lead to increase in overexpression of PSMA.^[2] Although PSMA first was identified in the prostate gland, its expression in the duodenal epithelium, proximal tubule cells in the kidney, salivary glands, and tumor-associated vascular endothelium have been revealed in eventual histopathological studies.^[3-5]

Recently, innovative development of PSMA-targeted small molecule labeled with ^{68}Ga and $^{99\text{m}}\text{Tc}$ allowed precise molecular imaging of prostate cancer and PSMA-targeted small molecule labeled with ^{177}Lu led to the development of radionuclide-targeted therapy of prostate cancer.

^{68}Ga -PSMA positron-emission tomography (PET) since its first use in 2013 has revolutionized the management and imaging

of patients with prostate cancer. Numerous studies have proved the high efficacy of ^{68}Ga -PSMA in diagnosing, staging, follow-up, restaging, and evaluating treatment response.^[6-9]

Regarding the cost benefits and broader availability of single-photon emission computed tomography (CT)

**ESMAIL JAFARI, HOJJAT AHMADZADEHFAR¹,
HABIBOLLAH DADGAR², MAJID ASSADI**

Department of Molecular Imaging and Radionuclide Therapy, The Persian Gulf Nuclear Medicine Research Center, Bushehr Medical University Hospital, Bushehr University of Medical Sciences, Bushehr, ²Cancer Research Center, RAZAVI Hospital, Imam Reza International University, Mashhad, Iran, ¹Department of Nuclear Medicine, University Hospital Bonn, Bonn, Germany


Address for correspondence: Prof. Majid Assadi, The Persian Gulf Nuclear Medicine Research Center, Bushehr University of Medical Sciences, Bushehr, Iran.
E-mail: asadi@bpums.ac.ir, assadipoya@yahoo.com

Submission: 28-Oct-19, **Accepted:** 28-Dec-19, **Published:** 22-Jul-20

This is an open access journal, and articles are distributed under the terms of the Creative Commons Attribution-NonCommercial-ShareAlike 4.0 License, which allows others to remix, tweak, and build upon the work non-commercially, as long as appropriate credit is given and the new creations are licensed under the identical terms.

For reprints contact: WKHLRPMedknow_reprints@wolterskluwer.com

How to cite this article: Jafari E, Ahmadzadehfar H, Dadgar H, Assadi M. An overview on prostate-specific membrane antigen uptake in malignancies other than prostate cancer: A pictorial essay. World J Nucl Med 2020;19:260-5.

Access this article online	
Website: www.wjnm.org	Quick Response Code 
DOI: 10.4103/wjnm.WJNM_78_19	

compared to PET, ^{99m}Tc-labeled small molecule inhibitor has been developed. The clinical evaluation and detection rate of ^{99m}Tc-PSMA in staging, recurrence, and treatment response of patients with prostate cancer have been evaluated in previous studies.^[10-13] Schmidkonz *et al.*^[13] used ^{99m}Tc-MIP-1404 as a ^{99m}Tc-labeled PSMA inhibitor for the detection of prostate cancer with biochemical recurrence. Tracer-positive lesions were detected in 77% of patients, which indicated that this radiotracer has a high probability in the management of prostate cancer patients with biochemical recurrence. In another study, Reinfelder *et al.*^[14] evaluated the detection efficacy of ^{99m}Tc-MIP-1404 in prostate cancer patients with biochemical recurrence. It has been reported that 70% of patients showed positive lesion which revealed that MIP-1404 is a promising radiotracer for the detection of prostate cancer lesions.

However, despite its name, in addition to prostate tissue, PSMA is physiologically expressed in a multiple number of nonprostatic malignancies because of PSMA mRNA transcripts and protein expression in the endothelium of tumor-related neovasculature, leading to potential

pitfalls in the clinical use of PSMA-targeted imaging.^[3,4,15] Nevertheless, PSMA expression in nonprostatic malignancies may prove beneficial in therapeutic and imaging targets for these conditions. Table 1 represents malignancies other than prostate cancer which shows PSMA uptake in previous researches. In this pictorial assay, we reported a few nonprostatic malignancies cases, i.e., differentiated thyroid cancer, esophageal cancer, pancreaticobiliary adenocarcinoma, ureteral cancer, cholangiocarcinoma, pancreatoblastoma, hepatoblastoma, and carcinoma of unknown primary showing PSMA expression during ^{99m}Tc/¹⁷⁷Lu-PSMA scintigraphy and ⁶⁸Ga-PSMA PET imaging [Figures 1-8].

CONCLUSION

Regarding the current literature, interpretation and reporting the PSMA scan in prostate cancer needs careful evaluation as its specificity is limited by some false-positive findings. These limitations may increase the diagnostic pitfalls and decrease the confidence of interpreting physicians. Nonspecific uptakes of ⁶⁸Ga - labeled PSMA PET/CT and ^{99m}Tc/¹⁷⁷Lu-PSMA scintigraphy for prostate imaging at the other malignancies

Table 1: Previous literatures on prostate-specific membrane antigen uptake in malignancies other than prostate cancer

Authors	Diagnosis
Taywade <i>et al.</i> ^[116]	Thyroid cancer
Verma <i>et al.</i> ^[117]	
Bychkov <i>et al.</i> ^[118]	
Sollini <i>et al.</i> ^[119]	
Haffner <i>et al.</i> ^[20]	Oral cancer
Haffner <i>et al.</i> ^[21]	gastric and colorectal cancers
Wang <i>et al.</i> ^[22]	Lung cancer
Wernicke <i>et al.</i> ^[23]	Breast cancer
Wernicke <i>et al.</i> ^[24]	Endometrial and ovarian cancer
Baccala <i>et al.</i> ^[25]	Renal cancer
Rhee <i>et al.</i> ^[26]	
Samplaski <i>et al.</i> ^[27]	Bladder cancer
Nomura <i>et al.</i> ^[28]	Glioblastoma
Wernicke <i>et al.</i> ^[29]	
Kanthan <i>et al.</i> ^[30]	Follicular lymphoma
Sasikumar <i>et al.</i> ^[31]	Brain tumors
Sasikumar <i>et al.</i> ^[32]	Multiple myeloma
Sasikumar <i>et al.</i> ^[33]	Hepatocellular carcinoma
Sasikumar <i>et al.</i> ^[34]	Osteosarcoma
Alipour <i>et al.</i> ^[35]	Hepatocellular cholangiocarcinoma
Anconina <i>et al.</i> ^[36]	Melanoma
Krishnaraju <i>et al.</i> ^[37]	Thymoma type B2
Malik <i>et al.</i> ^[38]	GE junction adenocarcinoma
Malik <i>et al.</i> ^[39]	Signet-ring cell carcinoma
Noto <i>et al.</i> ^[40]	GI stromal tumor
Stoykow <i>et al.</i> ^[41]	Rectal adenocarcinoma
Vamadevan <i>et al.</i> ^[42]	Pancreatic neuroendocrine tumor
Arora <i>et al.</i> ^[43]	Adrenocortical carcinoma
Froehner <i>et al.</i> ^[44]	Squamous cell carcinoma of the penis

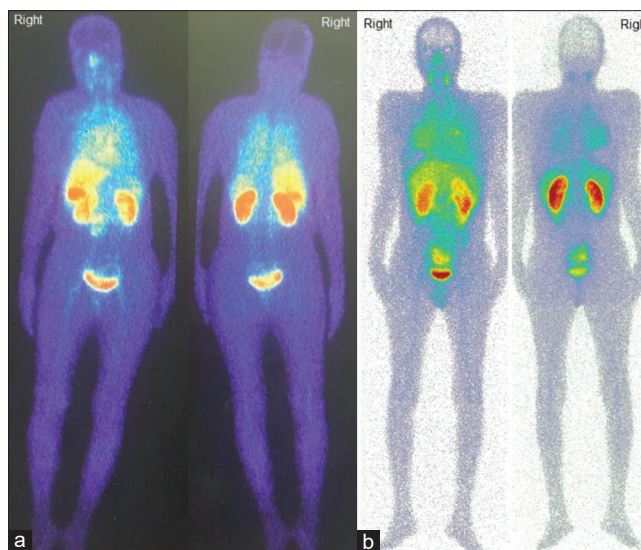


Figure 1: A 54-year-old woman with differentiated thyroid cancer underwent ablation with radioiodine therapy. Posttreatment scan revealed just extensive uptake of I-131 in thyroid bed and did not show any remarkable uptake in the rest of the body. As the previous study indicated the Prostate-specific membrane antigen expression in differentiated thyroid cancer,^[18,20] ^{99m}Tc-prostate-specific membrane antigen scintigraphy was done for disease assessment showing diffuse severe uptake in the lung (a). As mentioned in previous studies,^[45,46] currently, the therapeutic options are limited for patients with metastasized, ¹³¹I-resistant differentiated thyroid cancer, therefore, in another case, ^{99m}Tc-prostate-specific membrane antigen scintigraphy was performed in a 40-year-old male with radioiodine refractory differentiated thyroid cancer. The scan showed a diffuse severe uptake of radiotracer in the lung (b). Therefore, such patients can be a candidate for novel therapy with ¹⁷⁷Lu-prostate-specific membrane antigen

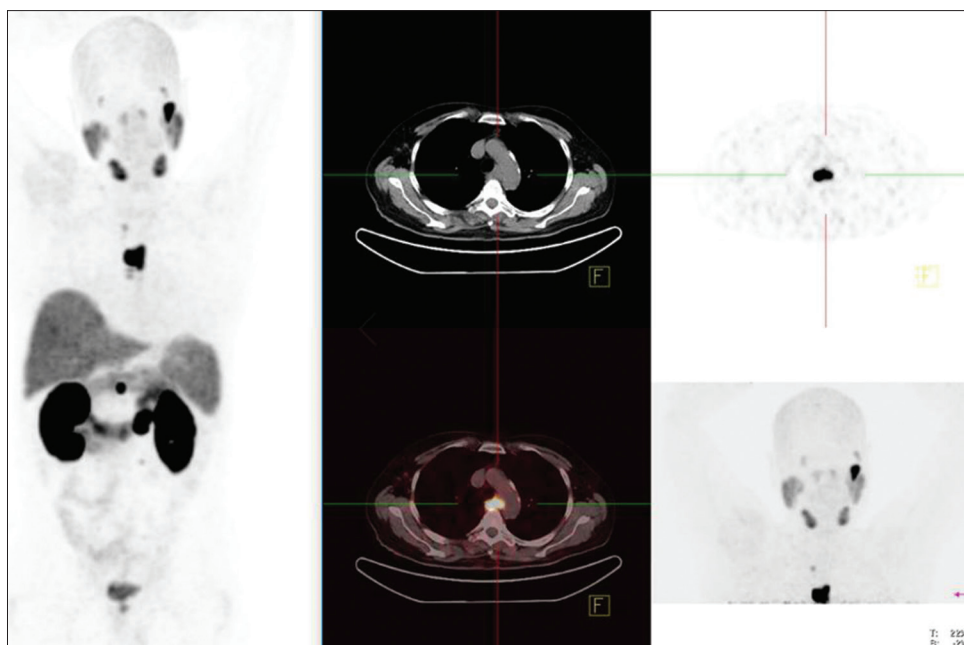


Figure 2: ⁶⁸Ga-prostate-specific membrane antigen positron emission tomography/computed tomography was performed for a 71-year-old male with a history of prostate adenocarcinoma (GS: 4 + 5) underwent prostatectomy 6 years ago. One year after prostatectomy, due to local recurrence, the patient underwent second surgery, external beam radiation therapy and brachytherapy. Due to rising prostate-specific antigen, ⁶⁸Ga-prostate-specific membrane antigen positron-emission tomography/computed tomography was performed for recurrence evaluation. The scan revealed a mid-esophageal mass with esophageal stenosis and highly increased radiotracer uptake, suggesting a second primary cancer with mediastinal lymph nodes metastases. According to the prior studies, increased prostate-specific membrane antigen expression maybe due to significant neovascularization revealed in gastroesophageal cancers [21,38]

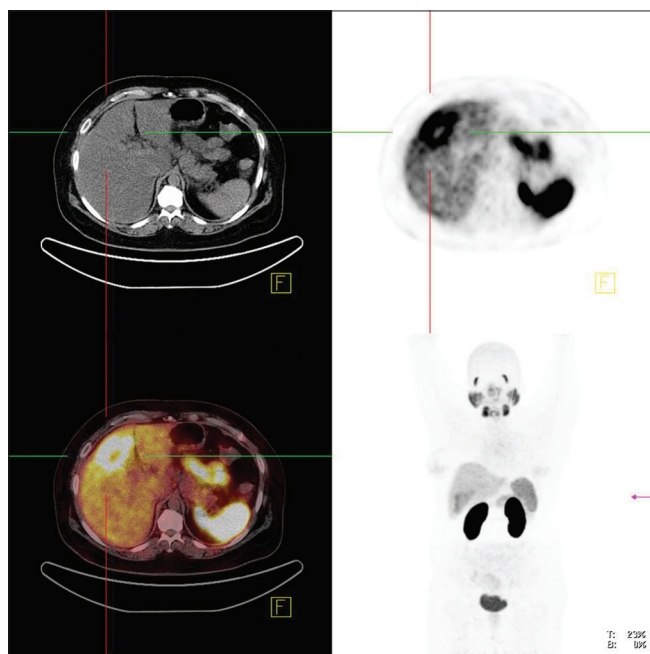


Figure 3: ⁶⁸Ga-prostate-specific membrane antigen positron emission tomography/computed tomography was performed for a 46-year-old woman with a history of multiple hepatic lesions which on biopsy it was adenocarcinoma most likely pancreatobiliary underwent 7 courses of chemotherapy. The scan revealed a 54 mm × 39 mm mass lesion in the segment 5 liver with a maximum standardized uptake value of 11.32 corresponding to the recently computed tomography and fluorodeoxyglucose-positron emission tomography/computed tomography finding. The fluorodeoxyglucose-positron emission tomography/computed tomography, also, showed a solitary hepatic lesion in the right hepatic lobe with the mean standardized uptake value of 2.54

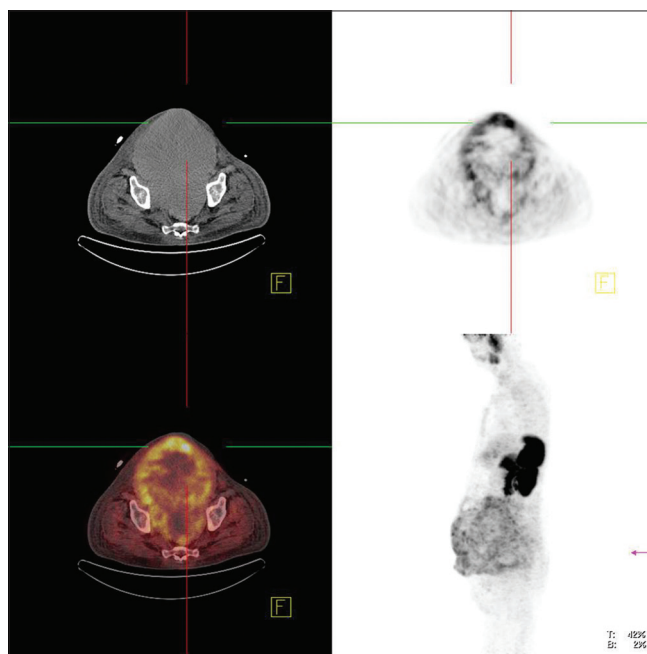


Figure 4: ⁶⁸Ga-prostate-specific membrane antigen positron emission tomography/computed tomography was performed for a 53-year-old male with high-grade transitional cell carcinoma of the ureter received chemotherapy. The patient presented with abdominal pain, bowel obstruction, and colostomy bag. The scan revealed prostate-specific membrane antigen uptake in peritoneal implants

apart from prostate cancer are being reported. Case reports have shown PSMA avidity in high-grade gliomas, lung cancer, breast cancer, multiple myeloma, and malignant melanoma

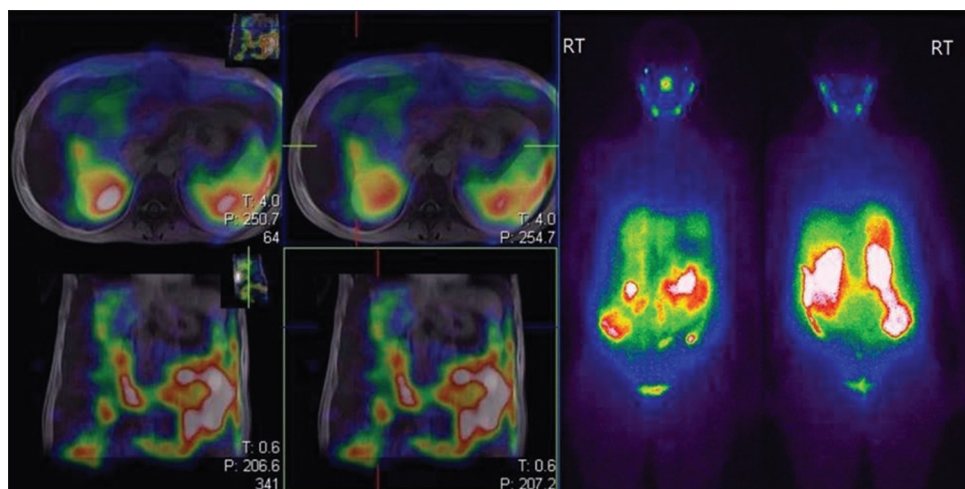


Figure 5: ^{99m}Tc-prostate-specific membrane antigen whole-body scintigraphy was performed for a 42-year-old woman with a history of cholangiocarcinoma. The scan revealed a prostate-specific membrane antigen avid hepatic lesions

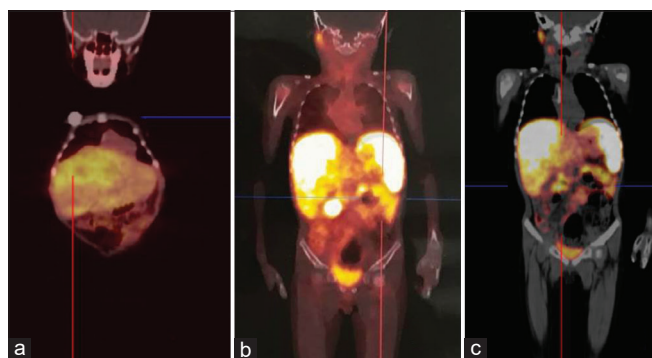


Figure 6: A 5-year-old male with a history of pancreatoblastoma underwent ⁶⁸Ga-prostate-specific membrane antigen positron emission tomography/computed tomography. There are large multiple and lobulated hypodense masses with high prostate-specific membrane antigen uptake throughout the right liver lobe suggested metastatic lesions (maximum standardized uptake value = 7.99) (a). Furthermore, there are soft-tissue lesions in the left side of the abdomen (lateral wall of the abdomen adjacent to the abdominal wall below the left kidney (2.77 cm × 2 cm with maximum standardized uptake value = 3.89 and 2.7 cm × 2.04 cm with maximum standardized uptake value = 3.04) (b) and the pancreatic head (2 cm with maximum standardized uptake value = 5.21) (c). The fluorodeoxyglucose positron emission tomography/computed tomography revealed only the hepatic lesions (maximum standardized uptake value = 6.6) and the lesion between the stomach fundus and spleen (maximum standardized uptake value = 2.8)

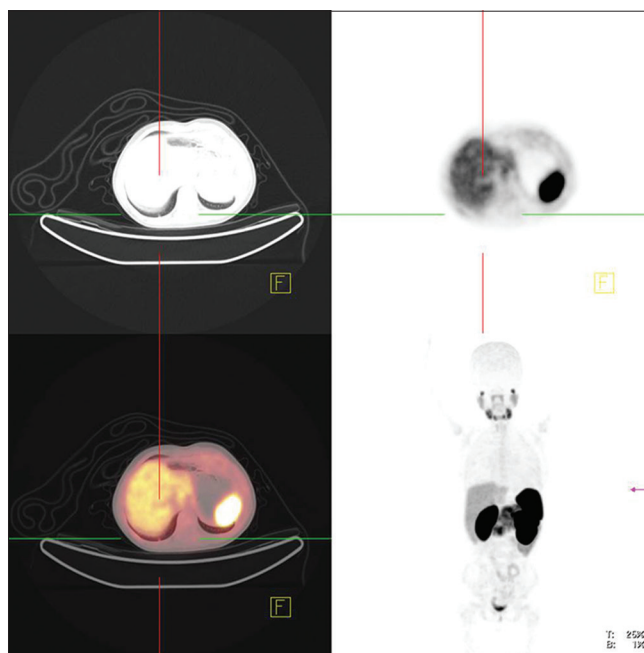


Figure 7: ⁶⁸Ga-prostate-specific membrane antigen positron-emission tomography/computed tomography was performed for an 8-year-old male with a history of hepatoblastoma. The scan revealed mild radiotracer uptake in the liver

due to the PSMA expression in the endothelial cells of the tumor neovasculature. The finding of PSMA expression in these malignancies may lead to radioligand-based therapeutic options.

Declaration of patient consent

The authors certify that they have obtained all appropriate patient consent forms. In the form the patients have given their consent for their images and other clinical information to be reported in the journal. The patients understand that

their names and initials will not be published and due efforts will be made to conceal their identity, but anonymity cannot be guaranteed.

Financial support and sponsorship

Nil.

Conflicts of interest

There are no conflicts of interest.

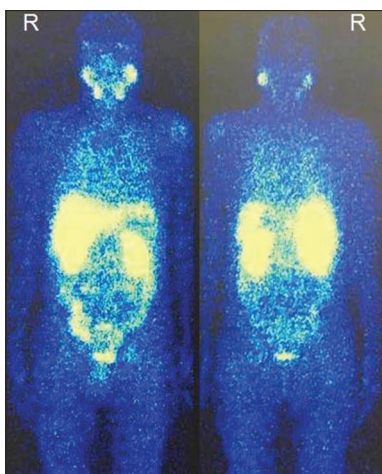


Figure 8: ^{99m}Tc-prostate-specific membrane antigen whole-body scintigraphy was performed for a 44-year-old male with unknown origin cancer revealed multifocal uptake more pronounced pelvis. The prostate cancer origin excluded according to the prostate magnetic resonance imaging, serum prostate-specific antigen level (0.83 ng/ml) and immunohistochemistry report. The whole-body bone scan, magnetic resonance imaging and fluorodeoxyglucose-positron-emission tomography showed multiple osseous metastasis in the thoracic and lumbar spine, some ribs, bilateral pelvic bones, and both femurs

REFERENCES

- Ahmadzadehfard H, Aryana K, Pirayesh E, Farzanehfard S, Assadi M, Fallahi B, *et al.* The Iranian Society of Nuclear Medicine practical guideline on radioligand therapy in metastatic castration-resistant prostate cancer using ¹⁷⁷Lu-PSMA. *Iran J of Nucl Med* 2018;26:2-8.
- DeMarzo AM, Nelson WG, Isaacs WB, Epstein JI. Pathological and molecular aspects of prostate cancer. *Lancet* 2003;361:955-64.
- Malik D, Sood A, Mittal BR, Singh H, Basher RK, Shukla J, *et al.* Nonspecific Uptake of ⁶⁸Ga-prostate-specific membrane antigen in diseases other than prostate malignancy on positron emission tomography/computed tomography imaging: A pictorial assay and review of literature. *Indian J Nucl Med* 2018;33:317-25.
- Chang SS, O'Keefe DS, Bacich DJ, Reuter VE, Heston WD, Gaudin PB. Prostate-specific membrane antigen is produced in tumor-associated neovasculature. *Clin Cancer Res* 1999;5:2674-81.
- Silver DA, Pellicer I, Fair WR, Heston WD, Cordon-Cardo C. Prostate-specific membrane antigen expression in normal and malignant human tissues. *Clin Cancer Res* 1997;3:81-5.
- Afshar-Oromieh A, Avtzi E, Giesel FL, Holland-Letz T, Linhart HG, Eder M, *et al.* The diagnostic value of PET/CT imaging with the ⁶⁸Ga-labelled PSMA ligand HBED-CC in the diagnosis of recurrent prostate cancer. *Eur J Nucl Med Mol Imaging* 2015;42:197-209.
- Afshar-Oromieh A, Holland-Letz T, Giesel FL, Kratochwil C, Mier W, Haufe S, *et al.* Diagnostic performance of ⁶⁸Ga-PSMA-11 (HBED-CC) PET/CT in patients with recurrent prostate cancer: Evaluation in 1007 patients. *Eur J Nucl Med Mol Imaging* 2017;44:1258-68.
- Hope TA, Truillet C, Ehman EC, Afshar-Oromieh A, Aggarwal R, Ryan CJ, *et al.* ⁶⁸Ga-PSMA-11 PET imaging of response to androgen receptor inhibition: First human experience. *J Nucl Med* 2017;58:81-4.
- Perera M, Papa N, Christidis D, Wetherell D, Hofman MS, Murphy DG, *et al.* Sensitivity, specificity, and predictors of positive ⁶⁸Ga-prostate-specific membrane antigen positron emission tomography in advanced prostate cancer: A systematic review and meta-analysis. *Eur Urol* 2016;70:926-37.
- Rathke H, Afshar AA, Giesel FL, Kremer C, Flechsig P, Haufe S, *et al.* Intra-individual comparison of Tc-99m-MDP bone scan and the PSMA-ligand Tc-99m-MIP-1427 in patients with osseous metastasized prostate cancer. *J Nucl Med* 2018;117.
- Schmidkonz C, Cordes M, Beck M, Goetz TI, Schmidt D, Prante O, *et al.* SPECT/CT with the PSMA ligand ^{99m}Tc-MIP-1404 for whole-body primary staging of Patients with prostate cancer. *Clin Nucl Med* 2018;43:225-31.
- Schmidkonz C, Cordes M, Beck M, Goetz TI, Schmidt D, Prante O, *et al.* Assessment of treatment response by ^{99m}Tc-MIP-1404 SPECT/CT: A pilot study in patients with metastatic prostate cancer. *Clin Nucl Med* 2018;43:e250-8.
- Schmidkonz C, Hollweg C, Beck M, Reinfelder J, Goetz TI, Sanders JC, *et al.* ^{99m}Tc-MIP-1404-SPECT/CT for the detection of PSMA-positive lesions in 225 patients with biochemical recurrence of prostate cancer. *Prostate* 2018;78:54-63.
- Reinfelder J, Kuwert T, Beck M, Sanders JC, Ritt P, Schmidkonz C, *et al.* First experience with SPECT/CT using a ^{99m}Tc-labeled inhibitor for prostate-specific membrane antigen in patients with biochemical recurrence of prostate cancer. *Clin Nucl Med* 2017;42:26-33.
- Backhaus P, Noto B, Avramovic N, Grubert LS, Huss S, Bögemann M, *et al.* Targeting PSMA by radioligands in non-prostate disease-current status and future perspectives. *Eur J Nucl Med Mol Imaging* 2018;45:860-77.
- Taywade SK, Damle NA, Bal C. PSMA expression in papillary thyroid carcinoma: Opening a new horizon in management of thyroid cancer? *Clin Nucl Med* 2016;41:e263-5.
- Verma P, Malhotra G, Agrawal R, Sonavane S, Meshram V, Asopa RV. Evidence of prostate-specific membrane antigen expression in metastatic differentiated thyroid cancer using ⁶⁸Ga-PSMA-HBED-CC PET/CT. *Clin Nucl Med* 2018;43:e265-8.
- Bychkov A, Vutrapongwatana U, Tepmongkol S, Keelawat S. PSMA expression by microvasculature of thyroid tumors - Potential implications for PSMA theranostics. *Sci Rep* 2017;7:5202.
- Sollini M, di Tommaso L, Kirienko M, Piombo C, Erreni M, Lania AG, *et al.* PSMA expression level predicts differentiated thyroid cancer aggressiveness and patient outcome. *EJNMMI Res* 2019;9:93.
- Haffner MC, Laimer J, Chaux A, Schäfer G, Obrist P, Brunner A, *et al.* High expression of prostate-specific membrane antigen in the tumor-associated neo-vasculature is associated with worse prognosis in squamous cell carcinoma of the oral cavity. *Mod Pathol* 2012;25:1079-85.
- Haffner MC, Kronberger IE, Ross JS, Sheehan CE, Zitt M, Mühlmann G, *et al.* Prostate-specific membrane antigen expression in the neovasculature of gastric and colorectal cancers. *Hum Pathol* 2009;40:1754-61.
- Wang HL, Wang SS, Song WH, Pan Y, Yu HP, Si TG, *et al.* Expression of prostate-specific membrane antigen in lung cancer cells and tumor neovasculature endothelial cells and its clinical significance. *PLoS One* 2015;10:e0125924.
- Wernicke AG, Varma S, Greenwood EA, Christos PJ, Chao KS, Liu H, *et al.* Prostate-specific membrane antigen expression in tumor-associated vasculature of breast cancers. *APMIS* 2014;122:482-9.
- Wernicke AG, Kim S, Liu H, Bander NH, Pirog EC. Prostate-specific membrane antigen (PSMA) expression in the neovasculature of gynecologic malignancies: Implications for PSMA-targeted therapy. *Appl Immunohistochem Mol Morphol* 2017;25:271-6.
- Baccala A, Sercia L, Li J, Heston W, Zhou M. Expression of prostate-specific membrane antigen in tumor-associated neovasculature of renal neoplasms. *Urology* 2007;70:385-90.
- Rhee H, Blazak J, Tham CM, Ng KL, Shepherd B, Lawson M, *et al.* Pilot study: Use of gallium-68 PSMA PET for detection of metastatic lesions in patients with renal tumour. *EJNMMI Res* 2016;6:76.
- Samplaski MK, Heston W, Elson P, Magi-Galluzzi C, Hansel DE. Folate hydrolase (prostate-specific membrane [corrected] antigen) 1 expression in bladder cancer subtypes and associated tumor

- neovasculature. *Mod Pathol* 2011;24:1521-9.
28. Nomura N, Pastorino S, Jiang P, Lambert G, Crawford JR, Gymnopoulos M, *et al.* Prostate specific membrane antigen (PSMA) expression in primary gliomas and breast cancer brain metastases. *Cancer Cell Int* 2014;14:26.
 29. Wernicke AG, Edgar MA, Lavi E, Liu H, Salerno P, Bander NH, *et al.* Prostate-specific membrane antigen as a potential novel vascular target for treatment of glioblastoma multiforme. *Arch Pathol Lab Med* 2011;135:1486-9.
 30. Kanthan GL, Coyle L, Kneebone A, Schembri GP, Hsiao E. Follicular Lymphoma showing avid uptake on 68Ga PSMA-HBED-CC PET/CT. *Clin Nucl Med* 2016;41:500-1.
 31. Sasikumar A, Joy A, Pillai MR, Nanabala R, Anees KM, Jayaprakash PG, *et al.* Diagnostic value of 68Ga PSMA-11 PET/CT imaging of brain tumors-preliminary analysis. *Clin Nucl Med* 2017;42:e41-8.
 32. Sasikumar A, Joy A, Pillai MR, Nanabala R, Thomas B. 68Ga-PSMA PET/CT imaging in multiple myeloma. *Clin Nucl Med* 2017;42:e126-7.
 33. Sasikumar A, Joy A, Nanabala R, Pillai MR, Thomas B, Vikraman KR. (68) Ga-PSMA PET/CT imaging in primary hepatocellular carcinoma. *Eur J Nucl Med Mol Imaging* 2016;43:795-6.
 34. Sasikumar A, Joy A, Pillai MR, Alex TM, Narayanan G. 68Ga-PSMA PET/CT in osteosarcoma in fibrous dysplasia. *Clin Nucl Med* 2017;42:446-7.
 35. Alipour R, Gupta S, Trethewey S. 68Ga-PSMA Uptake in combined hepatocellular cholangiocarcinoma with skeletal metastases. *Clin Nucl Med* 2017;42:e452-3.
 36. Anconina R, Hod N, Levin D, Ezroh Kazap D, Lantsberg S. Incidental detection of metastatic malignant melanoma on 68Ga-prostate-specific membrane antigen PET/CT imaging: Correlative imaging With FDG PET/CT and review of the literature. *Clin Nucl Med* 2018;43:204-6.
 37. Krishnaraju VS, Basher RK, Singh H, Singh SK, Bal A, Mittal BR. Incidental detection of Type B2 thymoma on 68Ga-labeled prostate-specific membrane antigen PET/CT imaging. *Clin Nucl Med* 2018;43:356-8.
 38. Malik D, Kumar R, Mittal BR, Singh H, Bhattacharya A, Singh SK. 68Ga-labeled PSMA uptake in nonprostatic malignancies: Has the time come to remove “PS” From PSMA? *Clin Nucl Med* 2018;43:529-32.
 39. Malik D, Kumar R, Mittal BR, Singh H, Bhattacharya A, Sood A, *et al.* 68Ga-labelled PSMA (prostate specific membrane antigen) expression in signet-ring cell gastric carcinoma. *Eur J Nucl Med Mol Imaging* 2018;45:1276-7.
 40. Noto B, Weckesser M, Buerke B, Pixberg M, Avramovic N. Gastrointestinal stromal tumor showing intense tracer uptake on PSMA PET/CT. *Clin Nucl Med* 2017;42:200-2.
 41. Stoykow C, Huber-Schumacher S, Almasreh N, Jilg C, Ruf J. Strong PSMA radioligand uptake by rectal carcinoma: Who put the “S” in PSMA? *Clin Nucl Med* 2017;42:225-6.
 42. Vamadevan S, Shetty D, Le K, Bui C, Mansberg R, Loh H. Prostate-specific membrane antigen (PSMA) avid pancreatic neuroendocrine tumor. *Clin Nucl Med* 2016;41:804-6.
 43. Arora S, Damle NA, Aggarwal S, Passah A, Behera A, Arora G, *et al.* Prostate-specific membrane antigen expression in adrenocortical carcinoma on 68Ga-prostate-specific membrane antigen PET/CT. *Clin Nucl Med* 2018;43:449-51.
 44. Froehner M, Kuithan F, Zöphel K, Heberling U, Laniado M, Wirth MP. Prostate-specific membrane antigen-targeted ligand positron emission tomography/computed tomography and immunohistochemical findings in a patient with synchronous metastatic penile and prostate cancer. *Urology* 2017;101:e5-6.
 45. Verburg FA, Krohn T, Heinzel A, Mottaghy FM, Behrendt FF. First evidence of PSMA expression in differentiated thyroid cancer using [⁶⁸Ga] PSMA-HBED-CC PET/CT. *Eur J Nucl Med Mol Imaging* 2015;42:1622-3.
 46. Luster M, Weber T, Verburg FA. Differentiated thyroid cancer-personalized therapies to prevent overtreatment. *Nat Rev Endocrinol* 2014;10:563-74.