

## Original Article



# Comparison of Hydrocolloid Dressings and Silver Nanoparticles in Treatment of Pressure Ulcers in Patients with Spinal Cord Injuries: A Randomized Clinical Trial

Parvaneh Asgari<sup>1</sup>, Mitra Zolfaghari<sup>2</sup>, Yee Bit-Lian<sup>3</sup>, Amir Hossein Abdi<sup>1</sup>, Younes Mohammadi<sup>4</sup>, Fatemeh Bahramnezhad<sup>5,6\*</sup>

<sup>1</sup>Department of Critical Care Nursing, School of Nursing and Midwifery, Tehran University of Medical Sciences, Tehran, Iran

<sup>2</sup>Department of E-learning in Medical Education, Nursing and Midwifery Care Research Center, Virtual School, Tehran University of Medical Sciences, Tehran, Iran

<sup>3</sup>Cluster of Applied Sciences, Petaling Jaya Learning Centre, Open University Malaysia, 46350 Petaling Jaya, Malaysia

<sup>4</sup>Department of Epidemiology, School of Health, Hamadan University of Medical Sciences, Hamadan, Iran

<sup>5</sup>Department of Critical Care Nursing, Nursing and Midwifery Care Research Center, School of Nursing and Midwifery, Tehran University of Medical Sciences, Tehran, Iran

<sup>6</sup>Spiritual Health Group, Research Center of Quran, Hadith and Medicine, Tehran University of Medical Sciences, Tehran, Iran

## Article Info

### Article History:

Received: 23 Mar. 2021

Accepted: 20 Sep. 2021

e-Published: 15 Jan. 2022

### Keywords:

Hydrocolloid, Dressing, Silver nanoparticles, Pressure ulcer, Spinal cord injuries

### \*Corresponding Author:

Fatemeh Bahramnezhad,  
Email: bahramnezhad@sina.tums.ac.ir

## Abstract

**Introduction:** There are numerous dressings used to treat pressure ulcers (PUs), depending on their advantages to achieve optimum patient outcomes. This study aimed to compare hydrocolloid dressings and silver nanoparticles in treating PUs among patients with spinal cord injury (SCI).

**Methods:** This randomized clinical trial was conducted on 70 patients with SCI in Iran. Participants were randomly divided into two equal groups (n=35) receiving silver nanoparticle dressing and hydrocolloid dressing, respectively. The groups were evaluated in four assessment periods using the Bates-Jensen Wound Assessment Tool (BWAT). Data analysis was performed using SPSS software version 13, repeated measures ANOVA, non-parametric tests, and chi-square.

**Results:** Chi-square test was used to investigate the difference between the scores before the intervention, the results of which were not statistically significant. In repetitive measurements, the results of the analysis of variance showed that the average assessment score in both groups decreased and both dressings were effective in the treatment process. Although PU improvement status in the group that received silver nanoparticles was better, between-group analysis of variance did not show any statistically significant difference between the two groups.

**Conclusion:** Our results indicated that silver nanoparticles and hydrocolloid dressings can be used interchangeably in the treatment of PUs.

## Introduction

Spinal cord injuries (SCIs) usually occur following acute traumatic events such as accidents, falling from the height, and shots. SCI leads to the loss of sense of movement partially or completely.<sup>1</sup> Almost every year, 40 per one million people are added to people with SCI. The mean age of traumatic SCI is 31.5 years, and the injury level in males is four times higher than females.<sup>2</sup> SCI causes physical, physiological, sensational, emotional, economic, and social changes in these victims and it has a negative effect in their quality of life. People with SCI suffer from problems, such as changes in bowel function, bladder, urine and stool control, change in sexual function, respiratory disorders, pain, spasticity of muscles, dependence, pressure ulcer (PU), and loss of the sense

of independence.<sup>3</sup> Moreover, 33% of patients with SCI experience PU at least after one year.<sup>4</sup> These patients, due to the relatively incomplete ability to move, urinary and stool incontinence, and malnutrition are more sensitive against PU and the wound healing process in these people is very slow.<sup>5</sup> Some drugs such as antipsychotics, muscle relaxants, analgesics, and blood flow-modifying drugs can be effective in treating ulcers.<sup>6</sup>

These ulcers are chronic and create problems for the patient, treatment team, family, and society.<sup>7</sup> PU leads to pain, suffering, deformation, osteomyelitis, septicemia, and mortality. Moreover, the treatment of these ulcers is costly and requires a long-term period.<sup>8</sup> Nowadays, PU prevention has been widely developed with a massive range of interventions including skincare, repositioning,

and using dressings.<sup>9</sup>

Selecting appropriate dressings is one of the most important duties of a nurse in treating PU, and choosing the right one can speed up the healing process.<sup>10</sup> Different dressings constitute the most prevalent therapeutic approaches for this problem.<sup>11</sup> Since the dressing is directly placed on the ulcer, it should be selected with caution. An ideal dressing should have characteristics, such as maintaining a moist and optimal environment for wound healing, creating suitable heat (37°C), providing an environment for oxygen and CO<sub>2</sub> exchange, the possibility to see the ulcer, high absorption capacity, lack of pain while replacing, easy application, and suitable and payable cost for the patient.<sup>12</sup> Nowadays, the use of modern dressings is developed and they have more applications than conventional dressings.<sup>13</sup> One of the most common dressings in the treatment of these ulcers is hydrocolloid dressing. These dressings have most of the characteristics of an ideal dressing and include components such as cellulose, pectin, gelatin, sodium, alginate, and calcium alginate. This dressing does not attach to the ulcers and due to keeping moisture in the wound, it alleviates the pain.<sup>14</sup> Recently, the use of dressings containing silver nanoparticles has been considered in the treatment of PUs. These dressings have a special coating and are indirectly related to the ulcer through a hydrophilic layer. Therefore, while removing them from the ulcer, damage to the tissue is unlikely and they have high anti-bacterial potential.<sup>15</sup>

In a systematic review, Keogh et al showed that treating PUs through using a hydrochloric dressing takes a long time and that the dressing cannot prevent infection. There have been many studies on hydrocolloid dressings, some of which have been used to heal PUs or burn wounds.<sup>16</sup> But silver nanoparticle dressing is a new dressing that was first used to treat burns and has been used in vitro and in vivo.<sup>17</sup>

However, limited studies have been conducted on PUs. Khampiang et al evaluated the effect of silver nanoparticle dressing on the treatment of PUs, and they recommended further studies on this dressing in the treatment of PU.<sup>18</sup>

A suitable dressing not only can lead to rapid improvement of ulcers and decrease complications, but also it can decrease the costs and help the patient to get a normal life in a shorter period of time. Suitable dressing selection can help the patients and their families in decreasing the burden of care and healthcare costs. In selecting dressings, in addition to quality, factors such as availability and cost are important to consider. Since silver nanoparticle dressing is cost-effective and it results in good patient outcomes, its usage is increasing. Accordingly, the current study attempted to evaluate the effectiveness of hydrocolloid and silver nanoparticle dressings in treating PUs.

## Materials and Methods

This randomized clinical trial study (Code: IRCT201112038286N1) included two groups and was

conducted in hospitals affiliated to Tehran University of Medical Sciences, Iran from 2015 to 2017.

To determine the required sample volume at 95% confidence level and 80% power, it was assumed that the hydrocolloid dressing in comparison with silver nanoparticles can reduce the average wound surface by 10% in the process of healing PUs in comparison with the control group. The intervention was considered as statistically significant. The sample size in each group was initially calculated to be  $n = 30$  patients with assuming 5% and 20% probability of type I and II errors. Then, due to the probability of 10% drop, the sample size was finally estimated to be  $n = 35$  in each group. It should be noted that based on several similar studies, the standard deviation of the wound surface was estimated to be 9.5 cm.

After receiving the approval of the research ethics committee of the Tehran University of Medical Sciences, using a simple random sampling, the researcher (F.B.) selected the patients who met the inclusion criteria and assigned them into two groups of receiving hydrocolloid dressing and silver nanoparticle dressing. The inclusion criteria were: PU based on National Pressure Ulcer Advisory Panel (NPUAP), age between 18-65 years, lack of infection in ulcers, lack of necrotic tissue, patients who could change their position every hour, lack of using other dressings (Figure 1).

At first, after receiving a written informed consent from all patients, using Bates-Jensen Wound Assessment Tool (BWAT), several photos were taken from the edge of the ulcer and under it, tunnel condition or absence of ulcers, type and amount of secretions, the color of the ulcer and skins around it, granular tissue, and ulcer epithelium (to investigate the healing process of the ulcer). The patient's ulcer was washed with normal saline and then covered with the dressing. Dressing replacements were based on guidelines provided by the manufacturer. Hydrocolloid dressing (transparent type) was produced by the Coloplast company. This dressing package is presented in two different sizes (5×5 cm and 10×10 cm). This dressing is placed on the ulcer and does not need protective dressing. According to the guidelines of the manufacturer, after placing the dressing on the ulcer, over time and based on the level of exodus and moisture of the ulcer bed, a milky colored gel accumulates under this dressing that functions as a guideline for replacing the ulcer. When this gel gets close to the edges of the ulcer, the dressing is removed gradually from one side and it is washed by normal saline and the healing process is investigated, and the ulcer is dressed again. Separately, silver nanoparticle dressing in this study was fabricated by AgCoat company in different sizes (5×5 cm and 10×10 cm) with a silver concentration of 1.7 ppm/cm<sup>2</sup>. To use this dressing, the ulcer was washed by normal saline. Then, normal saline on the ulcer was dried by sterile gas. The dressing was then placed on the ulcer so that it was out of the ulcer edges by 1 cm. Then, a sterile gas was placed on the ulcer and the dressing was

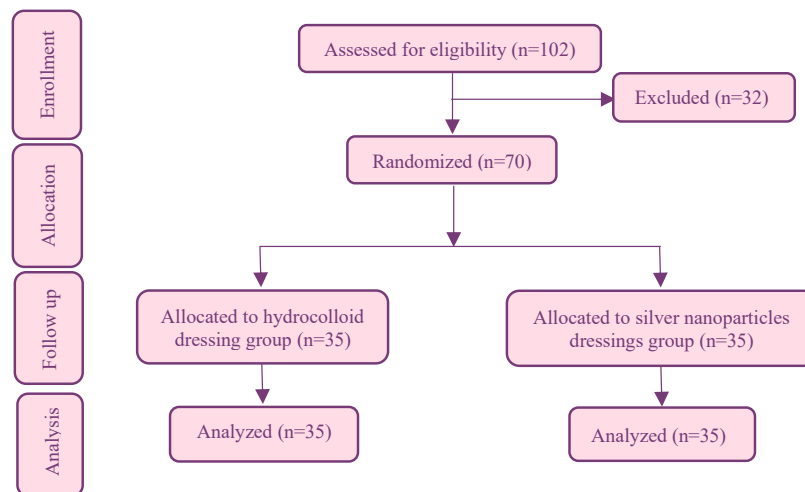


Figure 1. Flow chart of the study.

fixed with a simple band. According to the guidelines of the manufacturer, when the color of dressing changes from dark green to light green, it means that more than 70% of its silver has been released and it should be replaced (this takes almost 72 hours in accordance with the manufacturer's instructions). In both groups, the ulcer was washed with normal saline.

In four periods (every three days) and while replacing the dressing, the healing process of the ulcer (changing from stage 2 to stage 1 or complete healing of the ulcer) was investigated by BWAT. Since dressing method and experience of healthcare professionals in performing the dressing method can affect the healing process of ulcers and influence the results, therefore, dressings in both groups were performed by a nurse with 10 years of experience in dressing and taking care of the PUs. Ulcers were observed by the first nurse; the photos were provided and sent to a second nurse with 15 years of experience in taking care of PUs. None of those observers were informed of the dressing type. The observers were required to study them immediately to prevent ambiguity due to the interval between observation and study.

The tool in this study consisted of demographic profile form and BWAT. The BWAT consisted of 15 items in which the position and form of ulcer were not classified, but the other 13 items were based on a 5-point Likert scale. This instrument investigates parameters, such as the extent of the ulcer, degree of ulcer (depth), edema of the ulcer, degradation of the underlying tissues, type of necrosis tissue, exudate type, exudative amount, peripheral tissue induration, peripheral edema, granular tissue, and epithelialization. Scores ranged between 1 and 5 and the lowest score (1) showed the best condition and the highest score (5) showed the worst condition. Accordingly, the minimum and maximum scores of this instrument were 13 and 60, respectively.<sup>19</sup> A higher score in this questionnaire shows more analysis of the ulcer and lower score shows more improvement of the ulcer. The first questionnaire was translated to Persian through the backward-forward approach. Regarding the content

of the questionnaire, content validity index (CVI=0.89) and content validity ratio (CVR=0.77) with a significance level of 0.05 were used. Cronbach's alpha was used to measure reliability ( $\alpha=0.86$ ). Moreover, since BWAT is a Likert tool and agreement index between two observers for each item is 0.20, the kappa coefficient was estimated for each item and was obtained larger than 60%. Because this agreement is close to 1, so this agreement is direct and proportionate.<sup>20</sup>

To measure ulcers, the plastic strip meter with an accuracy of 1:1000 was used. By the admission of the patient and treatment period (12 days), ulcer area was measured by strip meter and expressed as length  $\times$  width. It should be noted that in studying the ulcer, 4 cm around it was taken into consideration. To characterize the ulcer percentage, transparent circular talc with 4 equal parts (25%) was used.<sup>19</sup> To determine the area under the ulcer, an epilator was used. Epilator was placed under the ulcer edge without any pressure. Force implementation is needed to prevent more progress. Then, the last point where the epilator is moved without pressure was characterized by a pen and the distance between this point and the ulcer edge was measured. This method was implemented in all points around the ulcer. Finally, to determine the percentage of these areas, transparent circular talc including 4 equal parts (25%) was used.

The SPSS software version 13 was used to analyze the data of statistical tests of the repeated measures ANOVA, Friedman test, chi-squared test ( $\chi^2$ ), and Fisher's exact test (summarizing participants' demographic data and homogeneity of demographic characteristics). An alpha error of  $P < 0.05$  was used to determine statistical significance in all analyses.

## Results

A total of 70 patients were eligible for inclusion in the study (no drop-outs). There was no statistically significant difference between the groups with respect to baseline population characteristics. The findings of this study showed that the mean (SD) of age in patients

receiving silver nanoparticle and hydrocolloid groups was 69.5 (14.58), 69.08 (16.2), respectively. Regarding the anatomical position of ulcers in both groups, most of the ulcers were in sacral areas (silver nanoparticles = 63.8% vs. hydrocolloid = 51.1%). After observing the environment and ulcer depth, the most common ulcer pattern was irregular in both groups (silver nanoparticle = 62.1% vs. hydrocolloid = 53.2%). In addition, body mass index (BMI) varied between 21 and 23.8 kg/m<sup>2</sup> (Table 1).

Comparing the ulcer in assessment periods, the findings showed that ulcer size had decreased. Comparing the mean (SD) of cases, such as ulcer depth, ulcer edge, degradation of the underlying tissues, type of necrosis tissue, exudate type, exudative amount, peripheral tissue induration, peripheral edema, granular tissue, and epithelialization, paired *t* test showed that there was no significant difference between the two groups in four periods (every three days).

Figure 2 shows that the PU conditions of patients before the intervention and second assessment period were similar, and in terms of fold change were symmetrical; but after the second period up to the end of the fourth period in silver nanoparticles group, the healing process was better. The mean for the two groups was not statistically significantly different in the fourth period. In repeated measures, the results of the analysis of variance showed that the mean assessment score in both groups decreased, and both dressings were effective in the healing process. Although PU improvement status in the silver nanoparticles group was better (Figure 2 and Table 2), between-group analysis of variance did not show any statistically significant difference between the two groups.

**Discussion**

The results showed that there was no statistically significant difference between the silver nanoparticle and hydrocolloid dressings in terms of affecting the healing process of PUs, and their effects were similar among patients with SCI. As far as the researcher investigated, there was no study to compare the effects of these two dressings on the treatment of PUs. However, a study by Mehrabani et al showed that hydrocolloid and honey dressings did not have a significant difference in terms of PU healing process.<sup>21</sup> The results of a meta-analysis by He and Chen showed that hydrocolloid dressings were more

effective than gauze dressings for PU treatment in the complete wound healing rate (OR: 3.64, 95% CI: 1.10 to 12.01).<sup>22</sup>

The researcher assumed that silver nanoparticles had better effects in treating PUs; however, no significant difference was observed between the two groups in this study. This might be attributed to the fact that silver nanoparticles by releasing silver ion create antimicrobial and anti-inflammatory effects, and with this approach, blood flow around the ulcer increases and this further improves the healing process. In this regard, the researcher believes that silver nanoparticle dressing has anti-inflammatory properties. In addition, as suggested by a few studies, silver nanoparticle dressings decreased the production of inflammatory cytokines, and controlling interferon activity and alpha necrotic factor are among the anti-inflammatory properties of silver nanoparticles.<sup>23,24</sup>

However, it should be noted that like other biomaterials, these dressings can cause toxicity depending on their characteristics and entrance path. The toxicity created by

**Table 1.** Baseline characteristics of the patients in two groups (each group = 35)

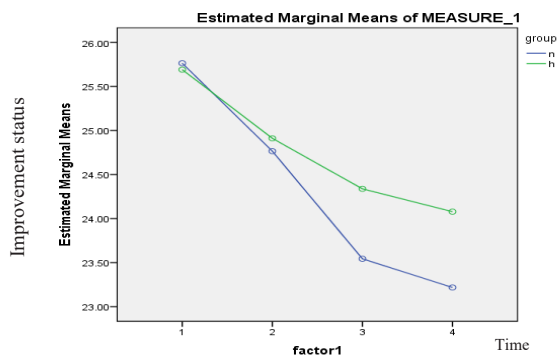
Variable	No. (%) <sup>a</sup>		P value <sup>b</sup>
	Silver nanoparticles	Hydrocolloid	
Gender			
Female	12 (34.30)	15 (42.85)	0.45 <sup>c</sup>
Male	23 (65.70)	20 (57.15)	
Marital status			
Married	30 (85.70)	28 (80)	0.30
Single	5 (14.30)	7 (20)	
Education level			
Illiterate	2 (5.71)	5 (14.28)	0.17
Elementary	10 (28.6)	10 (28.6)	
Diploma	8 (22.84)	9 (25.71)	
Bachelor	14 (40.00)	9 (25.71)	
Graduate	1 (2.85)	2 (5.70)	
Underlying disease			
Diabetes	8 (22.90)	9 (25.72)	0.80
High cholesterol	7 (20)	6 (17.14)	
Hypertension	20 (57.10)	18 (51.44)	
COPD	0 (0)	2 (5.70)	

<sup>a</sup> Number (Percent), <sup>b</sup> Fisher's exact test, <sup>c</sup>  $\chi^2$ .

**Table 2.** Comparison of mean (SD) of total BWAT score of pressure ulcer before and after intervention (four period assessments) in two groups

Assessment periods	Mean (SD)		95% CI	P value <sup>a</sup>
	Silver nanoparticles	Hydrocolloid		
Before intervention	27.25 (6.7)	23.87 (4.09)	(0.81, 1.25)	0.90
The first assessment period	27.02 (7.02)	24.22 (4.3)	(-1.09, -0.73)	0.20
The second assessment period	25.73 (6.07)	23.52 (4.7)	(0.92, 1.28)	0.60
The third assessment period	24.71 (7.1)	22.97 (5.1)	(-0.53, 0.13)	0.60
The fourth assessment period	24.3 (7.1)	22.80 (5.3)	(0.23, 0.87)	0.80

<sup>a</sup> ANOVA test was used.



**Figure 2.** Comparison of wound healing process using silver nanoparticle and hydrocolloid dressings. n = nanoparticle silver, h = hydrocolloid.

silver nanoparticles is oxidative whereby its accumulation in the cytoplasm and cell core can produce free radicals. Silver nanoparticles are particles that have high toxicity due to high connection, but over time and by increased connections, their toxicity is decreased. It should be noted that this toxicity is double and in addition to the presence of bacteria, at the concentrations lower than 20-25 ppm/cm<sup>2</sup>, it does not influence human cells.<sup>25,26</sup> In this study, the concentration of silver nanoparticles was 1.9 ppm/cm; according to the nanotechnology experts, this amount does not cause toxicity and no one was reported in the study. Wang compared silver ion and hydrocolloid gel dressings in the treatment of a diabetic foot and stated that both dressings did not show any significant difference in terms of infection control, epithelial reconstruction, and granulation tissue repair; however, the average healing process duration in silver ion group was shorter than gel group.<sup>27</sup> Chen et al compared silver nanoparticles, carbon fiber, hydrogel, and Vaseline gas dressings in terms of absorption ability and evaporation rate of stage II burning, and the findings showed that after carbon fiber, silver nanoparticle dressing showed high absorption ability with decreased healing process duration.<sup>28</sup> Therefore, it seems that silver nanoparticle dressing, due to the properties such as making humid environment in the ulcer area, ventilation, prevention of microorganism transmission, and removal of ulcer secretions, is one of the most ideal dressings to treat PUs. Similarly, in our study, silver nanoparticle dressing was ideal for SCI patients with PUs.

Hydrocolloid dressing creates a humid environment, simulates granulation, and improves the wound healing process. This dressing was transparent and did not require protective dressing.<sup>29</sup> Hydrocolloid dressings with high absorption ability and decreasing the pain and healing process duration are one of the most common dressings in healing the second and stage III PUs. However, their effectiveness compared with other modern dressings requires more studies.<sup>27</sup> In a study by Hollisaz et al, on PU healing, hydrocolloid, technical, and simple dressings were compared and it was shown that hydrocolloid dressing is more effective compared with other dressings and its healing process is shorter than other dressings.<sup>30</sup>

According to previous studies and current findings,

hydrocolloid dressing is effective in improving the healing process of stage II PUs. This dressing creates a humid environment and prevents mechanical debris of ulcers while removing the dressing, and it does not damage the granular tissue. In addition, due to the easy application of hydrocolloid dressing, it seems to be one of the desirable dressings.

One of the limitations of this study was the lack of access to silver nanoparticle dressings. Although this dressing is produced inside the country, some of its primary materials such as polymer coating are imported from other countries. Accordingly, since this study was conducted during the US sanctions against Iran, it was not possible to import some materials for 11 months. Hence, due to inaccessibility of this dressing, the present study was conducted with a considerable delay. This limitation in the future may cause problems for patients in terms of access to dressing materials. Moreover, numerous factors such as the immune system, tissue resistance, genetic differences, and nutrition influence the healing process of PUs and cannot be fully controlled by the researcher. However, the researcher attempted to cope with this challenge through using random sampling. Finally, it was difficult to generalize the results due to the small sample size and inability to exclude the confounding factors of these measures provided to both groups.

## Conclusion

Although there was no statistically significant difference between the two dressings in PU healing, the results of this study showed that both dressings could provide a moist environment for the ulcer and accelerate the ulcer healing process.

In addition to accelerating the healing process, silver nanoparticle dressing has antibacterial properties and prevents wound infection, so it may be a good option for using this dressing on infectious PUs. It is recommended that further studies with larger sample sizes be performed on patients with infectious PUs.

## Acknowledgments

This project was approved by the Nursing and Midwifery Care Research Center, Tehran University of Medical Sciences, Iran (NO: 90/130/1561). The authors are grateful to this center and all the participants.

## Authors' Contributions

FB, PA: Participated in concept design, definition of intellectual

## Research Highlights

### What is the current knowledge?

There are several treatments for PUs. But dressings are the most common.

### What is new here?

Both silver nanoparticle and hydrocolloid dressings are effective in treating PUs. But silver nanoparticle dressing speeds up wound healing.

content, clinical studies, manuscript preparation, manuscript editing, manuscript review, and approval of final draft; MZ, AHA: Participated in concept design, clinical studies, experimental studies, and data gathering; YBL: Participated in concept design, clinical studies, and reviewing the data analysis. YM: Performed the data analysis and statistical analysis.

### Ethical Issues

This study has been registered with the Nursing and Midwifery Care Research Center (NMCRC), School of Nursing and Midwifery, Tehran University of Medical Sciences (90/130/1561).

### Conflict of Interest

The authors declare no conflict of interest in this study.

### References

- Arango-Lasprilla JC, Ketchum JM, Francis K, Premuda P, Stejskal T, Kreutzer J. Influence of race/ethnicity on divorce/separation 1, 2, and 5 years post spinal cord injury. *Arch Phys Med Rehabil.* 2009; 90(8): 1371-8. doi: 10.1016/j.apmr.2009.02.006
- Stampas A, Tansy KE. Spinal cord injury medicine and rehabilitation. *Semin Neurol.* 2014; 34(5): 524-33. doi: 10.1055/s-0034-1396006
- Gibbs K, Beaufort A, Stein A, Leung TM, Sison C, Bloom O. Assessment of pain symptoms and quality of life using the International Spinal Cord Injury Data Sets in persons with chronic spinal cord injury. *Spinal Cord Ser Cases.* 2019; 5: 32. doi: 10.1038/s41394-019-0178-8
- Stockton L, Gebhardt KS, Clark M. Seating and pressure ulcers: clinical practice guideline. *J Tissue Viability.* 2009; 18(4): 98-108. doi: 10.1016/j.jtv.2009.09.001
- Bates-Jensen BM, Guihan M, Garber SL, Chin AS, Burns SP. Characteristics of recurrent pressure ulcers in veterans with spinal cord injury. *J Spinal Cord Med.* 2009; 32(1): 34-42. doi: 10.1080/10790268.2009.11760750
- Lechner A, Kottner J, Coleman S, Muir D, Beeckman D, Chaboyer W, et al. Outcomes for Pressure Ulcer Trials (OUTPUTs) project: review and classification of outcomes reported in pressure ulcer prevention research. *Br J Dermatol.* 2021; 184(4): 617-26. doi: 10.1111/bjd.19304
- Campani V, Pagnozzi E, Mataro I, Mayol L, Perna A, D'Urso F, et al. Chitosan gel to treat pressure ulcers: a clinical pilot study. *Pharmaceutics.* 2018; 10(1): 15. doi: 10.3390/pharmaceutics10010015
- Kaplan HM. *Neuromuscular Electrical Stimulation for Pressure Ulcer Prevention.* United States: University of Southern California; 2008.
- Lagana G, Anderson EH. Moisture dressings: the new standard in wound care. *J Nurse Pract.* 2010; 6(5): 366-70. doi: 10.1016/j.nurpra.2010.01.025
- Ebi WE, Hirko GF, Mijena DA. Nurses' knowledge to pressure ulcer prevention in public hospitals in Wollega: a cross-sectional study design. *BMC Nurs.* 2019; 18: 20. doi: 10.1186/s12912-019-0346-y
- Bluestein D, Javaheri A. Pressure ulcers: prevention, evaluation, and management. *Am Fam Physician.* 2008; 78(10): 1186-94.
- Aoyagi S, Onishi H, Machida Y. Novel chitosan wound dressing loaded with minocycline for the treatment of severe burn wounds. *Int J Pharm.* 2007; 330(1-2): 138-45. doi: 10.1016/j.ijpharm.2006.09.016
- Huang SS, Bowblis JR. Is the quality of nursing homes counter-cyclical? evidence from 2001 through 2015. *Gerontologist.* 2019; 59(6): 1044-54. doi: 10.1093/geront/gny148
- Fujimoto Y, Shimooka N, Ohnishi Y, Yoshimine T. Clinical evaluation of hydrocolloid dressings for neurosurgical wounds. *Surg Neurol.* 2008; 70(2): 217-20; discussion 20. doi: 10.1016/j.surneu.2007.06.091
- Aburayan WS, Booq RY, BinSaleh NS, Alfassam HA, Bakr AA, Bukhary HA, et al. The delivery of the novel drug 'halicin' using electrospun fibers for the treatment of pressure ulcer against pathogenic bacteria. *pharmaceutics.* 2020; 12(12): 1189. doi: 10.3390/pharmaceutics12121189
- Keogh SJ, Nelson A, Webster J, Jolly J, Ullman AJ, Chaboyer WP. Hydrocolloid dressings for treating pressure ulcers. *Cochrane Database Syst Rev.* 2018; 2018(4): CD010364. doi: 10.1002/14651858.CD010364.pub2
- Kalantari K, Mostafavi E, Afifi AM, Izadiyan Z, Jahangirian H, Rafiee-Moghaddam R, et al. Wound dressings functionalized with silver nanoparticles: promises and pitfalls. *Nanoscale.* 2020; 12(4): 2268-91. doi: 10.1039/c9nr08234d
- Khampiang T, Wongkittithavorn S, Chairwut S, Ekabutr P, Pavasant P, Supaphol P. Silver nanoparticles-based hydrogel: characterization of material parameters for pressure ulcer dressing applications. *J Drug Deliv Sci Technol.* 2014; 14(44): 91-100. doi: 10.1016/j.jddst.2017.12.005
- Sipahi S, Gungor O, Gunduz M, Cilci M, Demirci MC, Tamer A. The effect of oral supplementation with a combination of beta-hydroxy-beta-methylbutyrate, arginine and glutamine on wound healing: a retrospective analysis of diabetic haemodialysis patients. *BMC Nephrol.* 2013; 14: 8. doi: 10.1186/1471-2369-14-8
- Vanbelle S. Asymptotic variability of (multilevel) multirater kappa coefficients. *Stat Methods Med Res.* 2019; 28(10-11): 3012-26. doi: 10.1177/0962280218794733
- Mehrabani M, Hosseini MA, Nourozi Tabrizi K, Karimloo M. Comparison of honey dressing with hydrocolloid dressing effects on pressure ulcer healing of ICU hospitalized patients. *Journal of Health Promotion Management.* 2012; 1(3): 37-45. [Persian]
- He XQ, Chen HL. Hydrocolloid vs Gauze dressings in treating pressure ulcers: a meta-analysis of randomized controlled trials. *Wounds.* 2014; 26(9): 60-4.
- Lo SF, Hayter M, Chang CJ, Hu WY, Lee LL. A systematic review of silver-releasing dressings in the management of infected chronic wounds. *J Clin Nurs.* 2008; 17(15): 1973-85. doi: 10.1111/j.1365-2702.2007.02264.x
- Ai J, Kiasat-Dolatabadi A, Ebrahimi-Barough S, Ai A, Lotfikhshairesh N, Norouzi-Javidan A, et al. Polymeric scaffolds in neural tissue engineering: a review. *Arch Neurosci.* 2014; 1(1): 15-20. doi: 10.5812/archneurosci.9144
- GhavamiNejad A, Park CH, Kim CS. In situ synthesis of antimicrobial silver nanoparticles within antifouling zwitterionic hydrogels by catecholic redox chemistry for wound healing application. *Biomacromolecules.* 2016; 17(3): 1213-23. doi: 10.1021/acs.biomac.6b00039
- Chen X, Schluesener HJ. Nanosilver: a nanoparticle in medical application. *Toxicol Lett.* 2008; 176(1): 1-12. doi: 10.1016/j.toxlet.2007.10.004
- Wang J. Observation of the efficacy of Ionic silver dressing + GEL in local treating diabetic foot. *J Chongqing Med Univ.* 2003; 12: 34.
- Chen J, Han CM, Su GL, Tang ZJ, Su SJ, Lin XW. Randomized controlled trial of the absorbency of four dressings and their effects on the evaporation of burn wounds. *Chin Med J (Engl).* 2007; 120(20): 1788-91.
- Thomas S. Hydrocolloid dressings in the management of acute wounds: a review of the literature. *Int Wound J.* 2008; 5(5): 602-13. doi: 10.1111/j.1742-481X.2008.00541.x
- Hollisaz MT, Khedmat H, Yari F. A randomized clinical trial comparing hydrocolloid, phenytoin and simple dressings for the treatment of pressure ulcers [ISRCTN33429693]. *BMC Dermatol.* 2004; 4(1): 18. doi: 10.1186/1471-5945-4-18